

Case Report

Cardiac arrest caused by sibutramine obtained over the Internet: a case of a young woman without pre-existing cardiovascular disease successfully resuscitated using extracorporeal membrane oxygenation

Naofumi Bunya,¹  Keigo Sawamoto,¹ Shuji Uemura,¹ Ryoko Kyan,¹ Hiroyuki Inoue,¹ Junichi Nishida,² Hidemichi Kouzu,² Nobuaki Kokubu,² Tetsuji Miura,² and Eichi Narimatsu¹

¹Department of Emergency Medicine, Sapporo Medical University, Hokkaido, Japan, and ²Department of Cardiovascular, Renal and Metabolic Medicine, Sapporo Medical University, Hokkaido, Japan

Case: Sibutramine is a weight loss agent that was withdrawn from the market in the USA and European Union because it increases adverse events in patients with cardiovascular diseases. However, non-prescription weight loss pills containing sibutramine can be still easily purchased over the Internet.

A 21-year-old woman without history of cardiovascular diseases developed cardiac arrest. She was a user of a weight loss pills, containing sibutramine and hypokalemia-inducing agents, imported from Thailand over the Internet.

Outcome: She was successfully resuscitated without any neurological deficits by using extracorporeal membrane oxygenation for refractory ventricular fibrillation.

Conclusion: This case indicates that sibutramine can cause cardiac arrest even in subjects without pre-existing cardiovascular disease when combined with agents that promote QT prolongation.

Key words: cardiac arrest, extracorporeal membrane oxygenation, hypokalemia, QT prolongation, sibutramine

INTRODUCTION

IN RECENT YEARS, the use of spurious/falsey labelled/falsified/counterfeit medicines sold over the Internet has increased rapidly, raising concerns over the harmful effects they may have.¹ There are similar concerns regarding weight loss pills that are available to the general population over the Internet.² The pills can be obtained easily without a prescription anonymously by use of a credit card or online money transfer.

Sibutramine, a serotonin and norepinephrine re-uptake inhibitor, was used in the 1990s to treat obesity, but was frequently associated with increased cardiovascular events. The

Sibutramine Cardiovascular and Diabetes Outcome Study (SCOUT) showed that treatment with sibutramine for 5 years in subjects with pre-existing cardiovascular diseases significantly increased non-fatal myocardial infarction and non-fatal stroke, although the number of cardiovascular deaths or all-cause mortality was not increased.³ Because the benefits of sibutramine do not outweigh the risk of the cardiovascular events, it has been withdrawn by the USA and European Union. Sibutramine was never approved in Japan. Here we report a female patient who developed a cardiac arrest, despite no pre-existing cardiac disease, by sibutramine-containing weight loss pills imported using the Internet.

CASE

A 21-YEAR-OLD NON-OBESE woman was found unresponsive on the sidewalk and by-stander cardiopulmonary resuscitation (CPR) was initiated. On arrival of the emergency medical service, the patient's initial cardiac rhythm was ventricular fibrillation (VF). On the way to our hospital, return of spontaneous circulation was not achieved,

Corresponding: Naofumi Bunya, MD, Department Emergency Medicine, Sapporo Medical University, S1W16 Chuo-ku Sapporo, Hokkaido, 060-8543, Japan. E-mail: naobun1221@gmail.com
Received 8 Aug, 2016; accepted 30 Jan, 2017; online publication 29 Mar, 2017

Funding Information

No funding information provided.

although defibrillation was attempted twice concomitantly with conventional CPR. She had no past medical history or family history of any cardiac disorders.

On admission, she was still in VF arrest with agonal breathing. Due to a lack of response to four defibrillation attempts and administration of 3 mg epinephrine in total, the decision was made to resuscitate using extracorporeal membrane oxygenation (ECMO) for bringing forth certain circulation. Sixteen minutes after admission to our resuscitation bay (i.e., 36 min after the initial call for emergency medical service), ECMO was commenced. Her initial serum potassium measured during CPR was 3.8 mEq/L despite approximately 30 min of cardiac arrest (Table 1). Thirty minutes after starting ECMO, return of spontaneous circulation was achieved. After an intra-aortic balloon pump was placed, coronary angiography was carried out, indicating that the coronary arteries were normal. Chest computed tomography scan with contrast enhancement showed no abnormalities that could have led to the cardiac arrest. The patient was admitted to the intensive care unit (ICU), and therapeutic hypothermia was initiated in an attempt to bring her body temperature to 34°C. At the time of admission to the ICU, the patient's serum potassium level was 2.3 mEq/L and the QTc interval was 538 ms (Fig. 1, Table 2).

One day after the admission, her family brought to the hospital "weight loss pills" the patient had purchased from Thailand over the Internet. These pills contained sibutramine, hydrochlorothiazide, bisacodyl, chlorpheniramine, and a thyroid hormone (information regarding the contents was obtained from the Ministry of Health, Labor and Welfare of Japan's homepage regarding the health hazard due to unauthorized agents, <http://www.mhlw.go.jp/kinkyu/diet/jirei/030902-1.html>).

Therapeutic hypothermia was continued for 5 days. The patient's hemodynamic status gradually improved, the intra-aortic balloon pump and ECMO were removed on day 6 and

day 7, respectively, and she was extubated on day 8. Her QTc interval gradually shortened and normalized by day 9 (391 ms; Table 2).

As a possible cause of the cardiac arrest, cardiomyopathies, coronary vasospasm, Brugada syndrome, arrhythmogenic right ventricular cardiomyopathy, and congenital long QT syndrome were investigated, but these diseases were excluded based on the clinical data. Her hypokalemia did not reappear after the serum potassium level was corrected during her stay in the ICU. An automated implantable cardioverter defibrillator was implanted on day 42, and she was discharged on day 51 with no neurological deficits. Before her discharge, the patient admitted that she took weight loss pills from Thailand only one day's dose at a time.

DISCUSSION

TO OUR KNOWLEDGE, the present report is the first case of cardiac arrest by non-prescribed sibutramine in a subject without cardiovascular disease. There are two previously published reports of sibutramine-induced cardiac arrest, but in both cases, sibutramine was prescribed for 1–4 months to treat obesity before the cardiac arrest.^{4,5} In the reported cases^{4,5} and also the present patient, the QT interval was significantly prolonged at admission and was normalized after discontinuation of sibutramine. The significant impact of this agent on ventricular repolarization, that is, significant increase in QT dispersion, was shown in 65 consecutive patients.⁶ Increased QT dispersion was shown in several forms of heart disease and also is associated with increased risk of ventricular tachyarrhythmias.^{7–9} Kim *et al.*¹⁰ reported that sibutramine preferentially inhibits the hERG potassium channel through the residues Y652 and F656 and this hERG potassium channel is an important contributor to drug-induced QT interval prolongation and cardiac arrhythmias.¹¹ This mechanism may cause prolongation of the QT interval. Unfortunately, the effect of sibutramine on the QT interval was not evaluated in the SCOUT study.³ Nevertheless, the findings in the cases of cardiac arrest associated with sibutramine suggest that this agent should be avoided in patients already taking medications that potentially prolong the QT interval.

In the present case, the diet pills consisted of not only sibutramine but also a laxative (bisacodyl) and a diuretic (hydrochlorothiazide). How long and how regularly the patient had taken the pill before the cardiac arrest could not be confirmed, although she claimed that she had taken only one day's dose. We postulate that hypokalemia by hydrochlorothiazide and bisacodyl promoted

Table 1. Blood gas analysis at admission

pH	6.951
pCO ₂	57.3 mmHg
pO ₂	75.4 mmHg
HCO ₃ ⁻	12 mmol/L
Lactate	118 mg/dL
Na ⁺	139 mmol/L
K ⁺	3.8 mmol/L
Cl ⁻	108 mmol/L
Ca ²⁺	1.25 mmol/L

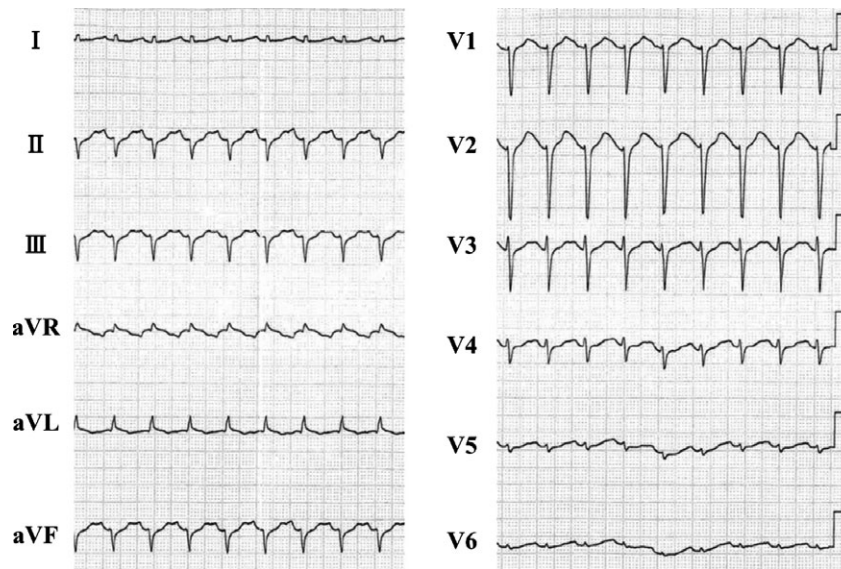


Fig. 1. Electrocardiogram of a 21-year-old woman on admission to the intensive care unit following cardiac arrest caused by sibutramine. The electrocardiogram shows the QTc interval prolongation.

Table 2. Electrocardiogram findings in a 21-year-old woman following cardiac arrest caused by sibutramine

	HR, b.p.m.	QT interval, ms	QTc interval, ms	QRS complex, ms
Day 1	134	360	538	80
Day 2	111	400	544	80
Day 3	133	360	536	80
Day 4	139	280	426	80
Day 6	120	320	453	60
Day 7	118	320	449	60
Day 8	124	280	403	60
Day 9	117	280	391	60
Day 11	111	280	381	60

HR, heart rate.

QT prolongation by sibutramine and the near-fatal arrhythmia.

There was no witness of the onset of the cardiac arrest in the present case. As the patient was suffering from VF with agonal breathing¹² by the time the patient was admitted to our resuscitation bay, she was likely found shortly after collapse. However, VF was refractory to conventional treatment; we used ECMO as a recent study showed its clinical benefits.^{13,14} By a multidisciplinary approach including ECMO, we could discharge the present patient with no neurological abnormalities.

CONCLUSION

EVEN BANNED HIGH-RISK agents are readily accessible to the general population over the Internet, and emergency physicians need to be aware of the potential toxicities of weight loss agents. Sibutramine is one such agent and potentially causes cardiac arrest even in subjects without pre-existing cardiovascular disease, particularly when combined with drugs that lead to QT prolongation.

CONSENT

WRITTEN CONSENT FOR the publication of this case report and any accompanying images was obtained from the patient.

CONFLICT OF INTEREST

NONE DECLARED.

REFERENCES

- 1 World Health Organization (WHO). Medicines: spurious/false-labelled/falsified/counterfeit (SFFC) medicines. [Fact sheet No 275]. May 2012; <http://www.who.int/mediacentre/factsheets/fs275/en/>. [cited 1 December 2015].
- 2 Nazeri A, Massumi A, Wilson JM *et al.* Arrhythmogenicity of weight-loss supplements marketed on the Internet. *Heart Rhythm* 2009; 6: 658–62.

- 3 James WP, Caterson ID, Coutinho W *et al.* Effect of sibutramine on cardiovascular outcomes in overweight and obese subjects. *N. Engl. J. Med.* 2010; 363: 905–17.
- 4 Ernest D, Gershenson A, Corallo CE *et al.* Sibutramine-associated QT interval prolongation and cardiac arrest. *Ann. Pharmacother.* 2008; 42: 1514–7.
- 5 Harrison-Woolrych M, Clark DW, Hill GR *et al.* QT interval prolongation associated with sibutramine treatment. *Br. J. Clin. Pharmacol.* 2006; 61: 464–9.
- 6 Yalcin AA, Yavuz B, Ertugrul DT *et al.* Elevation of QT dispersion after obesity drug sibutramine. *J. Cardiovasc. Med. (Hagerstown)* 2010; 11: 832–5.
- 7 Trusz-Gluza M, Wozniak-Skowerska I, Giec L *et al.* Dispersion of the QT interval as a predictor of cardiac death in patients with coronary heart disease. *Pacing Clin. Electrophysiol.* 1996; 19: 1900–4.
- 8 Miorelli M, Buja G, Melacini P *et al.* QT-interval variability in hypertrophic cardiomyopathy patients with cardiac arrest. *Int. J. Cardiol.* 1994; 45: 121–7.
- 9 Grimm W, Steder U, Menz V *et al.* Clinical significance of increased QT dispersion in the 12-lead standard ECG for arrhythmia risk prediction in dilated cardiomyopathy. *Pacing Clin. Electrophysiol.* 1996; 19: 1886–9.
- 10 Kim KS, Kim EJ, Lee HA *et al.* Effect of sibutramine HCl on cardiac hERGK⁺ channel. *Mol. Cell. Biochem.* 2009; 320: 125–31.
- 11 Sanguinetti MC, Jiang C, Curran ME *et al.* A mechanistic link between an inherited and an acquired cardiac arrhythmia: HERG encodes the LK^r potassium channel. *Cell* 1995; 81: 299–307.
- 12 Rea TD. Agonal respirations during cardiac arrest. *Curr. Opin. Crit. Care* 2005; 11: 188–91.
- 13 Sakamoto T, Morimura N, Nagao K *et al.* Extracorporeal cardiopulmonary resuscitation versus conventional cardiopulmonary resuscitation in adults with out-of-hospital cardiac arrest: a prospective observational study. *Resuscitation* 2014; 85: 762–8.
- 14 Stub D, Bernard S, Pellegrino V *et al.* Refractory cardiac arrest treated with mechanical CPR, hypothermia, ECMO and early reperfusion (the CHEER trial). *Resuscitation* 2015; 86: 88–94.