



Research Paper

# Transoral robotic surgery for obstructive sleep apnea syndrome: Principles and technique



Claudio Vicini, Filippo Montevercchi, Riccardo Gobbi, Andrea De Vito, Giuseppe Meccariello\*

Department of Head-Neck Surgery, Otolaryngology, Head-Neck and Oral Surgery Unit, Morgagni Pierantoni Hospital, Forlì, Italy

Received 5 April 2017

Available online 13 June 2017

## KEYWORDS

Transoral robotic surgery;  
TORS;  
Partial glossectomy;  
Midline glossectomy;  
Posterior glossectomy;  
Obstructive sleep apnea;  
Sleep surgery

**Abstract** *Objective:* The present study is a review of transoral robotic surgery (TORS) for the treatment of obstructive sleep apnea-hypopnea syndrome (OSAHS).

*Methods:* The review presents the experience of the robotic center that developed the technique with regards to patient selection, surgical method, and post-operative care. In addition, the review provides results of a systematic review and meta-analysis of the complications and clinical outcomes of TORS when applied in the management of OSAHS.

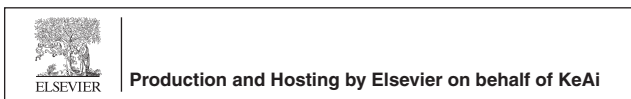*Results:* The rate of success, defined as 50% reduction of pre-operative AHI and an overall AHI <20 events/h, is achieved in up to 76.6% of patients with a range between 53.8% and 83.3%. The safety of this approach is reasonable as the main complication (bleeding) affected 4.2% of patients (range 4.2%–5.3%). However, transient dysphagia (7.2%; range 5%–14%) does compromise the quality of life and must be discussed with patients preoperatively.

*Conclusions:* TORS for the treatment of OSAHS appears to be a promising and safe procedure for patients seeking an alternative to traditional therapy. Appropriate patient selection

\* Corresponding author. Medico-Chirurgo Specialista in Otorinolaringoiatria, Chirurgia Endoscopica del Naso e dei Seni Paranasali, Qualificato in Disturbi Respiratori Ostruttivi in Sonno, Ospedale Morgagni-Pierantoni, Forlì, Italy. Fax: +39 0543 735660.

E-mail address: [drmeccariello@gmail.com](mailto:drmeccariello@gmail.com) (G. Meccariello).

Peer review under responsibility of Chinese Medical Association.



remains an important consideration for successful implementation of this novel surgical approach requiring further research.

Copyright © 2017 Chinese Medical Association. Production and hosting by Elsevier B.V. on behalf of KeAi Communications Co., Ltd. This is an open access article under the CC BY-NC-ND license (<http://creativecommons.org/licenses/by-nc-nd/4.0/>).

## Introduction

The first transoral robotic surgery (TORS) for OSAHS was carried out in May 2008.<sup>1</sup> It was devised as a robotically assisted transoral version of Chabolle's operation (open transcervical Tongue Base Reduction Hyo-epiglottoplasty, TBRHE) for moderate to severe obstructive sleep apnea. In 2014, the first multicenter study about TORS in which a cohort of 243 cases from 7 groups in 5 different countries was published.<sup>2</sup> Today, TORS is included in the surgical routine for sleep disordered breathing (SDB) treatment in a great number of ENT departments. Although cohort sizes are limited in most patient series, many groups have completed more than 50 consecutive TORS for OSAHS to date. From March 2008 until June 2016, a total of 240 TORS procedures for OSAHS were performed at our Institution. This review will summarize and present our personal experience as well as the worldwide expertise with robotic surgery for the management of OSAHS.

## Materials and methods


### Patient selection

The oropharyngeal area, in OSAHS patients, may be considered a unique, complex anatomical entity, defined as SubGlosso-SupraGlottic (SGSG) region. Its obstructive role in sleep apnea may be directly observed by awake or sedated endoscopy, as well as by imaging. Histology and geometry of the enlarged base of tongue differs widely among different patients. If the obstructing tissue is mainly lymphoid tissue, as is the case with lingual tonsil hyperplasia, a straight forward lingual tonsillectomy may be all that is the required. In other cases, a variably thin lymphoid mantle covers a true muscle enlargement, requiring tongue base debulking or reduction that, if necessary, includes removal of a midline wedge of oral tongue. A predictable array of vessels and nerves run inside the tongue muscle mass and requires careful handling.<sup>3</sup> If the epiglottis contributes to the airway obstruction during sleep, it may be fixed after tongue reduction. A primary or secondary obstructing epiglottis may be included in the main application of TORS. According to the patient morbid anatomy and according to the surgeon's preference, TORS in SGSG may be included in a multi-level approach including nasal and palate surgery as well, in a single step setting or in pre-planned staged steps. The robot may also be applied for palatal reshaping (palatine tonsillectomy and palate/pharyngoplasty). This approach may be justified for training and skill development. However, palate TORS is by far less

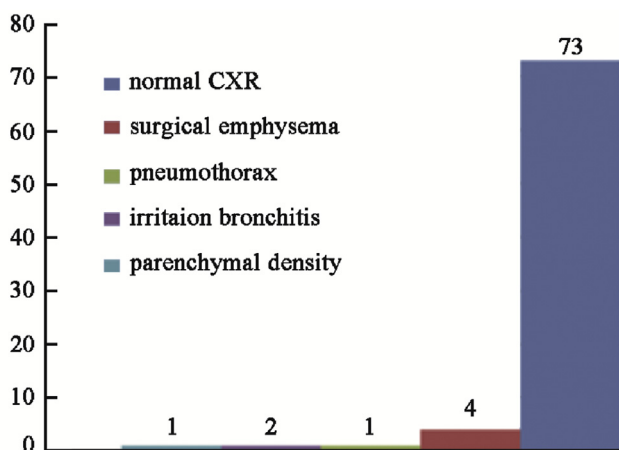
cost effective than conventional palate surgery, and it is difficult to apply TORS to newer refinements such as Expansion Sphincter Pharyngoplasty (ESP) or Barbed Relocation Pharyngoplasty (BRP),<sup>4</sup> which are now our preferred palate procedures. In this group of severe patients at high cardiovascular and neuromotor risk, the use of an expensive but successful technique is justified. TORS may be justified in certain cases of symptomatic patients with mild to moderate OSAHS but with a very huge tongue base. Most of our patients are overweight males, but patients with a pre-operative BMI less than 30 kg/m<sup>2</sup> are preferred. Mouth opening measured as interincisive distance of 25 mm or more is a pre-requisite for sufficient exposure. About 70% of our cases were primary surgeries after CPAP refusal or non-adherence. In our center, Drug Induced Sleep Endoscopy (DISE) has been found to be useful for many reasons and is currently included in routine TORS work-up. From the strictly diagnostic point of view, DISE offers additional information about the dynamic behavior of the base of tongue (BOT) and supraglottic region (SG). In the event of significant lateral wall collapse observed during DISE, TORS may not be effective. In addition, DISE provides an opportunity to determine the difficulty of the surgical exposure.

### Technique

Nasotracheal intubation must be considered the first option whenever possible. It is proved to be the most practical from the surgical point of view. In this setting, the tube is posterior to the center of the surgical field and is easily manipulated by the head assistant. If nasal intubation is not possible, oropharyngeal intubation can be carried out. Planned tracheotomy is recommended in multilevel surgery; in case of SGSG as single procedure, tracheostomy may be not performed. The patient is positioned in supine position, with neck flexed and head extended (sniffing position). A 0–0 suture is routinely passed through the tongue body for pulling out the BOT. Our first-choice mouth-gag is Davis-Meyer or Crowe-Davis, which are absolutely preferred to FK for this type of surgery. In all but a few cases, the shortest and widest blade is preferred. We do not use teeth or soft tissue protecting devices in order to avoid any reduction of the baseline narrow mouth opening commonly observed in OSAHS patients. The next step is to insert the scope and the couple of instruments in the robotic arms. The scope is a 12 mm (may be 8 mm), 30° facing up. In TORS, the head surgeon is usually instructed to keep in sight the scope and instruments' tips all times in order to prevent accidental tissue penetration in case of blind maneuvers. Following the scope, a couple of 5 mm instruments is mounted into the arms:



**Fig. 1** Patient perceived swallowing difficulty as measured before and after TORS for OSAHS (*n* = 78). Lower score indicates less swallowing difficulty.



**Fig. 2** Findings on video fluoroscopic swallow study in patients with dysphagia following TORS for OSAHS (*n* = 80).

1. A round tip cautery.
2. A Maryland forceps.

We do not routinely use any kind of laser (Thallium or CO<sub>2</sub>) for SGSG surgery in OSAHS patients. Laser devices, in our experience, did not give advantages rather than monopolar scalpel and those devices are developed by other

**Table 1** The type and rate of complications observed after TORS for OSAHS (*n* = 243).

Complication type	<i>n</i>	Rate
Intraoperative bleeding	1	0.4%
Post-operative bleeding (controlled surgically)	4	1.6%
Post-operative bleeding (spontaneously resolved)	7	2.9%
Transient pharyngeal globus	1	0.4%
Transient pharyngeal edema	1	0.4%
Transient hypogeusia	35	14.4%
Pharyngeal stenosis	1	0.4%

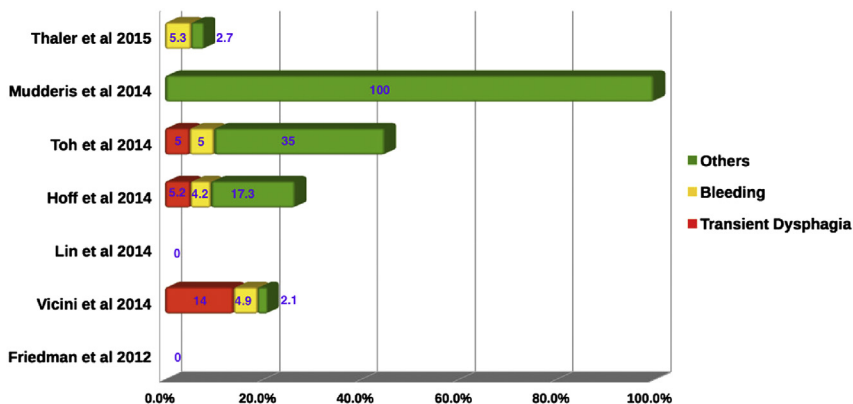
company then they represent an adding cost. The SGSG TORS procedure includes a couple of surgical steps in sequence:

1. The Tongue Base Reduction, both sides.
2. The Supra-Hyoid Horizontal Epiglottectomy.

The procedure has been described in greater detail elsewhere.<sup>5</sup>

**Post-operative management**

If the patient has not undergone tracheotomy, overnight ICU stay with continued intubation can be considered per surgeon’s preference and the capabilities of the center. Otherwise the patient is kept under observation in the recovery room and extubation is planned after 3–6 h. A feeding tube is optional, and a liquid diet is begun on the first postoperative day. Continuous pulse oximetry is recommended, and the patient should be monitored closely for bleeding. Postoperative intravenous steroids can help to reduce nausea, airway edema, and pain from the inflammatory response. A patient-controlled analgesic pump has proved to be useful. In Forlì, the average hospital stay is 5 days. Patients are followed closely following discharge. Diet is normalized as healing progresses, and formal therapist-directed swallowing therapy is rarely required (<10% of cases). Postoperative polysomnography is performed once healing is complete, usually within 6 months after surgeries.



**Fig. 3** Systematic review of the rates and types of complications commonly observed after TORS for OSAHS.

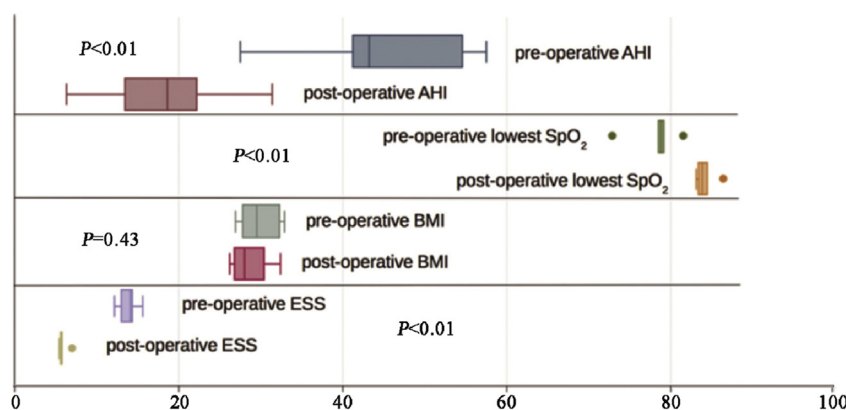


Fig. 4 Meta-analysis of clinical outcomes following TORS for OSAHS ( $n = 243$ ).

### Postoperative functional profile

In our experience, the average pain scored is below 6 (measured by means of Visual Analogue Scale (VAS)) in the 3 day window following surgery. As expected, the pain is minimally higher in multilevel procedures. Our group evaluated the short and long-term swallowing outcomes following TORS for OSAHS.<sup>6</sup> In the short-term (1 month post-operatively), there was minimal significant impact on the swallowing function ( $P = 0.56$ ) based on the MD Anderson Dysphagia Inventory (MDADI) questionnaire (Fig. 1). The degree of dysphagia as demonstrated by video fluoroscopic swallow study (VFSS) was not related to the volume of tissue removed ( $P = 0.72$ ). There were no complaints of swallowing dysfunction in the long term (up to 32 months post-operatively), and any complaints spontaneously resolved within 3 months post-operatively in all patients with initial abnormal findings on VFSS (Fig. 2).

### Complications

The safety of this approach is reasonable as the main complication (bleeding) affected 4.2% of patients (range 4.2%–5.3%). However, transient dysphagia (7.2%; range 5%–14%) does compromise the quality of life and must be discussed with patients preoperatively. Recently our group published a meta-analysis showing the rates and types of complication (Fig. 3).<sup>7</sup> The full range of encountered complications in our experience is listed in Table 1.

### Conclusion

In our meta-analysis, there was compelling evidence that TORS reduces AHI and daytime sleepiness in the current body of published studies. The rate of success, defined as 50% reduction of pre-operative AHI and an overall AHI < 20

events/h, is achieved in up to 76.6% of patients with a range between 53.8% and 83.3% (Fig. 4). Unfortunately, reliable predictors of who will have the best surgical response remains an area of active research but holds the potential for even better outcomes in the future.

### References

1. Vicini C, Dallan I, Canzi P, Frassinetti S, La Pietra MG, Montevecchi F. Transoral robotic tongue base resection in obstructive sleep apnoea-hypopnoea syndrome: a preliminary report. *ORL J Otorhinolaryngol Relat Spec.* 2010;72(1):22–27.
2. Vicini C, Montevecchi F, Campanini A, et al. Clinical outcomes and complications associated with TORS for OSAHS: a benchmark for evaluating an emerging surgical technology in a targeted application for benign disease. *ORL J Otorhinolaryngol Relat Spec.* 2014;76(2):63–69.
3. Vicini C, Dallan I, Canzi P, et al. Transoral robotic surgery of the tongue base in obstructive sleep apnea-hypopnea syndrome: anatomic considerations and clinical experience. *Head Neck.* 2012;34(1):15–22.
4. Vicini C, Hendawy E, Campanini A, et al. Barbed reposition pharyngoplasty (BRP) for OSAHS: a feasibility, safety, efficacy and teachability pilot study. "We are on the giant's shoulders". *Eur Arch Otorhinolaryngol.* 2015;272(10):3065–3070.
5. Vicini C, Hoff PT, Montevecchi F. *Transoral Robotic Surgery for Obstructive Sleep Apnea.* Springer; 2017.
6. Eesa M, Montevecchi F, Hendawy E, D'Agostino G, Meccariello G, Vicini C. Swallowing outcome after TORS for sleep apnea: short- and long-term evaluation. *Eur Arch Otorhinolaryngol.* 2015; 272(6):1537–1541.
7. Meccariello G, Cammaroto G, Montevecchi F, et al. Transoral robotic surgery for the management of obstructive sleep apnea: a systematic review and meta-analysis. *Eur Arch Otorhinolaryngol.* 2017;274(2):647–653.