

A Newly Designed Intramedullary Nail for the Treatment of Diaphyseal Forearm Fractures in Adults

Abstract

Background: The treatment of diaphyseal forearm fractures using open reduction and plate fixation is generally accepted as the best choice in many studies. However, periosteal stripping, haematoma evacuation may result in delayed union, nonunion and infection. Refracture after plate removal is another concern. To overcome these problems intramedullary nails (IM) with different designs have been used with various outcomes. However previous IM nails have some shortcomings such as rotational instability and interlocking difficulties. We evaluated the results of newly designed IM nail in the treatment of diaphyseal forearm fractures in adults. **Materials and Methods:** 32 patients who had been treated with the interlocking IM nail for forearm fractures between 2011 and 2014 were included in this study. There were 23 males and 9 females with mean age of 36 years (range 18-68 years). 22 patients (68.8%) had both bone fractures. Nine patients (28.1%) had open fractures. The remaining ten patients (31.2%) had radius or ulna fractures. Grace and Eversmann rating system was used to assess functional evaluation. Patient reported outcomes were assessed using the Disabilities of the Arm, Shoulder and Hand (DASH) questionnaire scores. **Results:** Union was achieved in all patients. The mean followup was 17 months (range 13 – 28 months). According to the Grace-Eversmann criteria, 27 patients (87.5%) had excellent or good results. The mean DASH score was 14 (range 5-36). Overall complication rate was 12.5%. Superficial infection was encountered in two patients. One patient had delayed union, however fracture healed without any additional surgical procedure. One patient who had open grade 3A, comminuted proximal third radius fracture developed radioulnar synostosis. **Conclusions:** The new design IM interlocking forearm nail provides satisfactory functional and radiological outcomes in the treatment of adult diaphyseal forearm fractures.

Keywords: Forearm fractures, intramedullary nail, radius, ulna

MeSh terms: Nailing, intramedullary, forearm injuries, radius fractures, ulna

**Ibrahim Azboy,
Abdullah Demirtaş¹,
Celil Alemdar²,
Mehmet Gem²,
Kadir Uzel²,
Huseyin Arslan²**

Department of Orthopaedic Research, The Rothman Institute at Thomas Jefferson University, Philadelphia, PA, USA,

¹Department of Orthopaedics and Traumatology, Göztepe Training and Research Hospital, Medeniyet University, Istanbul,

²Department of Orthopaedics and Traumatology, Dicle University Medical Faculty, Diyarbakir, Turkey

Introduction

Diaphyseal forearm fractures should be stabilized to maintain axial and rotational alignment.^{1,2} Open reduction and internal fixation with plate osteosynthesis usually provides adequate reduction and high union rates. However, periosteal stripping and excessive cortical contact may disrupt the blood supply.³ Limited contact dynamic compression plate was developed to reduce the plate's interference with cortical perfusion, thus decreasing cortical porosis.⁴ Subsequently, locking compression plate was developed which provides stronger biological fixation.⁵ However, plates still have some disadvantages such as causing soft-tissue damage and evacuation of the fracture hematoma that may results in delayed fracture union, nonunion, and infection.^{6,7} Patients can also experience

symptoms related to the long incisions, hardware irritation, and refracture following implant removal.^{8,9}

Intramedullary (IM) nailing has been used in the treatment of forearm fractures.¹⁰ However, Kirschner wires (K-wires), Steinmann pins, or Rush rods resulted in high nonunion rates due to a lack of rotational control.^{10,11} To overcome the rotational control of previous nails, Street used square nail.¹² The main drawback of this nail was the distraction of the fracture with increased risk of nonunion (7%) and the need for cast immobilization. Crenshaw introduced Fore Sight locking nail system¹³ and favorable results have been reported.¹⁴ However, there were some disadvantages such as distal locking of ulnar nail was difficult, posterior interosseous nerve was at risk during proximal locking of the radial

Address for correspondence:

*Dr. Ibrahim Azboy,
Department of Orthopaedics,
Rothman Institute, Thomas
Jefferson University, Sheridan
Building, 10th Floor, 125,
South 9th Street, Suite 1000,
Philadelphia, PA 19107, USA.
E-mail: ibrahimazboy@hotmail.
com*

Access this article online

Website: www.ijoonline.com

DOI:
10.4103/ortho.IJOrtho_79_16

Quick Response Code:



How to cite this article: Azboy I, Demirtaş A, Alemdar C, Gem M, Uzel K, Arslan H. A newly designed intramedullary nail for the treatment of diaphyseal forearm fractures in adults. Indian J Orthop 2017;51:697-703.

This is an open access article distributed under the terms of the Creative Commons Attribution-NonCommercial-ShareAlike 3.0 License, which allows others to remix, tweak, and build upon the work non-commercially, as long as the author is credited and the new creations are licensed under the identical terms.

For reprints contact: reprints@medknow.com

nail, and fluoroscopy exposure time was long.^{15,16} Lee *et al.* used prebent locking nail which allows locking only for distal radius and proximal ulna.¹⁷ However, they reported ulnar nonunion to be due to instability of ulnar fracture.

Recently, a new type of forearm nail was introduced.¹⁸ Radial IM nail that is precontoured to the shape of the bone is fluted at the proximal end to enhance rotational fracture control. The distal interlocking screw head is locked to the nail and also eliminates fluoroscopy use. The distal locking hole is located at the distal tip of the nail which allows surgeon placing the locking screw under direct vision. Ulnar IM nail can provide compression at the fracture site, and its distal locking system does not need fluoroscopy. This IM nail with its unique properties may address the problems encountered with the previous forearm nails.

This study evaluates the outcomes of newly designed interlocking IM nail in the treatment of diaphyseal forearm fractures.

Materials and Methods

32 consecutive patients who underwent interlocking IM nail (radius elastic anatomic interlocking IM nail and interlocking IM ulnar nail, TST Rakor Tibbi Aletler San. Ve Tic. Ltd., Şti., Istanbul, Turkey) in closed or open Gustilo Anderson grade I, II, and IIIA forearm diaphyseal fractures between 2011 and 2014 were included in this study. There were 23 males and 9 females. The mean age was 36 years (range 18–68 years). Exclusion criteria were a floating elbow, a Monteggia fracture, a Galeazzi fracture, a pathologic fracture, rheumatoid arthritis treated with corticosteroids for a long period of time, and a history of previous fractures or abnormalities of the affected limb. The study was approved by the Institutional Ethics Committee. Informed consent was obtained from the patients. An electronic query followed by manual chart review was performed to collect the data. We have started to use these new nails from the certain time for diaphyseal forearm fractures except open-grade IIIB and IIIC fractures. Although the data of this study is collected prospectively we decided to perform the study later. Therefore we got approval from our institutional ethics committee as a retrospective study.

The AO/OTA classification was used to classify the fractures.¹⁹ Table 1 shows the distribution of patients according to this classification. 22 patients (68.8%) had both bone fractures and the remaining ten patients (31.2%) had radius or ulna fractures only. Nine patients (28.1%) had open fractures according to the criteria defined by Gustilo and Anderson [Table 2].²⁰

Seven patients (21.9%) had concomitant injuries. Two had fractures of the tibia, two had a fracture of the contralateral humerus, two had a fracture of the pelvis, one had a thorax, and one had abdominal injuries. The mechanism of

Table 1: Distribution of the fractures according to the AO/OTA classification

Fracture type	n
A1	2
A2	4
A3	6
B1	2
B2	6
B3	5
C1	4
C2	3
C3	0
Total	32

Table 2: Details of the treatment group

Parameters	Value
Number of patients	32
Mean age (years)	35 (18-68)
Gender (male), n (%)	23 (71.9)
Injury mechanism, n (%)	
Motor vehicle accident	11 (34.4)
Injury from falling down	8 (25)
Sports injury	6 (18.7)
Gunshot injury	4 (12.5)
Industrial accident	3 (9.4)
Fractured bone, n (%)	
Ulna	3 (9.4)
Radius	7 (21.9)
Both bones	22 (68.7)
Side of fracture (right), n (%)	24 (75)
Soft-tissue coverage, n (%)	
Closed	23 (71.9)
Open	9 (28.1)
Grade I	4 (12.5)
Grade II	1 (3.1)
Grade IIIA	4 (12.5)
Nerve injury at presentation, n (%)	
Radial	1 (3.1)
Ulnar	2 (6.3)
Ulnar and median	1 (3.1)
Total	4 (12.5)

injury was traffic accident in 11 patients (34.4%), fall in eight patients (25%), sports injury in six patients (18.7%), gunshot injury in four patients (12.5%), and work related injury in three patients (9.4%) [Table 2].

All open fractures received urgent debridement and irrigation, immediate fixation, and primary wound closure on the date of admission. The average time from injury to surgery was 3 days (range 1–18 days).

Specifications of implant design

The IM nails are made from titanium alloy. The radial nail provides sufficient bending, axial and rotational stability with their different proximal designs, and does not require

the use of fluoroscopy and a guide or an^{18,21} additional incision for distal interlocking [Figure 1]. The nail provides 3-point fixation due to its parabolic body, 10° anterior-angled oblong proximal-fluted design in the proximal 3 cm part, and 15° anterior-angled design in the distal 3 cm part. The design of the proximal and distal ends provides rotational stability and restores radial bowing. Distal static locking can be achieved by placing a locking screw through the 17° proximal-volar angled, oblique hole [Figure 2]. Distal static locking screw hole is located at the distal tip of the nail. After inserting the nail, this hole remains over the cortex which provides distal locking without fluoroscopy. In addition, this hole provides a locking with 17° of proximal and volar angle. This angle prevents the locking screw from directing toward the distal joint surface of the radius. Locking screws are 2.7 mm in diameter, and they are available in 6, 18, 20, 22, and 24-mm lengths. Diameter choices for the radial nails are 3, 3.5, and 4 mm, and the length choices for the nail are 18, 19, 20, 21, 22, 23, and 25 cm. The same nail can be used for the right and left radius.

The IM ulnar nail is solid, round, and unreamed [Figure 3].¹⁸ Distal locking can be achieved by one or more locking screws passing through the eight semi-oval transverse grooves on the distal 3 cm of the nail [Figure 4a and b]. Each semi-oval groove is 3 mm in dimension. There is 1 mm distance between the semi-oval grooves. As the distal part of ulna is narrow, the locking guide is near the ulna and the ulna is covered only with the skin in the lateral distal part of the wrist fluoroscopy which was not required during distal locking. Bicortical ulnar drilling over the guide was considered enough to insert distal ulnar locking screws. The




Figure 1: View of the ulnar intramedullary nail over application guide



Figure 2: Parabolic shape of the intramedullary radial nail and view of the distal locking screw

nail allows static, dynamic, and single-cortex interlocking using its proximally located three holes, round, oval, and proximally oblique [Figure 5]. Dynamic interlocking can be made through the oval hole. Single-cortex interlocking can be performed in any direction (360°) with an angle of 20° from the proximal oblique hole toward the nail axis [Figure 6]. The proximal diameter is 6 mm. Diameter choices for the distal part are 3.5, 4, 4.5, 5, and 6 mm, and 22 different lengths were available. The first 5 cm of proximal part of nails were 6 mm in diameter. The same nail can be used for the right and left ulna.

Operative procedure

First-generation cephalosporin was used for prophylaxis. All operations were performed under tourniquet control in the supine position. Closed reduction was attempted in all cases. If closed reduction could not be achieved, mini-open reduction by placing a 2-cm incision at the fracture line was performed. If both bones were fractured, the ulna was approached first. The nail for a radial and ulnar fracture was determined by measuring the length and diameter of the medullary canal on anteroposterior and lateral radiographs of the uninjured forearm.

A dorsal 2 cm incision was made over the second tunnel for radial fracture. The nail was inserted into the medullary canal through an entry hole created with an awl in the distal end of the radius, just radial to the Lister's tubercle. Under fluoroscopic guidance, the selected nail




Figure 3: The ulnar intramedullary nail is solid, round, and introduced unreamed. Distal locking can be achieved by passing one or more locking screws through the eight transverse grooves on the distal end

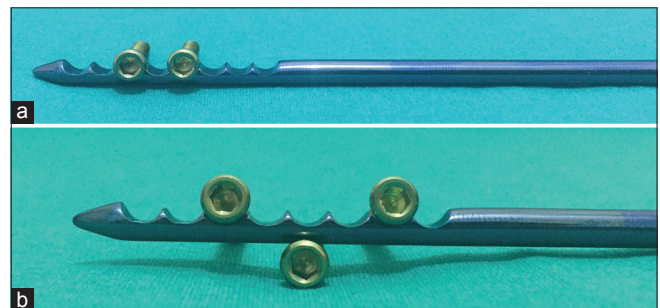


Figure 4: (a and b) The distal locking options of the interlocking intramedullary ulnar nail




Figure 5: The proximal design of ulnar intramedullary nail allows static, dynamic, and single-cortex interlocking. SH: Static hole, OOH: Oval oblique hole, POH: Proximal oblique hole

with nail holder was gently moved forward past the fracture site and up to the proximal metaphysis. Then, distal interlocking was performed under direct vision without fluoroscopy using an obliquely oriented locked screw. The nail position and fracture reduction were assessed fluoroscopically.

A similar procedure was used for an ulnar fracture. A 2-cm, longitudinal incision was made from the tip of the olecranon. A 2-mm K-wire was introduced into the medulla 6.5 mm proximal and 3 mm lateral to the most prominent part of the olecranon tip. A cannulated drill was advanced 5 cm into the medulla over the K-wire. The nail was inserted using nail holder. Then, distal locking screws were inserted without fluoroscopy. Proximal interlocking can be performed as preferred. Static or oblique interlocking was preferred in Type-B (wedge) and Type-C (complex) fractures. Dynamic interlocking screw was preferred to achieve compression in Type-A (simple) fractures.

Closed reduction was achieved in 22 (69%) fractures. The remaining 10 fractures (31%) were reduced through mini incisions. Postoperatively, long-arm splints were applied for 2 weeks in complex fractures (Type-C). Active range of motion of elbow and wrist exercises was initiated immediately.

Patient evaluation

The patients were followed up by X-ray studies every month until the fracture union was achieved. Bone union was defined as the presence of bridging the periosteal callus in three or four cortices in the anteroposterior and lateral radiographs. According to the criteria proposed by Anderson *et al.*,¹ fracture healing in <6 months was considered to have union; fracture healing lasting longer than 6 months without the need for additional surgical intervention was considered as delayed union, and the absence of fracture healing requiring additional surgery was considered as nonunion.

Grace and Eversmann rating system²² was used to assess functional evaluation. With the use of a forearm goniometer, the ranges of pronation and supination were evaluated according to the neutral zero method, with the elbow flexed 90°, and were recorded as a percentage of the range of motion on the contralateral side. The results were rated as excellent when the fracture had united and there was at least 90% of the normal forearm rotation arc,

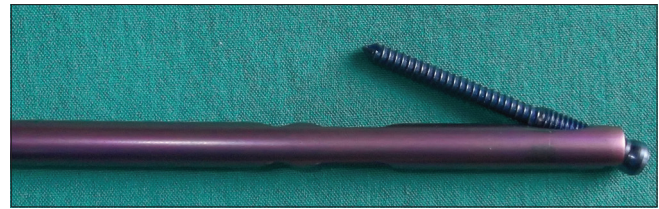

Figure 6: Single-cortex locking through the proximal oblique hole

good when the fracture had united and there was 80%–89% of the rotation arc, acceptable when the fracture had united and there was 60%–79% of normal forearm rotation, and poor when there was a nonunion or <60% of normal forearm rotation.

Patient-reported outcomes were assessed using the Disabilities of the Arm, Shoulder, and Hand (DASH) questionnaire scores.²³ A score of zero point indicates a perfectly functioning upper extremity, whereas a score of 100 points indicates a complete impairment.

Results

Union was achieved in all patients [Figure 7]. The mean followup was 17 months (range 13–28 months). According to Grace-Eversmann criteria, 27 patients (87.5%) had excellent or good results [Table 3]. The mean DASH score was 14 (range 5–36).

Patients were applied splint immobilization for an average of 4.2 days (range 2–14 days) as they could tolerate the pain. Four patients (12.5%) had nerve injuries at the time of presentation [Table 4]. One patient had complete recovery of motor function 1 year after a neurolysis was performed, but one had paresthesia in the ulnar nerve distribution. The remaining nerve injuries had complete recovery after 6 months.

After bone union, implant removal was performed in 4 (12.5%) patients with an average of 19 months (range 13–26 months).

Complications

The overall complication rate was 12.5% [Table 4]. Superficial infection was encountered in two patients (6.3%). These patients were recovered with local wound care and antibiotic treatment. One patient (3.1%) had delayed union; however, fracture healed without any need for an additional surgical procedure. One patient (3.1%) who had a Grade IIIA open, comminuted proximal third radius fracture developed radioulnar synostosis. Although synostosis resection was performed, the patient had a poor result with limited pronation and supination. No patient had deep infection, implant failure, or iatrogenic neurological and vascular damage.

Discussion

The treatment of diaphyseal forearm fractures using open reduction and plate fixation is generally accepted as the

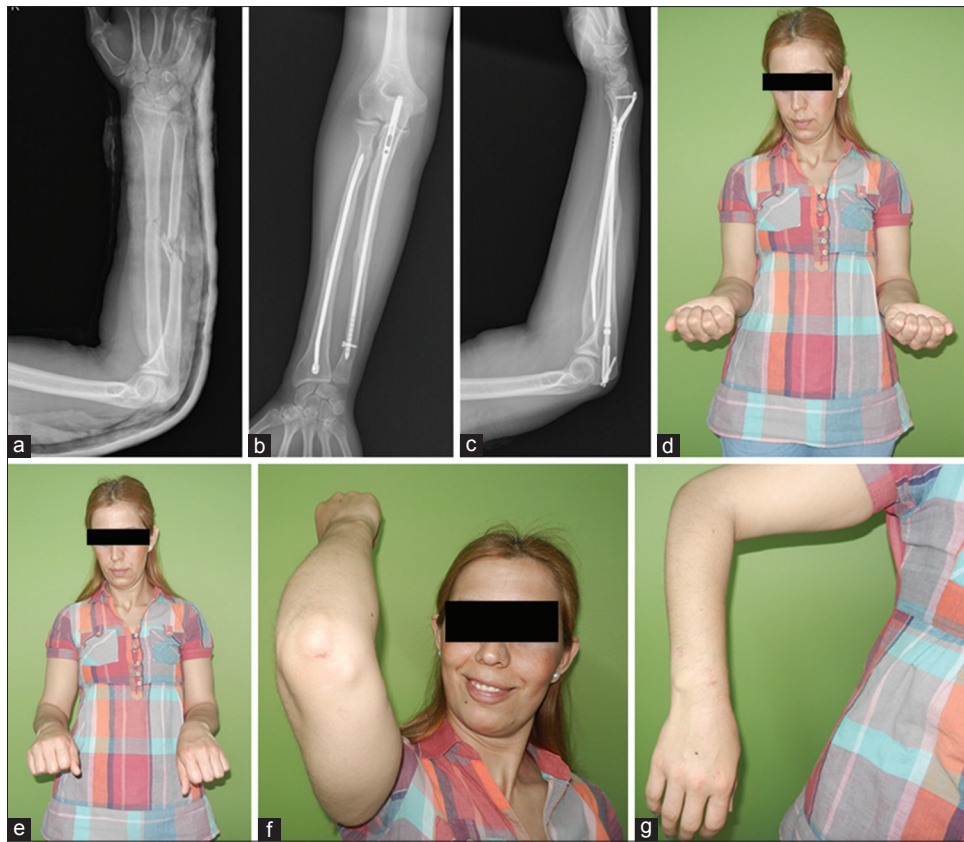


Figure 7: A 38-year-old female with a diaphyseal forearm fracture. (a) Preoperative radiographs of the forearm showing diaphyseal forearm fracture (b and c) At 11 months postoperatively x-ray of forearm bones anteroposterior and lateral views showing healing and alignment as satisfactory (d and e) Clinical photographs showing functional outcome (f and g) Clinical photographs showing minimal skin incisions

Table 3: Functional outcomes of the patients

Grace-Eversmann criteria	n (%)
Excellent	21 (65.6)
Good	7 (21.9)
Acceptable	3 (9.4)
Poor	1 (3.1)

Table 4: The perioperative data and complications

Parameters	Value
Mean timing of surgery (day)	3 (1-18)
Mean fluoroscopy time (min)	1.6 (1-4)
Mean operating time (min)	52 (30-65)
Mean blood loss (ml)	20 (0-90)
Fracture reduction, n (%)	
Closed	22 (69)
Mini open	10 (31)
Complications, n (%)	
Superficial infection	2 (6.3)
Radioulnar synostosis	1 (3.1)
Delayed union	1 (3.1)
Total	4 (12.5)

best choice in many studies.^{1,2,6,7} However, delayed union and nonunion which were attributed to open reduction and periosteal stripping may disrupt blood supply.³ Long skin

incisions, difficulty encountered due to cold fusion between plate and screw, and refracture after plate removal were the other concerns about plate fixation.⁶⁻⁹ At this point, closed reduction and IM nailing were considered to improve the results. However, early reports of IM nail fixation with K-wires, Steinmann pins, or rush rods resulted in high nonunion rates due to lack of rotational control.^{10,11} Street used square nail in 137 forearm fractures.¹² The main drawback of this nail was the distraction of the fracture with an increased risk of nonunion (7%) and the need for cast immobilization.

Crenshaw introduced ForeSight nail system (Smith and Nephew, Memphis, Tennessee, USA).¹³ This nail was used in adult forearm fractures and good results were reported.¹⁴⁻¹⁶ However, this nail requires an intraoperative bending procedure to create the anatomic bow of the radius and the serpentine shape of the ulna in each case.^{15,16} Therefore, additional time is needed for this procedure. In addition, insertion of interlocking screw through the distal part of the ulna, which has a relatively small diameter, was difficult, time-consuming, and increased intraoperative fluoroscopy exposure. Moreover, proximal interlocking of radial nail requires an additional incision which can cause a posterior interosseous nerve injury.^{15,16}

Lee *et al.* used prebent nail (Acumed, Hillsboro, Oregon, USA) to facilitate insertion in forearm fractures.¹⁷ The

targeted interlocking screw was inserted on only one end of the nail. The other nail end was fluted and had a paddle-blade tip, which was driven into the metaphyseal portion to provide rotational stability. However, they reported one nonunion (3.7%) which was attributed to the instability of distal ulna. When critically analyzing this nail, the main disadvantage was not using the locking screw at both ends of the ulnar nail. Therefore, this nailing system may not be suitable for patients with osteoporosis or comminuted fractures.

In this study, we used the recently developed anatomic forearm nail which has the ability to provide sufficient bending, axial and rotational stability. The radial nail that is precontoured to the shape of the bone is fluted at the proximal end to enhance rotational fracture control. This nail system has several advantages compared with the previous nails.^{12,13,17} First, distal interlocking of radial nail with locked screw provides additional stability, also it does not require a guide or fluoroscopy. Second, 15° angled blade in the proximal aspect of the radial nail and parabolic body provides a 3-point fixation. In addition, the design of the radial nail restores radial bowing that is consistent with the normal forearm architecture. Third, ulnar nail design has a distal oblique locking system feature which eliminates the need for fluoroscopy. Fourth, transverse, lateromedial, and posteroanterior dynamic interlocking can be made through the oval hole, which allows up to 7 mm compression at the fracture site. Fifth, ulnar nail allows static interlocking by proximal round hole. Finally, using the proximal oblique hole, single-cortex interlocking can be performed in any direction (360°) with an angle of 20° from the proximal part of nail.

Saka *et al.*¹⁸ performed the biomechanical analyses using IM radius and ulnar nails of the same length and diameter placed in synthetic bones (Saw-bones Europe AB, Malmo, Sweden-4th Generation Composite). They created the diaphysis of the sawbones, and then axial pressure, bending, torsion, and fatigue tests were applied. The biomechanical analyses demonstrated 0.0280 Nm/° and 0.0539 Nm/° torsional stiffness and 0.4925 Nm and 1.0975 Nm maximum torsion moments for radial and ulnar nails, respectively. A comparative study may be conducted using the same biomechanical setting and saw bone generation to delineate biomechanical differences between this novel IM nail and previous IM nails.

The mean time to union in our study was 12.4 weeks. Our results are keeping with the literature.^{15,16,24} Good or excellent results with locked IM nails for the treatment of forearm fractures have been reported as 92% by Lee *et al.*,¹⁷ 72% by Gao *et al.*,¹⁵ 79% by Weckbach *et al.*,¹⁶ 88.6% by Visna *et al.*,¹⁴ 100% by Saka *et al.*,¹⁸ and 94% by Köse *et al.*²⁴ Our results are consistent with literature.

The risk of refracture after removal of the plate has been reported to change between 3% and 22%.^{1,6,8,9,25} After plate removal, the patients used long-arm splint for 2 weeks

and returned to sports after 2 months to reduce the risk of refracture. In the IM nail group, the implants were removed in four patients (12.5%). The patients returned to activities without any restriction. However, difficulties may be encountered during IM nail removal. Therefore, surgeons should prepare universal nail extraction devices before surgery.

In our study, one patient who had a Grade IIIA open comminuted fracture developed synostosis. Pathogenesis for the development of synostosis after forearm fractures is not yet fully understood. Reasons could be primary damage to soft tissues, type of surgical approaches, bone grafting, or severe head and brain trauma.¹⁶ The frequency of synostosis was reported as 0%–8% after plating^{26,27} and of 0%–6.2% after nailing.^{16,26} Although we had achieved closed reduction in that patient, the degree of soft-tissue damage during injury might be the cause of synostosis.

Surgeons should be aware of the problems that might be encountered during the IM forearm nailing. If selected IM nail diameter is smaller than the required size, the nail may bend or it may cause rotational instability. If the IM nail is bigger than the actual canal size, it may cause iatrogenic fracture.¹⁵ The posterior interosseous branch of the radial nerve is at risk when proximal locking of radial nail is performed.^{15,17,28} The extensor pollicis longus tendon rupture and superficial branch of the radial nerve injuries have been reported in previous studies.^{25,29,30} In the present study, locking screw was not used for proximal stability. With specific design of the current IM radial nail that provide excellent 3-point fixation stability, no additional incision was required for proximal locking. Therefore, no posterior interosseous nerve injury was observed. Moreover, no other iatrogenic vascular, neurological, tendon, or bone injury was observed. We believe that meticulous surgical technique and appropriate selection of nail length and diameter using the preoperative radiographs of the unaffected side considering the narrowest medullary region would minimize the complications.

This study has several limitations. First, it is a retrospective study. Second, it comprises a relatively small number of patients. Third, we could not make a comparison between subgroups of the diaphyseal forearm fractures, for example, osteoporotic or comminuted fractures. Future studies consisting of homogeneous subgroup types can reveal more accurate results.

Conclusion

This design of IM interlocking forearm nails provides satisfactory functional and radiological outcomes in the treatment of adult diaphyseal forearm fractures. We recommend the use of IM nails as a reliable alternative to the plate fixation, which allows closed reduction, requires no periosteal stripping, uses cosmetically acceptable smaller incision, and allows early free movement.

Declaration of patient consent

The authors certify that they have obtained all appropriate patient consent forms. In the form the patient(s) has/have given his/her/their consent for his/her/their images and other clinical information to be reported in the journal. The patients understand that their names and initials will not be published and due efforts will be made to conceal their identity, but anonymity cannot be guaranteed.

Financial support and sponsorship

Nil.

Conflicts of interest

There are no conflicts of interest.

References

- Anderson LD, Sisk D, Tooms RE, Park WI 3rd. Compression-plate fixation in acute diaphyseal fractures of the radius and ulna. *J Bone Joint Surg Am* 1975;57:287-97.
- Chapman MW, Gordon JE, Zissimos AG. Compression-plate fixation of acute fractures of the diaphyses of the radius and ulna. *J Bone Joint Surg Am* 1989;71:159-69.
- Perren SM, Cordey J, Rahn BA, Gautier E, Schneider E. Early temporary porosis of bone induced by internal fixation implants. A reaction to necrosis, not to stress protection? *Clin Orthop Relat Res* 1988;232:139-51.
- Perren SM, Klaue K, Pohler O, Predieri M, Steinemann S, Gautier E. The limited contact dynamic compression plate (LC-DCP). *Arch Orthop Trauma Surg* 1990;109:304-10.
- Frigg R. Locking Compression Plate (LCP). An osteosynthesis plate based on the Dynamic Compression Plate and the Point Contact Fixator (PC-Fix). *Injury* 2001;32 Suppl 2:63-6.
- Saikia K, Bhuyan S, Bhattacharya T, Borgohain M, Jitesh P, Ahmed F. Internal fixation of fractures of both bones forearm: Comparison of locked compression and limited contact dynamic compression plate. *Indian J Orthop* 2011;45:417-21.
- Azboy I, Demirtas A, Uçar BY, Bulut M, Alemdar C, Ozkul E. Effectiveness of locking versus dynamic compression plates for diaphyseal forearm fractures. *Orthopedics* 2013;36:e917-22.
- Leung F, Chow SP. Locking compression plate in the treatment of forearm fractures: A prospective study. *J Orthop Surg (Hong Kong)* 2006;14:291-4.
- Henle P, Ortlieb K, Kuminack K, Mueller CA, Suedkamp NP. Problems of bridging plate fixation for the treatment of forearm shaft fractures with the locking compression plate. *Arch Orthop Trauma Surg* 2011;131:85-9.
- Knight RA, Purvis GD. Fractures of both bones of the forearm in adults. *J Bone Joint Surg Am* 1949;31A:755-64.
- Sage FP. Medullary fixation of fractures of the forearm. A study of the medullary canal of the radius and a report of fifty fractures of the radius treated with a prebent triangular nail. *J Bone Joint Surg Am* 1959;41-A: 1489-516.
- Street DM. Intramedullary forearm nailing. *Clin Orthop Relat Res* 1986;212:219-30.
- Crenshaw AH Jr. Fractures of shoulder girdle, arm, and forearm. In: Canale ST, Beaty JH, editors. *Campbell's Operative Orthopaedics*. 11th ed. St. Louis: Mosby; 2008. p. 3431-41.
- Visna P, Beitl E, Pilný J, Cizmár I, Vlcek M, Kalvach J, *et al.* Interlocking nailing of forearm fractures. *Acta Chir Belg* 2008;108:333-8.
- Gao H, Luo CF, Zhang CQ, Shi HP, Fan CY, Zen BF. Internal fixation of diaphyseal fractures of the forearm by interlocking intramedullary nail: Short-term results in eighteen patients. *J Orthop Trauma* 2005;19:384-91.
- Weckbach A, Blattert TR, Weisser CH. Interlocking nailing of forearm fractures. *Arch Orthop Trauma Surg* 2006;126:309-15.
- Lee YH, Lee SK, Chung MS, Baek GH, Gong HS, Kim KH. Interlocking contoured intramedullary nail fixation for selected diaphyseal fractures of the forearm in adults. *J Bone Joint Surg Am* 2008;90:1891-8.
- Saka G, Saglam N, Kurtulmus T, Avci CC, Akpınar F, Kovaci H, *et al.* New interlocking intramedullary radius and ulna nails for treating forearm diaphyseal fractures in adults: A retrospective study. *Injury* 2014;45 Suppl 1:S16-23.
- Fracture and dislocation compendium. Orthopaedic Trauma Association Committee for Coding and Classification. *J Orthop Trauma* 1996;10 Suppl 1:v-ix, 1-154.
- Gustilo RB, Anderson JT. Prevention of infection in the treatment of one thousand and twenty-five open fractures of long bones: Retrospective and prospective analyses. *J Bone Joint Surg Am* 1976;58:453-8.
- Saka G, Saglam N, Kurtulmus T, Bakir U, Avci CC, Akpınar F, *et al.* Treatment of isolated diaphyseal fractures of the radius with an intramedullary nail in adults. *Eur J Orthop Surg Traumatol* 2014;24:1085-93.
- Grace TG, Eversmann WW Jr. Forearm fractures: Treatment by rigid fixation with early motion. *J Bone Joint Surg Am* 1980;62:433-8.
- Hudak PL, Amadio PC, Bombardier C. Development of an upper extremity outcome measure: The DASH (disabilities of the arm, shoulder and hand) [corrected]. The Upper Extremity Collaborative Group (UECG) *Am J Ind Med* 1996;29:602-8.
- Köse A, Aydın A, Ezirmik N, Can CE, Topal M, Tipi T. Alternative treatment of forearm double fractures: New design intramedullary nail. *Arch Orthop Trauma Surg* 2014;134:1387-96.
- Lee SK, Kim KJ, Lee JW, Choy WS. Plate osteosynthesis versus intramedullary nailing for both forearm bones fractures. *Eur J Orthop Surg Traumatol* 2014;24:769-76.
- Ozkaya U, Kiliç A, Ozdoğan U, Beng K, Kabukçuoğlu Y. Comparison between locked intramedullary nailing and plate osteosynthesis in the management of adult forearm fractures. *Acta Orthop Traumatol Turc* 2009;43:14-20.
- Stern PJ, Drury WJ. Complications of plate fixation of forearm fractures. *Clin Orthop Relat Res.* 1983;175:25-9
- Behnke NM, Redjal HR, Nguyen VT, Zinar DM. Internal fixation of diaphyseal fractures of the forearm: A retrospective comparison of hybrid fixation versus dual plating. *J Orthop Trauma* 2012;26:611-6.
- Fanuele J, Blazar P. Extensor pollicis longus tendon rupture in an adult after intramedullary nailing of a radius fracture: Case report. *J Hand Surg Am* 2009;34:627-9.
- Parikh SN, Jain VV, Denning J, Tamai J, Mehlman CT, McCarthy JJ, *et al.* Complications of elastic stable intramedullary nailing in pediatric fracture management: AAOS exhibit selection. *J Bone Joint Surg Am* 2012;94:e184.