



CLASSIC AND MODIFIED BARR'S TECHNIQUE OF ANTERIOR TRANSFER OF THE TIBIALIS POSTERIOR TENDON IN IRREPARABLE PERONEAL PALSIES

SANELA SALIHAGIĆ^{1*}, ZORAN HADŽIAHMETOVIĆ², ABDULAH FAZLIĆ¹

¹ Clinic for Plastic and Reconstructive Surgery, University of Sarajevo Clinics Centre,
Bolnička 25, 71000 Sarajevo, Bosnia and Herzegovina

² Emergency Medicine Center, University of Sarajevo Clinics Centre,
Bolnička 25, 71000 Sarajevo, Bosnia and Herzegovina

* Corresponding author

ABSTRACT

Peroneal palsy with loss of active dorsal flexion in foot can be surgically treated by anterior transfer of tibialis posterior tendon. Two techniques are available, classic and modified Barr's technique of the anterior transfer of tibialis posterior tendon, with different place of tendon's reinsertion. The aim of the study is evaluation of the degree of active dorsal flexion in foot, and appearance of varus position and hipercorrection of the foot, by comparing the results of the two operative techniques. The study included 40 patients with peroneal irreparable palsies, divided into two equally sized groups. The first group was treated by classic Barr's technique. The other group of patients was treated by modified Barr's technique. The group treated by modified Barr's technique exhibited better functional results. Active dorsal flexion achieved between 95° (in 35% cases) and 90° (in 50% cases), while varus position and hipercorrection of the foot were absent. In the second group of 20 patients, treated by classic Barr's technique, 80° (40%) and 90° (25%) of active dorsal flexion, indicated worse functional postoperative results. Active dorsal flexion of 70° achieved by this method in two cases (10%), represents unsatisfactory functional result. Varus position of the foot was recorded in 5 cases (25%) and hipercorrection in 4 cases (20%). Modified Barr's technique is surgical method with better functional and postoperative results in treatment of irreparable peroneal palsy.

KEY WORDS: peroneal palsy, tendon transfer, active dorsal flexion

INTRODUCTION

Irreparable peroneal palsies, without possibility of functional recovery, can be treated by anterior transfer of tibialis posterior tendon. Absence of innervation in neuromuscular junction, with loss of function, may be an indication for tendon transfer (1). Functional recovery of injured nerve can be evaluated electromyographically, by interval tracking of Tinnel sign and by Hidget's method of evaluation of postoperative results in the sense of motor and sensory recovery (2). Electromyographic evaluation of reinnervation of neuromuscular junction is not a guarantee of functional recovery, because electromyography is rather functional than diagnostic test (3). The aim of anterior transfer of tibialis posterior tendon, in the case of irreparable peroneal palsy, is re-establishment of lost active dorsal flexion in foot (4). Anterior transfer of tibialis posterior tendon, which primary function is plantar flexion of the foot, with reinsertion on cuboid, or one of the cuneiform or metatarsal bones, is convenient type of tendon transfer in irreparable peroneal palsy (5). Indications for tibialis posterior anterior transfer (6):

1. Irreparable, central and peripheral, peroneal palsies
2. Pes equinovarus in children caused by poliomyelitis (peroneal musculature is seriously weakened or paralyzed, with intact tibialis posterior)
3. Dynamic varus deformity in spastic cerebral paralysis
4. Cavovarus deformity in Charcot-Marie-Tooth disease
5. Duchenne muscular dystrophy
6. Recurrence of forefoot deformity in club foot
7. Other conditions that weaken dorsiflexion of the foot (e.g. traumatic injuries)

Anterior transfer of tibialis posterior tendon serves two purposes (7):

1. Removal of tibialis posterior tendon as deforming force
2. Establishment or augmentation of active dorsal flexion in foot.

Two operative techniques are available (6,8):

1. Transfer of the tendon through interosseus membrane
2. Routing the tendon around the medial side of tibia and through anterior compartment of leg to the dorsum of foot

Anterior transfer of tibialis posterior tendon could be performed by four variations of operative technique (9):

1. **CLASSIC BARR'S TECHNIQUE** - reinsertion of tibialis posterior tendon on either second or third cuneiform bone, or at the base of either second or

third metatarsal bone, after desinsertion from the navicular bone, with passage of the tendon through the interosseus membrane of the leg

2. **MODIFIED BARR'S TECHNIQUE**- procedure identical to the classic Barr's technique, but with reinsertion on cuboid bone (The technique developed at the Clinic for Plastic and Reconstructive Surgery (University of Sarajevo Clinics Centre)
3. **OBER'S TECHNIQUE OF TIBIALIS POSTERIOR TRANSFER**- routing of tibialis posterior tendon around the medial side of tibia and through anterior compartment of the leg, with reinsertion at the basis of the third metatarsal bone
4. **HATT'S MODIFICATION OF OBER'S TECHNIQUE** - reinsertion of tibialis posterior tendon on the medial cuneiform bone

Anterior transfer of tibialis posterior tendon removes dynamic deformity of the foot, while establishing active dorsal flexion (10). The aim of the study is to compare success of classic and modified Barr's techniques by evaluating the degree of active dorsal flexion after anterior transfer of tibialis posterior tendon and by observing unfavorable postoperative results in the form of varus position and hypercorrection of the foot.

MATERIAL AND METHODS

The study included 40 patients with irreparable peroneal palsies. The first group of 20 patients was treated by classic Barr's technique while the modified technique was applied in the other group of 20 patients. Criteria for inclusion in the study:

- Patients of different sex
- Clinically and diagnostically verified lesion of peroneal nerve
- Patients treated by classic and modified Barr's technique

Criteria for exclusion from the study:

- Untreated peroneal palsies
- Peroneal palsies treated by other operative techniques of tibialis posterior transposition

Denervation of neuromuscular junction was verified electromyographically before the surgery. All the deforming changes in ankle joints were also corrected. Functional and full range of motions of joints before tendon transfer are essential for all types of tendon transfers. Postoperative results were evaluated by:

- Clinical examination
- Degree of active dorsal flexion of the foot
- Presence of varus position and hypercorrection of the foot

RESULTS AND DISCUSSION

We have evaluated the results of operative treatment of 40 patients with irreparable peroneal palsies, loss of active dorsal flexion in foot and functional range of motion in the ankle joint. The patients were divided in two identically sized groups. The first group was treated by classic Barr's technique and the second group was treated by modified Barr's technique.

The degree of active dorsal flexion, achieved by classic and modified Barr's techniques is represented in Table 1. Comparison of these two techniques according to the achieved active dorsal flexion of the foot, is given in Table 2 and Figure 1. Varus position and hipercorrection of the foot, as unfavorable post-

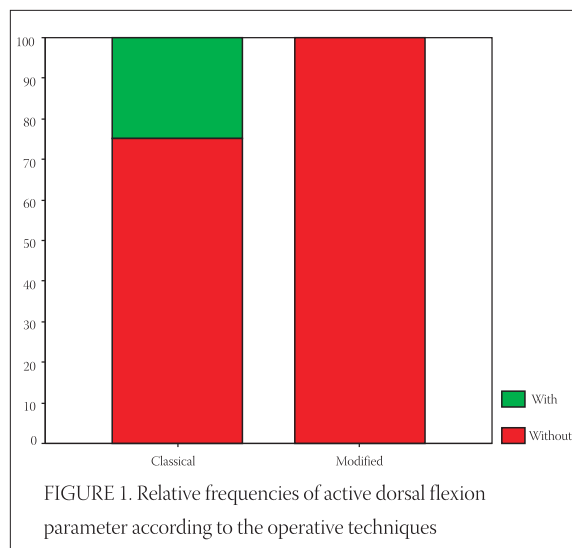
operative results, were observed only in the group of patients treated by classic Barr's technique, as illustrated in Tables 3 and 4 and Figures 2 and 3. Better functional results, with higher degree of active dorsal flexion of the foot - 950 (35%) and 900 (50%), were found in the group of patients treated by modified Barr's technique. Also, varus position and hipercorrection were completely absent. In the group of patients treated by classic Barr's technique, functional postoperative results were less successful. Active dorsal flexion of 950 was not achieved. The highest degree of the achieved active dorsal flexion was 900 (25%) while 850 was achieved in certain cases (25%). Active dorsal flexion of 700 was evaluated in 10% patients and is considered bad functional result. Varus position was found in 5 cases (25%) and hipercorrection in 4 cases (20%).

| OPERATIVE TECHNIQUE | N | Minimum | Maximum | Average | Median | Std. De v. |
|----------------------------------|----|---------|---------|---------|--------|------------|
| <i>Classic Barr's technique</i> | 20 | 70 | 90 | 82,75 | 82,50 | 5,95 |
| <i>Modified Barr's technique</i> | 20 | 85 | 95 | 91,00 | 90,00 | 3,48 |
| Total | 40 | 70 | 95 | 86,88 | 90,00 | 6,37 |

TABLE 1. Parameter of active dorsal flexion evaluated by maximal, minimal, median and standard deviation

| | | Active dorsal flexion (DF) | | | | | |
|----------------------------------|--------------------|----------------------------|-------|-------|-------|-------|--------|
| | | 70 | 80 | 85 | 90 | 95 | Total |
| <i>Classic Barr's Technique</i> | Absolute frequency | 2 | 8 | 5 | 5 | | 20 |
| | Relative frequency | 10,0% | 40,0% | 25,0% | 25,0% | | 100,0% |
| <i>Modified Barr's Technique</i> | Absolute frequency | | | 3 | 10 | 7 | 20 |
| | Relative frequency | | | 15,0% | 50,0% | 35,0% | 100,0% |
| Total | Absolute frequency | 2 | 8 | 8 | 15 | 7 | 40 |
| | Relative frequency | 5,0% | 20,0% | 20,0% | 37,5% | 17,5% | 100,0% |

TABLE 2. Absolute and relative frequencies of the treated patients according to the parameter of active dorsal flexion



| | | Varus position of the foot (VP) | | |
|----------------------------------|--------------------|---------------------------------|---------|--------|
| | | Absent | Present | Total |
| <i>Classic Barr's technique</i> | Absolute frequency | 15 | 5 | 20 |
| | Relative frequency | 75,0% | 25,0% | 100,0% |
| <i>Modified Barr's Technique</i> | Absolute frequency | 20 | | 20 |
| | Relative frequency | 100,0% | | 100,0% |
| Total | Absolute frequency | 35 | 5 | 40 |
| | Relative frequency | 87,5% | 12,5% | 100,0% |

TABLE 3. Absolute and relative frequencies of treated patients according to the varus position parameter

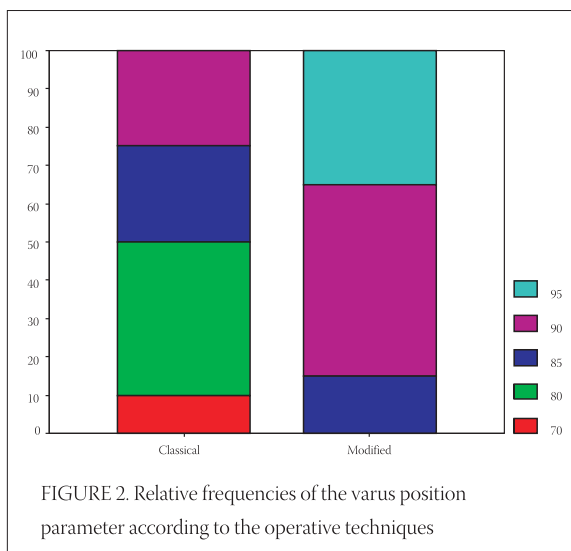


FIGURE 2. Relative frequencies of the varus position parameter according to the operative techniques

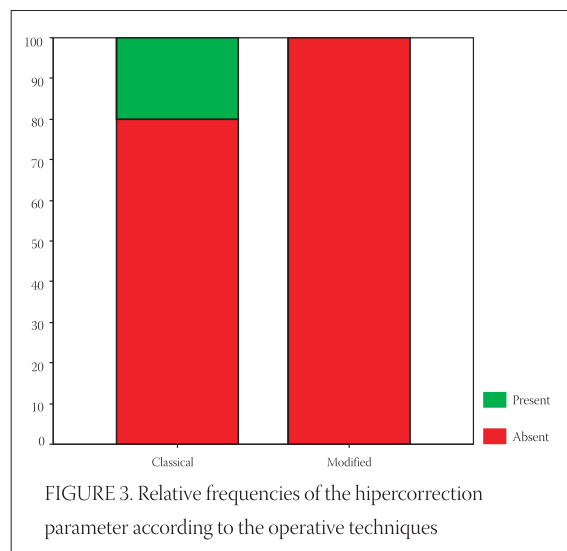


FIGURE 3. Relative frequencies of the hypercorrection parameter according to the operative techniques

| | | Hypercorrection of the foot (HS) | | |
|----------------------------------|--------------------|----------------------------------|---------|--------|
| | | Absent | Present | Total |
| <i>Classic Barr's technique</i> | Absolute frequency | 16 | 4 | 20 |
| | Relative frequency | 80,0% | 20,0% | 100,0% |
| <i>Modified Barr's Technique</i> | Absolute frequency | 20 | 0 | 20 |
| | Relative frequency | 100,0% | 0,0% | 100,0% |
| Total | Absolute frequency | 36 | 4 | 40 |
| | Relative frequency | 90,0% | 10,0% | 100,0% |

TABLE 4. Absolute and relative frequencies of treated patients according to hypercorrection parameter

CONCLUSION

Anterior transfer of tibialis posterior tendon in the cases of irreparable peroneal palsy removes dynamic deformity of the foot. Redirection of tendon in relation to medial malleolus diminishes the force of plantar flexion of the foot.

Comparing the two methods of Barr's technique of tibialis posterior transfer, statistical significance was found in differences in postoperative degree of active dorsal flexion of the foot and in frequencies of varus position and hypercorrection. We found correlation between operative technique and postoperative results. Better functional results were obtained by modified Barr's technique, with complete absence of varus position and hypercorrection of the foot, and higher degree of active dorsal flexion. It implicates faster functional postoperative recovery and better walking stability. Tibialis posterior tendon has adequate length for reinsertion on cuboid bone, without angulation. According to our clinical experience, modified Barr's technique is the method of choice in the treatment of irreparable peroneal palsies.

REFERENCES

- (1) Mc.Carthy J. G., Plastic Surgery, Vol 8, The Hand, Part 2, W.B. Saunders Company, 1998.
- (2) Samardžić M., Antunović V., Grujičić D. Povrede i oboljenja perifernih nerava: Školska knjiga Zagreb, 1990
- (3) Omer G.E., Jr. The technique and Timing of Tendon Transfers, Assessment of Peripheral nerve injuries, Vol 3, CU Mosby, St. Louis, 1999.
- (4) Beasley R. W. Principles of Tendon Transfers in Campbell, Times Mirror Company. Edition: Robert Hurley, 2000
- (5) Kling T. F., Kaufer H., Hesinger R. N. Split posterior tibialis transfer in children with cerebral spastic paralysis and equinovarus deformity, J. Bone Joint Surgery, Vol2 1998;67A:186
- (6) Morrissey R.T. Atlas of Pediatric Orthopaedics Surgery, J. B. Lippincott Company, Philadelphia, 2003
- (7) Coleman S. S.: Complex foot deformities in children, Philadelphia, Lea/Febiger, 1998
- (8) Johnson W. L., Lester E. L. Transposition of Posterior Tibial Tendon, Raven Press, Ltd. 2003.
- (9) Lambrinudi C. The New operation of drop foot, Bone Joint Surgery, 1998
- (10) Hoffer M. M., Lehmann M., Mitanni M.: Long term follow-up on tendon transfers in patients with cerebral palsy, J. Hand Surgery, 1999, Vol 3., 67B:432