



A Case of Schnitzler's Syndrome without Monoclonal Gammopathy-Associated Chronic Urticaria Treated with Anakinra

Min Joo Ahn, Ji Eun Yu, Jiung Jeong, Da Woon Sim, and Young-Il Koh

Department of Internal Medicine, Chonnam National University Medical School, Gwangju, Korea.

Chronic urticaria may often be associated with interleukin (IL)-1-mediated autoinflammatory disease, which should be suspected if systemic inflammation signs are present. Here, we report a case of Schnitzler's syndrome without monoclonal gammopathy treated successfully with the IL-1 receptor antagonist anakinra. A 69-year-old man suffered from a pruritic urticarial rash for 12 years. It became aggravated episodically and was accompanied by high fever, arthralgia, leukocytosis, and an elevated C-reactive protein and erythrocyte sedimentation rate. The episodes each lasted for over one week. Neutrophilic and eosinophilic inflammation was found on skin biopsy. However, serum and urine electrophoresis showed no evidence of monoclonal gammopathy. The cutaneous lesions were unresponsive to various kinds of anti-histamines, systemic glucocorticoids, colchicine, cyclosporine, dapson, and methotrexate, which were administered over a span of 3 years immediately preceding successful treatment. A dramatic response, however, was observed after a daily administration of anakinra. This observation suggests that the correct diagnosis of this case is Schnitzler's syndrome without monoclonal gammopathy. For an adult patient with refractory chronic urticaria and systemic inflammation, Schnitzler's syndrome could be considered as a possible differential diagnosis. Although the typical form of Schnitzler's syndrome exhibits the presence of monoclonal gammopathy as a diagnostic criterion, monoclonal gammopathy may be absent in an atypical form. In such a situation, an IL-1 antagonist should be effective for the management of chronic urticaria.

Key Words: Interleukin 1 receptor antagonist protein, Schnitzler's syndrome, urticaria

INTRODUCTION

Chronic urticaria may be associated with underlying diseases, such as urticarial vasculitis and autoinflammatory disease.¹ The condition should be suspected if signs of systemic inflammation are present.² Autoinflammatory disease is characterized by various systemic inflammatory symptoms and cuta-

neous urticarial rashes.

Schnitzler's syndrome is an autoinflammatory disease that appears in patients over 40 years of age. The syndrome is described as having chronic urticaria, monoclonal gammopathy (major criteria), and at least two of the following symptoms: fever, leukocytosis and/or elevated C-reactive protein (CRP), abnormal bone remodeling, or neutrophilic infiltration (minor criteria). Additionally, other findings, such as arthralgia, lymphadenopathy and hepatomegaly, and/or splenomegaly, may be present.³ It does not respond well to antihistamines, corticosteroids, or immunomodulators. However, as it is interleukin (IL) 1-mediated, the IL-1 antagonist anakinra is known to be very effective.³ Interestingly, a few cases of Schnitzler's syndrome without monoclonal gammopathy have been reported.⁴⁻⁶

Here, we report a case of Schnitzler's syndrome without monoclonal gammopathy treated successfully with anakinra. To the best of our knowledge, the case is the first in an Asian population.

Received: February 13, 2017 **Revised:** April 13, 2017

Accepted: May 11, 2017

Corresponding author: Dr. Young-Il Koh, Department of Internal Medicine, Chonnam National University Medical School, 42 Jebong-ro, Dong-gu, Gwangju 61469, Korea.

Tel: 82-62-220-6580, Fax: 82-62-225-8578, E-mail: yikoh@chonnam.ac.kr

•The authors have no financial conflicts of interest.

© Copyright: Yonsei University College of Medicine 2018

This is an Open Access article distributed under the terms of the Creative Commons Attribution Non-Commercial License (<http://creativecommons.org/licenses/by-nc/4.0>) which permits unrestricted non-commercial use, distribution, and reproduction in any medium, provided the original work is properly cited.

CASE REPORT

A 69-year-old man was admitted to our department in July 2015 due to fever, urticarial rash, and arthralgia. He had suffered from urticarial rash since 2003 but visited our department in August 2012 for the first time. The urticarial rash appeared over the entire body, including the trunk and both upper and lower extremities. It had aggravated episodically without noticeable factors. It was not painful but was accompanied by severe pruritus. It was accompanied by fever of up to 39°C that persisted throughout the day, arthralgia, myalgia, leukocytosis, and elevated CRP and erythrocyte sedimentation rate (ESR). The episodes have lasted over 1 week. The urticarial symptoms were not found in his family.

Laboratory findings were as follows: leukocytes 10600/μL (reference range, 4800–10800/μL), hemoglobin 9.4 g/dL (12–18 g/dL), platelets 258000/μL (130000–450000/μL), ESR 63 mm/hr (0–20 mm/hr), CRP 13.6 mg/dL (0–0.3 mg/dL), ferritin 360.77 ng/mL (4.63–274.66 ng/mL), complement (C) 3 158 mg/dL (90–180 mg/dL), C4 48.7 mg/dL (10–40 mg/dL), immunoglobulin (Ig) G 611 mg/dL (700–1600 mg/dL), IgA 124 mg/dL (70–400 mg/dL), IgM 154 mg/dL (40–230 mg/dL), and IgE 18.7 IU/mL (0–100 IU/mL). Liver and renal functions were in normal ranges. Blood and urine cultures were negative. Anti-nuclear antibody, anti-neutrophil cytoplasmic antibody, rheumatoid factor, and cryoglobulin were also negative. Serum and urine immunoelectrophoresis showed no evidence of monoclonal gammopathy.

He had undergone a thorough examination in our hospital before this presentation. Skin histology revealed neutrophilic and eosinophilic inflammation without evidence of vasculitis. Computed tomography showed subpleural nodular consolidation in the lower left lung and bilateral pleural effusion. Positron emission tomography additionally revealed splenomegaly, lymphadenopathy, and bone marrow hypermetabolism. A transthoracic needle biopsy for the subpleural nodule showed chronic granulomatous inflammation with organization. At that time, the possibility of adult-onset tumor necrosis factor (TNF) receptor-associated periodic syndrome (TRAPS), an autoinflammatory disease, was considered based on his manifestations. However, a tumor necrosis factor receptor superfamily 1A (*TNFRSF1A*) gene mutation was not detected. Additionally, TNF-α antagonist, etanercept (Embre^l, Immunex Corporation, Seattle, WA, USA) 50 mg, which is known to be effective for TRAPS,⁷ was subcutaneously administered once, and he did not respond.

Over three years before successful treatment, he was unresponsive to various combinations of anti-histamines and various doses of systemic glucocorticoids, colchicine, cyclosporine, dapsone, and methotrexate. The observation that he had signs of systemic inflammation and did not respond to any conventional medications indicated the possibility of another autoinflammatory disease, such as Schnitzler's syndrome.

However, Schnitzler's syndrome could not be diagnosed, because of the absence of monoclonal gammopathy. Despite the lack of diagnostic criteria for the typical TRAPS and Schnitzler's syndrome, we still did not exclude the possibility of autoinflammatory disease. Recent European guidelines suggest a diagnosis of IL-1-mediated autoinflammatory disease in such a situation.² Therefore, an IL-1 receptor antagonist, anakinra (Kineret[®], Swedish Orphan Biovitrum, Stockholm, Sweden) 100 mg, was subcutaneously injected on a daily basis. Fever, arthralgia, and urticaria were resolved within 24 hours of the first injection. The patient was very satisfied with the anakinra injections. Thus, antihistamines were tapered off in a few days, and systemic steroids were gradually tapered. Inflammatory markers, such as CRP and ESR, were normalized for the first time after ten days (Fig. 1). Transient increases in leukocytes, CRP, and ESR were observed shortly after anakinra injection, which may be associated with slight aggravation of Schnitzler's syndrome by the reduction of steroid doses. However, as the anakinra treatment was continued, the inflammatory markers returned to normal ranges although the steroids were further tapered. Prednisolone was tapered to a dose of 5 mg/day after one month. The treatment with anakinra was well tolerated, except for a mild reaction at the injection site.

Unfortunately, due to economic problems, anakinra was discontinued after 56 days of treatment. Two days later, his symptoms recurred. The systemic steroids were again increased. Three months after discontinuation of anakinra, he died due to pneumonia.

DISCUSSION

When the present case is considered retrospectively, the patient should have been diagnosed with Schnitzler's syndrome without monoclonal gammopathy. Clinical and laboratory findings were all compatible with Schnitzler's syndrome, except monoclonal gammopathy. He had recurrent episodes of urticarial rash, fever, and arthralgia. Whenever he presented these symptoms, leukocytosis and CRP elevation were noted. Lymphadenopathy and splenomegaly were also found. Neutrophilic inflammation in cutaneous lesions was observed.

The finding that all the clinical manifestations dramatically disappeared following the administration of an IL-1 antagonist strongly suggests that our patient had an IL-1-mediated autoinflammatory disease, such as Schnitzler's syndrome.^{8,9} The patient did not respond well to conventional medications, such as antihistamines, systemic steroids, colchicine, cyclosporine, dapsone, and methotrexate. Other IL-1-mediated autoinflammatory diseases, including adult-onset TRAPS and adult-onset Still's disease (AOSD), can be included in the differential diagnosis. The known mutation of the *TNFRSF1A* gene was not found in the present case, suggesting little possibility of TRAPS. However, a new mutation in the *TNFRSF1A*

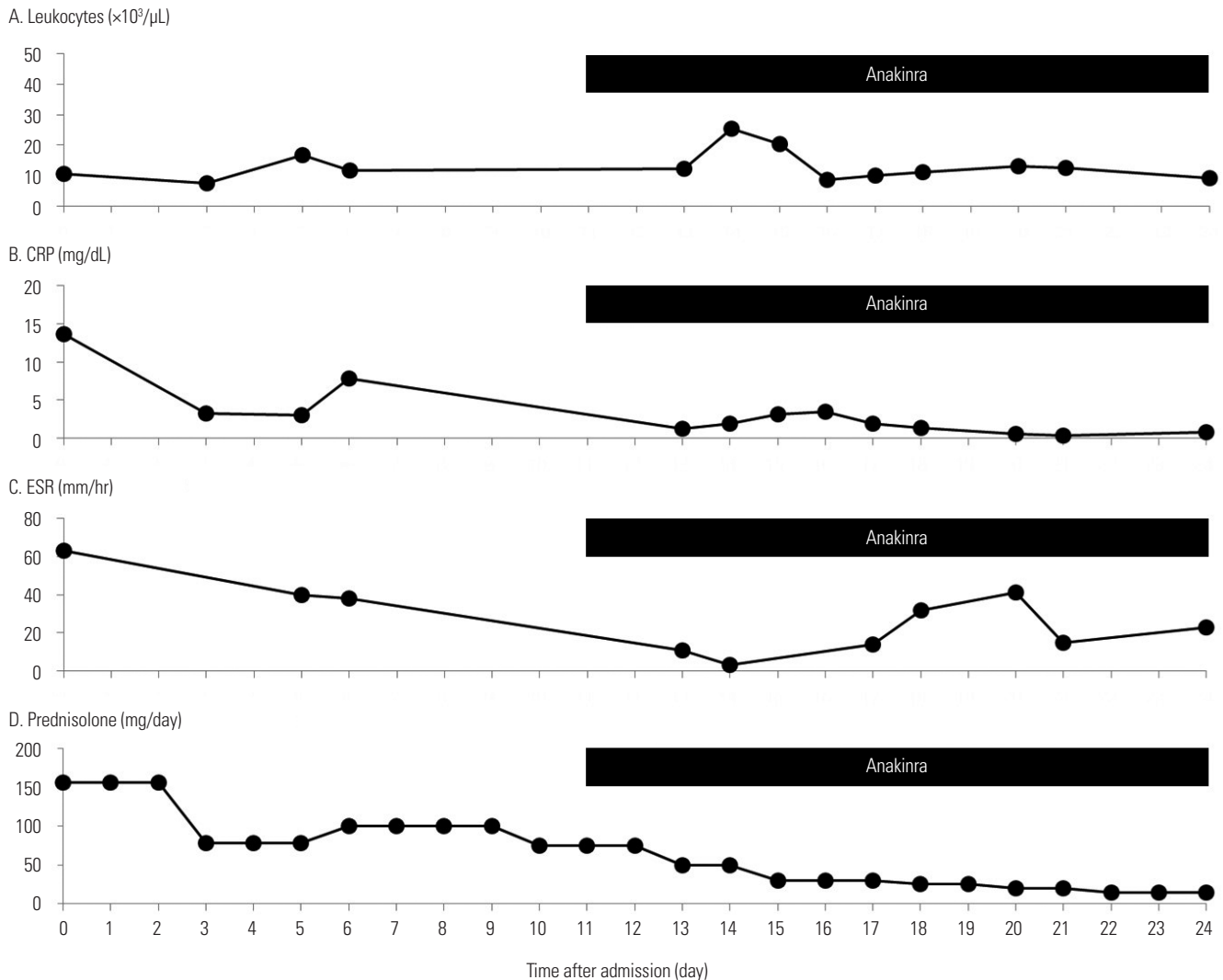


Fig. 1. Changes in blood leukocytes (A), CRP (B), ESR (C), and the doses of systemic steroids (D) after anakinra treatments. Anakinra was subcutaneously injected daily from day 11 after admission. The amounts of systemic steroids are presented as equivalent doses of prednisolone. CRP, C-reactive protein; ESR, erythrocyte sedimentation rate.

gene has been reported in adult-onset TRAPS.¹⁰ AOSD was excluded due to the absence of daily spiking fever and less markedly elevated ferritin.¹¹ Urticarial vasculitis was excluded on the basis of a skin biopsy.

It is not known why monoclonal gammopathy is often absent in Schnitzler's syndrome. A few cases have shown that monoclonal gammopathy is not detected in earlier stages but appears at later follow-up time points, indicating that monoclonal gammopathy may occur as the disease progresses. However, it has been reported that monoclonal gammopathy can also be absent during the entire observation period.⁴⁻⁶

KoreaMed searches showed no cases of Schnitzler's syndrome. Other autoinflammatory diseases have only rarely been reported in Korea. Only a few cases of familial Mediterranean fever were found in KoreaMed.¹²

High doses of anakinra might increase the risk of infection.¹³ However, in the present case, pneumonia occurred 3 months

after discontinuation of anakinra, which may suggest that the pneumonia was not related to anakinra injection. We speculate that the pneumonia may be associated with long-term use of systemic steroids.

IL-1-mediated autoinflammatory disease should be considered in patients with chronic urticaria, particularly if systemic inflammation signs are present and a response to conventional medications is absent. For adult patients, Schnitzler's syndrome could be one of the likely diagnoses. Although the typical form of Schnitzler's syndrome has the presence of monoclonal gammopathy as a diagnostic criterion, monoclonal gammopathy may be absent in an atypical form. In such a situation, an IL-1 antagonist can be very effective.

ORCID

Min Joo Ahn <https://orcid.org/0000-0002-2778-0735>
 Young-Il Koh <https://orcid.org/0000-0002-5100-9473>

REFERENCES

1. Brodell LA, Beck LA. Differential diagnosis of chronic urticaria. *Ann Allergy Asthma Immunol* 2008;100:181-8.
2. Zuberbier T, Aberer W, Asero R, Bindslev-Jensen C, Brzoza Z, Canonica GW, et al. The EAACI/GA(2) LEN/EDF/WAO Guideline for the definition, classification, diagnosis, and management of urticaria: the 2013 revision and update. *Allergy* 2014;69:868-87.
3. Simon A, Asli B, Braun-Falco M, De Koning H, Ferman J, Gratton C, et al. Schnitzler's syndrome: diagnosis, treatment, and follow-up. *Allergy* 2013;68:562-8.
4. Varella TC, Nishimura MY, Machado MC, de Moraes-Vasconcelos D, Rivitti EA. Schnitzler's syndrome without monoclonal gammopathy. *Acta Derm Venereol* 2005;85:272-3.
5. Urbanski M, Holfeld K, Milne A, Abbas M. Schnitzler syndrome without a monoclonal gammopathy: a case report. *J Cutan Med Surg* 2016;20:575-8.
6. Husak R, Nestoris S, Goerdt S, Orfanos CE. Severe course of chronic urticaria, arthralgia, fever and elevation of erythrocyte sedimentation rate: Schnitzler's syndrome without monoclonal gammopathy? *Br J Dermatol* 2000;142:581-2.
7. Bulua AC, Mogul DB, Aksentijevich I, Singh H, He DY, Muenz LR, et al. Efficacy of etanercept in the tumor necrosis factor receptor-associated periodic syndrome: a prospective, open-label, dose-escalation study. *Arthritis Rheum* 2012;64:908-13.
8. Besada E, Nossent H. Dramatic response to IL1-RA treatment in longstanding multidrug resistant Schnitzler's syndrome: a case report and literature review. *Clin Rheumatol* 2010;29:567-71.
9. Krause K, Tsianakas A, Wagner N, Fischer J, Weller K, Metz M, et al. Efficacy and safety of canakinumab in Schnitzler syndrome: a multicenter randomized placebo-controlled study. *J Allergy Clin Immunol* 2017;139:1311-20.
10. Greco E, Aita A, Galozzi P, Gava A, Sfriso P, Negm OH, et al. The novel S59P mutation in the TNFRSF1A gene identified in an adult onset TNF receptor associated periodic syndrome (TRAPS) constitutively activates NF- κ B pathway. *Arthritis Res Ther* 2015;17:93.
11. Gerfaud-Valentin M, Jamilloux Y, Iwaz J, Séve P. Adult-onset Still's disease. *Autoimmun Rev* 2014;13:708-22.
12. Kim KT, Jang HJ, Lee JE, Kim MK, Yoo JJ, Lee GY, et al. Familial mediterranean fever with complete symptomatic remission during pregnancy. *Intest Res* 2015;13:287-90.
13. Salliot C, Dougados M, Gossec L. Risk of serious infections during rituximab, abatacept and anakinra treatments for rheumatoid arthritis: meta-analyses of randomised placebo-controlled trials. *Ann Rheum Dis* 2009;68:25-32.