

Effect of multiple intra-articular injections of polynucleotides on treatment of intractable knee osteoarthritis

A case report

Jong-Uk Mun, MD^a, Hyung Rae Cho, MD^b, Young Soon Choi, MD, PhD^c, Young Uk Kim, MD^{c,*}

Abstract

Rationale: Knee osteoarthritis (KOA) is a chronic joint degenerative disease. Intra-articular injection (IAI) of hyaluronic acid (HA) is widely used to treat KOA. However, some HA injections have no effect at all. Polynucleotides (PN) are recently noted as a valid substitute for HA.

Patient concerns: A 61-year-old female was admitted to the pain center with symptoms of pain over the knee and warmth feeling with stiffness in the left knee. The patient reported chronic severe pain in the left knee area despite 6 times IAI of HA. She had past medical history of breast cancer and thyroid cancer.

Diagnoses: She was diagnosed as having KOA.

Interventions: Ultrasound-guided IAI of PN was carried out 3 times in 3 weeks.

Outcomes: She was followed-up for more than 5 months with good improvement in intractable knee pain without any adverse event.

Lessons: IAI of PN is an efficient therapeutic option for KOA treatment if HA injection is unsuccessful.

Abbreviations: IAI = intra-articular injection, KOA = knee osteoarthritis, NSAIDs = nonsteroidal anti-inflammatory drugs, PN = polynucleotides, VAS = visual analog scale.

Keywords: case report, hyaluronic acid, knee osteoarthritis, polynucleotides

1. Introduction

Knee osteoarthritis (KOA) is a chronic joint disorder characterized by changes in chemical-physico and functional properties of the synovial fluid, degeneration of the articular cartilage, and macroscopical modifications of knee joint.^[1] KOA is a leading cause of pain and disability among elderly people.^[2] Therapeutic modalities for KOA include analgesics, physiotherapy, intra-articular steroid injection, oral supplementation with chondroitin, glucosamine, nonsteroidal anti-inflammatory drugs (NSAIDs), and topical capsaicin.^[3] Intra-articular injection

(IAI) of hyaluronic acid (HA) is also commonly used in the treatment of the mid- to moderate-stages of KOA.^[4,5] The main effect of HA is a “cushion effect” that reduces the friction of articular cartilage and provides a lubricant composition for intra-articular space. Thus, cartilage is able to maintain elasticity and become more resistant to mechanical stress.^[4,6] However, the effect of HA remains still controversial. Previous studies have casted doubt on the disease modifying effect of HA.^[1,7] Several adverse events of HA have been reported, including hemarthrosis, synovitis, pseudogout, and muscle pain.^[5] Polynucleotides (PN) (product name: Condrotide) has been developed in an attempt to provide nutrients to restore the physiology of the intra-articular environment and articular cartilage homeostasis. PNs are polymer molecules that are able to bind large amounts of water and form a tridimensional gel.^[3] Here we report a patient with KOA who underwent ultrasound guided multiple IAI of PN for management of intractable knee pain.

2. Case presentation

A 61-year-old female was admitted to the pain center with symptoms of pain over the knee and warmth feeling with stiffness in the left knee. The patient reported chronic severe pain in the left knee area aggravating in the morning. It is exacerbated when she is active. At the time of admission, she walked with a limp due to refractory pain rated 6/10 on visual analog scale (VAS). Physical examination revealed crackling and creaking sound during knee flexion and extension movement. The knee had lost its strength and range of motion. It resisted knee flexion. Her height, weight,

Editor: N/A.

JUM and HRC equally contributed to this paper as co-first authors.

The authors have no conflicts of interest to disclose.

^a Department of Orthopaedic Surgery, Changwon Gyeongsang National University Hospital, Republic of Korea, ^b Myongji Hospital, College of Medicine, Seonam University, Goyang, Korea, ^c Department of Anesthesiology and Pain Medicine, Catholic Kwandong University of Korea College of Medicine, International St. Mary's Hospital, Incheon, Republic of Korea.

* Correspondence: Young Uk Kim, Department of Anesthesiology and Pain Medicine, Catholic Kwandong University of Korea College of Medicine, International St. Mary's Hospital, Simgokro, 100 Gil 25, Seo-Gu, Incheon City, Republic of Korea (e-mail: uk201@hanmail.net).

Copyright © 2017 the Author(s). Published by Wolters Kluwer Health, Inc. This is an open access article distributed under the Creative Commons Attribution License 4.0 (CCBY), which permits unrestricted use, distribution, and reproduction in any medium, provided the original work is properly cited.

Medicine (2017) 96:49(e9127)

Received: 7 November 2017 / Accepted: 16 November 2017

<http://dx.doi.org/10.1097/MD.00000000000009127>

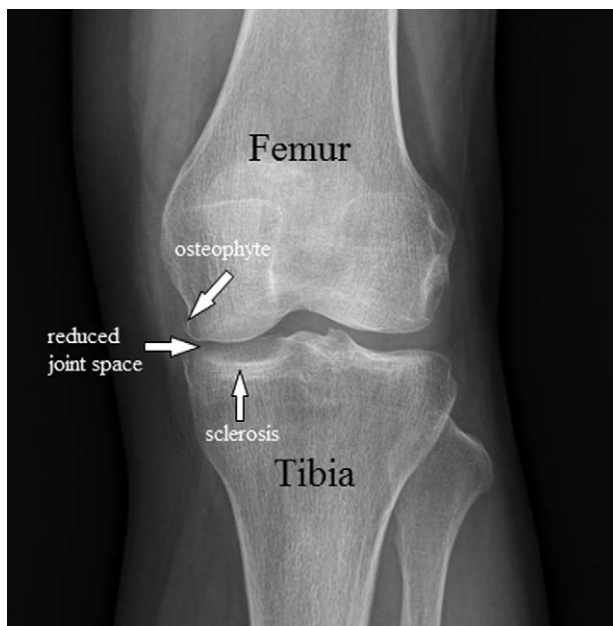


Figure 1. X-ray of the knee showing bone spurs, sclerosis, and a narrowed joint space caused by osteoarthritis.

and body mass index were 167cm, 64kg, and 22.93kg/m², respectively. She had the past medical history of breast cancer, thyroid cancer, and spinal stenosis. She had received IAI of HA 6 times in 3 months and NSAIDs for intractable pain of the medial knee. However, there was no improvement.

Knee x-ray revealed the loss of joint space, subchondral sclerosis, and bone spurs developing along edges of the knee joint (Fig. 1).

We presented therapeutic effects of PN to her. Verbal and written informed consent was obtained from the patient before the procedure. The patient was brought to the ultrasound room and placed on the table in a supine position with bent left knee. We performed ultrasound guided IAI using 40mg/2mL of PN with a 26-G 4-cm needle (Fig. 2). At the 1 week follow-up after the IAI of PN, no decrease in VAS score was recorded. The patient reported a persistent refractory pain in her left knee. Therefore, a

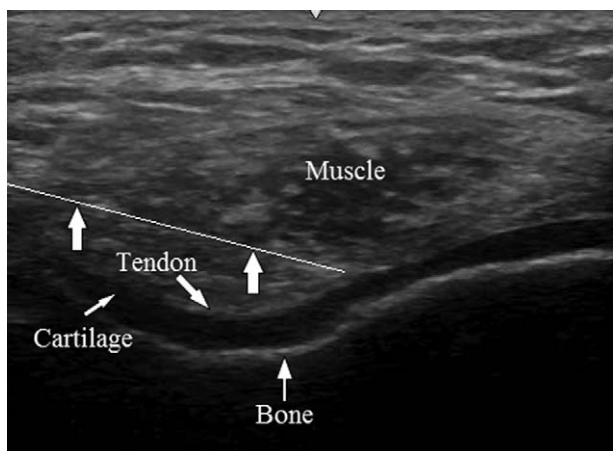


Figure 2. Ultrasound image during injection of polynucleotides in the knee joint space (arrow indicates the block needle.).

Table 1

Knee injury and osteoarthritis outcome score and VAS score.

Outcome	Pretreatment	Post-treatment	Difference
Pain	34/100	84/100	50
Symptoms	33/100	83/100	50
ADL	59/100	96/100	37
Sport/Rec	14/100	88/100	74
Quality of life	36/100	78/100	42
VAS	6/10	1/10	5

ADL = activities of daily living, VAS = visual analog scale.

second IAI of PN was performed. At the 2-weeks follow-up, the patient reported little pain relief with decreased VAS scores from 6 to 5. After the third IAI of PN, she described significant pain reduction with decreased VAS scores from 5 to 1. The patient also showed improvement for all Knee Injury and Osteoarthritis Outcome Score subscales (Table 1).

Follow-up was continued for more than 5 months. Clinically, she showed almost complete functional resolution. She was able to jump, run, and hop without disability or pain. She almost completely restored both passive and active ranges of motion without stiffness. We also investigated the adverse effect of PN injection during follow-up. No side-effect was observed.

3. Discussion

We present a case of a female patient with KOA who was successfully treated after receiving multiple IAI of PN for intractable knee pain. KOA represents a major burden to public health worldwide. It is the most common subtype of arthritis. The prevalence of KOA is estimated to be 44% in patients over 80 years old and 27% in patients under 70 years old.^[5] Progressive stages in KOA are characterized by cartilage erosion, synovial inflammation, subchondral bone sclerosis, increased bone resorption, soft tissue fibrosis, stiffness, and pain in affected joints.^[8–10] Diverse pharmacological agents are used for the treatment of KOA, including NSAIDs, IAI of corticosteroid or HA, oral supplements such as chondroitin^[11] or glucosamine, and topical treatments such as capsaicin.^[12] However, a number of treatments only provide short-term benefit. They may not be satisfactorily effective. Moreover, some procedures are associated with risks. For example, hemarthrosis, synovitis, pseudogout, and muscle pain have been reported after IAI of HA.^[5] Autologous conditioned serum, intra-articular mesenchymal stem cell injection, and platelet rich plasma have been recently studied.^[13,14] However, currently there are not enough randomized controlled data available. Moreover, these operations are too expensive. Conversely, PNs are polymeric molecules that are subjected to enzymatic cleavage with progressive intra-articular release of both small oligonucleotides (nucleotides, nucleosides, nucleobases) and water molecules. They can deeply moisturize the articular surface, thus maintaining viscoelastic, moisturizing, and metabolic effects for a long time.^[15] Giarratana et al^[3] have reported a significant reduction in pain after PN injection by maintaining homeostasis of chondrocytes through providing nutritional supplements to the joint and restoring the microenvironment. Vanelli et al^[11] have demonstrated that PN can stimulate the healing process of cartilage with remarkable trophic and viscoelastic properties, thus providing satisfactory and stable clinical outcome.

By administering IAI of PN, the synovial fluid is enriched with nucleotides, purine, and pyrimidine bases to support cellular metabolism.^[1,5] Polynucleotides (PN) extracted from fish sperm are highly pure. PNs consist of polymers and polynucleotides ubiquitously present in the human body.^[1] Chronic and acute toxicity studies have reported that PN has no toxic effect.^[1,5] Based on safety and the efficacy of PN presented in previous studies, we decided to administer PN and received informed consent from the patient after giving the patient a detailed explanation of the procedure. We conducted ultrasound guided IAI of PN. Despite previous treatments such as IAI of HA, NSAIDS administration, and physiotherapy, they all failed. However, the patient showed good clinical response to PN. The important point of this case report is that IAI of PN is an efficient therapeutic option for treatment of KOA if HA injection is unsuccessful.

4. Informed consent

Informed consent was obtained from the patient for publication of this case report and related images.

References

- [1] Vanelli R, Costa P, Rossi SM, et al. Efficacy of intra-articular polynucleotides in the treatment of knee osteoarthritis: a randomized, double-blind clinical trial. *Knee Surg Sports Traumatol Arthrosc* 2010; 18:901–7.
- [2] Corti MC, Rigon C. Epidemiology of osteoarthritis: prevalence, risk factors and functional impact. *Aging Clin Exp Res* 2003;15:359–63.
- [3] Giarratana LS, Marelli BM, Crapanzano C, et al. A randomized double-blind clinical trial on the treatment of knee osteoarthritis: the efficacy of polynucleotides compared to standard hyaluronan viscosupplementation. *Knee* 2014;21:661–8.
- [4] Bert JM, Bert TM. Nonoperative treatment of unicompartmental arthritis: from bracing to injection. *Clin Sports Med* 2014;33:1–0.
- [5] Richards MM, Maxwell JS, Weng L, et al. Intra-articular treatment of knee osteoarthritis: from anti-inflammatories to products of regenerative medicine. *Phys Sportsmed* 2016;44:101–8.
- [6] Hanypsiak BT, Shaffer BS. Nonoperative treatment of unicompartmental arthritis of the knee. *Orthop Clin North Am* 2005;36:401–11.
- [7] Bellamy N, Campbell J, Robinson V, et al. Viscosupplementation for the treatment of osteoarthritis of the knee. *Cochrane Database Syst Rev* 2006;19:2.
- [8] Bettica P, Cline G, Hart DJ, et al. Evidence for increased bone resorption in patients with progressive knee osteoarthritis: longitudinal results from the Chingford study. *Arthritis Rheum* 2002;46:3178–84.
- [9] Phan CM, Link TM, Blumenkrantz G, et al. MR imaging findings in the follow-up of patients with different stages of knee osteoarthritis and the correlation with clinical symptoms. *Eur Radiol* 2006;16:608–18.
- [10] Plaas A, Li J, Riesco J, et al. Intraarticular injection of hyaluronan prevents cartilage erosion, periarticular fibrosis and mechanical allodynia and normalizes stance time in murine knee osteoarthritis. *Arthritis Res Ther* 2011;13:R46.
- [11] Reichenbach S, Sterchi R, Scherer M, et al. Meta-analysis: chondroitin for osteoarthritis of the knee or hip. *Ann Intern Med* 2007;146:580–90.
- [12] Schnitzer TJ, Posner M, Lawrence ID. High strength capsaicin cream for osteoarthritis pain: rapid onset of action and improved efficacy with twice daily dosing. *J Clin Rheumatol* 1995;1:268–73.
- [13] Frizziero A, Giannotti E, Oliva F, et al. Autologous conditioned serum for the treatment of osteoarthritis and other possible applications in musculoskeletal disorders. *Br Med Bull* 2013;105:169–84.
- [14] Wakitani S, Imoto K, Yamamoto T, et al. Human autologous culture expanded bone marrow mesenchymal cell transplantation for repair of cartilage defects in osteoarthritic knees. *Osteoarthritis Cartilage* 2002; 10:199–206.
- [15] Saggini R, Di Stefano A, Cavezza T, et al. Intraarticular treatment of osteoarthropathy knee with polynucleotides: a pilot study with medium-term follow-up. *J Biol Regul Homeost Agents* 2013;27:543–9.