

# Surgical Treatment vs Nonsurgical Treatment for Brain Arteriovenous Malformations in Patients with Hereditary Hemorrhagic Telangiectasia: A Retrospective Multicenter Consortium Study

Ali Tayebi Meybodi, MD\*  
 Helen Kim, PhD<sup>†</sup>  
 Jeffrey Nelson, MS<sup>‡</sup>  
 Steven W. Hetts, MD<sup>§</sup>  
 Timo Krings, MD, FRCPC<sup>||</sup>  
 Karel G. terBrugge, MD<sup>||</sup>  
 Marie E. Faughnan, MD, MSc<sup>#</sup>  
 Michael T. Lawton, MD<sup>\*†</sup>  
 On Behalf Of The Brain  
 Vascular Malformation  
 Consortium HHT Investigator  
 Group

\*Department of Neurological Surgery, University of California, San Francisco, San Francisco, California; <sup>†</sup>Department of Anesthesia and Perioperative Care, University of California, San Francisco, San Francisco, California; <sup>‡</sup>Division of Neurointerventional Radiology, Department of Radiology and Biomedical Imaging, University of California, San Francisco, San Francisco, California; <sup>§</sup>Center for Cerebrovascular Research, University of California, San Francisco, San Francisco, California; <sup>||</sup>Division of Neuroradiology, Department of Medical Imaging, Toronto Western Hospital, University of Toronto, Toronto, Ontario, Canada; <sup>#</sup>Division of Respiriology, Keenan Research Centre, and Li Ka Shing Knowledge Institute, St. Michael's Hospital, University of Toronto, Toronto, Ontario, Canada

#### Correspondence:

Michael T. Lawton, MD,  
 Department of Neurosurgery,  
 University of California, San Francisco,  
 505 Parnassus Avenue, M780,  
 San Francisco, CA 94143.  
 E-mail: [Michael.Lawton@ucsf.edu](mailto:Michael.Lawton@ucsf.edu)

Received, July 15, 2016.

Accepted, May 24, 2017.

Published Online, July 4, 2017.

Copyright © 2017 by the  
 Congress of Neurological Surgeons

**BACKGROUND:** Cerebral arteriovenous malformations (AVMs) are common in patients with hereditary hemorrhagic telangiectasia (HHT). However, due to the rarity of HHT and little published evidence of outcomes from management of brain AVMs in this disease, current international HHT guidelines recommend an individualized approach. Specifically, the outcomes for surgical vs nonsurgical management of these lesions have not been reported to date.

**OBJECTIVE:** To report long-term outcomes of surgical resection of brain AVMs in HHT patients compared to outcomes in nonsurgically treated patients.

**METHODS:** From the database of the Brain Vascular Malformation Consortium HHT project, 19 patients with 20 resected AVMs (group 1) and 22 patients with 33 AVMs who received nonsurgical treatment (group 2) were studied. The groups were retrospectively reviewed for changes in functional status (modified Rankin Scale score) during the follow-up period.

**RESULTS:** During the follow-up period, 9% of patients in group 1 suffered from worsening of functional status, whereas this figure was 16% for group 2 ( $P > .05$ ). Functional outcomes were not statistically different between the 2 groups at the latest follow-up ( $P > .05$ ).

**CONCLUSION:** HHT patients treated surgically for brain AVMs appear to have long-term functional outcomes comparable to nonsurgical (including observational) therapy with fewer unfavorable outcomes. It is therefore reasonable to consider surgical resection as a management option in the multidisciplinary team's individualized treatment strategy for HHT patients with brain AVMs.

**KEY WORDS:** Arteriovenous malformation, Hereditary hemorrhagic telangiectasia, Rendu-Osler-Weber disease, Embolization, Radiosurgery, AVM grading, Microsurgical resection, Brain vascular malformation consortium

*Neurosurgery* 82:35–47, 2018

DOI:10.1093/neuros/nyx168

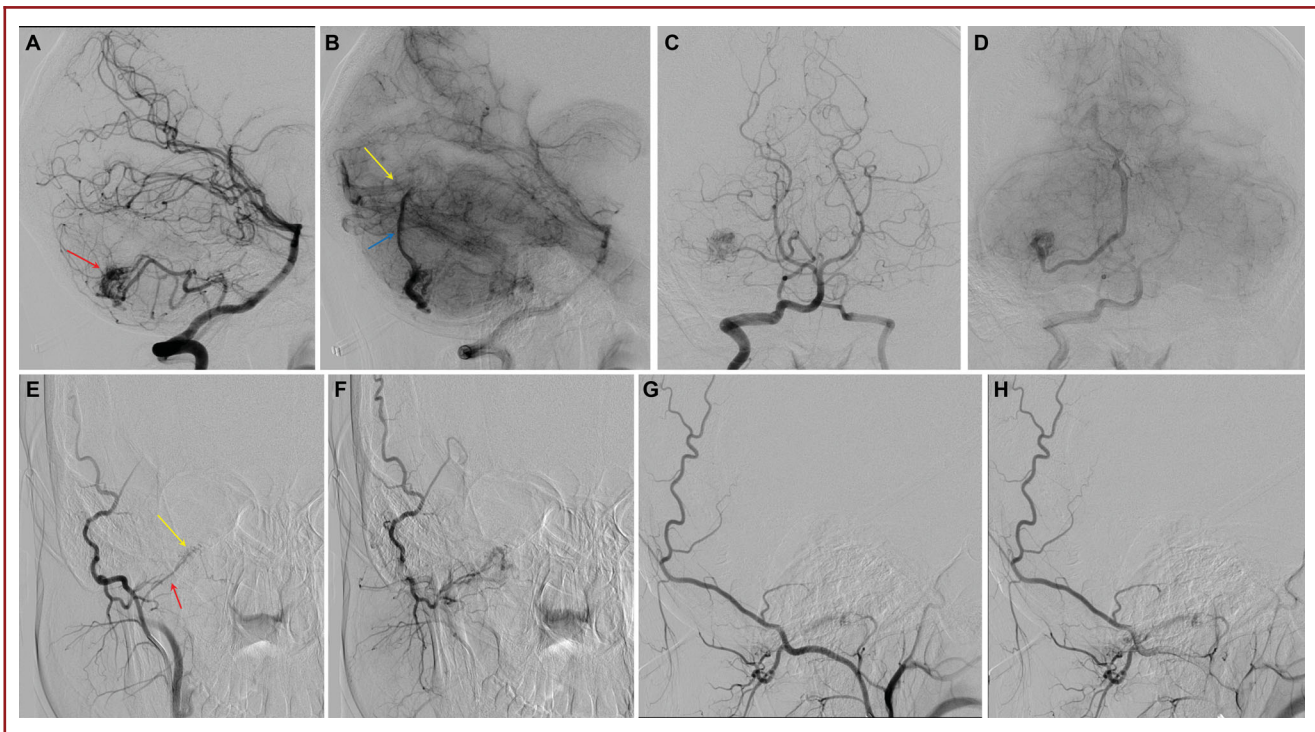
[www.neurosurgery-online.com](http://www.neurosurgery-online.com)

**H**ereditary hemorrhagic telangiectasia (HHT) is a rare familial disorder with autosomal dominant inheritance.<sup>1</sup> It is characterized by multiple mucocutaneous telangiectasias and visceral vascular malformations (VMs). HHT has a reported overall preva-

lence of 1 to 2 in 10 000, although geographical location has great impact on this figure.<sup>2–4</sup> Neurological complications affect about 8% to 27% of HHT patients.<sup>5–8</sup> The majority of neurological complications in HHT patients are associated with pulmonary AVMs, causing stroke or brain abscess.<sup>9–11</sup> However, cerebral VMs account for one-third of neurological manifestations in HHT patients.<sup>10,12</sup> VMs of the brain are found in 5% to 23% of HHT patients.<sup>12–15</sup> Generally, 3 types of cerebral VMs are described in HHT patients: (1) arteriovenous malformations (AVMs); (2) nonshunting, small, superficially located collections of enhancing vessels with no enlarged feeding artery or

**ABBREVIATIONS:** AVF, arteriovenous fistula; AVM, arteriovenous malformation; BVMC, Brain Vascular Malformation Consortium; HHT, hemorrhagic telangiectasia; mRS, modified Rankin Scale; SD, standard deviation; SM, Spetzler–Martin; VM, vascular malformation

*Neurosurgery* Speaks! Audio abstracts available for this article at [www.neurosurgery-online.com](http://www.neurosurgery-online.com).



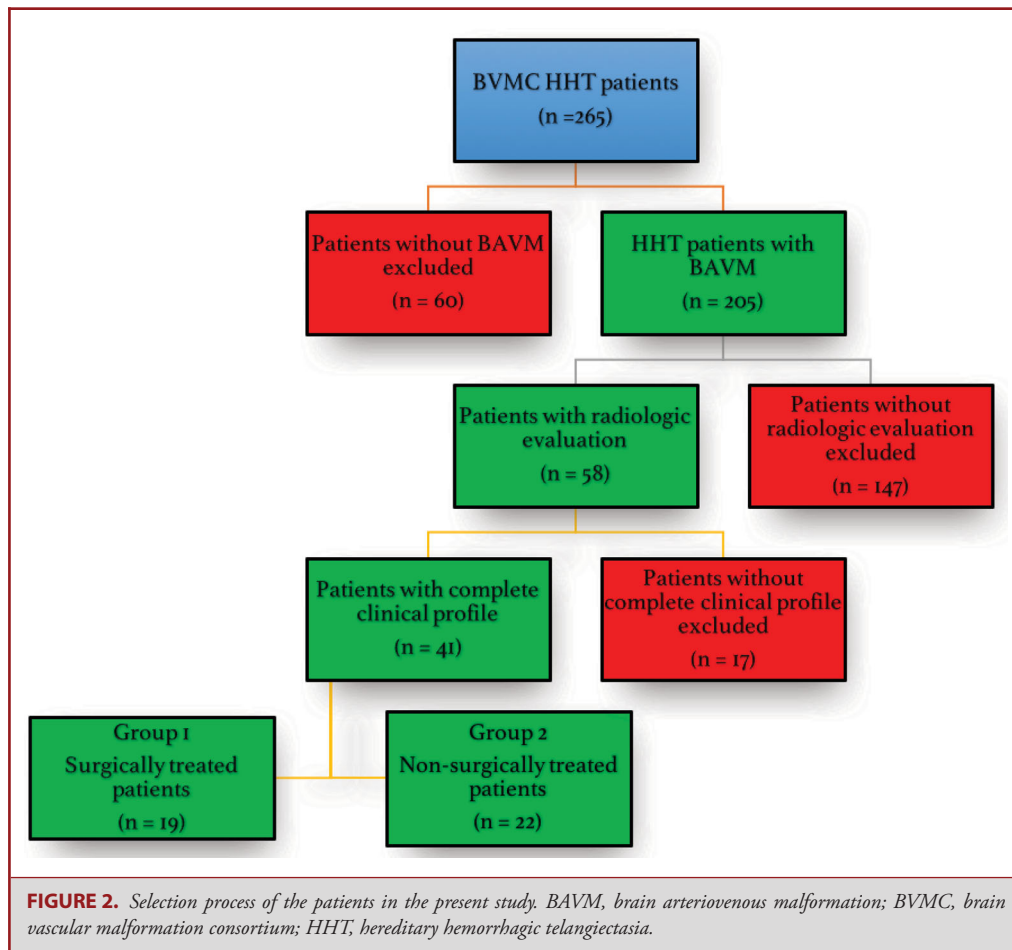
**FIGURE 1.** Cerebral digital subtraction angiograms of a 19-yr-old female presenting with intractable headaches and syncopal episodes demonstrate a characteristic AVM in an HHT patient. Lateral **A, B** and anteroposterior **C, D** projections of vertebral artery injection in arterial and capillary phases showing a right superficial cerebellar 1.2 × 1.3 cm arteriovenous malformation (red arrow in **A**) supplied by posterior inferior cerebellar artery with superficial hemispheric drainage (blue arrow in **B**) to the straight sinus near the torcula (yellow arrow in **B**). Although there are no flow-related or intranidal aneurysms, there is a high-grade stenosis of the venous outflow at the junction between the cortical vein and the straight sinus. Anteroposterior **E, F** and lateral **G, H** projections of selective right occipital artery injection in the same patient also show a hypoglossal canal arteriovenous fistula (yellow arrow in **E**) fed by the hypoglossal branch of the right occipital artery (red arrow in **E**) and draining into condylar veins.

draining vein, named “capillary VMs”; and (3) arteriovenous fistulas (AVFs).<sup>16-18</sup> AVMs, with evidence of shunting and the presence of a nidus, comprise 15.8% to 83.3% of all cerebral VMs in HHT patients.<sup>12,15-20</sup> Most of these brain AVMs are superficial and small (<3 cm) and have a single feeder and a single draining vein (Figure 1).<sup>9,17,18,20-22</sup>

The annual risk of an AVM rupture in HHT patients has been estimated to be 0.36% to 1.02% per year.<sup>15,23,24</sup> In the largest series to date, however, the confidence intervals were large, with intracranial hemorrhage rates ranging from 0.42% to 2.44% per year, and higher rates reported in those with initial hemorrhagic presentation.<sup>23</sup> Most brain AVMs in these patients were discovered by magnetic resonance screening, as routinely performed for HHT patients in North American HHT centers.<sup>13,15,16,24</sup> Although multiple radiological and clinical descriptions of cerebral VMs in HHT patients exist, few studies have focused on the treatment of these lesions.<sup>13,21,25,26</sup> Due to the paucity of the literature in this regard, there is no accepted standard treatment paradigm for brain AVMs in HHT. Current international HHT guidelines recommend an individualized approach conducted by a multidisciplinary team with

neurovascular expertise.<sup>27</sup> Presently, there are various available treatment techniques (microsurgical resection, radiosurgery, and embolization therapy) as well as combined modalities and, finally, the “wait-and-see” approach.

The development of treatment guidelines for HHT patients with brain AVMs is difficult for many reasons. First, HHT-related brain AVMs are rare, and single-institution experiences are small; second, the anatomic characteristics of these lesions differ from sporadic brain AVMs, which may prevent experiences and guidelines derived from sporadic AVM therapy from being applied to HHT AVMs; and third, some studies have suggested a dynamic clinical course for HHT-related brain AVMs with clear growth and regression,<sup>25,28,29</sup> which may modify their response to standard AVM therapies. Nonetheless, guidelines are important for these patients because their lesions are increasingly detected by screening studies rather than by hemorrhagic presentation, and the diagnosis of an unruptured brain AVM creates a management dilemma, particularly in the aftermath of the ARUBA (A Randomized Trial of Unruptured Brain Arteriovenous Malformations) trial results. Therefore, we formed a multicenter consortium of academic institutions with



dedicated expertise in the management of HHT patients—the Brain Vascular Malformation Consortium (BVMC)—with the intention of studying HHT-related AVMs and their treatments. The BVMC, which is funded by the National Institutes of Health and is part of the Rare Diseases Clinical Research Network, facilitated the assembly of the largest cohort of operated HHT-brain AVM patients to date for analysis of surgical therapy and outcomes, and compared these results to those from nonsurgically treated brain AVMs in HHT patients.

## METHODS

This retrospective study was approved by the institutional review board and performed in compliance with Health Insurance Portability and Accountability Act regulations. HHT patients enrolled in the BVMC HHT project between April 2010 and November 2015 were studied ( $n = 265$ ). After obtaining informed consent, patients were recruited to the BVMC as previously described.<sup>18</sup> All patients had a genetic or clinical diagnosis of HHT (definite HHT with  $\geq 3$  criteria of the 4 Curaçao criteria).<sup>30</sup> We included all patients recruited with known

history of brain AVMs and who also had available diagnostic imaging for review ( $n = 58$ ). Of these, we excluded 17 patients with incomplete clinical profiles. Only 2 of these 17 patients underwent surgery, and neither of the operated patients showed worsening of functional status at long-term follow-up, as the modified Rankin Scale (mRS) scores for these 2 patients were 2, both before surgery and at the latest follow-up visit. Patients with brain AVMs had their brain imaging reviewed by our senior radiologist (TK). These patients were allocated to one of 2 groups: (1) patients with at least 1 of the brain AVMs resected ( $n = 19$ ) and (2) patients without a history of surgery for brain AVMs ( $n = 22$ ; Figure 2). Clinical information retrieved from the BVMC dataset included (1) age at the time of diagnosis (and surgery, if performed), (2) symptoms at clinical presentation (including cerebral hemorrhage from AVM rupture), (3) the functional status (ie, mRS) at the time of diagnosis (for nonsurgically treated patients) or at the time of surgery (for the surgically treated patients), and (4) the latest follow-up mRS score. For patients who underwent surgery, the early postoperative mRS score (at 6 wk) was also recorded.

Radiological evaluation included recording type, count, and location of all cerebral VMs (including AVMs, AVFs, and capillary VMs), as well as criteria for determining Spetzler–Martin (SM), Lawton–Young, and Supplemented Spetzler–Martin (Supp-SM) scores<sup>31</sup> for brain AVMs.

**TABLE 1. Clinical Data for Surgically Treated and Nonsurgically Treated HHT Patients With Brain Arteriovenous Malformation in Current Series**

	Surgically treated (n = 19)	Nonsurgically treated (n = 22)
Age at diagnosis, median (range)	27 (0.1-55)	42 (0.6-72.5)
Female, n (%)	12 (63%)	12 (54%)
Presentation, n (% lesions)		
Asymptomatic	6 (32%)	18 (82%)
Headache	10 (52%)	3 (14%)
Seizure	3 (16%)	3 (14%)
Focal neurological deficit	6 (32%)	2 (9%)
Hemorrhage	1 (5%)	3 (14%)

<sup>a</sup>AVM, arteriovenous malformation.

Lesion obliteration was confirmed by postoperative imaging reviewed by BVMC radiologists.

### Statistical Analysis

Statistical analysis included Mann–Whitney *U*-test to compare median mRS scores between the two groups, Student's *t*-test to compare parametric means, and the 2-sample *z* test to compare proportions of various parameters (eg, functional status, radiological grades) between the 2 groups. Spearman's Rho was calculated to evaluate correlation between the radiological lesion grade and the surgical outcome.

## RESULTS

### Group 1: Surgically Treated

Of the 14 centers enrolled in BVMC, the 19 surgically treated patients were recruited at 8 centers. Average total number of brain AVM cases enrolled in each site was 15 patients (range, 9-24). Considering all patients diagnosed with brain AVM in these 8 centers regardless of the completeness of clinical profile or radiological evaluation (n = 118), average surgery rate for the BAVM was 16% (range: 8%-25%, standard deviation [SD] 6%).

There were 12 female and 7 male patients with 20 brain AVMs resected, and a total number of 27 lesions including 21 AVMs and 6 capillary VMs (mean 1.4 lesions per patient, range 1-5). No cerebral AVF was present in any of the surgically treated patients. Median age at surgery was 28 yr (range, 0.5-69 yr), whereas median age at diagnosis was 27 yr (range, 0.1-55 yr). One patient (5%) presented with clinical manifestations of AVM rupture (ie, intracranial hemorrhage). Six patients (32%) were diagnosed through screening studies or while evaluating for other cerebral lesions. The most common presenting symptoms were headache (52%) and focal neurological deficit (32%; Table 1).

Lesions were most commonly located in the frontal (45%) and parietal (20%) lobes (Table 2). Eight lesions were in eloquent areas (40%). Average size of the lesions was 18.6 mm (range: 8-36 mm; SD: 8). Most lesions were superficially located with super-

ficial venous drainage (90%); 2 lesions had deep venous drainage. Lesion grade was SM grade 1 or 2 in 90% (Table 2). Most of the parietal lobe (3/4, 75%) and frontal lobe (8/9, 89%) lesions were symptomatic in this group (Table 3).

### Complications and Outcomes

All lesions were eradicated surgically as confirmed by postoperative imaging. Median preoperative, early postoperative, and late follow-up mRS scores were 1. Three patients suffered from early postoperative neurological complications that resolved within 1 month after surgery. These included transient sensorimotor deficits in 1 frontal (SM grade 2) and 1 parietal (SM grade 3) AVM and transient dysmetria in a cerebellar AVM (SM grade 1). One patient with a left frontal AVM (SM grade 2) had an associated aneurysm that ruptured while the patient was on the operating table and caused hemiparesis and dysphasia. This patient's neurological deficits rapidly improved over the following months, and he was completely symptom-free at the first long-term follow-up visit. Table 3 summarizes the clinical picture of the individual patients in this group.

Median mRS score at the time of diagnosis was 1. Overall, the early postoperative functional status (6 wk after surgery) was unchanged in 14 (74%), improved in 3 (16%), and worsened in 2 (10%) patients. Patient follow-up was available for an average of 9.6 yr (median 6.3 yr; 1.6-33.9 yr). Overall, the functional status of the patients was improved in 3 (16%), worsened in 5 (26%), and not changed in 11 (58%) during the entire period of follow-up. At the latest follow-up, 14 patients (74%) had good functional status (mRS 0 and 1) and 5 had an mRS score of 2 (Figure 3). Calculation of Spearman's Rho did not reveal any significant correlation between preoperative SM or Supp-SM grades with early and late postoperative mRS scores ( $P > .05$ ).

Twelve patients (63%) did not receive any adjuvant therapy, including radiosurgery or embolization. One patient had received stereotactic radiosurgery 1 yr before surgery without any evidence of shrinkage of the AVM. A total of 10 embolization sessions had been performed preoperatively in 7 patients, with the goal of facilitating surgery in 5 patients and the goal of definitive treatment in



**TABLE 2. Radiological Characteristics and Lesion Grades of 20 Surgically Resected Arteriovenous Malformations and 33 Lesions Managed Nonsurgically**

Characteristic	Surgery n (%)	No surgery
Deep venous drainage	2 (10)	2 (6)
Eloquent Lobe	8 (40)	10 (30)
Frontal	9 (45)	18 (55)
Parietal	4 (20)	2 (6)
Occipital	2 (10)	7 (21)
Cerebellum	2 (10)	3 (9)
Temporal	2 (10)	2 (6)
Deep	1 <sup>a</sup> (5)	1 <sup>b</sup> (3)
<b>Spetzler–Martin grade</b>		
1	9 (45)	22 (66)
2	9 (45)	9 (27)
3	2 (10)	1 (3.5)
4	0	1 (3.5)
5	0	0
<b>Lawton–Young grade</b>		
1	1 (5)	0
2	7 (35)	8 (24)
3	3 (15)	12 (37)
4	9 (45)	11 (33)
5	0	2 (6)
<b>Supplemented Spetzler–Martin grade<sup>c</sup></b>		
2	0	0
3	3 (15)	5 (15)
4	7 (35)	9 (27.5)
5	6 (30)	12 (36.5)
6	3 (15)	7 (21)
7	1 (5)	0
8	0	0
9	0	0
10	0	0

<sup>a</sup>Brainstem.<sup>b</sup>Thalamus.<sup>c</sup>Supplemented Spetzler–Martin grade is the add-up of Spetzler–Martin and Lawton–Young grades.

2 patients. Attempts at curative embolization in these 2 patients were unsuccessful.

### Group 2: Nonsurgically Treated

A total of 22 patients (12 females and 10 males) were included (Table 1). In this group of patients, 33 AVMs and 9 micro-AVMs were present (1.9 lesions per patient). No cerebral AVF was present in these patients. The median age of this group was 42 yr at diagnosis. Three patients/lesions were diagnosed after initial presentation with ICH. Overall, 5 patients/lesions were diagnosed after they became symptomatic (headache, seizure, focal deficit, and/or hemorrhage), while the rest of the lesions were diagnosed during screening studies or incidentally during brain angiography performed for the symptomatic lesion.

Most common locations for the lesions were the frontal (55%) and occipital (21%) lobes (Table 2). Ten lesions were in eloquent locations (30%). Mean size of the lesions in the nonsurgically treated group was 14.7 mm (range 7–35 mm, SD 6.9). Lesions were superficially located with superficial drainage (94%) except for 1 thalamic lesion and 1 temporal AVM with deep venous drainage. The majority of lesions (93%) were of SM grade 1 or 2 (Table 4). In this group, all the occipital and parietal lesions and the majority of frontal lobe lesions (15/18) were asymptomatic.

### Complications and Outcomes

Median mRS score at the time of diagnosis was 1. Follow-up was available for an average of 4.6 yr. During the entire follow-up period, 8 (36%) worsened functionally, while 12 (55%) did not change and 2 (9%) improved. At the latest follow-up, median mRS score was 1, and 15 patients (68%) had good functional status (mRS 0 and 1; Figure 3).

Thirteen patients (59%) were followed up without any therapeutic intervention. Six patients (27%) were treated only with radiosurgery, 2 patients (9%) received only embolization, and 1 (5%) patient received both.

Summary of clinical and radiological data of the lesions is depicted in Tables 1 and 2. Tables 3 and 4 show the individual patients' clinicoradiological characteristics and functional status data in the surgically treated and nonsurgically treated groups, respectively.

### Comparison of the 2 Groups

There was no statistically significant difference between the surgically treated and nonsurgically treated groups in terms of number of AVMs, lesion size, venous drainage, and mRS scores at the time of diagnosis and latest follow-up. Although the median ages at the time of diagnosis differed (27 yr for group 1 vs 42 yr for group 2), Student's *t*-test failed to show a statistically significant difference in the mean age of patients at the time of diagnosis between the 2 groups. The percentages of low-radiological grade lesions (ie, SM grade  $\leq 2$  and Supp-SM grade  $\leq 6$ ) were not statistically different between groups ( $P > .05$ ). When the latest follow-up mRS of the surgically treated group was compared with the patients who received no form of treatment in the nonsurgically treated group (13 patients), no significant difference was observed (Mann–Whitney *U*-test,  $P > .05$ ). Two-sample *z* test did not reveal any statistically significant difference regarding the proportions of various functional status changes (ie, not changed, improved, and worsened) between 2 groups ( $P > .05$ ).

## DISCUSSION

### Operative Risk

Previous reports on surgery for brain AVMs in HHT patients are scant, with limited information on postoperative outcomes (Table 5).<sup>24,25</sup> Here, we report the outcomes for the largest surgical cohort of HHT patients ( $n = 19$ ) with cerebral AVMs (not including capillary VMs or AVFs) to date and compare

**TABLE 3. Clinical and Radiological Features of Individual Patients in Group 1 (Surgically Treated) and Their Initial, Early Postop, and Late Postop Functional Status**

Patient no.	Age at surgery (years), sex	Symptoms prior to surgery	Lesion location	Lesion grade		Early postop mRS score		Latest postop mRS score	Complications	Adjuvant therapy
				SM	LY	Preop mRS score	Postop mRS score			
1	10, F	Headache, Seizure, FND	R Frontal	1	2	2	0	2	None	E
2	29, F	Asymptomatic	R Temporal	1	2	0	1	2	None	–
3	24, F	Headache	R Parietal	2	3	2	2	2	None	–
4	50, M	Headache	R Frontal	1	4	2	2	1	None	–
			R Parietal	1	4					
5	45, F	Headache	R Frontal	2	4	1	1	0	None	–
6	41, M	Congenital facial weakness due to encephalomalacia	R Frontal	2	4	1	1	1	None	–
7	15, F	Asymptomatic	L Frontal	2	2	1	1	1	None	E
8	11, F	Headache, Somatosensory partial Seizures	L Frontal	2	2	1	1	1	seizures, sensorimotor deficit resolved in 30 d	–
9	69, M	Gait instability	Brainstem	3	4	0	0	2	None	E
10	19, F	Headache, Fainting	Cerebellar	1	2	1	0	1	mild dysmetria resolved within 1 d after surgery	–
11	0.5, M	Hemorrhage	L Parietal	3	1	0	0	1	R hemiparesis resolved 10 d after surgery	–
12	39, M	Asymptomatic	Cerebellar	1	4	0	0	0	None	E, RS
13	9, M	Asymptomatic	Cerebellar	2	2	0	0	0	None	–
14	26, F	Headache	L Frontal	1	3	0	0	0	None	E
15	40, F	Asymptomatic <sup>a</sup>	L Parietal	2	3	2	2	1	None	E
16	27, M	Headache <sup>b</sup>	L Frontal	1	4	0	4	0	Hemiparesis	–
17	6, F	Headache	R Frontal	2	2	0	0	0	None	–
18	55, F	Asymptomatic	L Temporal	2	4	0	0	1	None	E
19	65, F	Partial Seizure	L Occipital	1	4	1	0	2	None	–

M, male; F, female; FND, focal neurological deficit; R, right; L, left; E, embolization; RS, radiosurgery.

<sup>a</sup>Underwent angiography for decreased vision which revealed an ophthalmic artery aneurysm and the asymptomatic arteriovenous malformation.

<sup>b</sup>Aneurysm rupture on operating table.

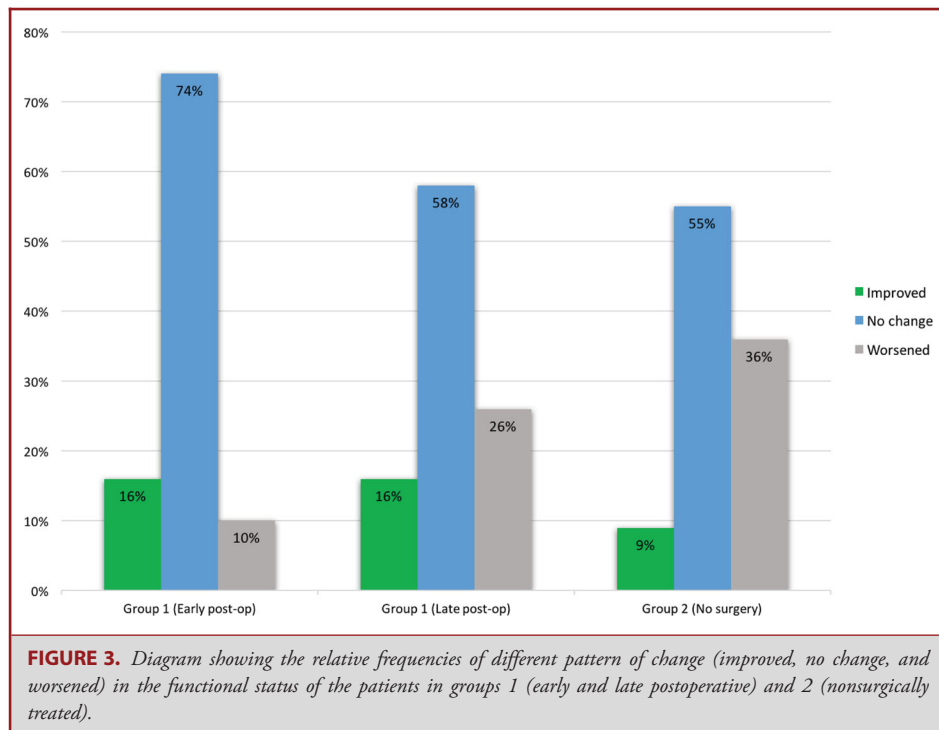
them to outcomes of a similar group of HHT patients who did not receive surgical treatment for their brain AVM(s). This comparison shows that, when carefully selected, operative resection of brain AVMs can be considered a safe treatment option in HHT patients (Figure 4). The multicenter nature of our study generalizes this point of view, as different centers with variable levels of surgical expertise were involved in treating these patients. Surgical patients had a relatively long follow-up time (mean 9.6 yr, minimum 1.6 yr), and the majority of the patients had good functional status (median mRS = 1) at early and late follow-up (Figure 3). Small lesion size (average 18.6 mm), superficial location, low frequency of deep drainage (10%), and low SM and Supp-SM grades overall, as typically seen in HHT patients,<sup>18,24</sup> may have contributed to the favorable early and late postoperative outcomes, even though 40% of the operated lesions were in

eloquent brain areas. We found no correlation between the preoperative lesion grade and postoperative mRS scores, suggesting that SM (or Supp-SM) grading may not be the best preoperative tool for surgical decision making in HHT. This finding might also be due to the small sample size, absence of high-grade lesions in our sample, and a high percentage of favorable postoperative functional outcomes.

### Comparison of Surgically Treated and Nonsurgically Treated Groups

#### Mode of Presentation

There is controversy about the hemorrhage risk of brain AVMs in HHT patients.<sup>15,23,24</sup> However, it is generally accepted that the hemorrhage risk of brain AVMs in HHT patients does not exceed



that of sporadic AVMs.<sup>15,23,24,32</sup> In both groups, hemorrhage was not a common mode of presentation in the patients. However, most lesions were symptomatic in group 1 (headache and/or focal neurological deficit). Although headaches are common in patients with AVMs, it is difficult to attribute solitary headaches to nonruptured AVMs.<sup>15,19,20,33-35</sup> This can be more problematic when an HHT patient with multiple AVMs presents with headache. Nevertheless, as one of the common presentations of cerebral AVMs in undiagnosed HHT patients, headaches may prompt a neurological workup and lead to diagnosis of AVMs.

#### Radiological Features

The 2 groups were similar regarding the radiological grades of the lesions. The frontal lobe harbored most AVMs in both groups. However, parietal lobe lesions were more frequently encountered in the surgically treated group, whereas occipital lobe lesions were more commonly found in the nonsurgically treated group. The higher frequency of symptomatic lesions in frontal and parietal lobes of group 1 patients might have lowered the threshold for surgical resection. On the other hand, higher frequency of lesions of the occipital lobe as well as lack of symptoms in most frontal lobe lesions (83%) of group 2 patients might have increased the threshold of decision to operate in the nonsurgically treated group.

#### Clinical Outcome

Long-term clinical outcomes between the surgical and nonsurgical groups were not significantly different. Although both

groups had a favorable functional status at long-term follow-up (median mRS score 1), the nonsurgical group suffered from worsening functional status at a rate of almost 1.5× the surgically treated group (Figure 3). This finding is emphasized by the longer duration of follow-up in group 1 (see below). This is not in concordance with the results of the ARUBA trial, which showed a relatively unfavorable outcome for surgically treated sporadic AVMs compared to observation. However, several subsequent studies showed a benefit from operating sporadic brain AVMs,<sup>36-39</sup> and our study now shows a benefit from operating HHT brain AVMs. Therefore, surgery remains a viable option for brain AVMs in HHT patients, protecting them from the risk of future hemorrhage with minimal associated surgical morbidity.

We acknowledge the selection bias in the current series, with symptomatic lesions easily selected for surgical resection, and observation more readily selected for asymptomatic AVMs (the patient groups are heterogeneous). It is also important to note that different follow-up periods might have affected our results. As mentioned, the follow-up duration for the surgically treated group was almost twice that of the nonsurgically treated group. Because the cumulative risk of hemorrhage in nonruptured AVMs is lower with a shorter follow-up, the probability of failing to detect a significant difference between long-term outcomes of the 2 groups should not be underestimated. In other words, if the nonsurgically treated group was followed for a longer period, declining outcomes might have been detected. This fact favors our suggestion for the surgical treatment of these lesions. Another important bias to consider is the survivor bias. While some centers

**TABLE 4. Clinical and Radiological Features of Individual Patients in Group 2 (Nonsurgically Treated) Patients and Their Initial and Long-Term Functional Status**

Patient no.	Age at diagnosis (years), sex	Symptoms	Lesion location	Lesion grade		mRS score at diagnosis	Latest follow-up mRS score	Adjuvant therapy
				SM	LY			
1	43, M	Asymptomatic	R Frontal	1	4	0	1	–
2	38, M	Asymptomatic	R Occipital	1	3	2	1	RS
3	64, F	Asymptomatic	R Occipital	2	4	1	1	–
4	72, M	Asymptomatic	L Frontal	1	4	0	2	–
5	0.6, M	ICH, Seizure	Thalamus	4	2	0	2	E
6	53, M	Asymptomatic	L Occipital	2	4	0	1	–
7	45, F	Asymptomatic	L Frontal	1	4	1	2	–
8	23, F	Asymptomatic	R Parietal	1	3	1	3	–
9	40, F	Asymptomatic	R Temporal	1	4	0	0	RS
10	52, M	Asymptomatic	L Frontal	1	4	0	0	RS
11	50, F	Headache, Hemiparesis	L Frontal	2	3	0	1	RS
12	55, F	Asymptomatic	L Frontal	1	4	0	0	–
13	9, M	Asymptomatic	L Frontal	1	2	1	1	RS, E
14	7, M	Asymptomatic	R Temporal	2	2	2	2	E
15	48, F	Asymptomatic	L Frontal	2	4	2	2	RS
16	21, F	Asymptomatic	L Frontal	3	3	0	1	RS
17	18, M	Asymptomatic	L Frontal	1	3	1	1	–
18	39, F	Asymptomatic	L Parietal	1	3	1	1	–
19	52, M	Hemiparesis	L Occipital	1	5	1	1	–
			R Occipital	1	5			–
20	57, F	Headache, Seizure	R Frontal	1	4	1	2	–
			R Occipital	1	4			–
21	23, F	Headache, Seizure	R Frontal	2	3	2	1	–
			R Frontal	2	3			–
			L Frontal	1	3			–
			L Frontal	1	3			–
			Cerebellum	1	3			–
			L Occipital	2	3			–
22	14, F	Asymptomatic	R Frontal	2	2	1	1	–
			R Frontal	1	2			–
			R Frontal	1	2			–
			Cerebellum	1	2			–
			Cerebellum	1	2			–

M, male; F, female; R, right; L, left; E, embolization; RS, radiosurgery.

may be reluctant to recruit deceased HHT patients, which might influence results, BVMC centers are encouraged to recruit all of their patients (current and previous) with brain VM history, even if deceased. Therefore, such bias may have had little effect on our results.

### The Dilemma of Decision to Operate

The management strategy of brain AVMs in HHT patients is controversial. Due to the rarity of HHT, landmark previous studies such as the ARUBA trial did not include HHT patients.<sup>37-41</sup> This fact, along with the unknown natural history of the disease, further adds to the complexity of developing a

treatment algorithm of brain AVMs in HHT patients. Several factors need to be considered when deciding to treat a brain AVM in these patients. First, the spontaneous hemorrhage risk of these lesions (on a per-lesion basis) seems to be lower, on average, than sporadic AVMs.<sup>15,23,24,33-35</sup> Second, the outcome of hemorrhage from HHT-related AVMs is reported to be relatively favorable compared to sporadic AVMs.<sup>19,24</sup> Third, multiplicity is very common in brain VMs of HHT patients, which lowers the likelihood of achieving curative resection or obliteration of all lesions with surgery. Fourth, there have been rare reports of spontaneous regression of brain VMs in HHT.<sup>25,28,29</sup> Also, a recent study has shown that bleeding in HHT-related brain AVMs



**TABLE 5. Previous Reports of Surgical Treatment of Brain Arteriovenous Malformations in HHT Patients**

Study (year)	Patient	Lesion location (SM grade)	Presentation	Early outcome	Late outcome
Kikuchi et al (1994) <sup>13</sup>	2-yr-old girl	Left parietal AVM (II)	ICH	Uneventful	Not reported
Du et al (2007) <sup>25</sup>	26-d-old	Left parasagittal parietal AVM (III)	ICH	Immediate hemiparesis	Completely resolved after 4 mo
Yang et al (2016) <sup>24</sup>	19-yr-old male	Right temporal (I)	None	No residual neurological deficit	n/s
	n/s	Left frontal (I)	n/s	No residual neurological deficit	n/s

n/s, not specified.

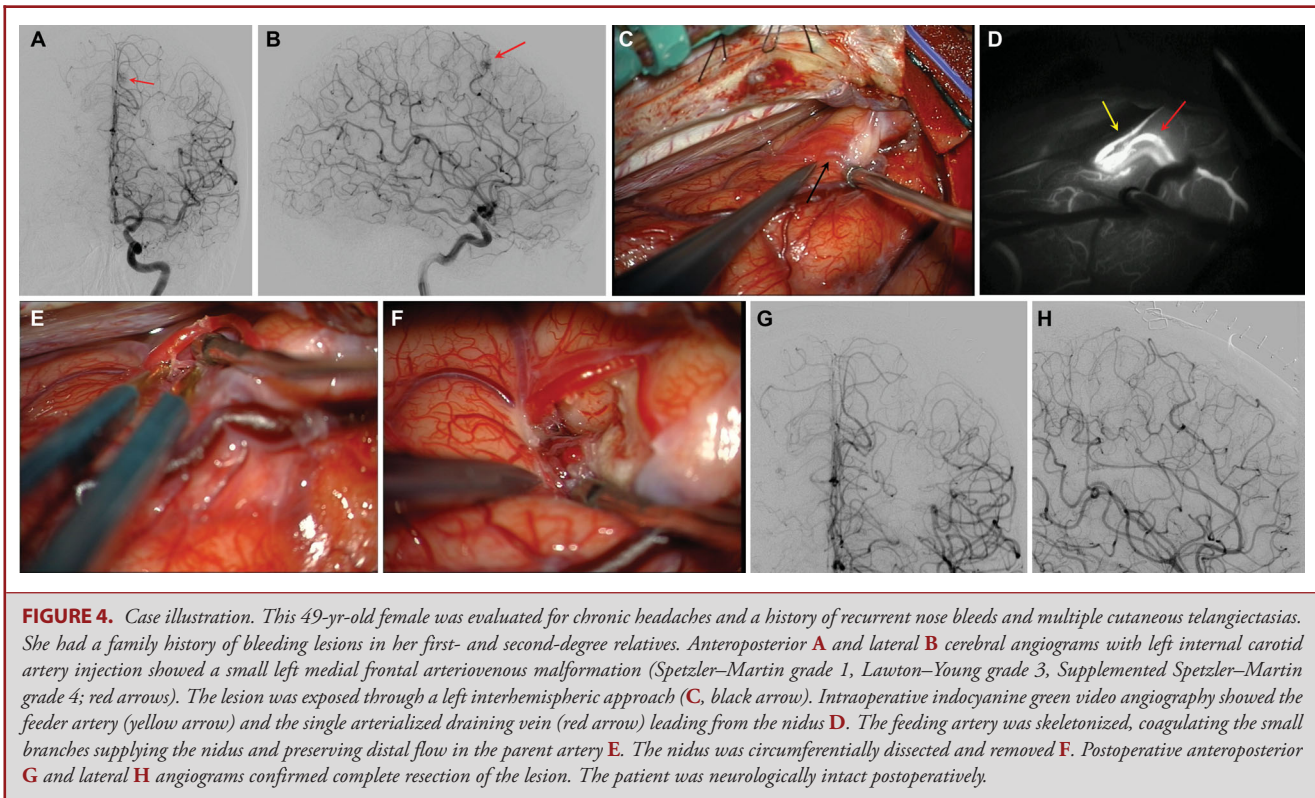
is associated with an increased risk of future hemorrhage.<sup>23</sup> These factors make patient management more challenging than with sporadic AVM with regard to the decision to intervene, and with which treatment modality. These factors lead some clinicians to favor conservative observation for these HHT-brain AVMs instead of active intervention treatment. In fact, the same strategy seems to prevail in BVMC centers, as the average surgery rate for HHT-related brain AVMs was low (16%).

On the other hand, risk of hemorrhage in critical regions of the brain along with the low-complication profile of treatment modalities favor aggressive treatment for these lesions. In addition, our consortium has previously demonstrated higher risk for intracranial hemorrhage amongst HHT patients with previous AVM rupture.<sup>23</sup> Although radiosurgery is a promising method for treatment, especially for small lesions that are multiple and far apart (as occurs frequently in HHT patients), the latency period after radiosurgery and lower obliteration rates than surgical extirpation favor a surgical strategy when curative resection of lesions is possible.<sup>42-46</sup> Embolization therapy is usually used as an adjunct for definitive surgical treatment of an AVM. Although the obliteration rate for brain AVMs after embolization treatment is low with a high rate of recurrence, small lesions such as those seen in HHT may appear favorable for endovascular treatment.<sup>47,48</sup> However, small feeding artery size and superficial location of many HHT-related AVMs can also make embolization more challenging than surgery or radiosurgery for such lesions. In the current series, embolization was primarily used as a preoperative adjunct to facilitate surgical resection (5 of 7 patients undergoing embolization). In the remaining 2 patients, embolization elected as the definitive treatment failed to obliterate the lesion, and completion surgery was undertaken. This is consistent with the results of embolization in sporadic AVMs<sup>48</sup> and supports multimodality treatment of AVMs using a multidisciplinary team approach.<sup>49,50</sup>

The results of our study show a low risk and favorable long-term outcome for surgical resection of brain AVMs in HHT

patients. Compared to observation, surgery remains a viable option for selected brain AVMs in HHT patients, protecting them from the risk of future hemorrhage with minimal associated surgical morbidity. Previous reports of surgical results for AVMs (although in very limited numbers) in HHT patients are also favorable (Table 5).<sup>13,24,25</sup> Compared to radiosurgery and embolization therapy, surgery confers immediate and durable cure without a latency period and, thus, provides the most definitive extirpation of the lesion. Studies show that, when possible, surgical resection should be considered in low-grade AVMs.<sup>40,41,51</sup> This recommendation may be applied to HHT-related AVMs that frequently have low SM and Supp-SM grades (ie, they are small, superficial, compact, and have a single feeder), which may translate to a less challenging surgical resection. However, it is important to note that even though only 2 patients were worse as a result of treatment (early postoperative functional status), not all low SM/Supp-SM grade lesions had a favorable long-term postoperative outcome in our study (90% low SM grade lesions vs 74% favorable outcome). It is also important to note that the small AVMs seen in HHT patients can be more difficult to identify than sporadic AVMs seen in other patients, although intraoperative navigation with frameless stereotactic guidance and intraoperative videoangiography with fluorescent dyes like indocyanine green dye (Figure 4) can help localize the AVM, as can anatomic clues like an arterialized cortical vein. Therefore, our conclusion on the relative safety of surgical intervention needs to be cautiously interpreted, and an individualized treatment strategy is essential for every patient. Further delineation of lesion characteristics and predictors of surgical outcome is necessary to help guide decisions on surgical treatment.

The decision to proceed with surgical resection of a symptomatic AVM causing neurological deficit (eg, seizure, hemiparesis) may be more straightforward. However, in asymptomatic cases or cases in which the only presenting symptom is headache, it is even more difficult to decide for surgery or



**FIGURE 4.** Case illustration. This 49-yr-old female was evaluated for chronic headaches and a history of recurrent nose bleeds and multiple cutaneous telangiectasias. She had a family history of bleeding lesions in her first- and second-degree relatives. Anteroposterior **A** and lateral **B** cerebral angiograms with left internal carotid artery injection showed a small left medial frontal arteriovenous malformation (Spetzler–Martin grade 1, Lawton–Young grade 3, Supplemented Spetzler–Martin grade 4; red arrows). The lesion was exposed through a left interhemispheric approach (**C**, black arrow). Intraoperative indocyanine green video angiography showed the feeder artery (yellow arrow) and the single arterialized draining vein (red arrow) leading from the nidus **D**. The feeding artery was skeletonized, coagulating the small branches supplying the nidus and preserving distal flow in the parent artery **E**. The nidus was circumferentially dissected and removed **F**. Postoperative anteroposterior **G** and lateral **H** angiograms confirmed complete resection of the lesion. The patient was neurologically intact postoperatively.

other interventions. Again, with the current level of evidence, no definitive treatment paradigm can be suggested for these lesions, and the best individualized treatment must be proposed to patients by a multidisciplinary team that considers all aspects of the disease and its neurological impact, as well as the particular expertise and experience of the team.

### Preoperative Considerations

It is important to note several points before proceeding with surgical treatment of an HHT-related brain AVM. Screening for pulmonary AVMs is recommended in all HHT patients, followed by preventative embolization of significant AVMs and lifelong pulmonary AVM precautions.<sup>27</sup> This screening and treatment should be performed prior to cranial surgery, when feasible, to reduce perioperative risks (intrapulmonary hemorrhage, stroke, brain abscess) from pulmonary AVMs. In urgent cases, with unknown pulmonary AVM status, pulmonary AVMs should be presumed present, and pulmonary AVM precautions should be followed, including antibiotic prophylaxis and the use of intravenous air filters, until screening can be completed postoperatively.

Patients with brain AVM may have an unrecognized HHT diagnosis, as the disease remains underdiagnosed. Multiplicity of brain AVMs is a strong predictor for the diagnosis of HHT.<sup>9,52</sup> In addition, a personal and/or family history of epistaxis and the

presence of mucocutaneous telangiectasias should be sought as clues towards the diagnosis of HHT. If the diagnosis of HHT is suspected, family members need to be screened to rule out HHT.

### Limitations

The major limitation of the current study is the small sample size. Although this consortium study involved multiple centers, the total number of HHT patients is a small fraction of those with sporadic brain AVMs. The BVMC continues to record all deaths, including those caused by surgery or its complications, and poor outcomes. Although we did not see any surgical mortality in the current reported series, exclusion of 17 patients with incomplete clinical data is a possible source of selection bias. However, only 2 of these 17 patients underwent surgery, and they did not show any functional decline in long-term follow-up. On the other hand, the heterogeneous nature of the 2 groups of patients causes their comparison to be less reliable. Presentation mode did not follow a similar pattern between groups. Some of the patients in this series received radiosurgery and/or embolization before surgery, making the patient population nonhomogeneous. Preoperative embolization and/or radiosurgical treatment of a brain AVM may affect the difficulty of its surgical resection. Embolization might reduce the intraoperative bleeding and improve surgical outcomes, while radiosurgical treatment may shrink the AVM and facilitate resection. Lack of a sizable control

group who did not undergo any treatment modality limits the generalizability of our results (our series had only 13 patients with these features). Without such a control group, it is difficult to reach the statistical power to generate firm guidelines.

The current study also has the weaknesses of any retrospective review. However, it is the largest series of its kind, and the good outcomes found in group 1 support the operative management of HHT-related brain AVMs. Future studies with larger patient populations, including larger numbers of observed patients, will be possible as the BVMC increases its enrollment of patients, which may better delineate the role of different treatment modalities in HHT-related brain AVMs.

## CONCLUSION

HHT-related brain AVMs are rare lesions with a genetic basis, a different radiological profile from sporadic AVMs, and a more benign natural history. A comprehensive treatment paradigm for brain AVMs in HHT patients has not been established. This multicenter study shows that HHT patients with brain AVMs treated surgically appear to have good long-term functional outcomes. This surgical cohort, although small, is the largest reported to date, and it is reasonable to consider surgical resection as a therapeutic option in the context of an individualized, multi-disciplinary team approach for HHT patients with brain AVMs. The decisions regarding management of AVMs in HHT patients presently parallel those for sporadic AVMs, but future research should identify determinants of outcomes in HHT-related brain AVMs.

## Disclosures

Ali Tayebi Meybodi was supported by a fellowship training grant from the Brain Vascular Malformation Consortium (BVMC). The BVMC is part of the Rare Diseases Clinical Research Network (RDCRN) and is supported through collaboration between the National Institutes of Health Office of Rare Diseases Research at the National Center for Advancing Translational Science, and the National Institute of Neurological Disorders and Stroke (NIH/NINDS grant: U54 NS065705). The authors have no personal, financial, or institutional interest in any of the drugs, materials, or devices described in this article.

## REFERENCES

- Guttmacher AE, Marchuk DA, White RI. Hereditary hemorrhagic telangiectasia. *N Engl J Med.* 1995;333(14):918-924.
- Dakeishi M, Shioya T, Wada Y, et al. Genetic epidemiology of hereditary hemorrhagic telangiectasia in a local community in the northern part of Japan. *Hum Mutat.* 2002;19(2):140-148.
- Kjeldsen AD, Vase P, Green A. Hereditary haemorrhagic telangiectasia: a population-based study of prevalence and mortality in Danish patients. *J Intern Med.* 1999;245(1):31-39.
- Bideau A, Brunet G, Heyer E, Plauchu H, Robert JM. An abnormal concentration of cases of Rendu-Osler disease in the Valsérine valley of the French Jura: a genealogical and demographic study. *Ann Hum Biol.* 1992;19(3):233-247.
- Fuchizaki U, Miyamori H, Kitagawa S, Kaneko S, Kobayashi K. Hereditary haemorrhagic telangiectasia (Rendu-Osler-Weber disease). *Lancet.* 2003;362(9394):1490-1494.
- Salara M, Taylor J, Bogwitz M, Winship I. Hereditary haemorrhagic telangiectasia, an Australian cohort: clinical and investigative features. *Intern Med J.* 2014;44(7):639-644.
- Hodgson CH, Burchell HB, Good CA, Clagett OT. Hereditary hemorrhagic telangiectasia and pulmonary arteriovenous fistula: survey of a large family. *N Engl J Med.* 1959;261:625-636.
- Boczko ML. Neurological implications of hereditary hemorrhagic telangiectasia. *J Nerv Ment Dis.* 1964;139:525-536.
- Putman CM, Chaloupka JC, Fulbright RK, Awad IA, White RI, Fayad PB. Exceptional multiplicity of cerebral arteriovenous malformations associated with hereditary hemorrhagic telangiectasia (Osler-Weber-Rendu syndrome). *AJNR Am J Neuroradiol.* 1996;17(9):1733-1742.
- Román G, Fisher M, Perl DP, Poser CM. Neurological manifestations of hereditary hemorrhagic telangiectasia (Rendu-Osler-Weber disease): report of 2 cases and review of the literature. *Ann Neurol.* 1978;4(2):130-144.
- White RI, Lynch-Nyhan A, Terry P, et al. Pulmonary arteriovenous malformations: techniques and long-term outcome of embolotherapy. *Radiology.* 1988;169(3):663-669.
- Fulbright RK, Chaloupka JC, Putman CM, et al. MR of hereditary hemorrhagic telangiectasia: prevalence and spectrum of cerebrovascular malformations. *AJNR Am J Neuroradiol.* 1998;19(3):477-484.
- Kikuchi K, Kowada M, Sasajima H. Vascular malformations of the brain in hereditary hemorrhagic telangiectasia (Rendu-Osler-Weber disease). *Surg Neurol.* 1994;41(5):374-380.
- Haitjema T, Disch F, Overtoom TT, Westermann CJ, Lammers JW. Screening family members of patients with hereditary hemorrhagic telangiectasia. *Am J Med.* 1995;99(5):519-524.
- Willemsse RB, Mager JJ, Westermann CJ, Overtoom TT, Mauser H, Wolbers JG. Bleeding risk of cerebrovascular malformations in hereditary hemorrhagic telangiectasia. *J Neurosurg.* 2000;92(5):779-784.
- Matsubara S, Mandzia JL, ter Brugge K, Willinsky RA, Faughnan ME, Manzia JL. Angiographic and clinical characteristics of patients with cerebral arteriovenous malformations associated with hereditary hemorrhagic telangiectasia. *AJNR Am J Neuroradiol.* 2000;21(6):1016-1020.
- Krings T, Ozanne A, Chng SM, Alvarez H, Rodesch G, Lasjaunias PL. Neurovascular phenotypes in hereditary haemorrhagic telangiectasia patients according to age. Review of 50 consecutive patients aged 1 day-60 years. *Neuroradiology.* 2005;47(10):711-720.
- Krings T, Kim H, Power S, et al. Neurovascular manifestations in hereditary hemorrhagic telangiectasia: imaging features and genotype-phenotype correlations. *AJNR Am J Neuroradiol.* 2015;36(5):863-870.
- Maher CO, Piepgras DG, Brown RD, Friedman JA, Pollock BE. Cerebrovascular manifestations in 321 cases of hereditary hemorrhagic telangiectasia. *Stroke.* 2001;32(4):877-882.
- Woodall MN, McGettigan M, Figueroa R, Gossage JR, Alleyne CH. Cerebral vascular malformations in hereditary hemorrhagic telangiectasia. *J Neurosurg.* 2014;120(1):87-92.
- Maarouf M, Runge M, Kocher M, Zähringer M, Treuer H, Sturm V. Radio-surgery for cerebral arteriovenous malformations in hereditary hemorrhagic telangiectasia. *Neurology.* 2004;63(2):367-369.
- Willinsky RA, Lasjaunias P, Terbrugge K, Burrows P. Multiple cerebral arteriovenous malformations (AVMs). Review of our experience from 203 patients with cerebral vascular lesions. *Neuroradiology.* 1990;32(3):207-210.
- Kim H, Nelson J, Krings T, et al. Hemorrhage rates from brain arteriovenous malformation in patients with hereditary hemorrhagic telangiectasia. *Stroke.* 2015;46(5):1362-1364.
- Yang W, Liu A, Hung A, et al. Lower risk of intracranial arteriovenous malformation hemorrhage in patients with hereditary hemorrhagic telangiectasia. *Neurosurgery.* 2016;78(5):684-693.
- Du R, Hashimoto T, Tihan T, Young WL, Perry V, Lawton MT. Growth and regression of arteriovenous malformations in a patient with hereditary hemorrhagic telangiectasia. Case report. *J Neurosurg.* 2007;106(3):470-477.
- Kuo YH, Santoreneos S, Roos D, Brophy BP. Treatment of multiple arteriovenous malformations in pediatric patients with hereditary hemorrhagic telangiectasia and spontaneous hemorrhage. Report of two cases. *J Neurosurg.* 2007;107(6 suppl):489-494.
- Faughnan ME, Palda VA, Garcia-Tsao G, et al. International guidelines for the diagnosis and management of hereditary haemorrhagic telangiectasia. *J Med Genet.* 2011;48(2):73-87.
- Leung KM, Agid R, ter Brugge K. Spontaneous regression of a cerebral arteriovenous malformation in a child with hereditary hemorrhagic telangiectasia. Case report. *J Neurosurg.* 2006;105(5 suppl):428-431.



29. Cloft HJ. Spontaneous regression of cerebral arteriovenous malformation in hereditary hemorrhagic telangiectasia. *AJNR Am J Neuroradiol.* 2002;23(6):1049-1050.
30. Shovlin CL, Guttmacher AE, Buscarini E, et al. Diagnostic criteria for hereditary hemorrhagic telangiectasia (Rendu-Osler-Weber syndrome). *Am J Med Genet.* 2000;91(1):66-67.
31. Kim H, Abula AA, Nelson J, et al. Validation of the supplemented Spetzler-Martin grading system for brain arteriovenous malformations in a multicenter cohort of 1009 surgical patients. *Neurosurgery.* 2015;76(1):25-31; discussion 31-22; quiz 32-23.
32. Easey AJ, Wallace GM, Hughes JM, Jackson JE, Taylor WJ, Shovlin CL. Should asymptomatic patients with hereditary haemorrhagic telangiectasia (HHT) be screened for cerebral vascular malformations? Data from 22,061 years of HHT patient life. *J Neurol Neurosurg Psychiatry.* 2003;74(6):743-748.
33. Hernesniemi JA, Dashti R, Juvela S, Väärt K, Niemelä M, Laakso A. Natural history of brain arteriovenous malformations: a long-term follow-up study of risk of hemorrhage in 238 patients. *Neurosurgery.* 2008;63(5):823-829; discussion 829-831.
34. Mast H, Young WL, Koennecke HC, et al. Risk of spontaneous haemorrhage after diagnosis of cerebral arteriovenous malformation. *Lancet.* 1997;350(9084):1065-1068.
35. Abecassis IJ, Xu DS, Batjer HH, Bendok BR. Natural history of brain arteriovenous malformations: a systematic review. *Neurosurg Focus.* 2014;37(3):E7.
36. Bervini D, Morgan MK, Ritsen EA, Heller G. Surgery for unruptured arteriovenous malformations of the brain is better than conservative management for selected cases: a prospective cohort study. *J Neurosurg.* 2014;121(4):878-890.
37. Abula AA, Nelson J, Kim H, Hess CP, Tihan T, Lawton MT. Silent arteriovenous malformation hemorrhage and the recognition of "unruptured" arteriovenous malformation patients who benefit from surgical intervention. *Neurosurgery.* 2015;76(5):592-600; discussion 600.
38. Rutledge WC, Abula AA, Nelson J, Halbach VV, Kim H, Lawton MT. Treatment and outcomes of ARUBA-eligible patients with unruptured brain arteriovenous malformations at a single institution. *Neurosurg Focus.* 2014;37(3):E8.
39. Mohr JP, Parides MK, Stapf C, et al. Medical management with or without interventional therapy for unruptured brain arteriovenous malformations (ARUBA): a multicentre, non-blinded, randomised trial. *Lancet.* 2014;383(9917):614-621.
40. Nerva JD, Mantovani A, Barber J, et al. Treatment outcomes of unruptured arteriovenous malformations with a subgroup analysis of ARUBA (A Randomized Trial of Unruptured Brain Arteriovenous Malformations)-eligible patients. *Neurosurgery.* 2015;76(5):563-570; discussion 570; quiz 570.
41. Potts MB, Lau D, Abula AA, et al. Current surgical results with low-grade brain arteriovenous malformations. *J Neurosurg.* 2015;122(4):912-920.
42. van Beijnum J, van der Worp HB, Buis DR, et al. Treatment of brain arteriovenous malformations: a systematic review and meta-analysis. *JAMA.* 2011;306(18):2011-2019.
43. Ding D, Yen CP, Starke RM, Xu Z, Sheehan JP. Radiosurgery for ruptured intracranial arteriovenous malformations. *J Neurosurg.* 2014;121(2):470-481.
44. Pollock BE, Lunsford LD, Kondziolka D, Maitz A, Flickinger JC. Patient outcomes after stereotactic radiosurgery for "operable" arteriovenous malformations. *Neurosurgery.* 1994;35(1):1-7; discussion 7-8.
45. Wang YC, Huang YC, Chen HC, et al. Linear accelerator stereotactic radiosurgery in the management of intracranial arteriovenous malformations: long-term outcome. *Cerebrovasc Dis.* 2014;37(5):342-349.
46. Kano H, Lunsford LD, Flickinger JC, et al. Stereotactic radiosurgery for arteriovenous malformations, Part 1: management of Spetzler-Martin Grade I and II arteriovenous malformations. *J Neurosurg.* 2012;116(1):11-20.
47. Yu SC, Chan MS, Lam JM, Tam PH, Poon WS. Complete obliteration of intracranial arteriovenous malformation with endovascular cyanoacrylate embolization: initial success and rate of permanent cure. *AJNR Am J Neuroradiol.* 2004;25(7):1139-1143.
48. Reig AS, Rajaram R, Simon S, Mericle RA. Complete angiographic obliteration of intracranial AVMs with endovascular embolization: incomplete embolic nidus opacification is associated with AVM recurrence. *J Neurointerv Surg.* 2010;2(3):202-207.
49. Pandey P, Marks MP, Harraher CD, et al. Multimodality management of Spetzler-Martin Grade III arteriovenous malformations. *J Neurosurg.* 2012;116(6):1279-1288.
50. Nataraj A, Mohamed MB, Gholkar A, et al. Multimodality treatment of cerebral arteriovenous malformations. *World Neurosurg.* 2014;82(1-2):149-159.
51. Alén JF, Lagares A, Paredes I, et al. Cerebral microarteriovenous malformations: a series of 28 cases. *J Neurosurg.* 2013;119(3):594-602.
52. Bharatha A, Faughnan ME, Kim H, et al. Brain arteriovenous malformation multiplicity predicts the diagnosis of hereditary hemorrhagic telangiectasia: quantitative assessment. *Stroke.* 2012;43(1):72-78.

---

**Neurosurgery Speaks!** Audio abstracts available for this article at [www.neurosurgery-online.com](http://www.neurosurgery-online.com).

---

## Acknowledgments

The Brain Vascular Malformation Consortium HHT Investigator Group were nonauthor contributors, including Murali Chakinala, Marianne Clancy, Marie E Faughnan, James R Gossage, Katharine Henderson, Steven Hetts, Vivek Iyer, Raj Kasthuri, Helen Kim, Timo Krings, Michael T Lawton, Doris Lin, Johannes Jurgen Mager, Charles E McCulloch, Justin McWilliams, Jamie McDonald, Ludmila Pawlikowska, Jeffrey Pollak, Felix Ratjen, Karen Swanson, Karel terBrugge, Dilini Vethanayagam, Andrew White, Robert I White Jr, Pearce Wilcox.

## COMMENTS

**P**atients with arteriovenous malformations in the setting of Hereditary Hemorrhagic Telangiectasia present a unique dilemma for neurosurgeons. Most of these patients present after routine screening due to familial inheritance of HHT, therefore most AVMs are asymptomatic and without hemorrhage. Second, HHT patients can harbor multiple vascular malformations, and can include AVMs, arteriovenous fistulas, and capillary telangiectasias. Third, the natural history of HHT related AVMs appears to be slightly different than sporadic AVMs, with HHT patients having a lower initial hemorrhage rate but a higher rate of rebleeding, and some HHT related AVMs demonstrating growth followed by sporadic regression. And finally, previous studies have either not differentiated between sporadic and HHT related AVMs, or have entirely excluded HHT related AVMs (including the ARUBA trial). These factors complicate the decision to surgically intervene HHT patients with AVMs.

The authors of this manuscript shed light on outcome following surgical resection of HHT related AVMs. By pooling data from multiple centers, they are able to effectively characterize and report the outcomes on 20 surgically resected AVMs in 19 HHT patients. Both short and long-term outcome are reported, with a mean of 9.6 years. Modified Rankin Score at long-term follow-up was good (mRS scores 0 and 1) in 74% of patients treated with surgical resection.

These results indicate that surgical treatment is a reasonable option for these lesions. However, a definitive treatment paradigm cannot be formulated for a number of reasons, including the lack of a control group for comparison with medical observation, a small sample size, and the retrospective nature of the report. Despite these limitations, this report expands upon previous reports examining treatment of AVMs in HHT patients, and indicates that surgical intervention is a reasonable option.

**Eric J. Arias**  
**Ralph G. Dacey Jr.**  
*St. Louis, Missouri*

**P**atients with hereditary hemorrhagic telangiectasia (HHT) have a higher prevalence of intracranial arteriovenous malformations (AVMs). Whereas in the general population the prevalence of intracranial AVMs is approximately 0.2%,<sup>1</sup> the prevalence in HHT patients ranges between 5–23%, as cited in this article. AVMs in HHT patients tend to be smaller, be located in the cortex and have superficial drainage, and have multiple nodi. We and others have reported that HHT AVMs have a lower risk of hemorrhage.<sup>2</sup> Nevertheless incidental AVMs are often diagnosed in HHT patients as part of routine work-ups, and they are referred to us for possible treatment. The authors report a series of 19 patients from 8 different centers who underwent surgery for 20 AVMs. They compare them retrospectively to 20 other patients with 33 AVMs who were followed. Obviously, the outcomes of the 2 groups cannot be compared given the retrospective, observational structure of this report. The major message from this study is that surgical outcomes after resection of AVMs in HHT patients are similar to those of other patients with similar low-grade lesions. Given the rarity of HHT patients, this is helpful information.

**Rafael J. Tamargo**  
*Baltimore, Maryland*

- 
1. Weber F, Knopf H. Incidental findings in magnetic resonance imaging of the brains of healthy young men. *J Neurol Sci.* 2006;240:81-84.
  2. Yang W, Liu A, Hung AL, et al. Lower risk of intracranial arteriovenous malformation hemorrhage in patients with hereditary hemorrhagic telangiectasia. *Neurosurgery.* 2016;78(5):684-693.

**T**he authors are to be congratulated on this largest surgical series of the rare disease of Hereditary Hemorrhagic Telangiectasia (HHT). For someone like myself, who has participated in the management decisions of more than 1000 AVMs of all types, I feel singularly under-equipped to be confident of my “informed” recommendation with patients that are diagnosed with HHT. This study, only possible with the commitment of a consortium devoted to this disease, is a landmark with regards enhancing our knowledge of patients with brain AVM with HHT.

The authors note the decision making dilemma of an AVM type that untreated may be more benign (in terms of frequency and tendency to destructive hemorrhage) than sporadic AVM but with a risk of curative treatment that may also be, in general, safer than that for sporadic AVM. The low complication rate is notable.

An important point that the authors make is recognizing HHT at presentation or follow-up (in my experience, not all cases are diagnosed as HHT at the initial presentation) with evidence of mucocutaneous telangiectasia, nose bleeds, multiple brain AVM, a suggestion of a family history of any of the above, the presence of a small AVM remote from the site of hemorrhage, AVM and an associated brain abscess or any small-diffuse AVM (“smudge AVM” on DSA). This impacts on the recommendation for investigating both families as well as being vigilant for pulmonary arteriovenous shunts that may be the main life-threatening problem for the patient with the potential for brain abscess formation and pulmonary problems.

**Michael Morgan**  
*Sydney, Australia*

**T**his consortium presents a small retrospective series of patients with HHT who had identified AVMs of the brain and underwent surgical resection. The series is clearly highly selected, and gives no information about natural history. Nonetheless, the surgical results are as expected for a group of low grade Spetzler-Martin lesions. The useful message is that surgical treatment of patients with HHT is no more dangerous than in sporadic cases. Surgery continues to be an important treatment option for HHT patients as it is for all AVM patients. Each AVM patient needs to be evaluated on an individualized basis by an experienced team that can provide multi-modal therapy when appropriate, and consider conservative treatment in patients where the risks of treatment exceed natural history risks.

**Robert A. Solomon**  
*New York, New York*

**A**lthough a small series, there is little in our literature on the subject of AVMs in this group of patients. The natural history and response to treatment may be different from AVMs in the general population. It may well be that AVMs associated with HHT have a more benign natural history but may also be more straightforward in managing by surgical resection. By using a multi-institutional consortium, the authors have shed further insight into the management of this rare and often challenging issue.

**Daniel L. Barrow**  
*Atlanta, Georgia*