

Original research

The quantitative measurements of foveal avascular zone using optical coherence tomography angiography in normal volunteers

Fariba Ghassemi^{a,b,*}, Reza Mirshahi^a, Fatemeh Bazvand^a, Kaveh Fadakar^a, Houshang Faghihi^a, Siamak Sabour^c

^a Eye Research Center, Farabi Eye Hospital, Tehran University of Medical Sciences, Tehran, Iran

^b Retina & Vitreous Service, Farabi Eye Hospital, Tehran University of Medical Sciences, Tehran, Iran

^c Safety Promotion and Injury Prevention Research Center, Department of Clinical Epidemiology, Shahid Beheshti University of Medical Sciences, Tehran, Iran

Received 7 February 2017; revised 7 May 2017; accepted 13 June 2017

Available online 29 July 2017

Abstract

Purpose: To provide normative data of foveal avascular zone (FAZ) and thickness.

Methods: In this cross-sectional study both eyes of each normal subject were scanned with optical coherence tomography angiography (OCTA) for foveal superficial and deep avascular zone (FAZ) and central foveal thickness (CFT) and parafoveal thickness (PFT).

Results: Out of a total of 224 eyes of 112 volunteers with a mean age of 37.03 (12–67) years, the mean superficial FAZ area was 0.27 mm², and deep FAZ area was 0.35 mm² ($P < 0.001$), with no difference between both eyes. Females had a larger superficial (0.32 ± 0.11 mm² versus 0.23 ± 0.09 mm²) and deep FAZ (0.40 ± 0.14 mm² versus 0.31 ± 0.10 mm²) ($P < 0.001$) than males. By multivariate linear regression analysis, in normal eyes, superficial FAZ area varied significantly with the gender, CFT, and deep FAZ. Deep FAZ varied with the gender and CFT.

Conclusion: The gender and CFT influence the size of normal superficial and deep FAZ of capillary network.

Copyright © 2017, Iranian Society of Ophthalmology. Production and hosting by Elsevier B.V. This is an open access article under the CC BY-NC-ND license (<http://creativecommons.org/licenses/by-nc-nd/4.0/>).

Keywords: FAZ; Fovea; Foveal avascular zone; Foveal thickness; Normal eye; Optical coherence tomography angiography

Introduction

Foveal avascular zone (FAZ) is a highly specialized region of the human retina for the accurate vision.^{1,2} Many imaging modalities have highlighted the variability in FAZ shape and size in normal human eyes.^{3–15} The changes of shape and size of the FAZ in some diseases, causing the loss of vision, is already documented.^{16,17}

Introduction of fluorescein angiography (FA) to the ophthalmology as a simple invasive technique facilitated the

study of ocular vascular system abnormalities and the FAZ in numerous retinovascular diseases.^{3,18,19}

Recent advances in optical coherence tomography (OCT) technology affords a non-invasive optical biopsy, in particular by the increased scanning speed as well as progress in image-processing algorithms, have allowed the development of OCT angiography (OCTA).^{20–26}

Recently, a few studies have described FAZ sizes in normal population measured with OCTA.^{4,5,10,11,16,17,27,28} To understand the effects of retinal diseases on the FAZ, it is essential first to determine the variation of FAZ size and shape and its association with demographics and ocular factors among healthy individuals.²⁹

In this study, we aimed to provide a normative data from a sample of the Iranian population for normal superficial and deep capillary network free zone (FAZ), using XR Avanti AngioVue OCTA in healthy subjects and to ascertain any

* Corresponding author. Eye Research Center, Farabi Eye Hospital, Qazvin Square, Tehran, Iran.

E-mail addresses: ghasemi_f@sina.tums.ac.ir, fariba.ghassemi@gmail.com (F. Ghassemi).

Peer review under responsibility of the Iranian Society of Ophthalmology.

correlation of FAZ with other measured ocular and demographic factors.

Methods

The Institutional Review Board of Farabi Multi-Specialty Eye Hospital approved the research protocol, and informed consent was obtained from the patients and parents or legal guardians of children. The research conformed to the tenets of the Declaration of Helsinki. Both eyes of ocular and systemically healthy subjects were included. Inclusion criteria were best corrected visual acuity of 20/20 and refractive error between -3 and $+1$ diopter (D) spherical equivalent. Exclusion criteria were significant media opacity preventing high-quality imaging, motion and blinking artifact, and any ocular and systemic disease.

Two trained readers (F.G., F.B.) from Image Reading Center reviewed and graded all OCT images.

AngioVue retina imaging using optical coherence tomography angiography (OCTA; RTVue XR Avanti; Optovue, USA-pre-release version: 2016.1.0.23- beta) and the split-spectrum amplitude decorrelation angiography (SSADA) algorithm was performed.²² This instrument operated at 840-nm wavelength and performs 70,000 A-scans per second to acquire OCTA of two repeated horizontal and vertical B-scans of 3×3 mm (304×304 pixels) in the transverse dimension. Low quality scans (i.e., if the subject blinked or the scan had significant motion artifacts) were excluded and repeated until good quality scans were achieved. An internal fixation light was used to center the scanning area.

For all measurements, the automated segmentation with the preset settings for the superficial vascular network and deep vascular network was utilized. Hereby, the upper border of the superficial vascular network was defined as $3 \mu\text{m}$ below the

internal limiting membrane (ILM) and the lower border as $15 \mu\text{m}$ below the inner plexiform layer (IPL) and for the deep vascular network, as $15 \mu\text{m}$ – $71 \mu\text{m}$ below the IPL, respectively. FAZ area was measured in mm^2 . Briefly, a non-flow measurement on a superficial reference plane (superficial vascular network) of en-face projection was selected. The user manually fine-tuned the plane to maximize the visualization of the retinal capillary bed by changing the depth of the automatically segmented slab. Via clicking on the center of the FAZ, the software automatically calculated the area of non-perfusion (Fig. 1).²² The user manually fine-tuned the plane to maximize the visualization of the retinal capillary bed.

These thicknesses were measured in foveal and parafoveal area as a whole and selectively in superior, inferior, nasal, and temporal parafoveal sectors in macular region in superficial and deep capillary networks. In case of erroneous determination by the built-in software, manual correction was performed. The foveal region was outlined as a central circle with a 120-pixel (1.2 mm) diameter, and the parafoveal region was delineated as a ring, by 91 pixels wide, surrounding the foveal region.²⁸

Vertical cup/disc ratio was measured by clinical examination (Lens 90). The disc shaped was classified as round and oval shaped discs in clinical examination (more than 10% difference in vertical and horizontal diameters).

Two trained readers (F.G., F.B.) from our team reviewed and graded all OCT images with each other in each session. The results were the mean amount of values in the same session of reading. If there was any conflict of opinion, the third reader (H.F.) was involved. We categorized the ages of the candidates into 4 groups including: 30 years or less (41 cases), 31–40 years (37 cases), 41–50 years (20 cases), and older than 50 years (14 cases).

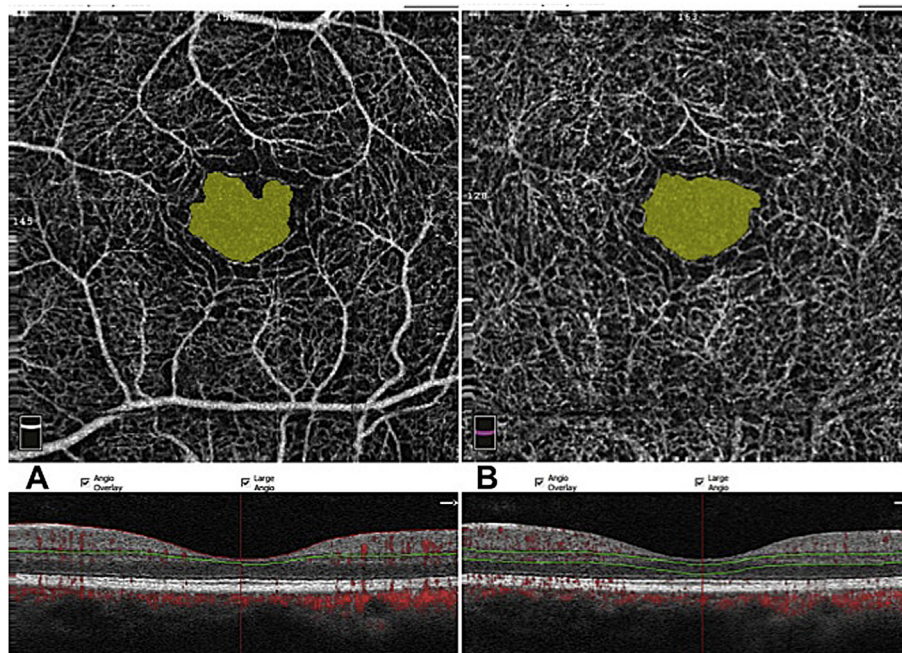


Fig. 1. Comparison of foveal avascular zone (FAZ) in the superficial and deep retinal capillary network (A) Superficial FAZ measured as area 0.29 mm^2 . (B) Deep FAZ (area 0.32 mm^2).

Statistical methods

All quantitative variables were reported as mean with standard deviation (SD) after confirming normality of distribution with the Kolmogorov-Smirnov test. All statistical analyses were performed using statistical software (SPSS software Version 21; SPSS, Inc., Chicago, IL, USA). Two-tailed, independent samples *t*-test was used to compare the FAZ areas with other two tailed variables as laterality and gender. Analysis of variance (ANOVA) was performed among the age groups. Multivariate linear regression analysis was used to determine the correlation between FAZ areas after adjusting for confounding factors including age, gender, and other correlated variables in partial *t*-test. In this study, collinearity for different variables was checked. *P* values less than 0.05 were considered statistically significant. Intraclass correlation coefficients (ICCs) were used to assess the intergrader agreement between the graders.

Results

Demographic data

A total of 224 eyes of 112 normal volunteer underwent FAZ area measurement. Mean age of participants was 37.03 ± 11.27 year (range, 12–67 years). The subjects included 59 (52.7%) male with the mean age of 34.98 ± 8.53 and 53 (47.3%) female with the mean age of 40.05 ± 13.87 ($P < 0.001$). The shapes of optic disc composed of 64 (40.5%) eyes with round and 94 (59.5%) eyes with oval forms. From the age groups, 41 cases (36.3%) were in the 30 years or less, 37 cases (33%) in 31–40 years, 20 cases (17.9%) in the 41–50 years, and 14 cases (12.5%) in more than 50 years group.

The mean \pm SD value of superficial and deep FAZ area were 0.27 ± 0.11 mm² and 0.35 ± 0.12 mm², respectively ($P < 0.001$). Central foveal thickness (CFT) was 247 ± 21.1 μ m and parafoveal thickness (PFT) was 317 ± 15.6 μ m. PFT in superior, temporal, inferior, and nasal quadrants were 321 ± 15.1 μ m, 307 ± 15.6 μ m, 319 ± 16.5 μ m and 319 ± 16.8 μ m, respectively (Table 1).

No correlation was found between superficial and deep FAZ area and the shape of the disc, and cup/disc ratio in the studied eyes. The areas of superficial and deep FAZ were highly correlated ($r = 0.82$, $P < 0.001$). No relation between the age and superficial FAZ area and deep FAZ area was found ($P > 0.05$) (Fig. 1). A correlation between gender and superficial FAZ ($r = 0.45$, $P < 0.001$), deep FAZ ($r = 0.33$, $P < 0.001$), and CFT ($r = -0.40$, $P < 0.001$) was detected. No significant difference was found between both eyes.

To remove the effect of bilaterality, one eye of each patient was selected sequentially, then all statistics were re-done. In this evaluation, only in the right eye, the difference between deep FAZ in males (9.14 ± 67.91 mm²) and females (0.39 ± 0.14 mm²) was not statistically significant ($P = 0.326$).

Superficial and deep capillary foveal avascular zone areas

The gender based amounts of superficial FAZ and deep FAZ areas in fovea are summarized in Table 1. The superficial FAZ was 0.27 ± 0.11 (range, 0.04–0.63) and deep FAZ was 0.35 ± 0.12 (range, 0.06–0.94). Comparing all eyes, the deep FAZ was significantly larger than the superficial FAZ (mean difference 0.08 mm², paired *t*-test, $P < 0.001$) (Fig. 1). These FAZ areas were similar in both eyes ($P > 0.05$). The FAZ areas were both not correlated with cup/disc ratio ($r = -0.03$, $P = 0.82$) and age ($r = -0.02$, $P = 0.85$) (Fig. 2).

Gender based foveal avascular zone areas and central foveal thickness and parafoveal thickness

The superficial and deep FAZ areas were larger in female volunteers than male (Table 1), and the results persist after adjusting for the age in multivariate linear regression analysis [Beta: 0.40, 95% confidence interval (CI): 0.05–0.13, $P < 0.001$ for superficial FAZ and Beta: 0.30, 95% CI: 0.03–0.13, $P = 0.002$ for deep FAZ]. Despite FAZ areas, the mean CFT and PFT are higher in males compared with females (Table 1). The

Table 1

Surface area of superficial and deep foveal avascular zone (FAZ), foveal and parafoveal thicknesses (PFTs), age and cup/disc ratio of normal right eyes.

FAZ area (mm ²)/foveal and parafoveal thicknesses (μ m) (Mean \pm SD) (ANOVA-Dunnett)	Overall (range) (N = 112)	Male (N = 59)	Female (N = 53)	<i>P</i> value
Surface area of superficial FAZ	0.22 ± 0.08 (0.04–0.63)	0.22 ± 0.08	0.31 ± 0.11	<0.001
Surface area of deep FAZ	0.31 ± 0.11 (0.06–0.94)	0.30 ± 0.10	0.39 ± 0.14	<0.001
Thickness of fovea	247.12 ± 21.19 (202–313)	255.54 ± 17.81	237.87 ± 21.56	<0.001
Thickness of parafoveal area	317.6 ± 15.63 (270–359)	322.64 ± 14.82	311.66 ± 13.56	<0.001
Thickness of superior hemifield	317.24 ± 15.06 (271–359)	321.92 ± 15.03	312.09 ± 12.36	<0.001
Thickness of inferior hemifield	317.20 ± 16.24 (261–361)	322.95 ± 15.01	311.60 ± 15.23	<0.001
Thickness of temporal area	307.70 ± 15.68 (257–350)	313.78 ± 15.22	302.40 ± 13.45	<0.001
Thickness of superior area	321.77 ± 15.32 (275–369)	326.34 ± 15.56	316.70 ± 12.54	0.001
Thickness of nasal area	319.74 ± 16.86 (266–365)	325.51 ± 16.03	313.28 ± 14.98	<0.001
Thickness of inferior area	319.95 ± 16.57 (262–363)	325.64 ± 15.00	314.58 ± 16.15	<0.001
Cup/disc ratio (%)	0.33 ± 0.12 (0.1–0.7)	0.36 ± 0.15	0.31 ± 0.09	0.129
Age (year)	36.39 ± 11.31 (12–67)	33.42 ± 7.99	39.70 ± 13.44	0.003

FAZ: Foveal avascular zone.

SD: Standard deviation.

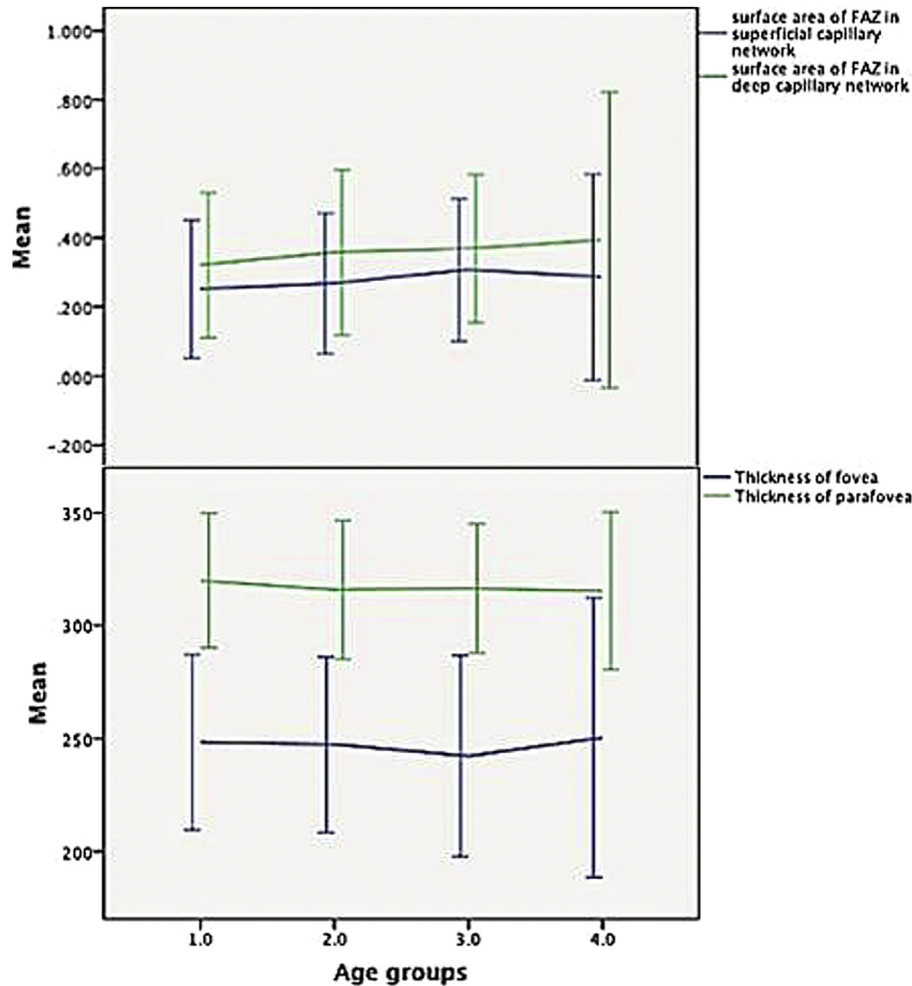


Fig. 2. The amount of foveal avascular zone (FAZ) areas and foveal and parafoveal thicknesses (PFTs) in different age groups. (Upper) The areas of superficial FAZ area with deep FAZ area. The deep FAZ is consistently larger than the superficial FAZ of the same age. (Lower) The foveal and PFTs in different age groups.

results were established on multivariate linear regression, after adjusting to the age (Beta: -0.46 , 95% CI: -27.18 to -11.95 , $P < 0.001$, for CFT and Beta: -0.37 , 95% CI: -16.79 to -5.62 , $P < 0.001$ for PFT).

Age grouping-based foveal avascular zone areas and central foveal thickness and parafoveal thickness

The means of FAZ areas and foveal and PFTs, based on age categories, are shown in Table 2. There was no significant difference of these parameters among different groups (by ANOVA test; Dunnett and Tukey, $P \geq 0.05$).

Correlation of superficial foveal avascular zone and deep foveal avascular zone areas with other evaluated variables

In the age- and gender-adjusted partial correlation, superficial FAZ area was correlated with deep FAZ area ($r = 0.84$, $P < 0.001$), CFT ($r = -0.72$, $P < 0.001$), PFT ($r = -0.25$, $P = 0.02$), thickness of superior hemifield ($r = -0.27$,

$P = 0.02$), thickness of inferior hemifield ($r = -0.25$, $P = 0.03$), thickness of superior area ($r = -0.23$, $P = 0.05$), and thickness of inferior area ($r = -0.33$, $P = 0.003$). In multivariate linear regression analysis, after checking collinearity and adjusting for age and gender, only the correlation of superficial FAZ to deep FAZ area (Beta: 0.60 , 95% CI: 0.42 – 0.59 , $P < 0.001$) and CFT (Beta: -0.49 , 95% CI: -0.003 to -0.002 , $P < 0.001$) persisted.

In the partial correlation analysis, as mentioned, deep FAZ area was correlated with superficial FAZ area ($r = 0.2$, $P < 0.001$) and CFT ($r = -0.50$, $P < 0.001$). In the age- and gender-adjusted multivariate regression analysis, CFT (Beta: -0.519 , 95% CI: -0.004 to -0.002 , $P < 0.001$) persisted.

Repeatability of foveal avascular zone measurements

Measurement of superficial and deep FAZ areas showed very good intergrader agreement (ICC, 0.97 ; 95% CI, 0.95 – 0.99) and intragrader repeatability for both observers (ICC, 0.98 ; 95% CI, 0.97 – 0.99).

Table 2

Surface area of superficial and deep foveal avascular zone (FAZ) and foveal and parafoveal thicknesses (PFT) of normal right eyes in the age groups ranging from 12 to 67 years.

FAZ area (mm ²)/foveal and parafoveal thicknesses (μm) (Mean ± SD) (ANOVA-Dunnett)	≤30 years (N = 41)	31–40 years (N = 37)	41–50 years (N = 20)	>50 years (N = 14)
Surface area of superficial FAZ	025 ± 0.15	0.26 ± 0.16 0.86	0.30 ± 0.02 0.16	0.28 ± 0.03 0.62
Surface area of deep FAZ	0.32 ± 0.16	0.35 ± 0.19 0.48	0.36 ± 0.23 0.39	0.39 ± 0.05 0.17
Thickness of fovea	248.37 ± 3.02	247.32 ± 3.20 0.99	242.25 ± 4.96 0.63	250.36 ± 8.30 0.98
Thickness of parafoveal area	319.95 ± 2.33	315.97 ± 2.53 0.55	316.45 ± 3.19 0.76	315.43 ± 4.66 0.68
Thickness of superior hemifield	318.95 ± 2.40	316.76 ± 2.33 0.86	316.45 ± 3.15 0.88	314.86 ± 4.02 0.72
Thickness of inferior hemifield	320.46 ± 2.31	315.46 ± 2.79 0.41	316.60 ± 3.24 0.73	316.14 ± 5.26 0.74
Thickness of temporal area	310.05 ± 2.48	307.30 ± 2.50 0.80	308.15 ± 3.17 0.95	306.79 ± 4.67 0.86
Thickness of superior area	324.32 ± 2.47	321.24 ± 2.38 0.72	320.25 ± 3.09 0.66	317.93 ± 4.09 0.40
Thickness of nasal area	322.88 ± 2.47	317.49 ± 2.86 0.37	318.20 ± 3.47 0.63	318.57 ± 4.51 0.76
Thickness of inferior area	323.83 ± 2.32	317.78 ± 2.77 0.27	319.40 ± 3.24 0.66	318.79 ± 5.78 0.66

FAZ: Foveal avascular zone.

SD: Standard deviation.

Discussion

In our current study of normal OCTA findings, the area of FAZ in superficial and deep capillary network was larger in the female volunteers. Superficial FAZ is highly correlated with deep FAZ. The central fovea and parafovea were thicker in male volunteers. Area of superficial and deep FAZ did not vary significantly within age groups in this study, and their sizes are inversely correlated with the amount of CFT.

According to the FAZ size, similar results were found in other investigations.^{16,27} Tan and colleagues reported mean superficial and deep area of FAZ to be 0.24 mm² and 0.38 mm² respectively, which is quite similar to our findings²⁹; however, the narrow age range of participants prevented further investigation within age groups. In the study, conducted by Samara et al., FAZ size in superficial network was measured 0.26 ± 0.09 mm² with a wide range (0.071–0.527 mm²), similar to our results. However, FAZ in deep network was measured 0.49 ± 0.22 mm², which was quite larger than our findings.¹⁰ Shahlaee and colleagues reported FAZ in superficial and deep network to be 0.27 ± 0.1 mm² and 0.34 ± 0.1 mm², respectively; however, relative small sample size prevented further analysis of associated factors.²⁸ A consistent finding in these studies was a larger FAZ area in deep network than superficial. Wang and associates measured superficial FAZ in a healthy Chinese population that was 0.35 ± 0.12 mm², which is quite larger than our results.³⁰ They did not report FAZ area in deep capillary network. The discrepancy emphasizes more attention to ethnic background, the technique of measurement, and artifact

removal technology used in newer versions of the software in the interpretation of normative values of the population studies.

Age is another crucial factor that, theoretically, can influence FAZ measurement. In this study, no significant difference in the mean superficial and deep FAZ area was found within age groups. In fact, the association of FAZ area with increasing age is a controversial theme throughout various studies. Yu and colleagues reported an increase in FAZ size annually by 1.48% accompanied by a decrease in vascular density by 0.4%.³¹ They attributed the enlargement of FAZ to tissue loss and relative reduction on oxygen and nutrient demand that leads to reduce vascular supply.^{31,32} As demonstrated in the present study, FAZ area is associated with the thickness of fovea, a factor that is not controlled in the study of Yu et al.³¹ Therefore different measures of CFT with advancing age could act as a confounder in their results. Coscas and associates investigated 135 eyes of 70 participants divided into three groups: 20–39 years; 40–59 years; and 60 years or older. The superficial capillary network FAZ was smaller in group 3 compared with groups 1 and 2. There was no statistically significant difference for the mean deep capillary network FAZ in the three groups. They found direct association of vascular density with age and gender and a lower mean FAZ area in the third group.³³ There are older reports that have measured FAZ area by FA and demonstrated an increase in FAZ size with advancing age.^{15,19} On the other hand, Samara et al. and Wang et al. reported no significant association of age with FAZ area.^{10,30} Different measurement method and diversity of ethnic background may contribute to these discrepancies.

A relation of FAZ with the gender was documented in our study (Table 1). The areas of both the superficial and the deep FAZ were 33% larger in female compared with the male group. Samara et al. showed no association between FAZ area and gender. In the Chinese population, Yu and associates reported that the capillary free zone area is larger in females than in males (male mean, 0.42 mm²; female mean, 0.52 mm²; $P = 0.012$).³¹ Similar to other authors, we think that this could be related to the thinner fovea found in females.^{7,19,28,31–35} The possible mechanisms behind these patterns need to be more investigated. Comparable results were found in the study of Tan and colleagues, too.²⁹ Additionally, they reported a direct correlation to spherical equivalent and axial length.

In our study, the morphology of the fovea was not considered in the evaluation. The impact of aging and gender in the dynamicity of foveal morphology is not evaluated so far, as the superficial and deep FAZ were both in the inner nuclear layer. The possible shallow pit in the females could explain the observed differences.

Current investigation is among the rare studies that have evaluated the effect of CFT on FAZ area.^{10,28,36,37} Based on our findings, superficial and deep capillary network FAZ have an inverse relationship with CFT after adjusting with age and gender, by checking for collinearity. It means that by considering the age and gender, the thinner CFT is correlated with the larger superficial and deep FAZ. In accordance with our results, Samara and associates reported an inverse correlation of both superficial and deep FAZ area with central retinal thickness and volume.¹⁰ No relationship was noticed with age and gender in their results. Tan et al.²⁹ documented that the FAZ size in normal eyes was affected by central retinal thickness and gender only. In their study, among eyes with high myopia, in addition to central retinal thickness and gender, central choroidal thickness also affected the superficial and deep FAZ size.

There are several limitations in our study. The unequal sample size in diverse age categories could affect the results and weaken a thorough model of regression. In this study, spherical equivalent of refractive error, axial length, choroidal thickness, foveal morphology, and vascular density of foveal area of the eyes were not included.

We demonstrated FAZ area at superficial and deep capillary level in a healthy Iranian population. It seems that aging has no influence on the size of FAZ areas. FAZ is larger at the deeper level than superficial capillary network. Superficial and deep FAZ areas are correlated with each other and CFT. Our results indicate that research on foveal deep and superficial avascular zone should take into account the gender-related variations.

References

- Jonas JB, Schneider U, Naumann GO. Count and density of human retinal photoreceptors. *Graefes Arch Clin Exp Ophthalmol*. 1992;230:505–510.
- Yu DY, Cringle SJ, Su EN. Intraretinal oxygen distribution in the monkey retina and the response to systemic hyperoxia. *Invest Ophthalmol Vis Sci*. 2005;46:4728–4733.
- Zheng Y, Gandhi JS, Stangos AN, Campa C, Broadbent DM, Harding SP. Automated segmentation of foveal avascular zone in fundus fluorescein angiography. *Invest Ophthalmol Vis Sci*. 2010;51:3653–3659.
- Mammo Z, Balaratnasingam C, Yu P, et al. Quantitative noninvasive angiography of the fovea centralis using speckle variance optical coherence tomography. *Invest Ophthalmol Vis Sci*. 2015;56:5074–5086.
- Kim DY, Fingler J, Zawadzki RJ, et al. Noninvasive imaging of the foveal avascular zone with high-speed, phase-variance optical coherence tomography. *Invest Ophthalmol Vis Sci*. 2012;53:85–92.
- Popovic Z, Knutsson P, Thaug J, Owner-Petersen M, Sjöstrand J. Noninvasive imaging of human foveal capillary network using dual-conjugate adaptive optics. *Invest Ophthalmol Vis Sci*. 2011;52:2649–2655.
- Chui TY, VanNasdale DA, Elsner AE, Burns SA. The association between the foveal avascular zone and retinal thickness. *Invest Ophthalmol Vis Sci*. 2014;55: 6870–6877.
- Pinhas A, Razeen M, Dubow M, et al. Assessment of perfused foveal microvascular density and identification of nonperfused capillaries in healthy and vasculopathic eyes. *Invest Ophthalmol Vis Sci*. 2014;55:8056–8066.
- Schmoll T, Singh AS, Blatter C, et al. Imaging of the parafoveal capillary network and its integrity analysis using fractal dimension. *Biomed Opt Express*. 2011;2:1159–1168.
- Samara WA, Say EA, Khoo CT, et al. Correlation of foveal avascular zone size with foveal morphology in normal eyes using optical coherence tomography angiography. *Retina*. 2015;35:2188–2195.
- Kuehlewain L, Tepelus TC, An L, Durbin MK, Srinivas S, Sadda SR. Noninvasive visualization and analysis of the human parafoveal capillary network using swept source OCT optical microangiography. *Invest Ophthalmol Vis Sci*. 2015;56:3984–3988.
- Dubis AM, Hansen BR, Cooper RF, Beringer J, Dubra A, Carroll J. Relationship between the foveal avascular zone and foveal pit morphology. *Invest Ophthalmol Vis Sci*. 2012;53:1628–1636.
- Tam J, Martin JA, Roorda A. Noninvasive visualization and analysis of parafoveal capillaries in humans. *Invest Ophthalmol Vis Sci*. 2010;51:1691–1698.
- Novotny HR, Alvis DL. A method of photographing fluorescence in circulating blood in the human retina. *Circulation*. 1961;24:82–86.
- Laatikainen L. The fluorescein angiography revolution: a breakthrough with sustained impact. *Acta Ophthalmol Scand*. 2004;82:381–392.
- Takase N, Nozaki M, Kato A, Ozeki H, Yoshida M, Ogura Y. Enlargement of foveal avascular zone in diabetic eyes evaluated by en face optical coherence tomography angiography. *Retina*. 2015;35:2377–2383.
- Freiberg FJ, Pfau M, Wons J, Wirth MA, Becker MD, Michels S. Optical coherence tomography angiography of the foveal avascular zone in diabetic retinopathy. *Graefes Arch Clin Exp Ophthalmol*. 2016;254:1051–1058.
- Ditzel J, Clair RW. Clinical method of photographing the smaller blood vessels and the circulating blood in the bulbar conjunctiva of human subjects. *Circulation*. 1954;10(2):277–281.
- Wu LZ, Huang ZS, Wu DZ, Chan E. Characteristics of the capillary-free zone in the normal human macula. *Jpn J Ophthalmol*. 1985;29:406–411.
- Puliafito CA, Hee MR, Lin CP, et al. Imaging of macular diseases with optical coherence tomography. *Ophthalmology*. 1995;102:217–229.
- Spaide RF, Klancnik JM, Cooney MJ. Retinal vascular layers imaged by fluorescein angiography and optical coherence tomography angiography. *JAMA Ophthalmol*. 2015;133:45–50.
- Savastano MC, Lumbroso B, Rispoli M. In vivo characterization of retinal vascularization morphology using optical coherence tomography angiography. *Retina*. 2015;35:2196–2203.
- Mendis KR, Balaratnasingam C, Yu P, et al. Correlation of histologic and clinical images to determine the diagnostic value of fluorescein angiography for studying retinal capillary detail. *Invest Ophthalmol Vis Sci*. 2010;51:5864–5869.
- Fingler J, Zawadzki RJ, Werner JS, Schwartz D, Fraser SE. Volumetric microvascular imaging of human retina using optical coherence tomography with a novel motion contrast technique. *Opt Express*. 2009;17: 22190–22200.
- Motaghianezam SM, Koos D, Fraser SE. Differential phase-contrast, swept-source optical coherence tomography at 1060 nm for in vivo human retinal and choroidal vasculature visualization. *J Biomed Opt*. 2012;17:026011.

26. Jia Y, Tan O, Tokayer J, et al. Split-spectrum amplitude decorrelation angiography with optical coherence tomography. *Opt Express*. 2012;20:4710–4725.
27. Carpineto P, Mastropasqua R, Marchini G, Toto L, Di Nicola M, Di Antonio L. Reproducibility and repeatability of foveal avascular zone measurements in healthy subjects by optical coherence tomography angiography. *Br J Ophthalmol*. 2016;100:671–676.
28. Shahlaee A, Pefkianaki M, Hsu J, Ho AC. Measurement of foveal avascular zone dimensions and its reliability in healthy eyes using optical coherence tomography angiography. *Am J Ophthalmol*. 2016;161, 50–55 e1.
29. Tan CS, Lim LW, Chow VS, et al. Optical coherence tomography angiography evaluation of the parafoveal vasculature and its relationship with ocular factors. *Invest Ophthalmol Vis Sci*. 2016;57:224–234.
30. Wang Q, Chan S, Yang JY, et al. Vascular density in retina and chorio-capillaris as measured by optical coherence tomography angiography. *Am J Ophthalmol*. 2016;168:95–109.
31. Yu J, Jiang C, Wang X, et al. Macular perfusion in healthy Chinese: an optical coherence tomography angiogram study. *Invest Ophthalmol Vis Sci*. 2015;56:3212–3217.
32. Vandewalle E, Abegao PL, Olafsdottir OB, et al. Oximetry in glaucoma: correlation of metabolic change with structural and functional damage. *Acta Ophthalmol*. 2014;92:105–110.
33. Coscas F, Sellam A, Glacet-Bernard A, et al. Normative data for vascular density in superficial and deep capillary plexuses of healthy adults assessed by optical coherence tomography angiography. *Invest Ophthalmol Vis Sci*. 2016;57:211–223.
34. Laatikainen L, Larinkari J. Capillary-free area of the fovea with advancing age. *Invest Ophthalmol Vis Sci*. 1977;16:1154–1157.
35. Tick S, Rossant F, Ghorbel I, et al. Foveal shape and structure in a normal population. *Invest Ophthalmol Vis Sci*. 2011;52:5105–5110.
36. Luo HD, Gazzard G, Fong A, et al. Myopia, axial length, and OCT characteristics of the macula in Singaporean children. *Invest Ophthalmol Vis Sci*. 2006;47:2773–2781.
37. Lam DS, Leung KS, Mohamed S, et al. Regional variations in the relationship between macular thickness measurements and myopia. *Invest Ophthalmol Vis Sci*. 2007;48:376–382.