

# Cervical epidural analgesia complicated by epidural abscess

## A case report and literature review

Jun-Hui Zhang, BS<sup>a,b</sup>, Zhi-Li Wang, BS<sup>a</sup>, Li Wan, MD, PhD<sup>b,\*</sup>

### Abstract

**Rationale:** Spinal epidural abscess is an uncommon complication in clinical practice. If the abscess is large enough, the patient will rapidly develop neurologic signs of spinal injury, and urgent neurosurgical intervention may be required.

**Patient concerns:** Rapid and correct diagnosis and treatment is important for spinal epidural abscess complication.

**Diagnoses:** This report describes a cervical epidural abscess (CEA) caused by epidural analgesia, wherein the patient was punctured twice. A CEA was suspected based on the patient's significant neck pain and elevated white blood cell and neutrophil counts. A CEA from C6 to T8 was confirmed by magnetic resonance imaging scan.

**Interventions:** The patient was treated with a combination of intravenous vancomycin and imipenem/cilastatin for more than 4 weeks.

**Outcomes:** After more than 2 weeks of intensive antibiotic treatment, the epidural abscess gradually diminished in size, the white blood cell count, neutrophil count, hyperallergic C-reactive protein (CRP), and general CRP decreased, and the patient's neck and back pain resolved. After more than 4 weeks of anti-inflammation therapy, the epidural abscess was completely absorbed, and there was no relapse during the 3-month follow-up period.

**Lessons:** Although an effective combination of intravenous antibiotics can cure an epidural abscess, caution is warranted when performing epidural steroid injections in immunocompromised patients.

**Abbreviations:** CEA = cervical epidural abscess, CRP = C-reactive protein, ESR = erythrocyte sedimentation rate, MRI = magnetic resonance imaging, SEA = spinal epidural abscess.

**Keywords:** antibiotics, cervical epidural abscess, epidural analgesia

## 1. Introduction

A cervical epidural abscess (CEA) is a rare complication after epidural puncture and injection. Immunocompromised hosts, diabetes mellitus, and epidural catheter placement, are risk factors for epidural abscess.<sup>[1–6]</sup> The classical triad of a spinal epidural abscess (SEA) is pain, fever, and neurologic deficits.<sup>[7]</sup> Specifically, CEA seems to initially present with neck pain, neck stiffness, and/or fever.<sup>[8]</sup> The combination of neck pain or stiffness along with fever should raise the suspicion for CEA.

Editor: Somchai Amorniyotin.

The authors report no conflicts of interest.

<sup>a</sup> 903 Hospital, Jiangyou City, Sichuan Province, <sup>b</sup> The Second Affiliated Hospital, State Key Clinical Specialty in Pain Medicine, Guangzhou Medical University, Guangzhou, Guangdong, P.R. China.

\* Correspondence: Li Wan, Department of Pain Management, The Second Affiliated Hospital, State Key Clinical Specialty in Pain Medicine, Guangzhou Medical University, Guangzhou, Guangdong P.R. China (e-mail: wanli5000cn@163.com).

Copyright © 2017 the Author(s). Published by Wolters Kluwer Health, Inc. This is an open access article distributed under the terms of the Creative Commons Attribution-NonCommercial-ShareAlike 4.0 License, which allows others to remix, tweak, and build upon the work non-commercially, as long as the author is credited and the new creations are licensed under the identical terms.

Medicine (2017) 96:40(e7789)

Received: 7 March 2017 / Received in final form: 11 July 2017 / Accepted: 26 July 2017

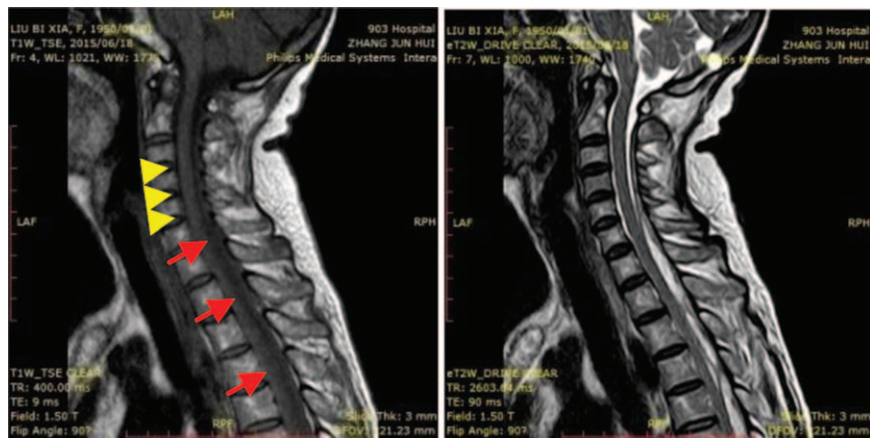
<http://dx.doi.org/10.1097/MD.0000000000007789>

Magnetic resonance imaging (MRI) is a useful diagnostic method to identify an epidural abscess and has contributed to the recent increase in SEA diagnoses. After diagnosis, urgent treatment, including early, effective, and adequate antibiotics as well as surgical decompression may be necessary to facilitate neurologic recovery.<sup>[8]</sup> In this article, we present a unique case of a patient who developed an epidural abscess after a cervical epidural puncture and injection. Once the diagnosis of CEA was made, antibiotics were promptly started, the patient was closely monitored, and the abscess was cured without surgical intervention.

## 2. Case presentation

A 65-year-old woman with 4 days of neck and shoulder pain that affected her sleep in addition to left arm numbness was seen in our Pain Management Department. Prior to her arrival, the patient had taken some medications (specific details were not clear), but the pain did not improve and became intolerable. The patient had a history of hypertension that had not been treated regularly, and her highest blood pressure was 180/100 mm Hg. All of the patient's examinations and treatments were approved by the ethics committee of 903 Hospital.

Upon arrival, the patient's vital signs showed hypertension with a blood pressure of 170/92 mm Hg; her other vital signs were normal. Physical examination showed a normal spine and extremities. There was slight tenderness over the cervical and the corresponding paravertebral area. The Spurling test, Jackson test,



**Figure 1.** Magnetic resonance imaging shows multiple disc herniation of cervical 3/4, 4/5, and 5/6. The epidural sac is compressed by disc herniation (yellow arrow head). Epidural inflammation is seen with increased signal intensity (red arrow).

and left Eaton test were all positive. Sensation to pain and muscular tension of the extremities were normal bilaterally, and motor strength was grade 4/5 in the upper and lower extremities bilaterally. The biceps and triceps reflexes were normal bilaterally, and the Hoffmann sign was negative.

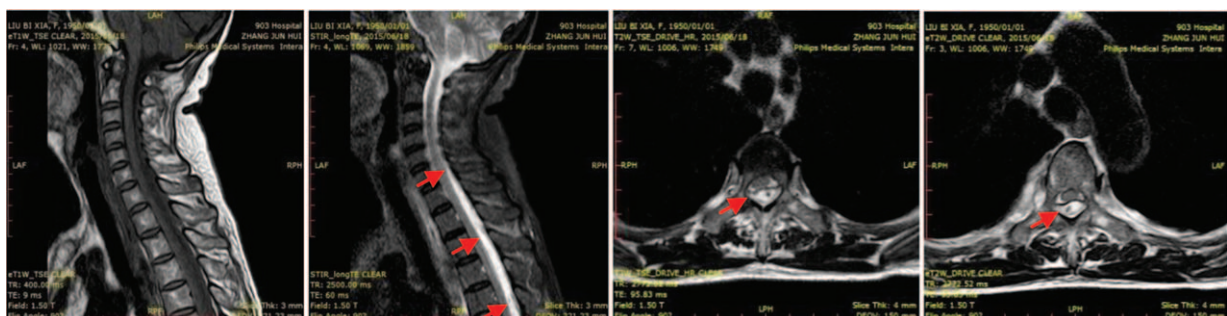
When she arrived, the patient underwent an MRI scan that showed multiple disc herniation at cervical 3/4, 4/5, and 5/6, and the epidural sac was compressed by the disc herniation (Fig. 1).

The initial diagnosis was cervical spondylosis and primary hypertension. It was decided to treat the patient conservatively with loxoprofen 60mg twice a day, nifedipine sustained release tablets 10mg daily, and an intravenous drip of 250mL of 20% mannitol daily.

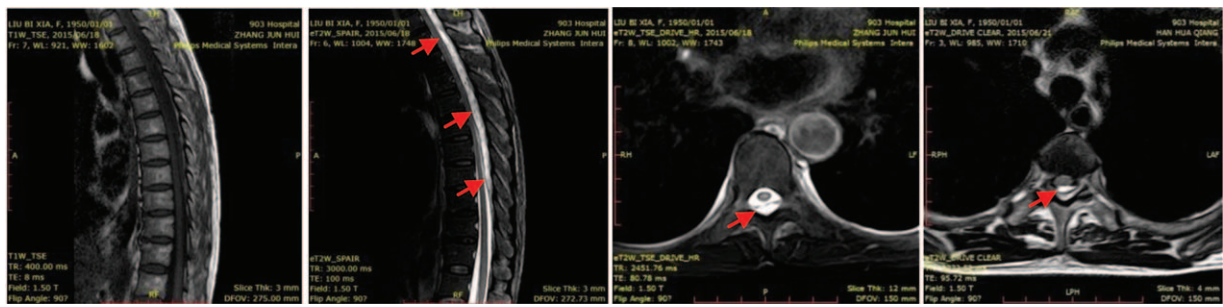
Two days later, the patient manifested clusters of tiny blisters along the C4 and C5 dermatome; the vesicular fluid was clear and there was no tenderness, suggesting the patient might have a concurrent acute herpes zoster infection. The antiviral drug famciclovir 0.25g was started 3 times a day. The next day, the patient underwent a nerve block procedure with an epidural puncture at the C7 to T1 space, and a catheter was inserted. The patient received an injection of 3mL of the following mixture through the epidural catheter: 5mL of 2% lidocaine, dexamethasone 10mg, vitamin B1 100mg, vitamin B6 100mg, mecobalamin 1mg, and 2mL 0.9% saline, total volume 12mL. The patient was observed for 10 minutes after the injection, and there were no signs of spinal anesthesia; the remaining volume of the mixture was subsequently injected and the catheter was removed.

The following day, the patient's pain had decreased and the clusters of blisters were somewhat reduced in size. A second epidural puncture and injection were performed, and the patient received the same nerve block mixture as before. The patient then showered and began to complain of body soreness, slight weakness, and a headache. Bilateral lung wheezing was heard on physical examination, and the patient was given 1 capsule of amoxicillin. However, the patient experienced severe pain of the shoulder, neck, and head accompanied by a low-grade fever (37.8°C), fatigue, and nighttime muscle aches. The patient also fell 1 time on the ward. Blood was tested due to these aggravated symptoms, and the white blood cell count was  $24.27 \times 10^9/L$ , neutrophil percentage was 92.41%, erythrocyte sedimentation rate (ESR) was 66mm/h, hyperallergic C-reactive protein (CRP) was over 10mg/L, and general CRP was 193.8mg/L, suggesting an acute inflammation. The patient underwent a chest x-ray and cervical/thoracic MRI scan and was started on intravenous cefperazone/sulbactam 2g twice a day and fosfomycin sodium. One day later the patient still complained of severe shoulder pain and headache; physical examination revealed C4 to T8 tenderness and neck stiffness; however, limb strength was normal. The MRI scan indicated epidural inflammation from C6 to T8 and an abscess formation (Fig. 2).

The patient was moved to the intensive care unit to receive more intensive antibiotic treatment with vancomycin 1g every 12 hours combined with imipenem/cilastatin sodium 1g every 8 hours for anti-inflammation. Famciclovir was also changed to



**Figure 2.** Magnetic resonance imaging shows cervical and thoracic epidural inflammation accompanying the abscess in the axial T2-weighted image. The epidural space in the C6 to T8 segment shows high signal gathering, and the right spinal cord has been compressed (red arrow).



**Figure 3.** Magnetic resonance imaging shows partial resolution of the abscess. On axial T2-weighted imaging, the gathering signal intensity is reduced, and the area of inflammation has decreased compared to Fig. 2.

gentinovir 0.15 g twice a day for antiviral treatment. The patient’s neck and back pain significantly improved after 4 days of anti-inflammation therapy, and the MRI scan showed significant absorption of the abscess (Fig. 3). This therapeutic regimen was continued for 17 days, during which the white blood cell count decreased to  $5.11 \times 10^9/L$ , the neutrophil percentage decreased to 57.3%, the ESR decreased to 76 mm/h, the hyperallergic CRP decreased to 4.71 mg/L, and the general CRP was less than 10 mg/L. The patient’s neck and back pain disappeared, and the clusters of blisters scabbed over. On physical examination, there was slight tenderness to percussion but no pressing pain or neck stiffness. After 3 weeks of anti-inflammation therapy, the antibiotics were gradually weaned. After over a month of anti-inflammation therapy, the epidural abscess was completely absorbed and the patient was discharged from the hospital (Fig. 4).

**3. Discussion**

An epidural abscess is a life-threatening infection with a high risk of disability and mortality. If the patient in this case had not been diagnosed and treated promptly, the patient may have developed permanent complications such as paraplegia or even death.<sup>[9]</sup> Therefore, rapid identification and treatment of an epidural abscess will yield the best outcomes.<sup>[10]</sup>

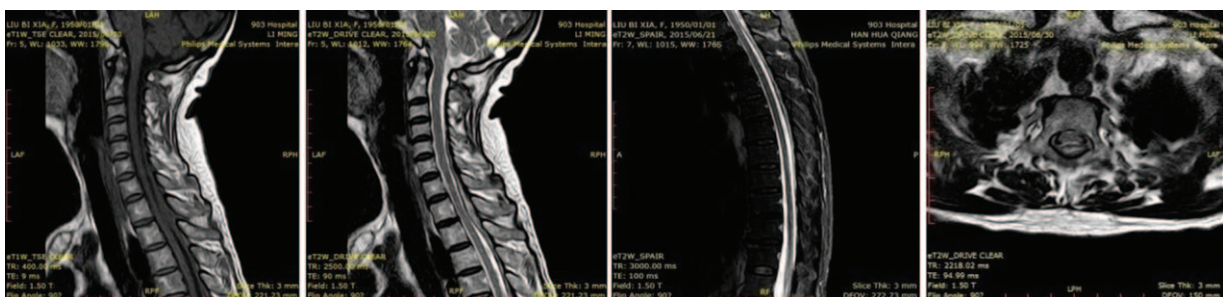
The most common symptoms and signs reported with an SEA are neck and back pain, fever, and neurologic deficits.<sup>[7,8,11]</sup> In this case, the patient showed some of the signs and symptoms, such as neck pain, neck stiffness, and a low-grade fever, which raised the suspicion for an epidural abscess. The inflammatory markers, such as the ESR, CRP, and white blood cell count, supported the diagnosis of an epidural abscess.<sup>[8]</sup> An MRI scan

can provide a definitive diagnosis once an SEA is suspected, and MRI enhancement has a sensitivity over 90%.<sup>[7,12]</sup> In this case, the MRI scan provided direct evidence of an epidural abscess between C6 and T8, which guided the treatment strategy.

An MRI is able to differentiate between SEAs and other spinal lesions such as subdural abscesses and tumors. The classical description of an SEA on MRI is an iso- or hyperintense collection in the epidural space on a T1-weighted image that enhances with gadolinium contrast and a non-homogeneous and hyperintense signal on a T2-weighted image.<sup>[8,11,13]</sup> These classical imaging signs of an epidural abscess were present in this case (Fig. 2).

Anti-inflammation by antibiotics is an important non-surgical treatment for an epidural abscess, especially in the early stages before any neurologic deficit occurs. Chan and Oh<sup>[11]</sup> reported that there is no guarantee that medical treatment will succeed. If antibiotic therapy alone is considered for aneurologically intact patient, frequent neurologic examinations, blood testing (such as ESR, CRP, and white blood cell count), and MRI examinations are required to monitor the development of the disease. Once the patient shows any neurologic deficit, surgical decompression should be considered.<sup>[8]</sup> Although the period of antibiotic therapy for epidural abscess is still being debated, it is preferable to continue treatment for at least 4 weeks, because studies have shown a 25% rate of relapse in patients who were treated for less than 4 weeks.<sup>[11,14,15]</sup> In the present case, the patient received antibiotic therapy for more than 1 month and showed no evidence of relapse during the 3-month follow-up period.

The patient in this case had a prodrome of herpes zoster infection of the shoulder and posterior neck pain with numbness followed by clusters of tiny blisters along the C4 to C5 dermatome; this suggests that the patient may have been immunocompromised, which could explain the development of



**Figure 4.** Magnetic resonance imaging shows that the epidural abscess is almost completely absorbed, and the epidural space now shows normal signal intensity (red arrow).



an epidural abscess. There were other iatrogenic mechanisms that could significantly increase the risk of an epidural abscess that we cannot exclude, including repeated punctures, epidural catheter placement, and injection of drugs,<sup>[16]</sup> which can disturb the local microenvironment and result in the spread of pathogens into the epidural space. Based on the events in this case, it is suggested that repeated epidural punctures should be avoided in immunocompromised patients to decrease the risk of an epidural abscess.

#### 4. Conclusions

In conclusion, an epidural abscess is a rare complication that requires rapid diagnosis and treatment. An MRI scan has a high sensitivity and specificity when an epidural abscess is suspected, and prompt diagnosis and treatment are key to curing this disease.

#### References

- [1] Tang HJ, Lin HJ, Liu YC, et al. Spinal epidural abscess—experience with 46 patients and evaluation of prognostic factors. *J Infect* 2002;45:76–81.
- [2] Huang RC, Shapiro GS, Lim M, et al. Cervical epidural abscess after epidural steroid injection. *Spine* 2004;29:E7–9.
- [3] Alcock E, Regaard A, Browne J. Facet joint injection: a rare form cause of epidural abscess formation. *Pain* 2003;103:209–10.
- [4] Philipneri M, Al-Aly Z, Amin K, et al. Routine replacement of tunneled, cuffed, hemodialysis catheters eliminates paraspinal/vertebral infections in patients with catheter-associated bacteremia. *Am J Nephrol* 2003;23:202–7.
- [5] Bang MS, Lim SH. Paraplegia caused by spinal infection after acupuncture. *Spinal Cord* 2006;44:258–9.
- [6] Sillevs Smitt P, Tsafka A, van den Bent M, et al. Spinal epidural abscess complicating chronic epidural analgesia in 11 cancer patients: clinical findings and magnetic resonance imaging. *J Neurol* 1999;246:815–20.
- [7] Sendi P, Bregenzer T, Zimmerli W. Spinal epidural abscess in clinical practice. *QJM* 2008;101:1–2.
- [8] Al-Hourani K, Al-Aref R, Mesfin A. Upper cervical epidural abscess in clinical practice: diagnosis and management. *Global Spine J* 2016;6:383–93.
- [9] Murata M, Yoshikawa K, Hiratsuka M, et al. A case of extensive sacral decubitus ulcer complicated by an epidural abscess. *Plast Reconstr Surg Glob Open* 2016;4:e790.
- [10] Ramos AD, Rolston JD, Gauger GE, et al. Spinal subdural abscess following laminectomy for symptomatic stenosis: a report of 2 cases and review of the literature. *Am J Case Rep* 2016;17:476–83.
- [11] Chan JJ, Oh JJ. A rare case of multiple spinal epidural abscesses and cauda equina syndrome presenting to the emergency department following acupuncture. *Int J Emerg Med* 2016;9:22.
- [12] An HS, Seldomridge JA. Spinal infections: diagnostic tests and imaging studies. *Clin Orthop Relat Res* 2006;444:27–33.
- [13] Jarvik JG, Deyo RA. Diagnostic evaluation of low back pain with emphasis on imaging. *Ann Intern Med* 2002;137:586–97.
- [14] Shweikeh F, Saeed K, Bukavina L, et al. An institutional series and contemporary review of bacterial spinal epidural abscess: current status and future directions. *Neurosurg Focus* 2014;37:1–1.
- [15] Suppiah S, Meng Y, Fehlings MG, et al. How best to manage the spinal epidural abscess? A current systematic review. *World Neurosurg* 2016;93:20–8.
- [16] Philipneri M, Al-Aly Z, Amin K, et al. Routine replacement of tunneled, cuffed, hemodialysis catheters eliminates paraspinal/vertebral infections in patients with catheter-associated bacteremia. *Am J Nephrol* 2003;23:202–7.