



# Collagenase Clostridium Histolyticum in the Treatment of Peyronie's Disease: Review of a Minimally Invasive Treatment Option

Andrew T Gabrielson, Laith M Alzweri, Wayne JG Hellstrom

Department of Urology, Tulane University School of Medicine, New Orleans, LA, USA

Peyronie's disease (PD) is an inflammatory disorder characterized by an abnormal collagen deposition in the tunica albuginea of the penis, leading to fibrous and non-compliant plaques that can impede normal erection. Although pharmacological treatments are available, only intralesional injection therapy and surgical reconstruction have demonstrated tangible clinical efficacy in the management of this condition. Intralesional injection of collagenase clostridium histolyticum (CCH) has come to the forefront of minimally invasive treatment of PD. In this review, the authors provide an update on the safety, efficacy, and indications for CCH. The efficacy of CCH will be assessed on the basis of improvement in the severity of penile fibrosis, curvature, and pain. Numerous well-designed clinical trials and post-approval studies involving more than 1,500 patients have consistently demonstrated the efficacy and tolerability of CCH in the treatment of PD. CCH significantly decreases penile curvature and plaque consistency, as well as improves quality of life. Post-approval studies continue to demonstrate the efficacy of CCH despite broader inclusion criteria for treatment, such as the case with acute phase disease and atypical plaque deformities (*i.e.*, ventral plaques, hourglass narrowing). CCH continues to be the gold standard for non-surgical management of stable phase PD, in the absence of strong evidence supporting oral therapy agents and ongoing evaluation of extracorporeal shockwave therapy. However, recent studies are beginning to provide precedent for the use of CCH in the management of acute phase and atypical PD.

**Key Words:** Injections, intralesional; Microbial collagenase; Penile Induration; Therapeutics; Urologic diseases

## INTRODUCTION

### 1. Origins of collagenase clostridium histolyticum

Collagenase clostridium histolyticum (CCH), marketed as Xiaflex<sup>®</sup> (Endo Pharmaceuticals, Inc., Malvern, PA, USA) [1], was first isolated and purified from the bacterium

*Clostridium histolyticum* in 1953 by Mandl et al [2]. CCH is comprised of a heterogeneous group of seven different enzymes that were found to demonstrate remarkable specificity to digestion of specific protein domains within type I and type III collagen fibers under physiological conditions. Commercially, CCH is available as a mixture of

Received: Aug 24, 2017; Accepted: Sep 1, 2017; Published online Sep 6, 2017

Correspondence to: Wayne JG Hellstrom  <https://orcid.org/0000-0003-1284-959X>

Department of Urology, Tulane University School of Medicine, 1430 Tulane Ave, 86-42, New Orleans, LA 70112, USA.  
Tel: +1-504-988-3361, Fax: +1-504-988-5059, E-mail: [whellst@tulane.edu](mailto:whellst@tulane.edu)

Copyright © 2017 Korean Society for Sexual Medicine and Andrology  
This is an Open Access article distributed under the terms of the Creative Commons Attribution Non-Commercial License (<http://creativecommons.org/licenses/by-nc/4.0>) which permits unrestricted non-commercial use, distribution, and reproduction in any medium, provided the original work is properly cited.

AUX-I collagenases, which cleave the N- and C-terminal ends of triple-helical collagen, and AUX-II collagenases, which hydrolyze internal peptide domains with higher affinity than AUX-I [3,4]. Furthermore, preclinical studies have demonstrated that AUX-I and AUX-II enzymes are not immunologically cross-reactive and work synergistically to breakdown collagen plaques [5]. The specificity of CCH makes it an attractive therapeutic option for patients with Peyronie's disease (PD), a fibroproliferative condition characterized by the formation of penile plaques composed largely of type I and type III collagens [6].

Studies have demonstrated that CCH exerts pleiotropic effects on the development and progression of PD. One *in vivo* study found that CCH could degrade the collagen fibers abundant in PD, as well as suppress cell adhesion and the maturation of fibroblasts. CCH accomplishes this by downregulating extracellular-matrix associated genes, cytokines and growth factors over-expressed in PD. CCH has also been shown to directly induce membrane leakage and decrease metabolic activity in fibroblasts, as well as reduce expression of alpha-smooth muscle actin, desmin, transforming growth factor beta-1 (TGF- $\beta$  1), and fibronectin [7]. Furthermore, CCH demonstrates no activity against elastin, keratin, albumin, or hemoglobin [8]. One important feature of CCH is that it does not exhibit activity against type IV collagen fibers, which are heavily expressed in the basal lamina of arteries and veins, and the perineurium of peripheral nerves [8]. Its poor activity against type IV collagen was supported by pre-clinical studies, which demonstrated that CCH did not cause significant degradation of blood vessels, nerves, and epithelium following local injection [9-11]. In summary, CCH selectively targets type I and III collagen fibers that generate the pathological curvature in PD, but spare type IV collagen that are important components of normal vascular anatomy of the penis. In 2013, the United States Food and Drug Administration approved CCH for the non-surgical management of PD in men with dorsal or lateral penile curvature  $>30^\circ$  with or without a tangible penile plaque [1]. CCH has since become the gold standard in the minimally invasive treatment of PD.

## 2. Pharmacokinetics, pharmacodynamics and safety profile

To test the safety of CCH in humans, 19 patients received a single cycle of intralesional injection of CCH (two injections at a dose of 0.58 mg separated by 24~72 hours). Plasma AUX-I and AUX-II levels in subjects with quantifiable levels of the two enzymes were minimal and short-lived. Within 10 minutes of intralesional injection, maximal plasma concentrations of AUX-I and AUX-II were less than 29 ng/mL and 71 ng/mL, respectively. All subjects had undetectable levels of AUX-I and AUX-II in their plasma within 30 minutes of injection [12,13].

Each AUX-I and AUX-II molecule requires fusion of catalytic and collagen-binding domains in order to possess the catalytic activity necessary to degrade collagen. *In-vivo* studies found that the enzymes require both calcium and zinc to act as cofactors to facilitate proteolysis, as zinc is necessary for activation at the catalytic site, and calcium maintains the appropriate structure of the collagen-binding site to accept the triple-helix structure of the collagen fibrils. When collagenase is injected intralesionally in patients with PD, it specifically targets the collagen within the plaque, which has an abundant amount of type I and III collagen. These enzymes lyse the cord's collagen structure to make it more susceptible to rupture following manual manipulation [9,14].

## PEYRONIE'S DISEASE

### 1. Epidemiology

Estimating the true prevalence of PD has been a challenge for researchers, given the heterogeneity of sub-populations and clinical settings in which studies have been carried out. Moreover, prevalence estimates may differ greatly by age, pre-existing comorbidities, and socioeconomic status [15-18]. Many clinicians have perceived PD to be a rare disease ( $<1\%$  of adult males). This perception may be attributed to a 1991 study conducted by Lindsay et al [19] which found a PD prevalence of 0.39% in males ages 19 and older living in Rochester, Minnesota from 1950 to 1984. More recent studies have shown that a significant percentage of the adult population suffers from PD. A large cross-sectional study conducted in 1999

in Cologne, Germany found the prevalence of PD to be 3.2% among all study subjects age 30 to 80 years old, and as high as 6.5% in men over 70 years old [20]. In another study, conducted in 2004 and involving 534 men undergoing prostate cancer screening in the United States, palpable penile plaques were found in 8.9% of patients [21]. In 2011, Dibenedetti et al [22] found, using an open Internet survey, a prevalence of 13% among males 18 years and older who had been diagnosed, treated, or currently had penile symptoms consistent with PD. Unfortunately, many of the aforementioned studies lack consistency with regards to their definition of PD and their reporting methodology, making comparisons between populations difficult. To address this issue, Stuntz et al [23] conducted a cross-sectional study using the same parameters as the Dibenedetti et al [22]. The 2016 study conducted by Stuntz et al [23] found the prevalence of definitive and probable cases of PD in the United States to be 0.7% and 11%, respectively. The estimate of 0.7% for definitive cases is consistent with the 0.5% prevalence of definitive cases found by Dibenedetti et al [22].

Despite improvements in recent estimates, the prevalence of PD is still likely underestimated for a variety of reasons. First, patients may consider the disease to be embarrassing and, therefore, may be unlikely to approach their physician with complaints of penile deformities. Second, patients may also mistakenly consider the effects of PD to be a natural effect of aging. Lastly, the prevalence of PD may be underestimated due to the high rate of comorbid erectile dysfunction, as penile deformities are potentially less notable when the penis is flaccid.

## 2. Pathophysiology

PD is an inflammatory disorder that is characterized by aberrant collagen deposition in the tunica albuginea of the penis leading to fibrous, non-compliant plaques that can impede erection. The most widely accepted theory for the cause of PD is repeated tunical mechanical stress and microvascular trauma to the erect penis. During erection, the tunica albuginea is stretched thin (<0.5 mm) relative to its thickness during the flaccid state (5 mm), making it prone to traumatic injury. Trauma may be brought on by: 1) the woman on top generates upward pressure on the relatively weak septal tunica junction, 2) the man accidentally

thrusts his penis against his partner's perineum, thereby fracturing the penis, or 3) aggressive manipulation of the penis during masturbation [24]. Trauma then results in fluid and fibrinogen deposition, which initiates a local wound healing response. Following infiltration of neutrophils and macrophages, cytokines such as TGF- $\beta$  1 are produced, increasing the production and deposition of collagen by fibroblasts [25]. TGF- $\beta$  1 has been described as a major driver of the fibroproliferative mechanism in PD. TGF- $\beta$  1 promotes plaque formation by inhibiting collagenases and stimulating the production of reactive oxygen species (ROS). ROS increase oxidative stress leading to lipid peroxidation, collagen III deposition and possible calcification. In 30 patients with PD, increased expression of TGF- $\beta$  1 (26/30 patients), TGF- $\beta$  2 (7/30 patients), and TGF- $\beta$  3 (5/30 patients) was observed, compared to only 1/8 patients in the Non-PD group [25]. A rat model of PD has also been developed using subcutaneous injections of cytomodulin, a synthetic peptide with TGF- $\beta$ -like activity [26]. After six weeks of subcutaneous injections of cytomodulin, El-Sakka et al [26] found histological and ultrastructural alterations in the rat penis similar to those found in human PD. Using this rat model, Bivalacqua et al [27] demonstrated upregulation of nuclear factor kappa B, a regulator of adhesion molecules and inducible nitric oxide synthase (iNOS) following injection of TGF- $\beta$  1 and injury to the rat penis. This study supports the notion that iNOS activity may correlate with a protective effect against the development of PD. Francisco et al [28] improved the durability of the rat model by injecting both TGF- $\beta$  1 and tetradecyl sulphate, which yielded a stronger fibrotic response than TGF- $\beta$  1 alone. While the precise mechanism of PD is still not fully understood, the interplay between trauma and the resultant expression of profibrotic cytokines continues to be a recurring theme.

## 3. Clinical presentation

The classic signs and symptoms of PD are palpable nodules in the penis that can cause varying degrees of penile deformity and erectile dysfunction. These penile deformities may also manifest as abnormal penile curvature, indentation, hourglass narrowing, and penile shortening, which can have detrimental effects on quality of life. Classically, PD follows two distinct clinical phases: an

acute, progressive phase and a chronic, inactive phase. The acute phase involves painful erections with worsening penile deformity that typically lasts between six months and two years [25]. In contrast, the chronic phase is often pain-free and patients have stabilization of penile deformities. In reality, the clinical course of PD is unpredictable, and the optimal time to initiate treatment remains unknown. Some studies have demonstrated stable disease in a majority of patients at 12 months following conservative management [29]. However, other studies have reported that more than half of patients have worsening of curvature at 12 months [30].

Of note, there are also several risk factors and comorbid conditions associated with PD. The most notable of which is Dupuytren's contracture, which mimics PD histologically and is observed in up to 21% of PD patients [31,32]. The prevalence of PD in patients receiving radical prostatectomy (RP) has also been reported to be as high as 15.9%, with a mean time to develop PD after RP of  $13.9 \pm 0.7$  months [33]. Penile trauma, diabetes mellitus, Paget's disease, lipomas, the use of beta-adrenergic blockers, plantar fascial contractures, tympanosclerosis, urethral instrumentation, and gout have also been associated with PD; however, no causative link has been described [34,35]. In addition, a family history of PD has been documented in 2% of patients [30].

#### 4. Treatment

There are myriad medical and surgical therapies available to urologists for managing PD. Topical, oral, and injectable pharmacological treatments along with non-pharmacological treatments such as electromotive drug administration (EMDA), penile traction therapy, and extracorporeal shockwave therapy have been investigated as initial treatment options for patients with PD. Unfortunately, many of the studies evaluating these therapies are underpowered and have failed to demonstrate significant clinical benefit.

The American Urological Association (AUA) does not recommend the use of oral treatments such as vitamin E, procabazine, omega-3 fatty acids, colchicine, potassium para-aminobenzoate, tamoxifen, pentoxifylline, co-enzyme Q10, and carnitine in the treatment of PD [24,36,37]. These therapies have failed to demonstrate clinical effi-

cacy in reducing penile curvature, plaque burden, and pain compared to placebo. Although many of these therapies do not carry significant adverse side effects, using oral agents alone may postpone the use of other efficacious therapies, leading to delayed treatment and increased costs.

EMDA with verapamil has also failed to demonstrate clinical efficacy in the management of PD, and is thus not endorsed by the AUA [24,38]. A randomized-controlled study using verapamil with EMDA (delivered at home) showed minimal improvement over placebo in terms of penile curvature, plaque size, erectile pain, and erectile quality in patients with PD [39]. However, a similar study found no statistically significant improvement in curvature versus placebo [40].

Like oral agents and EMDA, the use of extracorporeal shock wave therapy (ESWT) has been met with mixed results. ESWT is hypothesized to disrupt dense Peyronie's plaques and allow for resolution of penile deformity and pain; however, the exact mechanism has yet to be characterized [41]. Palmieri et al [42] found small non-significant decreases in curvature and plaque burden in patients treated with ESWT compared to placebo. However, several studies have demonstrated no effect on curvature or plaque size, and as such the AUA recommends against the use of ESWT, as well [24,43,44]. Additionally, ESWT may be associated with penile fibrosis and erectile dysfunction, furthering limiting its clinical application [45].

Intralesional injections with interferon-alpha2b, verapamil, and CCH, have proven to be more effective than topical and oral medications in the treatment of PD. Interferon-alpha2b has been shown to inhibit fibroblast proliferation and upregulate collagenase activity, thereby reducing collagen formation [46]. Hellstrom et al [47] conducted the first multi-institutional randomized controlled trial of intralesional interferon-alpha2b in patients with PD >12 months (6 doses), with penile curvature >30°. Patients given 5 million units interferon-alpha2b every two weeks for 12 weeks were compared to placebo. Patients in the treatment arm had significant improvements in curvature (treatment = -13.5° vs. placebo = -4.5°), plaque burden (treatment = 2.6 cm<sup>2</sup> vs. placebo = 0.9 cm<sup>2</sup>), pain (treatment = 68% vs. placebo = 28%), and penile blood flow as measured by duplex Doppler

ultrasonography. Erectile function as measured by the International Index of Erectile Function (IIEF) did not significantly differ between the two groups. Interestingly, another randomized controlled trial evaluating intralesional interferon-alpha2b in patients within early stage PD (<6 months) did not demonstrate statistically significant improvements in curvature and pain compared to vitamin E alone. These seemingly contradictory findings suggested that interferons should be administered to patients with stable PD [48]. Interferon- alpha2b injections have a good safety profile, with the most common adverse events being self-limiting sinusitis, flu-like symptoms, and minor penile swelling. This can be reduced by administering pre-injection non-steroidal anti-inflammatory drugs. Intralesional verapamil is also believed to increase collagenase activity and decrease collagen production; however, studies have shown mixed efficacy. Although verapamil has demonstrated improvements in plaque size and penile curvature in some studies, other large randomized controlled studies did not show any significant improvement compared to placebo [49-52]. Intralesional verapamil commonly causes side effects such as penile bruising and swelling; however dizziness, nausea, sweating, loss of libido, and pain at the injection site has been noted in some cases [53]. The role of CCH in the treatment of PD will be reviewed in the succeeding section of this article.

Escalation to surgical management is indicated in patients with PD symptoms for at least 12 months and stable penile curvature for at least three months. Surgical techniques used for penile reconstruction include, but are not limited to, tunical plication, tunical incision/excision with grafting, and implantation of a penile prosthesis [24]. It is important for clinicians to consider factors such as the length of the penis, the severity of curvature, nature of the deformity, and degree of erectile dysfunction when selecting a surgical modality. Tunical plication is the most common surgical technique for PD and has demonstrated improvement in penile curvature in >90% of cases. This technique is particularly beneficial for patients with curvatures <60° and normal erectile function (or respond to oral medication or vacuum pump therapy) [54,55]. For patients with severe curvature (>60°) or atypical deformity (narrowing or hinge) with normal erectile function, incision/excision and graft placement is employed [56].

Lastly, in patients with severe erectile dysfunction, insertion of an inflatable prosthesis is often recommended.

## COLLAGENASE CLOSTRIDIUM HISTOLYTICUM (Xiaflex<sup>®</sup>) IN THE TREATMENT OF PEYRONIE'S DISEASE

### 1. Efficacy in active phase disease

The treatment of active phase PD remains controversial, as the vast majority of data evaluating CCH's efficacy was conducted using patients with stable disease. Notably, the "Investigation of Maximal Peyronie's Reduction Efficacy and Safety Studies (IMPRESS)" clinical trials required at least one year of stable disease prior to initiation of CCH injections. Given the dearth of studies evaluating CCH in the acute phase, the AUA recommends against treatment until the plaque and curvature no longer demonstrate progression [24]. Fortunately, post-approval studies of CCH are beginning to incorporate patients who meet the acute phase criteria and have been met with positive results.

Yang and Bennett [57] were the first to report the outcomes of patients treated with CCH in the acute phase of PD. The authors included 12 patients with acute phase disease near the time of first injection and found a mean curvature decrease of 20° after treatment compared to a 13.9° curvature decrease in patients treated in the chronic phase ( $p < 0.0001$ ). Despite the small sample size, this study supports the authors claim that CCH may alter the course of PD if intervention occurs during the acute phase. Anaissie et al [58] conducted a retrospective study in 77 patients with heterogeneous forms of PD, 21 of which met criteria for acute phase disease. The authors of this study found that patients with acute phase PD had an overall decrease in penile curvature of  $-16.2^\circ \pm 16.3^\circ$ , which was comparable to the change in curvature observed in those with stable PD ( $-14.9^\circ \pm 11.5^\circ$ ;  $p = 0.702$ ). While this study fails to demonstrate superiority over stable phase intervention, it does provide further support that CCH use in acute phase PD is both safe and efficacious. Future post-approval studies of CCH should continue to incorporate patients with acute phase disease to better characterize these findings. If CCH can be given to patients before severe curvature deformity develops, clinicians may

be able to modify the physical and psychosocial impact of this disease.

## 2. Efficacy in stable phase disease

The efficacy of CCH in the management of stable phase PD has been evaluated through numerous clinical trials and post-approval studies over the past few years. Although the formulation of CCH has remained constant, the protocol in which it is administered has been in continual flux. This section will highlight the efficacy of CCH in the context of a constantly changing protocol.

The early studies evaluating the efficacy of CCH followed a protocol designed by Gelbard et al [3], in which patients were given one or two intralesional injections of CCH and observed for improvements in penile curvature, plaque burden, and penile pain. In this protocol, no penile modeling was performed by the patient or clinician. Gelbard et al [3] conducted the first of these studies involving 31 patients with stable PD. Within 4 weeks of first injection, the authors found that 20 patients (64.5%) had an objective improvement in their PD. PD was eliminated in four patients and penile curvature decreased between 20% to 100% in 16 patients (51.6%). Furthermore, CCH was shown to relieve penile deformity more effectively in patients with greater initial plaque burden. Of the 14 patients who began the study with penile pain, 13 patients (92.9%) reported complete resolution of pain within 4 weeks of treatment. Additionally, three of the four patients who reported erectile dysfunction regained full erectile function following treatment. Despite this success, patients with circumferential plaques and those with decreased erectile rigidity distal to the plaque failed to show improvement of symptoms following treatment [3]. The second of these studies, also conducted by Gelbard et al [59], was a prospective, randomized, placebo controlled, double-blind phase IIa study involving 49 men with stable PD. Patients were assigned different doses of CCH based on curvature and plaque size at presentation (Group 1:  $\leq 30^\circ$  and/or plaque size  $< 2$  cm; Group 2:  $30^\circ \sim 60^\circ$  and/or plaque size  $2 \sim 4$  cm; Group 3:  $> 60^\circ$  and/or plaque size  $> 4$  cm). Patients in Groups 1, 2, and 3 received intralesional CCH at doses of 0.35 mg, 0.58 mg, and 0.81 mg, respectively. When the treatment Groups 1, 2, and 3 were analyzed together for patient-reported improvement

of curvature, CCH demonstrated statistically significant benefit compared to placebo (36% vs. 4%,  $p=0.007$ ). However, when assessing the three treatment arms individually, only the patients treated in Group 2 had statistically significant improvement of curvature. As a result, future clinical studies would go on to adopt the Group 2 dose of CCH (0.58 mg) [59]. The last study to evaluate the efficacy of CCH without modeling in stable PD was Jordan [60], who reported results from a phase IIb trial data on a 9-month, open-label study involving 25 patients. Participants were given three injections of CCH with a total dose of 0.58 mg administered over 7 to 10 days, with repeat injections delivered every three months for three cycles. Interestingly, the greatest reduction in penile curvature and plaque size was observed after a single treatment cycle (at three months). Within the first three months, over 50% of patients experienced decreased curvature and 94% experienced decreased plaque size. Furthermore, patient questionnaires given at each follow-up point demonstrated significant improvements in subjective patient sexual function and quality of life.

The next generation of studies standardized the treatment regimen to include three 6-week cycles of CCH injections coupled with intermittent penile modeling therapy. Each treatment cycle consisted of two injections of CCH (0.58 mg) or placebo with an interval of 24 to 72 hours between the injections. Between 24 and 72 hours after the second injection of each treatment cycle, either the clinician or the patient performed gentle stretching of the flaccid penis for 30 seconds in the opposite direction of the curvature. Gelbard et al [61] was the first to incorporate modeling therapy in tandem with CCH injection in a phase IIb, randomized, double-blind, placebo controlled study that involved 147 patients. In this study, patients in the CCH plus modeling arm had a mean decrease in penile curvature of  $-17.5^\circ \pm 15.3^\circ$  (32.4% per patient), which was clinically superior to the mean decrease in curvature observed in both the CCH without modeling arm ( $-15.0^\circ \pm 14.0^\circ$  or 27.1% per patient) and the placebo arm receiving modeling without CCH ( $-5.4^\circ \pm 13.8^\circ$  or 11% per patient;  $p < 0.001$ ). The promising results from this and other phase I and phase II trials provided the framework with which two large phase III clinical trials, titled "IMPRESS I and II" would be based. These

studies were identical prospective, 1-year, double-blinded, randomized, placebo-controlled studies that enrolled a combined 832 men from 64 sites across the United States and Australia [62]. The protocol of the IMPRESS trials mirrored that of Gelbard's phase IIb study [61]; however, in addition to penile modeling by the investigator, patients were instructed to perform home modeling three times per day between each injection cycle. The mean baseline curvature for IMPRESS I and II was  $50.1^\circ \pm 14.4^\circ$  and  $49.3^\circ \pm 14.0^\circ$  in men in the CCH and placebo arms, respectively. Patients in the CCH arm had statistically significant greater reduction in penile curvature when compared to those receiving placebo ( $-17.0^\circ \pm 14.8^\circ$  or 34% vs.  $-9.3^\circ \pm 13.6^\circ$  or 18.2%, respectively;  $p < 0.0001$ ). Patients in the CCH arm also experienced improvement in the Peyronie's Disease Questionnaire (PDQ) symptom bother domain compared to placebo ( $p < 0.003$ ). All PDQ domains other than penile length and penile pain showed statistically significant improvements in the CCH arm versus placebo. Treatment-related adverse events were observed in 464 patients (84.2%) compared to 102 patients (36.3%) receiving placebo. However, the most common adverse events, such as penile bruising, swelling, and pain were self-limited and 79% resolved without intervention within 14 days. Six patients experienced serious adverse events requiring intervention, including three corporal ruptures and three penile hematomas [62]. Levine et al [63] reported results of another phase III multi-institutional clinical trial involving 347 patients, which utilized the same protocol and endpoints as the IMPRESS trials. Mean penile curvature in the treatment arm decreased by  $-18.3^\circ \pm 14.02^\circ$  (34%) after 36 weeks. Similar to the IMPRESS trials, the CCH arm also demonstrated a statistically significant improvement in mean PDQ symptom bother domain from baseline to week 36 when compared to placebo. The improvements in both curvature and PDQ bother score were evident in patients in the treatment arm irrespective of baseline penile curvature severity. Patients treated with CCH also demonstrated statistically significant improvement in penile plaque firmness, IIEF overall satisfaction score, and penile pain [63].

The most recent generation of studies has continued to use the protocol outlined in the IMPRESS trials, with the caveat that patients perform the modeling themselves be-

ginning on the first day of injections. The utility of home modeling is two-fold. Home modeling allows patients to be more involved with their care and limits manipulation performed by the clinician, which patients often find uncomfortable. Additionally, home modeling reduces the number of required office visits during treatment, thereby minimizing post-procedural costs. The efficacy of CCH with home modeling was first analyzed by Ziegelmann et al [64] in a prospective study involving 69 patients being treated for stable PD. In Ziegelmann's study [64], treatment cycles were administered in the same manner as the IMPRESS trials, but patients were instructed to perform the modeling themselves (rather than the clinician) beginning on the first day of the injection. This study was unique for several reasons. First, the authors utilize multiplanar (or composite) rather than uniplanar measurements of penile curvature, which more accurately characterizes baseline deformity and response to CCH treatment. Patients in the treatment arm had statistically significant improvements in both uni- and multi-planar curvatures after each successive cycle of CCH when compared to placebo. Those with multiplanar deformities demonstrated a  $23^\circ$  (38%) decrease in curvature, while those with uniplanar (purely dorsal or lateral) deformities demonstrated an  $18^\circ$  (33%) improvement ( $p < 0.0001$ ). Second, this study was the first to address the impact of CCH treatment on the need for surgery, which has been associated with erectile dysfunction, as well as decreased penile length and sensation [65]. Among those completing four cycles of CCH, 57% of patients believed that CCH negated the need for surgery, and 52% reported restoration of penetration. Overall, 81% of men perceived CCH treatment as meaningful and 88% reported subjective improvements after four cycles of injections. Seven patients developed penile hematomas (10%) without any reports of fracture or tunical rupture [64]. Yang and Bennett [57] reported the second prospective study involving 49 patients undergoing CCH injections with home modeling (after penile bruising and pain resolved). Patients in this study demonstrated a  $15.4^\circ$  curvature reduction (32.4%) following treatment. Similar to Ziegelmann et al [64], this study had a higher than expected rate of adverse events (10%). However, this may be attributed to more liberal patient selection than in the previous trials. Yang and Bennett [57] incorporated patients

with active disease, as well as hourglass and ventral deformities, and placed no restrictions with regards to baseline curvature.

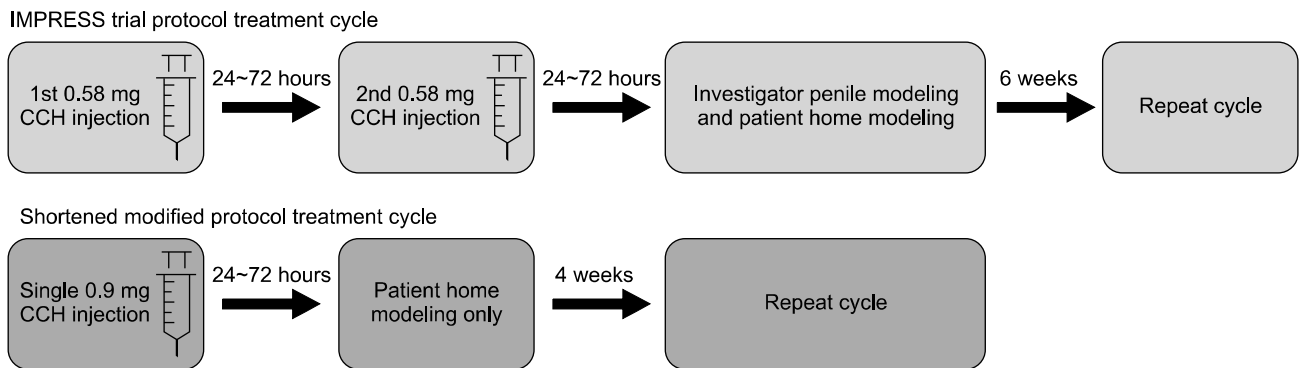
### 3. Comparison of standard and shortened protocol

The standard protocol for administration of CCH is outlined in the IMPRESS trials. Using this protocol, each patient receives a total of eight injections split into four cycles of two injections (0.58 mg) given 24 to 72 hours apart from one another at six weekly intervals. During the 24 to 72 hour post-injection period, either the patient or the physician applies traction to the penis in the opposite direction of the curvature to enhance plaque disruption [62]. While this protocol has demonstrated clinical efficacy, there are several drawbacks. First, the standard protocol utilizes small concentrations of CCH, making it difficult to adequately distribute the drug over a wide area of the curvature apex. Second, intralesional injection of CCH causes a local inflammatory reaction that can make it difficult to palpate the plaque for the second injection after 24 to 72 hours. Furthermore, 24 to 72 hours may not be enough time for the inflammation at the injection site to subside before the next injection, potentially contributing to penile bruising and pain. Third, the standard protocol requires 14 patient visits over a 24-week period, which can be a significant burden on patients from a cost and time perspective [66].

In the aforementioned study, Anaissie et al [58] was the first to report findings examining the relationship between the number of treatment cycles and clinical efficacy. This study involved retrospective analysis of 77 patients treated

at a single institution using the same treatment protocol as outlined in the IMPRESS trials. In their repeated measures model, penile curvature improved significantly following the first three treatment cycles, but not the fourth. These findings suggest that the four-cycle protocol set forth by the IMPRESS trials may be worth reevaluating. Interestingly, the authors found that patients who had a  $\geq 20\%$  final reduction in curvature had a significantly greater change in curvature following the first injection ( $-16.2^\circ$  vs.  $5.8^\circ$ ,  $p < 0.001$ ). Thus patients who have a strong response to the first cycle of CCH may be more likely to have a superior final reduction in penile curvature after completion of successive cycles of treatment. Equipped with this information, urologists can counsel patients who have a strong response to initial treatment to complete the CCH regimen. For example, patients who demonstrate a weak response to initial treatment can be told that they may still achieve significant clinical benefit from further cycles; however, final curvature improvement may be limited.

More recently, Abdel Raheem et al [66] evaluated the efficacy and safety of CCH administration using a modified and shortened treatment protocol in 53 patients at a single center. In their shortened protocol, each cycle consists of only one injection with a larger dose of CCH (0.9 mg; whole vial), rather than two injections of the dose (0.58 mg each) outlined by Gelbard et al [6,59,61,62] in earlier studies (Fig. 1). This method allows higher concentrations of CCH to be delivered to the plaque while limiting the inflammatory changes that occur with more injections. Furthermore, limiting the frequency of injections in the modified protocol and having patients com-



**Fig. 1.** Flowchart demonstrating differences between the Investigation of Maximal Peyronie’s Reduction Efficacy and Safety Studies (IMPRESS) trial protocol and shortened modified protocol. CCH: collagenase clostridium histolyticum.



**Table 1.** Comparison of the IMPRESS trial protocol and shortened modified protocol characteristics

| Variable                   | IMPRESS trial protocol | Shortened modified protocol |
|----------------------------|------------------------|-----------------------------|
| Duration of cycle (wk)     | 6                      | 4                           |
| Maximum number of cycle    | 4                      | 3                           |
| Number of office visit     | 14                     | 4                           |
| Duration of treatment (wk) | 24                     | 12                          |

IMPRESS: Investigation of Maximal Peyronie's Reduction Efficacy and Safety Studies.

plete the modeling themselves at home, allows patients to complete treatment in only four patient visits over a 12-week period (Table 1). This undoubtedly improves compliance and reduces costs associated with CCH treatment. More importantly however, this shortened modified protocol demonstrated a mean curvature reduction of  $-17.4^\circ$  ( $-31.4\%$ ) from baseline. This is comparable to the results obtained in the IMPRESS trials, which yielded mean curvature reduction of  $-17^\circ$  ( $-34\%$ ) from baseline [66]. Moreover, there was an improvement in each of the IIEF questionnaire domains, all 3 PDQ domains, and the global assessment of the PDQ.

#### 4. Efficacy in atypical Peyronie's disease

Although the vast majority of patients with PD have dorsal and uniplanar curvature, roughly 10% of patients have atypical presentations of PD, including ventral curvature, hourglass narrowing, and multiplanar curvature. Patients with atypical PD often have a greater burden of disease when compared to those with more typical presentations, especially in regard to sexual dysfunction [67,68]. Unfortunately, the IMPRESS trials excluded patients with ventral plaques and hourglass deformities due to concerns of urethral damage during injection and modeling therapy. To-date, only one report has been published analyzing the efficacy of CCH in the treatment of ventral plaques. Milam [69] administered four cycles of CCH to two patients with ventral plaques measuring  $30^\circ$  and  $45^\circ$  at presentation. There was a mean improvement of  $32^\circ$  (86%) between the two patients, and both reported marked improvement of symptoms without serious adverse events. This study suggests that ventral plaques can be managed with intrale-

sional injection, and may reduce the need for surgical intervention. Furthermore, intralesional injection poses fewer risks (erectile dysfunction, hematoma, corporal rupture) than surgery, making intralesional injection an attractive option for this patient population. If CCH is not tolerated, patients with ventral plaques may also benefit from intralesional interferon-alpha2b. Stewart et al [70] compared the efficacy of intralesional interferon-alpha2b in the treatment of dorsal versus ventral plaques in a retrospective analysis involving 131 patients. Intralesional interferon-alpha2b reduced curvatures by more than  $20^\circ$  in over 90% of patients irrespective of plaque location. To-date, despite the aforementioned report, clinical trials have not evaluated the use of CCH in the treatment of ventral plaques; however, these studies challenge the framework that atypical PD must be managed surgically.

Similar to the management of ventral plaques, there is a paucity of studies evaluating the management of patients with rare presentations of PD, such as hourglass deformity, penile shortening, or multiplanar curvature. A meta-analysis conducted by Yafi et al [68] concluded that surgical intervention using partial excision and grafting or plaque incision and grafting may be the best option for those with atypical presentations. However, for atypical presentations that can result in loss of adequate penile length, non-invasive approaches such as penile traction therapy and pharmacological management should be employed.

## CONCLUSION

Intralesional CCH reduces PD-associated penile curvature by an average of 30%, and produces clinically significant improvements in penile curvature, plaque thickness, and sexual function. Post-approval studies continue to become available and dynamically modify study protocols to optimize clinical outcomes. The archetypal protocol outlined in the IMPRESS trials involves 14 patient visits over a 24-week period and requires physician-assisted penile modeling. More recently, a shortened modified protocol involving only four patient visits over a 12-week period and home penile modeling was introduced. The shortened modified protocol improves patient compliance and reduces treatment-associated costs, while still maintaining clinical efficacy. Long-term efficacy and ad-

verse events are still being assessed; however, outcomes from recent studies are in keeping with the results obtained during the IMPRESS trials. An inclusion criterion of CCH has been expanded to include patients with acute phase and atypical deformities in pilot studies, which have been met with positive results. These studies suggest that CCH will continue to be the attractive modality for minimally invasive treatment of all forms and phases of PD for years to come.

## Disclosure

Dr. Wayne Hellstrom is an adviser and on a speaker's bureau of Endo Pharmaceuticals Co. (Malvern, PA, USA), but this has made no influence on this work in relation with the company or its products. Other authors have no potential conflicts of interest to disclose.

## Author Contribution

Research conception & design: Gabrielson AT, Hellstrom WJG. Performing the experiments: N/A. Data acquisition: Gabrielson AT, Alzweri LM, Data analysis and interpretation: Gabrielson AT, Alzweri LM. Statistical analysis: Gabrielson AT. Drafting of the manuscript: Gabrielson AT. Critical revision of the manuscript: Alzweri LM, Hellstrom WJG. Receiving grant: N/A. Approval of final manuscript: all authors.

## ORCID

Andrew T Gabrielson, <https://orcid.org/0000-0001-9971-9813>

Laith M Alzweri, <https://orcid.org/0000-0001-8467-2688>

Wayne JG Hellstrom, <https://orcid.org/0000-0003-1284-959X>

## REFERENCES

1. Endo Pharmaceuticals Inc. Xiaflex® (Collagenase Clostridium histolyticum) [prescribing information]. Malvern (PA): Endo Pharmaceuticals Inc.; 2016;1-42.
2. Mandl I, MacLennan JD, Howes EL, DeBellis RH, Sohler A. Isolation and characterization of proteinase and collagenase from *Cl. histolyticum*. *J Clin Invest* 1953;32:1323-9.
3. Gelbard MK, Lindner A, Kaufman JJ. The use of collagenase in the treatment of Peyronie's disease. *J Urol* 1985;134:280-3.
4. French MF, Mookhtiar KA, Van Wart HE. Limited proteolysis of type I collagen at hyperreactive sites by class I and II *Clostridium histolyticum* collagenases: complementary digestion patterns. *Biochemistry* 1987;26:681-7.
5. Kono T. Purification and partial characterization of collagenolytic enzymes from *Clostridium histolyticum*. *Biochemistry* 1968;7:1106-14.
6. Gelbard MK, Walsh R, Kaufman JJ. Collagenase for Peyronie's disease experimental studies. *Urol Res* 1982;10:135-40.
7. Levine LA, Schmid TM, Emeigh Hart SG, Tittelbach T, McLane MP, Tursi JP. PD22-03. Collagenase clostridium histolyticum degrades type I and III Collagen while sparing Type IV collagen in vitro in Peyronie's plaque explants. *J Urol* 2014;191:e672-3.
8. Auxilium Pharmaceuticals. Pharmacokinetics of a Single Treatment Cycle of AA4500 0.58 mg in Men with Peyronie's Disease. Bethesda (MD): National Library of Medicine; 2011.
9. Desai SS, Hentz VR. Collagenase clostridium histolyticum for Dupuytren's contracture. *Expert Opin Biol Ther* 2010;10:1395-404.
10. Rydevik B, Brown MD, Ehira T, Nordborg C. Effects of collagenase on nerve tissue. An experimental study on acute and long-term effects in rabbits. *Spine (Phila Pa 1976)* 1985;10:562-6.
11. Rydevik B, Ehira T, Linder L, Olmarker K, Romanus M, Brånemark PI. Microvascular response to locally injected collagenase. An experimental investigation in hamsters and rabbits. *Scand J Plast Reconstr Surg Hand Surg* 1989;23:17-21.
12. Mookhtiar KA, Van Wart HE. Clostridium histolyticum collagenases: a new look at some old enzymes. *Matrix Suppl* 1992;1:116-26.
13. Garvin PJ Jr. Toxicity of collagenase: the relation to enzyme therapy of disk herniation. *Clin Orthop Relat Res* 1974;(101):286-91.
14. Jung CM, Matsushita O, Katayama S, Minami J, Sakurai J, Okabe A. Identification of metal ligands in the *Clostridium histolyticum* ColH collagenase. *J Bacteriol* 1999;181:2816-22.
15. Shiraishi K, Shimabukuro T, Matsuyama H. The prevalence of Peyronie's disease in Japan: a study in men undergoing maintenance hemodialysis and routine health checks. *J Sex Med* 2012;9:2716-23.
16. El-Sakka AI, Tayeb KA. Peyronie's disease in diabetic patients being screened for erectile dysfunction. *J Urol* 2005;174:1026-30.
17. Arafa M, Eid H, El-Badry A, Ezz-Eldine K, Shamloul R. The prevalence of Peyronie's disease in diabetic patients with erectile dysfunction. *Int J Impot Res* 2007;19:213-7.
18. El-Sakka AI. Prevalence of Peyronie's disease among patients with erectile dysfunction. *Eur Urol* 2006;49:564-9.
19. Lindsay MB, Schain DM, Grambsch P, Benson RC, Beard CM, Kurland LT. The incidence of Peyronie's disease in Rochester, Minnesota, 1950 through 1984. *J Urol* 1991;146:1007-9.
20. Schwarzer U, Sommer F, Klotz T, Braun M, Reifenrath B, Engelmann U. The prevalence of Peyronie's disease: results of a large survey. *BJU Int* 2001;88:727-30.
21. Mulhall JP, Creech SD, Boorjian SA, Ghaly S, Kim ED, Moty A, et al. Subjective and objective analysis of the prevalence of Peyronie's disease in a population of men presenting for

- prostate cancer screening. *J Urol* 2004;171:2350-3.
22. Dibenedetti DB, Nguyen D, Zografos L, Ziemięcki R, Zhou X. A population-based study of Peyronie's disease: prevalence and treatment patterns in the United States. *Adv Urol* 2011. doi: 10.1155/2011/282503 [Epub].
  23. Stuntz M, Perlaky A, des Vignes F, Kyriakides T, Glass D. The prevalence of Peyronie's disease in the United States: a population-based study. *PLoS One* 2016;11:e0150157.
  24. Nehra A, Alterowitz R, Culkin DJ, Faraday MM, Hakim LS, Heidelbaugh JJ, et al. Peyronie's disease: AUA guideline. *J Urol* 2015;194:745-53.
  25. El-Sakka AI, Hassoba HM, Pillarisetty RJ, Dahiya R, Lue TF. Peyronie's disease is associated with an increase in transforming growth factor-beta protein expression. *J Urol* 1997; 158:1391-4.
  26. El-Sakka AI, Hassan MU, Nunes L, Bhatnagar RS, Yen TS, Lue TF. Histological and ultrastructural alterations in an animal model of Peyronie's disease. *Br J Urol* 1998;81:445-52.
  27. Bivalacqua TJ, Diner EK, Novak TE, Vohra Y, Sikka SC, Champion HC, et al. A rat model of Peyronie's disease associated with a decrease in erectile activity and an increase in inducible nitric oxide synthase protein expression. *J Urol* 2000;163:1992-8.
  28. Francisco G, Ling DY, Eric C, Michael B, Gerald B. MP-06.02. A Novel rat model for Peyronie's disease that demonstrates durability and functional detriments. *CUA J* 2012; 6:S51.
  29. Berookhim BM, Choi J, Alex B, Mulhall JP. Deformity stabilization and improvement in men with untreated Peyronie's disease. *BJU Int* 2014;113:133-6.
  30. Mulhall JP, Schiff J, Guhring P. An analysis of the natural history of Peyronie's disease. *J Urol* 2006;175:2115-8.
  31. Carrieri MP, Serraino D, Palmiotto F, Nucci G, Sasso F. A case-control study on risk factors for Peyronie's disease. *J Clin Epidemiol* 1998;51:511-5.
  32. Rhoden EL, Riedner CE, Fuchs SC, Ribeiro EP, Halmenschlager G. A cross-sectional study for the analysis of clinical, sexual and laboratory conditions associated to Peyronie's disease. *J Sex Med* 2010;7:1529-37.
  33. Tal R, Heck M, Teloken P, Siegrist T, Nelson CJ, Mulhall JP. Peyronie's disease following radical prostatectomy: incidence and predictors. *J Sex Med* 2010;7:1254-61.
  34. Jordan GH, McCammon KA. Peyronie's disease. In: Wein AJ, Kavoussi LR, Novick AC, Partin AW, Peters CA, editors. *Campbell-Walsh urology*. 10th ed. Philadelphia: Saunders; 2007;792-809.
  35. Chilton CP, Castle WM, Westwood CA, Pryor JP. Factors associated in the aetiology of peyronie's disease. *Br J Urol* 1982;54:748-50.
  36. Chung E, Ralph D, Kagioglu A, Garaffa G, Shamsodini A, Bivalacqua T, et al. Evidence-based management guidelines on Peyronie's disease. *J Sex Med* 2016;13:905-23.
  37. Jack GS, Gonzalez-Cadavid N, Rajfer J. Conservative management options for Peyronie's disease. *Curr Urol Rep* 2005;6:454-60.
  38. Levine LA, Estrada CR, Shou W, Cole A. Tunica albuginea tissue analysis after electromotive drug administration. *J Urol* 2003;169:1775-8.
  39. Fitch WP 3rd, Easterling WJ, Talbert RL, Bordovsky MJ, Mosier M. Topical verapamil HCl, topical trifluoperazine, and topical magnesium sulfate for the treatment of Peyronie's disease: a placebo-controlled pilot study. *J Sex Med* 2007; 4:477-84.
  40. Greenfield JM, Shah SJ, Levine LA. Verapamil versus saline in electromotive drug administration for Peyronie's disease: a double-blind, placebo controlled trial. *J Urol* 2007;177: 972-5.
  41. Hauck EW, Mueller UO, Bschleipfer T, Schmelz HU, Diemer T, Weidner W. Extracorporeal shock wave therapy for Peyronie's disease: exploratory meta-analysis of clinical trials. *J Urol* 2004;171:740-5.
  42. Palmieri A, Imbimbo C, Longo N, Fusco F, Verze P, Mangiapia F, et al. A first prospective, randomized, double-blind, placebo-controlled clinical trial evaluating extracorporeal shock wave therapy for the treatment of Peyronie's disease. *Eur Urol* 2009;56:363-9.
  43. Chitale S, Morsey M, Swift L, Sethia K. Limited shock wave therapy vs sham treatment in men with Peyronie's disease: results of a prospective randomized controlled double-blind trial. *BJU Int* 2010;106:1352-6.
  44. Hatzichristodoulou G, Meisner C, Gschwend JE, Stenzl A, Lahme S. Extracorporeal shock wave therapy in Peyronie's disease: results of a placebo-controlled, prospective, randomized, single-blind study. *J Sex Med* 2013;10:2815-21.
  45. Müller A, Akin-Olugbade Y, Devenci S, Donohue JF, Tal R, Kobylarz KA, et al. The impact of shock wave therapy at varied energy and dose levels on functional and structural changes in erectile tissue. *Eur Urol* 2008;53:635-42.
  46. Russell S, Steers W, McVary KT. Systematic evidence-based analysis of plaque injection therapy for Peyronie's disease. *Eur Urol* 2007;51:640-7.
  47. Hellstrom WJ, Kendirci M, Matern R, Cockerham Y, Myers L, Sikka SC, et al. Single-blind, multicenter, placebo controlled, parallel study to assess the safety and efficacy of intralesional interferon alpha-2B for minimally invasive treatment for Peyronie's disease. *J Urol* 2006;176:394-8.
  48. Inal T, Tokatli Z, Akand M, Ozdiler E, Yaman O. Effect of intralesional interferon-alpha 2b combined with oral vitamin E for treatment of early stage Peyronie's disease: a randomized and prospective study. *Urology* 2006;67:1038-42.
  49. Wolf SE, Nicolai M, Dagenais G. Growth hormone treatment in catabolic states other than burns. *Growth Horm IGF Res* 1998;8 Suppl B:117-9.
  50. Rehman J, Benet A, Melman A. Use of intralesional verapamil to dissolve Peyronie's disease plaque: a long-term single-blind study. *Urology* 1998;51:620-6.
  51. Wolff B, Peyronnet B, Cattarino S, Mozer P, Renard-Penna R, Phé V, et al. Intralesional injections for early peyronie disease: standardized assessment and analysis of predictive

- factors for treatment response. *Urology* 2015;86:57-61.
52. Shirazi M, Haghpanah AR, Badiie M, Afrasiabi MA, Haghpanah S. Effect of intralesional verapamil for treatment of Peyronie's disease: a randomized single-blind, placebo-controlled study. *Int Urol Nephrol* 2009;41:467-71.
  53. Peak TC, Mitchell GC, Yafi FA, Hellstrom WJ. Role of collagenase clostridium histolyticum in Peyronie's disease. *Biologics* 2015;9:107-16.
  54. Dean RC, Lue TF. Peyronie's disease: advancements in recent surgical techniques. *Curr Opin Urol* 2004;14:339-43.
  55. Levine LA, Lenting EL. A surgical algorithm for the treatment of Peyronie's disease. *J Urol* 1997;158:2149-52.
  56. Hatzimouratidis K, Eardley I, Giuliano F, Hatzichristou D, Moncada I, Salonia A, et al. EAU guidelines on penile curvature. *Eur Urol* 2012;62:543-52.
  57. Yang KK, Bennett N. Peyronie's disease and injectable collagenase clostridium histolyticum: safety, efficacy, and improvements in subjective symptoms. *Urology* 2016;94:143-7.
  58. Anaissie J, Yafi FA, DeLay KJ, Traore EJ, Sikka SC, Hellstrom WJ. Impact of number of cycles of collagenase clostridium histolyticum on outcomes in patients with Peyronie's disease. *Urology* 2017;100:125-30.
  59. Gelbard MK, James K, Riach P, Dorey F. Collagenase versus placebo in the treatment of Peyronie's disease: a double-blind study. *J Urol* 1993;149:56-8.
  60. Jordan GH. The use of intralesional clostridial collagenase injection therapy for Peyronie's disease: a prospective, single-center, non-placebo-controlled study. *J Sex Med* 2008;5:180-7.
  61. Gelbard M, Lipshultz LI, Tursi J, Smith T, Kaufman G, Levine LA. Phase 2b study of the clinical efficacy and safety of collagenase Clostridium histolyticum in patients with Peyronie disease. *J Urol* 2012;187:2268-74.
  62. Gelbard M, Goldstein I, Hellstrom WJ, McMahon CG, Smith T, Tursi J, et al. Clinical efficacy, safety and tolerability of collagenase clostridium histolyticum for the treatment of peyronie disease in 2 large double-blind, randomized, placebo controlled phase 3 studies. *J Urol* 2013;190:199-207.
  63. Levine LA, Cuzin B, Mark S, Gelbard MK, Jones NA, Liu G, et al. Clinical safety and effectiveness of collagenase clostridium histolyticum injection in patients with Peyronie's disease: a phase 3 open-label study. *J Sex Med* 2015;12:248-58.
  64. Ziegelmann MJ, Viers BR, McAlvany KL, Bailey GC, Savage JB, Trost LW. Restoration of penile function and patient satisfaction with intralesional collagenase clostridium histolyticum injection for Peyronie's disease. *J Urol* 2016;195:1051-6.
  65. Lipshultz LI, Goldstein I, Seftel AD, Kaufman GJ, Smith TM, Tursi JP, et al. Clinical efficacy of collagenase Clostridium histolyticum in the treatment of Peyronie's disease by subgroup: results from two large, double-blind, randomized, placebo-controlled, phase III studies. *BJU Int* 2015;116:650-6.
  66. Abdel Raheem A, Capece M, Kalejaiye O, Abdel-Raheem T, Falcone M, Johnson M, et al. Safety and effectiveness of collagenase clostridium histolyticum in the treatment of Peyronie's disease using a new modified shortened protocol. *BJU Int* 2017. doi: 10.1111/bju.13932 [Epub].
  67. Yafi FA, Hatzichristodoulou G, Knoedler CJ, Trost LW, Sikka SC, Hellstrom WJ. Comparative analysis of tunical plication vs. intralesional injection therapy for ventral Peyronie's disease. *J Sex Med* 2015;12:2492-8.
  68. Yafi FA, Hatzichristodoulou G, DeLay KJ, Hellstrom WJ. Review of management options for patients with atypical Peyronie's disease. *Sex Med Rev* 2017;5:211-21.
  69. Milam D. 116. Positive results with collagenase clostridium histolyticum treatment in two patients with ventral penile curvature due to Peyronie's disease. *J Sex Med* 2016;13:S55.
  70. Stewart CA, Yafi FA, Knoedler M, Mandava SH, McCaslin IR, Sangkum P, et al. Intralesional injection of interferon- $\alpha$  2b improves penile curvature in men with Peyronie's disease independent of plaque location. *J Urol* 2015;194:1704-7.