

Lichen planus following tetanus–diphtheria–acellular pertussis vaccination: A case report and review of the literature

SAGE Open Medical Case Reports
Volume 6: 1–4
© The Author(s) 2018
Reprints and permissions:
sagepub.co.uk/journalsPermissions.nav
DOI: 10.1177/2050313X17750335
journals.sagepub.com/home/sco



Heather C Rosengard, Chikoti M Wheat, Matthew P Tilson
and Jonathan D Cuda

Abstract

Lichen planus is an inflammatory dermatosis with a prevalence of approximately 1%. Recent meta-analyses show that patients with hepatitis C virus have a 2.5- to 4.5-fold increased risk of developing lichen planus. Lichen planus has also followed vaccinations and has specifically been attributed to the hepatitis B vaccine, the influenza vaccine, and the tetanus–diphtheria–acellular pertussis vaccine. We describe a case of lichen planus in a hepatitis C virus–infected African American male occurring in temporal association with the administration of the tetanus–diphtheria–acellular pertussis vaccine. The patient's presentation was clinically consistent with lichen planus and confirmed by biopsy. It is likely that many cases of vaccine-induced lichen planus have gone unpublished or unrecognized. In areas with high prevalence of hepatitis C virus infection, we may expect to see more cases of vaccine-induced lichen planus especially in light of the updated Centers for Disease Control and Prevention tetanus–diphtheria–acellular pertussis vaccination recommendations. This case serves to educate healthcare providers about vaccine-induced lichen planus and, in particular, the need to counsel hepatitis C virus–infected patients about a potential risk of developing lichen planus following vaccination. We also reflect on current theories suggesting the T-cell–mediated pathogenesis of lichen planus and the role that hepatitis C virus and toxoid or protein vaccines may play in initiating the disease.

Keywords

Lichen planus, hepatitis C virus, tetanus–diphtheria–acellular pertussis vaccine, vaccine-induced lichen planus

Date received: 12 May 2017; accepted: 21 November 2017

Introduction

Lichen planus (LP) is an inflammatory mucocutaneous dermatosis with a prevalence of approximately 1%. While most patients diagnosed with LP are over 40 years of age, LP has also been reported in children. LP classically presents as pruritic, violaceous, polygonal flat-topped papules and plaques, although clinical manifestations vary depending on the subtype.¹ Histopathologic examination reveals a lichenoid infiltrate of CD4⁺ and CD8⁺ T cells with necrotic basal keratinocytes, suggesting an immune-mediated disease.¹ Recent meta-analyses show that patients with hepatitis C virus (HCV) have a 2.5- to 4.5-fold increased risk of developing LP.^{2,3} This association supports the hypothesis that the pathogenesis of LP is related to cell-mediated immunity and

may be initiated by HCV-specific T lymphocytes in patients infected with HCV.^{4,5}

LP has also been linked with vaccinations, although the specific causative component within these vaccines (i.e. the immunogenic material, the adjuvants, the stabilizers, or

Department of Dermatology, School of Medicine, The Johns Hopkins University, Baltimore, MD, USA

Corresponding Author:

Heather C Rosengard, Department of Dermatology, School of Medicine, The Johns Hopkins University, 1800 Orleans St, Baltimore, MD 21287, USA.

Email: hroseng1@jhmi.edu



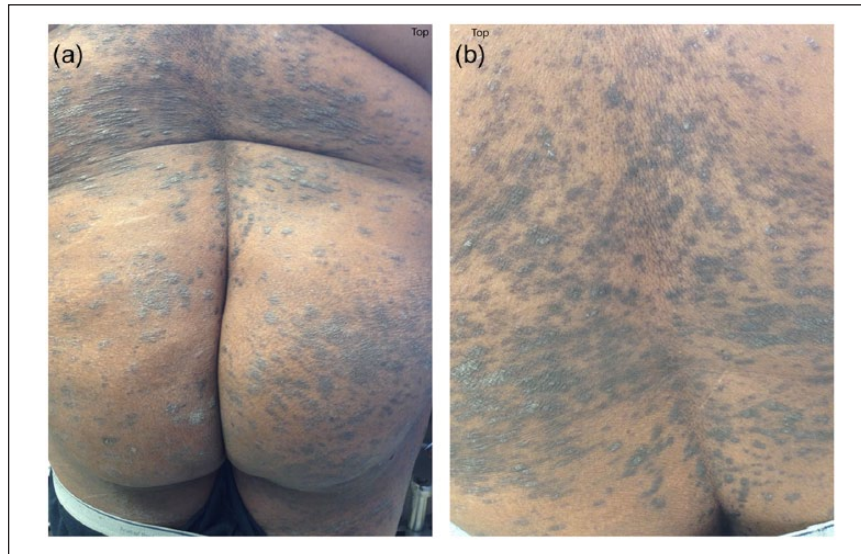

Figure 1. Discrete and coalescing polygonal-shaped, violaceous, flat-topped papules located on the trunk and extremities: (a) and (b) some lesions have a network of fine white lines, “Wickham striae.”

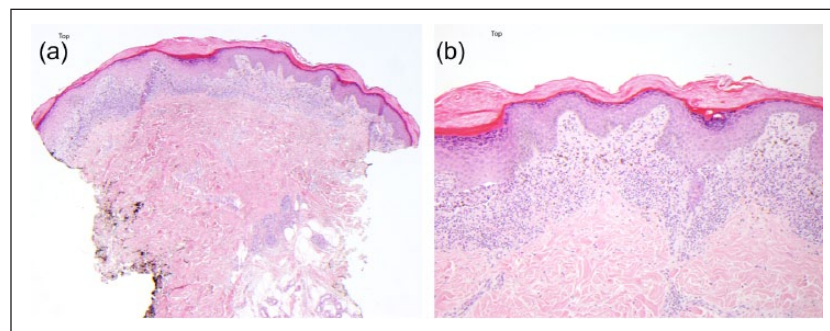


Figure 2. (a) H&E, original magnification 4 \times . (b) H&E, original magnification 10 \times . (a) and (b) Histologic images highlighting classic features of lichen planus including a lichenoid lymphocytic infiltrate, epidermal hyperkeratosis, hypergranulosis, basal vacuolar alteration, and Max Joseph spaces with colloid bodies and dermal melanophages.

the preservatives) has never been identified. The hepatitis B vaccine, both the primary and the booster, is the most commonly reported vaccine to be implicated in vaccine-induced LP.^{6–8} At least four cases of LP have been reported following administration of the influenza vaccine and two cases of LP have been reported following administration of the rabies vaccine.^{9–12} Immunizations against tetanus, diphtheria, and pertussis have been implicated in two reported cases of LP. One case occurred in a 6-year-old male following co-administration of the measles–mumps–rubella (MMR) and diphtheria–tetanus–pertussis–polio (DTaP-IPV) vaccines.¹³ Another case occurred in a 34-year-old male following administration of the tetanus–diphtheria–acellular pertussis (Tdap) vaccine.⁴ We report a second confirmed case of LP following administration of the Tdap vaccine.

Case Report

A 54-year-old African American male with chronic HCV presented to Johns Hopkins Dermatology with an intensely

pruritic rash on his hands, legs, and trunk of 4 weeks duration. The eruption began approximately 10 days after receiving the Tdap vaccine (Adacel[®]; Sanofi Pasteur, Swiftwater, PA, USA). On physical exam, he had violaceous, flat-topped, 3- to 6-mm discrete and coalescing papules on his dorsal hands, back, chest, abdomen, buttocks, and lower extremities (Figure 1(a) and (b)). Examination of buccal mucosal surfaces revealed slight hyperpigmentation without evidence of Wickham striae. There was no evidence of nail involvement.

A clinical diagnosis of LP was confirmed when punch biopsy of a representative skin lesion was obtained. Histopathology revealed a dense lichenoid infiltrate of lymphocytes with colloid bodies along the dermal–epidermal junction (Figure 2(a)). There was epidermal hyperplasia with orthokeratosis, focal hypergranulosis, and a saw-toothed rete-ridge pattern with Max Joseph spaces (Figure 2(b)). The patient’s daily medications included glimepiride 2 mg, metformin 500 mg, loratadine 10 mg, omeprazole 320 mg, simvastatin 40 mg, triamterene-hydrochlorothiazide 75-50 mg daily, ferrous sulfate 325 mg, methadone, and a fluticasone

inhaler 100 µg/actuation. As-needed medications included clonazepam 0.5 mg, oxycodone/acetaminophen, and an albuterol inhaler 90 µg/actuation. Laboratory testing revealed transaminase elevation (aspartate transaminase (AST): 79 U/L, alanine transaminase (ALT): 56 U/L), elevated alpha-2-macroglobulins (356 mg/dL), low apolipoprotein A-1 (81 g/L), low albumin (3.4 g/dL), and a microcytic anemia with low serum iron (24 µg/dL). Serum studies were positive for anti-HCV antibody and HCV RNA was elevated at 6.198 log IU/mL. HCV FibroSURE fibrosis score was 0.83 and necro-inflammatory activity score was 0.59, indicating fibrosis stage F4, cirrhosis, and moderate necroinflammatory activity. Rapid plasma reagin and human immunodeficiency virus were both negative.

The patient was treated with 60-mg intramuscular Kenalog and topical clobetasol 0.05% ointment. Significant improvement was noted on his 8-week follow-up visit.

Discussion

Localized non-specific injection site reactions are the most common adverse cutaneous manifestation of vaccinations, followed by systemic reactions to live attenuated virus and less commonly generalized hypersensitivity disorders.¹⁴ Lichenoid drug eruptions are commonly associated with a variety of medications. However, such reactions are not generally associated with vaccinations.

In 1990, the first case of LP following the hepatitis B virus (HBV) vaccination was reported.¹⁵ Since that time, there have been numerous case series documenting LP or LP-like eruptions following HBV vaccines in both the adult and the pediatric populations.⁶⁻⁸ The majority of patients presented with classic cutaneous LP, although some reports highlight primarily mucosal involvement. The latency period between administration of the HBV vaccine and clinical manifestation of LP has varied (between 1 and 180 days in one review).⁶ Patients who developed LP after their primary HBV immunization also had a shorter latency period following subsequent booster doses.⁶

Of the four published cases that linked LP to influenza vaccination, one patient was reported to have HCV antibodies. All four patients developed clinical manifestation of LP within 2 weeks of vaccination; three developed cutaneous eruptions, while one patient presented with oral LP.^{9,10} In the two published cases of LP that developed following rabies vaccine administration, neither patient had HCV antibodies nor mucosal involvement.^{11,12}

There are two reports of LP following immunization against diphtheria-tetanus-pertussis-containing vaccinations. The first is a case of a 6-year-old Finnish boy who developed cutaneous LP 1 week after co-administration of the MMR (Priorix; GlaxoSmithKline, Genval, Belgium) and DTap-IPV (Tetravac; Sanofi Pasteur MSD, Brussels, Belgium) vaccines.¹³ He had no laboratory testing performed at the time of diagnosis. In the second case, a 34-year-old American male presented with an eruption of LP 4 weeks

after receiving a single dose of the Tdap vaccine (Adacel).^{4,16} Laboratory serology was negative for HCV antibodies.

Similar to the patient reported by Ghasri et al., our patient was an adult male who received the Tdap vaccine (Adacel). Each 0.5-mL dose of Adacel contains diphtheria toxoid, tetanus toxoid, acellular pertussis antigens (pertactin, filamentous hemagglutinin, detoxified pertussis toxin, fimbriae) as well as aluminum phosphate, 2-phenoxyethanol, and residual amounts of formaldehyde and glutaraldehyde.¹⁶ Given the complex composition of the vaccine, the patient's LP may be due to a single ingredient or a combination of the ingredients in the vaccine.

In contrast to the patient reported by Ghasri et al., our patient was infected with HCV. The association between LP and HCV is well-documented, and a series of recent meta-analyses show an increased risk of LP in populations with HCV.^{2,3} Although HCV's role in the pathogenesis of LP has not been completely elucidated, numerous hypotheses have been proposed. LP is thought to be a manifestation of a T-cell-mediated immune phenomenon directed against basal keratinocytes. In patients with HCV, it has been postulated that the virus may act as a superantigen to activate self-reactive T cells or precipitate lymphocyte-induced basal cell damage following presentation of viral particles by Langerhans cells.¹⁷

In our patient, the temporal association between the Tdap vaccination and the onset of LP suggests Tdap-induced LP. While his underlying HCV infection may have played a pathogenic role, we believe the Tdap vaccine initiated the onset of LP in an already susceptible individual. As proposed by Sato et al.,¹⁰ vaccinations and the HCV virus may act synergistically to trigger LP. Of note, toxoid and protein vaccines (i.e. the Tdap vaccine), as well as inactivated viral vaccines (i.e. the influenza vaccine), induce higher-affinity antibodies and superior immune memory due to the T-dependent responses they elicit.¹⁸ Perhaps, in our patient, the T-cell-mediated anti-HCV immune response acted synergistically with the T-dependent response to the Tdap vaccine and manifested in the skin as LP. Of note, the Centers for Disease Control and Prevention (CDC) has updated their guidelines to recommend expanding the use of the Tdap vaccination.¹⁹ Therefore, in areas with a high prevalence of HCV infection, we may expect to see more cases of LP following administration of Tdap vaccine.

It is likely that many cases of vaccine-induced LP are misdiagnosed. For example, our patient initially presented to a local Emergency Department, where he was treated with intramuscular penicillin for presumed syphilis infection. We therefore hope that this case will serve to educate healthcare providers about vaccine-induced LP and, in particular, the need to counsel HCV-infected patients about the potential risks of immunization. Of course, given the rarity and relative ease of treatment of LP, we do not believe such risks outweigh the immense benefits of vaccinations. Rather, we hope that an awareness of vaccine-induced LP will enable its prompt diagnosis and treatment and thereby reduce the associated morbidity in our patients.

Declaration of conflicting interests

The author(s) declared no potential conflicts of interest with respect to the research, authorship, and/or publication of this article.

Ethical approval

Our institution does not require ethical approval for reporting individual cases or case series.

Funding

The author(s) received no financial support for the research, authorship, and/or publication of this article.

Informed consent

Written informed consent was obtained from the patients for their anonymized information to be published in this article.

References

1. Lehman JS and Gibson LE. Lichen planus. *Int J Dermatol* 2009; 48: 682–694.
2. Lodi G, Pellicano R and Carrozzo M. Hepatitis C virus infection and lichen planus: a systematic review with meta-analysis. *Oral Dis* 2010; 16(7): 601–612.
3. Shengyuan L, Songpo Y, Wen W, et al. Hepatitis C virus and lichen planus: a reciprocal association determined by a meta-analysis. *Arch Dermatol* 2009; 145(9): 1040–1047.
4. Ghasri P, Roehmholdt BF and Young LC. A case of lichen planus following Tdap vaccination. *J Drugs Dermatol* 2011; 10(9): 1067–1069.
5. Okuse C, Yotsuyanagi H and Koike K. Hepatitis C as a systemic disease: virus and host immunologic responses underlie hepatic and extrahepatic manifestations. *J Gastroenterol* 2007; 42(11): 857–865.
6. Calista D and Morri M. Lichen planus induced by hepatitis B vaccination: a new case and review of the literature. *Int J Dermatol* 2004; 43(8): 562–564.
7. Agrawal A and Shenoi SD. Lichen planus secondary to hepatitis B vaccination. *Indian J Dermatol Venereol Leprol* 2004; 70(4): 234–235.
8. Criado PR, Ramos RD, Vasconcellos C, et al. Two case reports of cutaneous adverse reactions following hepatitis B vaccine: lichen planus and granuloma annulare. *J Eur Acad Dermatol Venereol* 2004; 18(5): 603–606.
9. Akay BN, Arslan A, Cekirge S, et al. The first reported case of lichen planus following inactivated influenza vaccination. *J Drugs Dermatol* 2007; 6(5): 536–538.
10. Sato NA, Kano Y and Shiohara T. Lichen planus occurring after influenza vaccination: report of three cases and review of the literature. *Dermatology* 2010; 221(4): 296–299.
11. Ozbagcivan O, Akarsu S, Ilknur T, et al. Lichen planus after rabies vaccination. *Int J Dermatol* 2015; 54(12): e558–e559.
12. An I, Demir V, İbiloğlu I, et al. Lichen planus secondary to rabies vaccination. *Dermatol Online J* 2017; 23(3), <http://escholarship.org/uc/item/3hr3t4hs#page-3>
13. Tasanen K, Renko M, Kandelberg P, et al. Childhood lichen planus after simultaneous measles-mumps-rubella and diphtheria-tetanus-pertussis-polio vaccinations. *Br J Dermatol* 2008; 158(3): 646–648.
14. Rosenblatt AE and Stein SL. Cutaneous reactions to vaccinations. *Clin Dermatol* 2015; 33(3): 327–332.
15. Ciaccio M and Rebora A. Lichen-planus following HBV vaccination: a coincidence? *Br J Dermatol* 1990; 122(3): 424.
16. Pasteur S. Adacel (tetanus toxoid, reduced diphtheria toxoid, acellular pertussis) (package insert); 2005, <https://www.fda.gov/downloads/biologicsbloodvaccines/vaccines/approved-products/ucm142764.pdf>
17. Erkek E, Bozdogan O and Olut AI. Hepatitis C virus infection prevalence in lichen planus: examination of lesional and normal skin of hepatitis C virus-infected patients with lichen planus for the presence of hepatitis C virus RNA. *Clin Exp Dermatol* 2001; 26(6): 540–544.
18. Siegrist C. Vaccine immunology. In: Plotskin S, Orenstein W and Offit P (eds) *Vaccines*. 5th ed. Philadelphia, PA: Saunders Elsevier, 2008, pp. 17–36.
19. Centers for Disease Control and Prevention (CDC). Updated recommendations for use of tetanus toxoid, reduced diphtheria toxoid, and acellular pertussis (Tdap) vaccine in adults aged 65 years and older—Advisory Committee on Immunization Practices (ACIP), 2012. *MMWR Morb Mortal Wkly Rep* 2012; 61: 468–470.