

Hereditary diffuse gastric cancer: One family's story

Haley M Zylberberg, Keith Sultan, Steven Rubin

Haley M Zylberberg, Steven Rubin, Donald and Barbara Zucker School of Medicine at Hofstra/Northwell, Hempstead, NY 11549, United States

Keith Sultan, Division of Gastroenterology, Donald and Barbara Zucker School of Medicine at Hofstra/Northwell, Manhasset, NY 11030, United States

Steven Rubin, Donald and Barbara Zucker School of Medicine at Hofstra/Northwell, Merrick, NY 11566, United States

ORCID number: Haley M Zylberberg (0000-0002-4198-542X); Keith Sultan (0000-0002-7619-2024); Steven Rubin (0000-0001-8232-4807).

Author contributions: Zylberberg HM, Sultan K and Rubin S designed the report; Zylberberg HM and Rubin S collected the patient's clinical data; Zylberberg HM, Sultan K and Rubin S analyzed the data, drafted and edited the manuscript; all authors approve the final manuscript submitted and they approve the authorship list.

Informed consent statement: Informed consent was obtained from the patient by the article guarantor.

Conflict-of-interest statement: All authors declare that they have no conflicts of interest and nothing to declare.

Open-Access: This article is an open-access article which was selected by an in-house editor and fully peer-reviewed by external reviewers. It is distributed in accordance with the Creative Commons Attribution Non Commercial (CC BY-NC 4.0) license, which permits others to distribute, remix, adapt, build upon this work non-commercially, and license their derivative works on different terms, provided the original work is properly cited and the use is non-commercial. See: <http://creativecommons.org/licenses/by-nc/4.0/>

Manuscript source: Unsolicited manuscript

Correspondence to: Keith Sultan, MD, Assistant Professor, Division of Gastroenterology, Donald and Barbara Zucker School of Medicine at Hofstra/Northwell, 300 Community Dr., Manhasset, NY 11030, United States. ksultan@northwell.edu
Telephone: +1-516-3873990

Received: November 9, 2017

Peer-review started: November 9, 2017

First decision: November 30, 2017

Revised: December 8, 2017

Accepted: December 13, 2017

Article in press: December 13, 2017

Published online: January 16, 2018

Abstract

Hereditary diffuse gastric cancer (HDGC) is an inherited form of gastric cancer that carries a poor prognosis. Most HDGCs are caused by an autosomal dominant genetic mutation in the *CDH1* gene, which carries a 70%-80% lifetime risk of gastric cancer. Given its submucosal origin, endoscopic surveillance is an unreliable means of early detection, and prophylactic gastrectomy is recommended for *CDH1* positive individuals older than age 20 years. We describe the case of a male with recurrent gastric cancer who was diagnosed with HDGC secondary to the *CDH1* mutation, and we also describe the patient's pedigree and outcomes of recommended genetic testing.

Key words: Hereditary diffuse gastric cancer; Genetic testing; Genetic diseases; Gastric cancer; Lobular breast cancer; Inheritable diseases

© **The Author(s) 2018.** Published by Baishideng Publishing Group Inc. All rights reserved.

Core tip: Individuals who carry the *CDH1* gene mutation are at very high risk of acquiring hereditary diffuse gastric cancer, a cancer with a high mortality if not detected early. The clinical findings we describe in this case may aid medical practitioners in the assessment and testing of patients with a family history of gastric cancer and raise awareness about the importance of genetic testing for this condition.

Zylberberg HM, Sultan K, Rubin S. Hereditary diffuse gastric cancer: One family's story. *World J Clin Cases* 2018; 6(1): 1-5 Available from: URL: <http://www.wjgnet.com/2307-8960/full/v6/i1/1.htm> DOI: <http://dx.doi.org/10.12998/wjcc.v6.i1.1>

INTRODUCTION

Gastric cancer is the fifth most common cancer and the third leading cause of cancer related death worldwide^[1]. While most gastric cancers occur from sporadic mutations, inherited gastric cancers make up 1%-3% of cases and are referred to as Hereditary Diffuse Gastric Cancers (HDGC)^[2]. The majority of HDGCs are caused by an autosomal dominant inheritance of an abnormal copy of the tumor suppressor gene *CDH1*. As the *CDH1* gene has a high penetrance, mutations produce a multi-generational cancer syndrome that affects multiple organs^[2]. The *CDH1* gene mutation causes a 70%-80% life time risk of gastric cancer in both men and women and a 40%-60% life time risk of lobular breast cancer^[2,3]. Unfortunately, detection based on gastrointestinal symptoms and endoscopic surveillance has a poor prognosis. Therefore, the International Gastric Cancer Linkage Consortium (IGCLC) recommends prophylactic gastrectomy in individuals with the *CDH1* gene mutation between ages 20 to 30^[2]. It is therefore imperative that patients with a family history of gastric cancer have a comprehensive family pedigree reviewed and undergo genetic testing for the presence of HDGC if they fit the criteria proposed by the IGCLC.

In this report, we describe the case of a Caucasian male who was found to have the *CDH1* gene mutation and diagnosed with HDGC. We also describe the results of his family members' genetic testing.

CASE REPORT

At age 49, the patient presented with abdominal fullness and was found to have gastric signet ring adenocarcinoma, and was treated with a partial gastrectomy (Billroth II). The patient had no evidence of metastatic disease at this time as evidenced by normal CT scans. The patient subsequently underwent triennial esophago-gastroduodenoscopies (EGD) for surveillance of cancer recurrence. In 2012, at the age of 58, a surveillance EGD was performed with random biopsies taken from normal appearing mucosa in the gastric cardia, fundus, distal body, and anastomosis site. Only the biopsy from the distal gastric body revealed adenocarcinoma with signet cells; all other biopsy specimens were negative for cancer related pathology. Endoscopic ultrasound was performed and did not reveal any submucosal or mucosal aberrations. PET/CT showed no areas of increased activity suggestive of metastatic disease.

Family history revealed that the patient's mother was diagnosed with gastric cancer at age 59, when the

patient was 17, and subsequently died from metastatic disease (Figure 1). The patient's identical twin sisters were both diagnosed with gastric cancer at age 38, and died shortly thereafter.

The patient underwent total gastrectomy, with lymph node sampling. The pathologic specimen showed a 0.6-cm tumor in the lesser curvature of the stomach with invasion into the lamina propria. Histologic analysis showed a poorly differentiated signet ring cell carcinoma (Figure 2), grade 3. Immunohistochemical stains for mucicarmine and keratin AE1/AE3 highlighted the signet ring cell carcinoma. No additional staining was performed. All 16 sampled lymph nodes were negative for pathology, and staging was deemed T1a.

The patient underwent a gene panel for known mutations linked to gastrointestinal cancers. The DNA sampled was from the patient's lymphocytes and next-generation sequencing was used. The patient tested positive for the *CDH1* gene with aberration in the c.521 dvpA and the *STK11* gene had a mutation of unknown significance with aberration in p.5354L. Testing for lynch syndrome and familial adenomatous polyposis syndrome were negative. Given the defined mutation, and with the patient's encouragement, many of the patient's family members underwent genetic testing.

The patient's pedigree is shown in Figure 1. In total, 21 of the patient's relatives underwent genetic testing, of which 12 were found to have the *CDH1* gene mutation, including two of the patient's sons. Of these 12 relatives, 8 underwent prophylactic gastrectomy, despite having no concerning gastrointestinal symptoms. At the time of gastrectomy all 8 family members had evidence of gastric cancer when pathological specimens were histologically analyzed.

DISCUSSION

HDGC, unlike the sporadic forms of gastric cancer, is composed of signet ring cells and originates diffusely throughout the gastric submucosa^[4-6]. The sporadic form of gastric cancer is usually associated with *Helicobacter pylori* infection, which can lead to gastric atrophy and intestinal metaplasia^[4,5,7,8]. Often with *Helicobacter pylori* associated gastric cancer, cells are arranged in a gland-like formation and begin in the mucosa^[4,5,7,8]. As occurred in this case, the cancer found in HDGC related cases is usually poorly differentiated, which is a direct result of the *CDH1* gene mutation. The *CDH1* gene, located on chromosome 16, codes for E-cadherin, a calcium dependent cellular adhesion protein that is instrumental in maintaining epithelial cell structural integrity^[2,5,6]. When this gene is mutated, the decreased E-cadherin expression promotes atypical cellular architecture and irregular cell growth, ultimately leading to cancer development^[2,5,6].

The mutation in the *CDH1* gene can occur sporadically or can be inherited through an autosomal dominant inheritance pattern. The *CDH1* gene is a tumor suppressor gene and thereby requires a second hit,

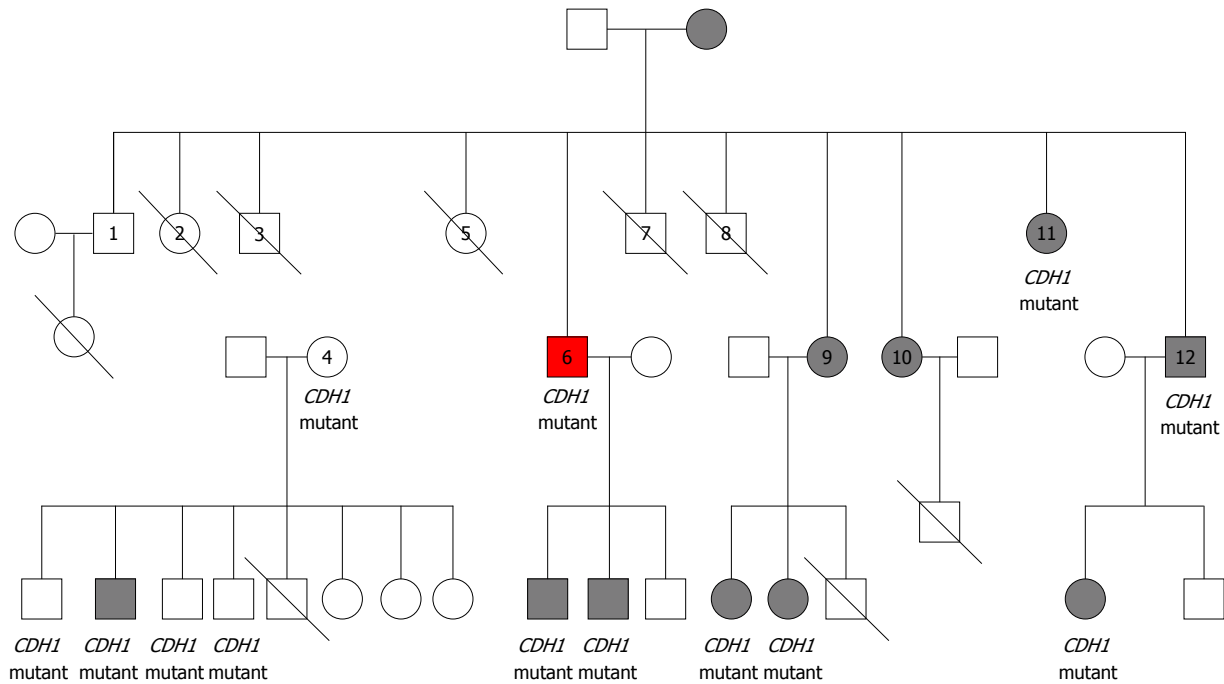


Figure 1 Family pedigree. Shading indicates presence of diagnosed HDGC. Strike through represents negative testing for the *CDH1* gene mutation. Red square represents our patient.

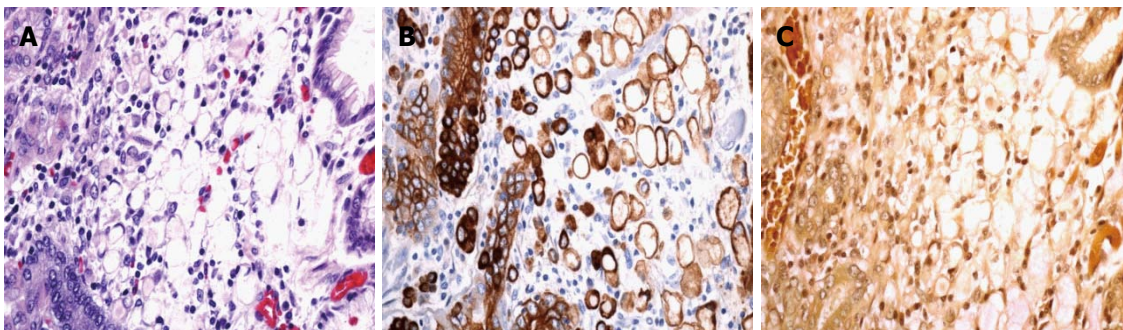


Figure 2 Histology of the gastric lamina propria showing signet ring cells. A: HE stain ($\times 200$); B: Cytokeratin AE1.3 antibody staining showing the presence of keratin ($\times 200$); C: Mucicarmine stain showing the presence of mucin ($\times 200$).

a somatic mutation in the second E-cadherin allele, in order to cause cancer progression. In individuals with germline mutations of *CDH1*, the second hit has been shown to occur mostly through *CDH1* promoter hypermethylation, with fewer instances of loss of heterozygosity^[9,10]. One study found that no additional somatic mutations beyond promoter hypermethylation in those with germline *CDH1* mutations were required for cancer formation^[9].

Because HDGC originates as discrete foci in the gastric submucosa, it produces no grossly visible architectural changes^[2,6]. The presence of cancer as a result is hidden in its early stages on endoscopy and nearly impossible to detect with sampling by random biopsies^[2,6]. Currently there is a lack of evidence regarding the timing of metastatic signet ring gastric carcinoma, though evidence suggests that there may be a dormant period before metastasis^[11,12]. The progression of diffuse gastric cancer seems to be particularly aggressive in

young individuals, as only 10% of those under age 40 who develop symptomatic and invasive diffuse gastric cancer have curable disease^[12,13]. Thus the IGCLC recommends that individuals with the *CDH1* gene mutation, even without evidence of gastric cancer, undergo prophylactic total gastrectomy between ages 20 to 30 years, rather than surveillance endoscopy^[2] (Table 1). If a person is unwilling to undergo prophylactic gastrectomy, the IGCLC recommends intensive endoscopic surveillance at an expert center^[2]. Other means of early cancer detection have also been met with limited success; PET imaging has a high rate of false negatives in mucinous cancers, such as occurs in HDGC^[14].

Given the low yield of random biopsies and the negative PET scan, our patient was highly fortunate that the random biopsy taken in the distal gastric body revealed the presence of cancer. This is especially lucky given the patient's intact gastric mucosal appearance

Table 1 *CDH1* related cancer risks and International Gastric Cancer Linkage Consortium 8th workshop management recommendations

	Gastric cancer	Lobular breast cancer	Colon cancer
Lifetime cancer risk	80%	60%	Unknown
Surveillance	EGD surveillance in persons not willing to undergo prophylactic gastrectomy If <i>CDH1</i> + with no evidence of cancer, EGD surveillance, usually starting at age 16 until time of prophylactic gastrectomy per IGCLC 7 guideline ^[11]	Annual clinical breast exams Bilateral breast MRI starting at age 30	Colon cancer screening in HDGC families with colon cancer from age 40 or 10 yr younger than the youngest diagnosis of colon cancer Repeat colonoscopy at 3-5 yr intervals per IGCLC 7 guidelines ^[11]
Therapy	Suggest prophylactic gastrectomy between age 20-30 if <i>CDH1</i> + without evidence of cancer Suggests gastrectomy if evidence of cancer regardless of age	Prophylactic mastectomy not recommended, but may be considered on case by case basis	Not available

EGD: Esophagogastroduodenoscopies; HDGC: Hereditary diffuse gastric cancer; IGCLC: International Gastric Cancer Linkage Consortium.

on endoscopy and the normal biopsies taken in the other gastric locations. At the time of gastrectomy, our patient's cancer was staged a T1. Thus, our patient's cancer was effectively caught early, before it metastasized. Furthermore, the 70%-80% penetrance^[2] of the *CDH1* mutation coupled with the patient's diagnosis of gastric cancer 10 years prior and the death of 3 family members due to metastatic gastric carcinoma, suggest that the patient's cancer would have ultimately progressed if it had been left undetected.

Due to the difficulty in early detection, the high penetrance of the *CDH1* gene, and the early onset of incurable disease, genetic testing is the only beneficial means of detecting and preventing HDGC in individuals with a family history. The IGCLC therefore recommends *CDH1* genetic testing in all individuals who meet one of the following criteria: 2 or more cases of gastric cancer in a family with 1 confirmed diffuse type in 1st or 2nd degree relatives independent of age, presence of diffuse gastric cancer in an individual less than age 50, and personal or family history of diffuse gastric cancer and lobular breast cancer with one of the diagnoses before age 50^[2]. Genetic testing may also be considered in individuals with bilateral lobular breast cancer under the age of 50 or in families with multiple members with lobular breast cancer (with two of these relatives younger than 50 years)^[2]. As the *CDH1* gene mutation has also been linked to cleft lip and palate, the IGCLC suggests that genetic testing may be considered in families with a history of cleft lip/palate and diffuse gastric cancer^[2].

Given the risk of lobular breast cancer, the IGCLC recommends breast screening from age 30 (composed of annual clinical breast exams and bilateral MRIs)^[2]. The IGCLC does not recommend prophylactic mastectomy in individuals with the *CDH1* mutation, though suggests that mastectomy can be considered on a case by case basis^[2]. Colon cancer screening is recommended only in families with HDGC related colon cancer starting at age 40 or 10 years younger than the affected individual^[2].

At the time of initial diagnosis of gastric cancer, our patient had 3 first-degree relatives who had already succumbed to metastatic disease. However, these 3 relatives died prior to the discovery of the *CDH1* gene mutation in 1998^[15] and were thus unable to undergo genetic testing. While our patient was initially diagnosed with gastric cancer in 2003, the expense of genetic testing and the lack of availability of genetic testing in office based medical practices precluded our patient from undergoing gene analysis. By the time of our patient's cancer recurrence in 2012, the widespread availability of genetic testing allowed our patient to undergo screening and also encourage screening in his family members. By doing so, the patient prompted life saving measures in his family: the *CDH1* gene mutation was detected in 12 relatives and evidence of histological gastric cancer was detected in 8 relatives who underwent prophylactic gastrectomy. This case highlights the importance of gathering a thorough family history, especially as it relates to gastric cancer, and encouraging genetic testing in patients who meet the IGCLC criteria. This case also emphasizes the benefit of affordable and available genetic testing and the need to make genetic testing available for office based practices.

ARTICLE HIGHLIGHTS

Case characteristics

A 58-year-old male with a past medical history of gastric signet ring adenocarcinoma, treated with partial gastrectomy, presenting to our practice for triennial esophagogastroduodenoscopies (EGD) for surveillance of cancer recurrence. Patient's family history was significant for 3 first degree relatives with gastric cancer. EGD performed showed normal appearing mucosa, though biopsy from the distal gastric body revealed adenocarcinoma with signet cells.

Clinical diagnosis

Patient was asymptomatic at diagnosis.

Differential diagnosis

The differential diagnosis included spontaneous gastric cancer recurrence or a hereditary gastric cancer syndrome.

Laboratory diagnosis

The patient underwent a gene panel for known mutations linked to gastrointestinal cancers. The patient tested positive for a mutation in the *CDH1* gene which confirmed the presence of hereditary diffuse gastric cancer.

Imaging diagnosis

Endoscopic ultrasound revealed no submucosal or mucosal aberrations. PET/CT imaging revealed no abnormalities suggestive of metastatic disease.

Pathological diagnosis

Examination of the pathologic specimen after total gastrectomy, confirmed a 0.6-cm poorly differentiated signet ring cell carcinoma in the lesser curvature of the stomach with invasion into the lamina propria.

Treatment

The patient underwent total gastrectomy. The patient encouraged genetic testing in his 21 family members, of which 12 were found to have the *CDH1* gene mutation.

Related reports

There are currently other case reports of families with the *CDH1* gene mutation, though none with as extensive a family pedigree.

Term explanation

HDGC is an inherited form of gastric cancer, with majority caused by an autosomal dominant genetic mutation in the *CDH1* gene.

Experiences and lessons

This case highlights the importance of gathering a thorough family history, especially as it relates to gastric cancer, and encouraging genetic testing in patients who meet the International Gastric Cancer Linkage Consortium criteria.

REFERENCES

- 1 **International Agency for Research on Cancer.** Globocan 2012. Accessed October 13, 2013. Available from: URL: http://globocan.iarc.fr/Pages/fact_sheets_cancer.aspx
- 2 **van der Post RS, Vogelaar IP, Carneiro F, Guilford P, Huntsman D, Hoogerbrugge N, Caldas C, Schreiber KE, Hardwick RH, Ausems MG, Bardram L, Benusiglio PR, Bisseling TM, Blair V, Bleiker E, Boussioutas A, Cats A, Coit D, DeGregorio L, Figueiredo J, Ford JM, Heijkoop E, Hermens R, Humar B, Kaurah P, Keller G, Lai J, Ligtenberg MJ, O'Donovan M, Oliveira C, Pinheiro H, Ragnath K, Rasenberg E, Richardson S, Roviello F, Schackert H, Seruca R, Taylor A, Ter Huurne A, Tischkowitz M, Joe ST, van Dijk B, van Grieken NC, van Hillegersberg R, van Sandick JW, VEHOF R, van Krieken JH, Fitzgerald RC.** Hereditary diffuse gastric cancer: updated clinical guidelines with an emphasis on germline *CDH1* mutation carriers. *J Med Genet* 2015; **52**: 361-374 [PMID: 25979631 DOI: 10.1136/jmedgenet-2015-103094]
- 3 **Lynch HT, Kaurah P, Wirtzfeld D, Rubinstein WS, Weissman S, Lynch JF, Grady W, Wyrick S, Senz J, Huntsman DG.** Hereditary diffuse gastric cancer: diagnosis, genetic counseling, and prophylactic total gastrectomy. *Cancer* 2008; **112**: 2655-2663 [PMID: 18442100 DOI: 10.1002/cncr.23501]
- 4 **Shah MA, Khanin R, Tang L, Janjigian YY, Klimstra DS, Gerdes H, Kelsen DP.** Molecular classification of gastric cancer: a new paradigm. *Clin Cancer Res* 2011; **17**: 2693-2701 [PMID: 21430069 DOI: 10.1158/1078-0432.CCR-10-2203]
- 5 **van der Woude CJ, Kleibeuker JH, Tiebosch AT, Homan M, Beuving A, Jansen PL, Moshage H.** Diffuse and intestinal type gastric carcinomas differ in their expression of apoptosis related proteins. *J Clin Pathol* 2003; **56**: 699-702 [PMID: 12944556 DOI: 10.1136/jcp.56.9.699]
- 6 **Onitilo AA, Aryal G, Engel JM.** Hereditary diffuse gastric cancer: a family diagnosis and treatment. *Clin Med Res* 2013; **11**: 36-41 [PMID: 22723466 DOI: 10.3121/cm.2012.1071]
- 7 **Adachi Y, Yasuda K, Inomata M, Sato K, Shiraishi N, Kitano S.** Pathology and prognosis of gastric carcinoma: well versus poorly differentiated type. *Cancer* 2000; **89**: 1418-1424 [PMID: 11013353 DOI: 10.1002/1097-0142(20001001)89:7<1418::AID-CNCR2>3.0.CO;2-A]
- 8 **Van Cutsem E, Sagaert X, Topal B, Haustermans K, Prenen H.** Gastric cancer. *Lancet* 2016; **388**: 2654-2664 [PMID: 27156933 DOI: 10.1016/S0140-6736(16)30354-3]
- 9 **Grady WM, Willis J, Guilford PJ, Dunbier AK, Toro TT, Lynch H, Wiesner G, Ferguson K, Eng C, Park JG, Kim SJ, Markowitz S.** Methylation of the *CDH1* promoter as the second genetic hit in hereditary diffuse gastric cancer. *Nat Genet* 2000; **26**: 16-17 [PMID: 10973239 DOI: 10.1038/79120]
- 10 **Machado JC, Oliveira C, Carvalho R, Soares P, Bex G, Caldas C, Seruca R, Carneiro F, Sobrinho-Simões M.** E-cadherin gene (*CDH1*) promoter methylation as the second hit in sporadic diffuse gastric carcinoma. *Oncogene* 2001; **20**: 1525-1528 [PMID: 11313896 DOI: 10.1038/sj.onc.1204234]
- 11 **Fitzgerald RC, Hardwick R, Huntsman D, Carneiro F, Guilford P, Blair V, Chung DC, Norton J, Ragnath K, Van Krieken JH, Dwerryhouse S, Caldas C; International Gastric Cancer Linkage Consortium.** Hereditary diffuse gastric cancer: updated consensus guidelines for clinical management and directions for future research. *J Med Genet* 2010; **47**: 436-444 [PMID: 20591882 DOI: 10.1136/jmg.2009.074237]
- 12 **Barber M, Murrell A, Ito Y, Maia AT, Hyland S, Oliveira C, Save V, Carneiro F, Paterson AL, Grehan N, Dwerryhouse S, Lao-Sirieix P, Caldas C, Fitzgerald RC.** Mechanisms and sequelae of E-cadherin silencing in hereditary diffuse gastric cancer. *J Pathol* 2008; **216**: 295-306 [PMID: 18788075 DOI: 10.1002/path.2426]
- 13 **Koea JB, Karpeh MS, Brennan MF.** Gastric cancer in young patients: demographic, clinicopathological, and prognostic factors in 92 patients. *Ann Surg Oncol* 2000; **7**: 346-351 [PMID: 10864341 DOI: 10.1007/s10434-000-0346-9]
- 14 **Berger KL, Nicholson SA, Dehdashti F, Siegel BA.** FDG PET evaluation of mucinous neoplasms: correlation of FDG uptake with histopathologic features. *AJR Am J Roentgenol* 2000; **174**: 1005-1008 [PMID: 10749239 DOI: 10.2214/ajr.174.4.1741005]
- 15 **Guilford P, Hopkins J, Harraway J, McLeod M, McLeod N, Harawira P, Taite H, Scouler R, Miller A, Reeve AE.** E-cadherin germline mutations in familial gastric cancer. *Nature* 1998; **392**: 402-405 [PMID: 9537325 DOI: 10.1038/32918]

P- Reviewer: Economescu MCC, Tanabe S **S- Editor:** Gong ZM
L- Editor: A **E- Editor:** Li RF





Published by **Baishideng Publishing Group Inc**
7901 Stoneridge Drive, Suite 501, Pleasanton, CA 94588, USA
Telephone: +1-925-223-8242
Fax: +1-925-223-8243
E-mail: bpgoffice@wjgnet.com
Help Desk: <http://www.f6publishing.com/helpdesk>
<http://www.wjgnet.com>

