

Haploidentical hematopoietic stem cell transplantation in a myelofibrosis patient with primary graft failure

Cristina Tecchio,¹ Angelo Andreini,¹ Claudio Costantini,¹ Alberto Zamò,² Donata de Sabata,¹ Fiorenza Aprili,³ Roberta Galavotti,⁴ Emanuele Guardalben,¹ Fabio Benedetti¹

¹Section of Hematology and Bone Marrow Transplant Unit, Department of Medicine, ²Section of Pathology and Diagnostics, Department of Pathology, ³Clinical Biochemistry Laboratory, Department of Life and Reproduction Sciences, ⁴Section of Biology and Genetics, Department of Mother and Child, University of Verona, Italy

Abstract

The prognosis of patients affected by myelofibrosis (MF) is usually dismal and allogeneic hematopoietic stem cell transplantation (HSCT) remains the only cure. The number of HSCTs in MF patients has recently increased. However, a major obstacle is still represented by primary graft failure (PGF). Currently there are no definitive guidelines for the treatment of PGF and a second HSCT can be performed only when an allogeneic donor is rapidly available. Herein we report on a MF patient with PGF after an unrelated HSCT, who was rescued by a non-myeloablative, unmanipulated, haploidentical HSCT that resulted in persistent engraftment and bone-marrow fibrosis regression, but not in a long-term disease control. Based on this experience we briefly review the role of different conditioning regimens and hematopoietic stem cell sources in the setting of HSCT for MF patients with PGF. The role of haploidentical donors in MF patients lacking HLA-matched relatives is also discussed.

Introduction

Myelofibrosis (MF) is a pathological condition caused by the clonal proliferation of a pluripotent stem cell. It is characterized by a deregulated kinase signaling, and an abnormal release of cytokines, the latter being responsible for the induction of bone-marrow (BM) fibrosis.¹ MF is associated with three main driver mutations namely the *V617F* mutation of the Janus Kinase 2

(*JAK2*) gene (in ~60% of cases), and mutations of the calreticulin (*CARL*) and the myeloproliferative leukemia protein (*MPL*) genes (in ~30% and 8% of cases, respectively).^{1,2} MF can arise *de novo* as primary myelofibrosis (PMF) or following essential thrombocythemia or polycythemia vera. Clinical presentation of MF includes blood cytopenia, leukoerithroblastosis, extramedullary hematopoiesis, progressive splenomegaly, and systemic symptoms.³ In spite of the recent developments of targeted therapies (e.g., *JAK1/2* inhibitors), the prognosis of MF patients is usually dismal and the allogeneic hematopoietic stem cell transplantation (HSCT) remains the only cure.³ Improvements in patient selection, conditioning strategies and timing, have recently contributed to increase the number of HSCTs in MF patients.⁴ However, one of the major obstacles for a successful HSCT is represented by primary graft failure (PGF), which has been reported in 2% to 25% of MF patients.¹

PGF is caused by the absence of an initial cell donor engraftment and is defined as the persistence of severe neutropenia together with red blood cells and platelets transfusion dependence after the HSCT conditioning. It is associated with a considerable morbidity and mortality, mainly driven by severe infections. A number of factors contribute to PGF, including hematopoietic stem cell (HSC) source, conditioning regimen, HLA disparity, ABO mismatches, and infections.⁵ In myeloproliferative neoplasms possible causes of PGF may also include a defective BM stroma, splenic consumption of infused HSCs and allo-immunization following multiple transfusions.⁵ In MF patients increased levels of plasma cytokines (mostly *TNF-α*) may also exert a cytotoxic activity against HSCs.¹

Worthy of note BM fibrosis has not been clearly proven to correlate with PGF, but rather a consequence of an altered cytokine milieu able to reverse upon the replacement of the abnormal hematopoietic system.⁶ In the absence of definitive guidelines for the treatment of PGF patients may undergo a second HSCT, which can be performed using the same or another allogeneic donor when available.

Case Report

A 54-year-old woman was referred to our Institution on December 2012 with painful splenomegaly and systemic symptoms. Blood tests showed leukocytosis ($24 \times 10^9/L$) and thrombocytopenia ($97 \times 10^9/L$). The circulating CD34+ cells

Correspondence: Cristina Tecchio, Department of Medicine, Hematology and Bone Marrow Transplant Unit, University of Verona, Piazzale L.A. Scuro 10, 37134 Verona, Italy.
Tel.: +39.045.8124902 - Fax: +39.045.8124104.
E-mail: cristina.tecchio@univr.it

Key words: primary graft failure, haploidentical hematopoietic stem cell transplantation, myelofibrosis.

Contributions: FB, CT, AA, and EG planned the treatment schedule; AZ, DdS, FA and RG performed the research; CT and CC wrote the paper.

Conflict of interest: the authors declare no potential conflict of interest.

Received for publication: 13 February 2017.
Revision received: 6 October 2017.
Accepted for publication: 13 October 2017.

This work is licensed under a Creative Commons Attribution-NonCommercial 4.0 International License (CC BY-NC 4.0).

©Copyright C. Tecchio et al., 2017
Licensee PAGEPress, Italy
Hematology Reports 2017; 9:7091
doi:10.4081/hr.2017.7091

were 2.4%. The BM aspirate was not evaluable due to the poor cellularity, while the BM biopsy was consistent with PMF. The karyotype was normal and the molecular analysis revealed the presence of the *JAK2 V617F* mutation. The patient was diagnosed with an intermediate-1 PMF according to the International Prognostic Scoring System.⁷ She was first treated with hydroxyurea, then with ruxolitinib, which became available in our Institution starting from February 2013. In spite of an initial reduction of the spleen size and the remission of the systemic symptoms, on May 2014 ruxolitinib was withdrawn due to the reappearance of both painful splenomegaly and systemic symptoms, and the patient underwent splenectomy followed by treatment with hydroxyurea.

Although the Dynamic International Prognostic Scoring System (DIPSS) score was now intermediate-2,⁸ the HSCT was not performed because the only patient's brother was HLA haploidentical and no unrelated donors were unavailable. A few months later, a 10/12 matched male donor (antigen mismatch in DPB1) was identified and a peripheral blood hematopoietic stem cell (PBSC) HSCT could be scheduled. Patient and donor differed in AB blood group systems and CMV serostatus (B+ vs

A+, CMV IgG positive vs negative). The BM biopsy done before the HSCT was revealing that the patient's BM had a diffuse and intense fibrosis (Figure 1).⁹ At that time the DIPSS score was still intermediate-2, and the HSCT-comorbidity index was low.¹⁰ The HSCT was finally administered on March 2015 with a myeloablative conditioning consisting of busulfan (16 mg/kg i.v.) and cyclophosphamide (120 mg/kg i.v.). The patient received 10.66×10^6 /kg CD34+ cells, while the CD3+ cells infused were 24.47×10^6 /kg. Graft-versus-host disease (GVHD) prophylaxis included rabbit antithymocyte globulins, cyclosporine and short course methotrexate. In spite of the high number of CD34+ cells infused, on day +28 the patient was diagnosed with PGF. At that time an empirical antibacterial and antimycotic therapy was being delivered due to a persistent fever and the CT-scan evidence of a single excavated lesion of 5-6 cm on the upper lobe of the left lung in the absence of galactomannan positivity.

The urgent requirement for a new donor and the rapid worsening of the patient's clinical condition (ECOG3) prompted us to schedule as a salvage treatment a PBSC HSCT from the haploidentical brother, who was AB0-mismatched (A+) and CMV IgG positive. Therefore, on day +37 from the first HSCT, the patient received 6×10^6 /kg CD34+ and 32.6×10^7 /kg CD3+ cells from the brother, following a conditioning regimen consisting of only fludarabine (30 mg/m² day for 3 days). On day +3 after the haploidentical HSCT the patient underwent cyclophosphamide (50 mg/kg i.v.) and starting from day +4 cyclosporine and mycophenolate mofetil as GVHD prophylaxis. G-CSF was given from day +5 and it was stopped on day +13, when the engraftment was documented. Starting from the same time the patient presented a grade II skin GVHD that required steroid therapy until day +49. Following the haploidentical HSCT, the BM aspirate was performed on day +21, +90, and +180, showing a full-donor chimerism by either fluorescence *in*

situ hybridization with sex chromosome-specific DNA probes, and variable number tandem repeats analysis. Worthy of note, the BM biopsies performed on day +90 and +180 showed a progressive reduction of BM fibrosis as shown in Figure 1.

Importantly, the excavated lesion of the left lung was progressively decreasing and no GVHD was observed.

Unfortunately, on day +290 a relapse of disease was documented and the patient died of pulmonary infection few months later while in palliative treatment.

Discussion

The immediate availability of new donors for patients experiencing PGF is of critical importance and in this perspective the use of related haploidentical donors may offer obvious advantages. However, the new conditioning regimen together with the increased immunosuppression required to overcome HLA disparity, may cause severe organ toxicities and infections. Recent reports have shown that haploidentical HSCT, either T-cell depleted,^{11,12} or unmanipulated,¹³⁻¹⁷ usually preceded by reduced intensity conditioning (RIC), can be safely and effectively administered to patients with PGF. However, the patients described in the aforementioned reports were mainly affected by acute or chronic myeloid leukemia, juvenile myelomonocytic leukemia, or myelodysplastic syndrome.¹¹⁻¹⁷

To the best of our knowledge, the successful administration of unmanipulated haploidentical HSCTs has been previously described only in two MF patients with a follow-up of 30 and 11.5 months respectively, who had reported a PGF after an unrelated HLA full-matched RIC-HSCT.¹⁴ In both cases the 1-day conditioning regimen was composed of 30 mg/m² fludarabine, 2 g/m² cyclophosphamide, 20 mg alemtuzumab i.v., and 200 cGy total body

irradiation, based on the assumption that the first preparative regimen might have already suppressed the recipient's immune systems. As for our patient, the conditioning scheme initially scheduled,¹⁸ actually included only fludarabine (30 mg/m² for 3 days) given the poor patient's clinical status and the lack of any residual hematopoiesis at the BM biopsy of day +28 (not shown). Moreover, in contrast to the original schedule,¹⁸ we infused PBSCs instead of BM, due to the need of a rapid engraftment. Interestingly, in agreement with a recent study demonstrating a better outcome for PGF patients receiving PBSCs as compared to other stem cell sources,¹⁹ most of the PGF patients who underwent a haploidentical HSCT also received PBSCs.¹³⁻¹⁷

Worthy of note, in our patient the engraftment paralleled the progressive regression of BM fibrosis (Figure 1), therefore confirming previous experiences evidencing that a high fibrosis grading is not a major obstacle to HSCT in MF patients, but instead a dynamic process largely dependent on the microenvironment.⁶

As for our patient, the haploidentical HSCT was able to overcome the PGF and to reduce the BM fibrosis. However it turned out to be ineffective against the long-term control of the disease, thus suggesting that the conditioning regimen delivered and/or the transplant-related immune-mediated effect, were not capable of eradicating the disease.

Conclusions

Overall, given the limits of a single experience, this clinical case indicates that the unmanipulated haploidentical HSCT may be effective in rescuing MF patients from PGF. In addition, the higher number of PGF observed in patients undergoing unrelated HSCT,¹⁹ together with the difficulties of delivering a new conditioning regimen, support recent data indicating that the hap-

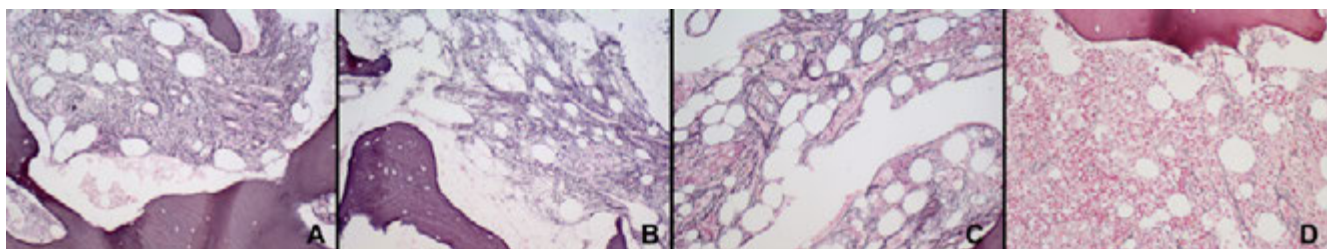


Figure 1. Grading of bone-marrow fibrosis (MF) according to the WHO guidelines using the Gomori stain. MF was evaluated: A) before the unrelated allogeneic HSCT, B) before the haploidentical HSCT, C) on day +90 and D) on day +180 following the haploidentical HSCT. Final magnification 200 \times .

loidentical donor may be a reasonable first option for MF patients lacking a HLA-matched relative.²⁰ We are aware that only prospective studies aimed at comparing the outcome of recipients of conventional *versus* alternative donors will definitively establish the role of haploidentical HSCT in MF patients.

References

- Cervantes F. How I treat myelofibrosis. *Blood* 2014;124:2635-42.
- Tefferi A, Vannucchi AM. Genetic risk assessment in myeloproliferative neoplasms. *Mayo Clin Proc* 2017;92:1283-90.
- Gupta V, Gotlib J, Radich JP, et al. Janus kinase inhibitors and allogeneic stem cell transplantation for myelofibrosis. *Biol Blood Marrow Transplant* 2014;20:1274-81.
- Kroger NM, Deeg JH, Olavarria E, et al. Indication and management of allogeneic stem cell transplantation in primary myelofibrosis: a consensus process by an EBMT/ELN international working group. *Leukemia* 2015;29: 2126-33.
- Olsson RF, Logan BR, Chaudhury S, et al. Primary graft failure after myeloablative allogeneic hematopoietic cell transplantation for hematologic malignancies. *Leukemia* 2015;29:1754-62.
- Kroger N, Kvasnicka M, Thiele J. Replacement of hematopoietic system by allogeneic stem cell transplantation in myelofibrosis patients induces rapid regression of bone marrow fibrosis. *Fibrogenesis Tissue Repair* 2012;5:S25.
- Cervantes F, Dupriez B, Pereira A, et al. New prognostic scoring system for primary myelofibrosis based on a study of the International Working Group for Myelofibrosis Research and Treatment. *Blood* 2009;113:2895-901.
- Passamonti F, Cervantes F, Vannucchi AM, et al. A dynamic prognostic model to predict survival in primary myelofibrosis: a study by the IWG-MRT (International Working Group for Myeloproliferative Neoplasms Research and Treatment). *Blood* 2010;115:1703-8.
- Thiele J, Kvasnicka HM, Facchetti F, et al. European consensus on grading bone marrow fibrosis and assessment of cellularity. *Haematologica* 2005;90:1128-32.
- Sorror ML, Maris MB, Storb R, et al. Hematopoietic cell transplantation (HCT)-specific comorbidity index: a new tool for risk assessment before allogeneic HCT. *Blood* 2005;106:2912-9.
- Moscardo F, Romero S, Sanz J, et al. T cell-depleted related HLA-mismatched peripheral blood stem cell transplantation as salvage therapy for graft failure after single unit unrelated donor umbilical cord blood transplantation. *Biol Blood Marrow Transplant* 2014;20:1060-3.
- Park JA, Koh KN, Choi ES, et al. Successful rescue of early graft failure in pediatric patients using T-cell-depleted haploidentical hematopoietic SCT. *Bone Marrow Transplant* 2013;49:270-5.
- Yoshihara S, Ikegame K, Taniguchi K, et al. Salvage haploidentical transplantation for graft failure using reduced-intensity conditioning. *Bone Marrow Transplant* 2011;47:369-73.
- Kanda J, Horwitz ME, Long GD, et al. Outcomes of a 1-day non myeloablative salvage regimen for patients with primary graft failure after allogeneic hematopoietic cell transplantation. *Bone Marrow Transplant* 2012;47:700-5.
- Tang BL, Zhu XY, Zheng CC, et al. Successful early unmanipulated haploidentical transplantation with reduced-intensity conditioning for primary graft failure after cord blood transplantation in hematologic malignancy patients. *Bone Marrow Transplant* 2015;50:248-52.
- Perini GF, Kerbauy FR, Fernandes JF, et al. Haploidentical non-myeloablative stem cell transplantation as salvage for graft failure in a patient with juvenile myelomonocytic leukemia. *Pediatr Blood Cancer* 2011;57:1084.
- Pagliuca S, Legendre H, Morin S, et al. Success of haploidentical hematopoietic stem cells transplantation in the treatment of graft failure. *Ann Hematol* 2016;95:353-4.
- Luznik L, O'Donnell PV, Symons HJ, et al. HLA-haploidentical bone marrow transplantation for hematologic malignancies using non myeloablative conditioning and high-dose, post transplantation cyclophosphamide. *Biol Blood Marrow Transplant* 2008;14:641-50.
- Fuji S, Nakamura F, Hatanaka K, et al. Peripheral blood as a preferable source of stem cells for salvage transplantation in patients with graft failure after cord blood transplantation: a retrospective analysis of the registry data of the Japanese Society for Hematopoietic Cell Transplantation. *Biol Blood Marrow Transplant* 2012;18:1407-14.
- Bregante S, Dominiotto A, Ghiso A, et al. Improved outcome of alternative donor transplantations in patients with myelofibrosis: from unrelated to haploidentical family donors. *Biol Blood Marrow Transplant* 2016;22:324-9.