

Combination therapeutic effects of high intensity focused ultrasound and Metformin for the treatment of adenomyosis

YANMEI HOU, ZHENLI QIN, KEFENG FAN, YANHUA XU and XIAOGE HUANG

Department of Gynaecology and Obstetrics, Jinan Maternity and Child Care Hospital, Shizhong, Jinan 250001, P.R. China

Received April 1, 2017; Accepted November 15, 2017

DOI: 10.3892/etm.2017.5601

Abstract. Adenomyosis is a pathological gynaecological condition characterized by benign invasion of the endometrium into the myometrium. High intensity focused ultrasound (HIFU) is one of the most common therapeutic strategies for the treatment of adenomyosis. However, the efficacy of single HIFU therapy is insufficient for the treatment of patients with adenomyosis. In the present study, the efficacy of HIFU and metformin for the treatment of adenomyosis was analyzed in 274 patients with adenomyosis who were admitted to Jinan Maternity and Child Care Hospital. The results demonstrated that there was a significant reduction in menstrual flow and pain between patients who received HIFU and metformin, and those who received single HIFU treatment ($P < 0.01$). Furthermore, the outcomes demonstrated that inflammatory cytokines levels were significantly lower compared with the baseline values ($P < 0.01$). In conclusion, the outcomes of the current study indicate that combined HIFU and metformin treatment is more efficacious in patients with enlarged adenomyosis compared with single HIFU treatment.

Introduction

Adenomyosis is one of common diseases caused by diffusion or invasion of endometrial glands and interstitial invasion of the myometrium in women of childbearing age (1,2). Pathological analysis indicates that adenomyosis is a condition in which the inner lining of the uterus (the endometrium) breaks through the muscle wall of the uterus (the myometrium) (3,4). The signs and symptoms of adenomyosis mainly include abnormal uterine bleeding, dysmenorrhea, dyspareunia, menorrhagia, enlarged uterus, dyspareunia, and infertility, which can seriously affect

the patient's reproductive system function and lead to gynecological diseases (5). In recent years, many therapeutic strategies for the treatment of adenomyosis have been proposed, such as drug treatments, surgery and interventional therapy.

Intensity focused ultrasound (HIFU) is a novel and efficient therapy method for the treatment of adenomyosis (6,7). Currently, feasibility of laparoscopic make high-intensity focused ultrasound treatment for patients with uterine localized adenomyosis become possible which may provide a promising laparoscopic treatment for localized adenomyosis (8). In addition, safety and efficacy of HIFU in ablating therapy for adenomyosis has been investigated in patients with localized adenomyosis and results indicate that HIFU may be a safe and effective method to treat adenomyosis, and an acoustic intensity of 420 W may be able to produce larger volumes of necrosis and better pain relief (9). However, single HIFU treatment is insufficient for adenomyosis therapy.

Metformin (C₄H₁₁N₅HC₁) is hydrochloride that was used to antidiabetics for patients with type 2 diabetes mellitus. Previous study has showed that Metformin can inhibit growth of eutopic stromal cells from adenomyotic endometrium via AMPK activation and subsequent inhibition of AKT phosphorylation, which may play essential role in the treatment of adenomyosis (10). Interestingly, effects of Metformin impaction of oxidative stress, inflammation and apoptosis have been analyzed in previous reports (11,12). However, the efficacy of Metformin in the treatment of adenomyosis has not yet been determined.

In this study, we reported the therapeutic effects of Metformin cooperated with HIFU for patients with adenomyosis. The purpose of this retrospective cohort study was to examine the differences therapeutic outcomes for adenomyosis patients with or without Metformin. Here we delineated further the benefits of combination therapy of HIFU and Metformin in the treatment of clinical patients with adenomyosis.

Materials and methods

Patients. This study included 274 patients with enlarged adenomyosis. The age of patient's was 26.7 to 44.5 years old. None of the patients participating in the study had any other complications. Patients were diagnosed with adenomyosis using MRI and histopathological techniques prior to treatment with HIFU or HIFU plus metformin. The characteristics of adenomyosis patients were summarized in Table I. All patients had moderate-to-severe dysmenorrhea and increased menstrual

Correspondence to: Professor Yanhua Xu or Dr Xiaoge Huang, Department of Gynaecology and Obstetrics, Jinan Maternity and Child Care Hospital, 2 Jianguo Xiaojingsan Road, Shizhong, Jinan 250001, P.R. China

E-mail: xuyanhuadoc@163.com

E-mail: sdjnybjy@126.com

Key words: adenomyosis, high intensity focused ultrasound, metformin, inflammation, menstrual flow, pain

flow. Patients were voluntarily divided into two groups and received HIFU (n=178) or combination therapy of HIFU and Metformin (n=96). Patients were received Metformin (2.5 mg/kg) 7 days pretreatment and 15 days posttreatment. This study was approved by the institutional ethics committee (Jinan Maternity and Child Care Hospital, Jinan, China). All adenomyosis patients were required to write informed consent with signature. The including criteria were: i) The adenomyosis patients were multiparous and had no desire for giving birth to another child; ii) there were no other reasons leading to dysmenorrhea and menorrhagia including abortion, hypoplasia of uterus and gynecological operations; iii) none of the patients had any history of serious health conditions. The follow-up period for patients was 12 months.

ELISA. Serum levels of IL-1 (MLB00C), IL-6 (D6050), IL-8 (D8000C) and TNF- α (MTA00B; all from R&D Systems, Inc., Minneapolis, MN, USA) were detected in patients with adenomyosis using ELISA kit according to the manufacturer's instruments. Finally, the serum concentration levels of inflammatory cytokines were measured by an enzyme micro-plate reader at 450 nm.

The degree of dysmenorrhea (pain). Dysmenorrhea was assessed in patients who undergone HIFU or combination therapy of HIFU and Metformin using the visual analogue scale. The no pain was recorded 0 and the intolerable pain was recorded 100. The degree of dysmenorrhea was recorded by patients.

Menstrual flow analysis. The menstrual flow was analyzed the weight changes of sanitary napkins. For baseline (100%), it was the number used before treatment. The posttreatment values are given as a percentage of the pretreatment values.

Volume and irregular menstruation analysis. Volume and irregular menstruation were measured on day 180 after HIFU treatment. Uterine volume of patients who under gone HIFU or combination therapy was calculated using the following formula: $0.523 \times a \times b \times c$. The variables *a*, *b*, and *c* represent the uterine 3D warp values determined by CT scanning. Irregular menstruation in patients after HIFU or combination therapy was recorded by patents themselves and was calculated through call visits.

Histological analysis. Eutopic endometrial specimens were obtained during the preoperative diagnostic curettage from the resected uterine lesion of patients with adenomyosis. Healthy endometrial specimens were collected during the diagnostic curettage from the removed uterus following uterine fibroids surgery. Endometrial specimens were obtained from five women (age-range: 28.4-37.2 years old), who were in Jinan Maternity and Child Care Hospital (Tianjin, China) from August, 2015 to May, 2016. All patients were provided written informed consent for the use of their tissue samples in the study. The formalin-fixed paraffin-embedded tissues were cut into 4- μ m thick sections. The sections were deparaffinized and stained with hematoxylin and eosin (H&E) for 30 min at 37°C. The sections were examined under blindfold conditions with standard light microscopy (Olympus Corp., Tokyo, Japan).

Table I. Patient characteristics.

Characteristic	HIFU	HIFU and Metformin
Age (years)	35.6 \pm 8.9	37.2 \pm 8.2
Number	178	96
Baseline uterine volume (cm ²)	382 (282-485)	395 (247-507)
Diagnosis		
MRI	178	96
Histopathology	178	96

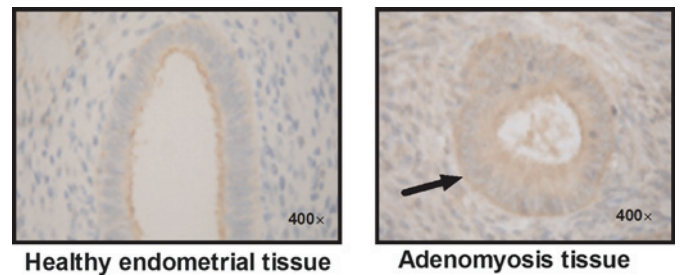


Figure 1. Representative image of healthy endometrial tissue and adenomyosis tissue. Arrow indicates dysfunctional hypertrophied muscular tissue surrounding ectopic endometrial glands.

Statistical analysis. Results are calculated as mean \pm SEM of triplicate. Statistical analyses were performed using Prism 5.0 (GraphPad Software, Inc., La Jolla, CA, USA). Differences between treatment groups were analyzed using one-way analysis of variance (ANOVA) followed by post-hoc pairwise comparison using an unpaired t-test. Kaplan-Meier was used to estimate the recurrence rate during a 12-month long-term observation. $P < 0.05$ was considered to indicate a statistically significant difference.

Results

Efficacy of combination treatment of HIFU and Metformin on inflammatory cytokines for adenomyosis patients. Patients with adenomyosis were diagnosed by pathologist microscopically examining small tissue samples of the uterus. As shown in Fig. 1, we showed that adenomyosis tissue presented representative images in patients with adenomyosis compared to healthy endometrial tissue. The inflammatory cytokines were analyzed in patients received combination treatment of HIFU and Metformin or single HIFU in serum. Outcomes showed that combination treatment of HIFU and Metformin significantly decreased inflammatory cytokines IL-1, IL-6, IL-8 and TNF- α compared to single HIFU treatment on day 30 after surgery (Fig. 2). These results indicate that combination treatment of HIFU and Metformin is beneficial for improvement of inflammation.

Efficacy of combination treatment of HIFU and Metformin on menstrual flow and dysmenorrhea for adenomyosis patients. Efficacy of combination treatment of HIFU and Metformin on flow and dysmenorrhea in patients with

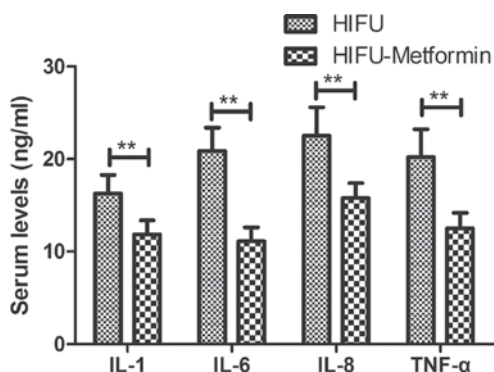


Figure 2. Serum levels of inflammatory cytokines IL-1, IL-6, IL-8 and TNF- α in patients with adenomyosis after HIFU or combination treatment of HIFU and Metformin. **P<0.01.

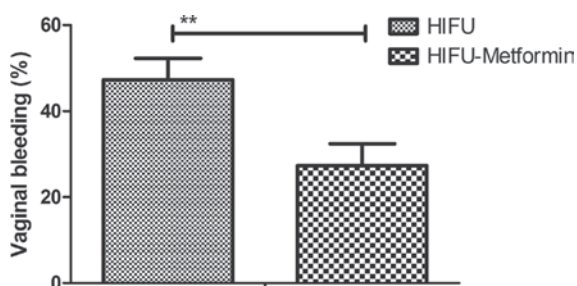


Figure 3. Combination treatments of HIFU and Metformin improves irregular vaginal bleeding for patients with adenomyosis. **P<0.01.

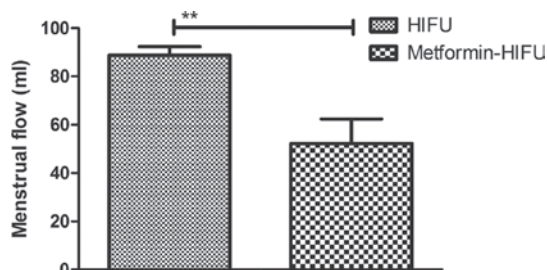


Figure 4. Menstrual flow was decreases by Combination treatment of HIFU and Metformin compared to single treatment of HIFU. **P<0.01.

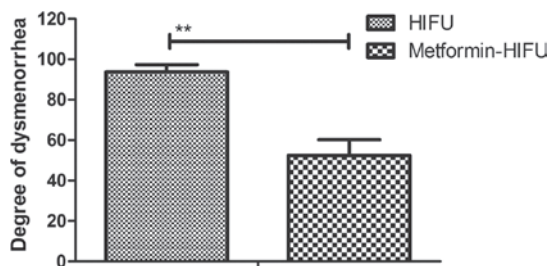


Figure 5. Combination treatments of HIFU and Metformin relieves patients' dysmenorrhea compared to HIFU treatment. **P<0.01.

adenomyosis was investigated in this study. We observed that regular vaginal bleeding was improved by combination treatment of HIFU and Metformin (Fig. 3). Menstrual flow was also resolved after the administration of HIFU and Metformin (Fig. 4). Notably, combination treatment of HIFU

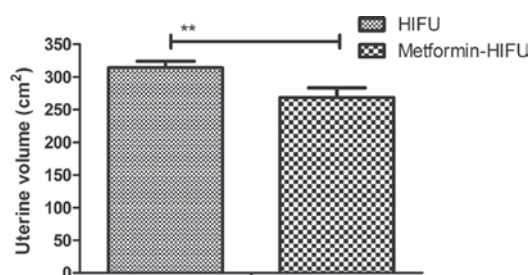


Figure 6. Combination treatments of HIFU and Metformin decreases uterine volume compared to HIFU treatment. **P<0.01.

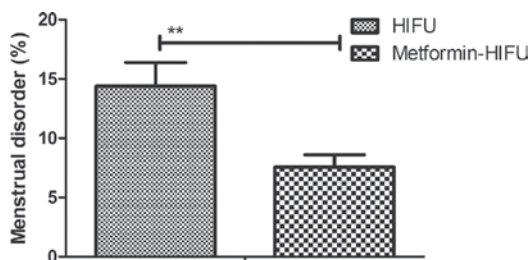


Figure 7. Menstrual disorder was significantly improved by combination treatment of HIFU and Metformin. **P<0.01.

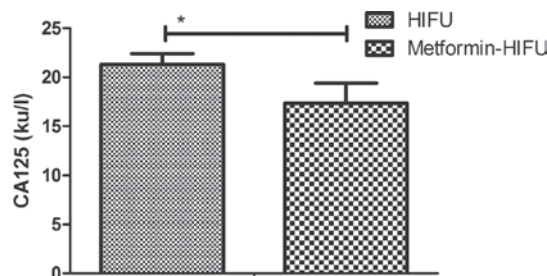


Figure 8. Combination treatments of HIFU and Metformin down-regulates serum levels of CA125 in patients with adenomyosis. *P<0.05.

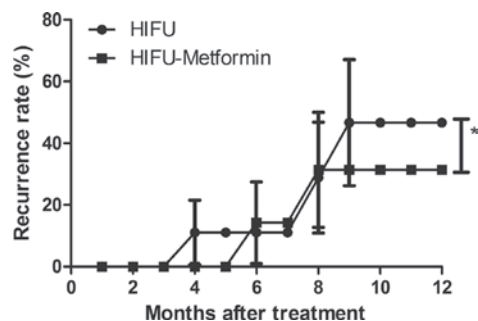


Figure 9. Recurrence rate of adenomyosis was decreases for patients received HIFU and Metformin therapy compared to single HIFU treatment. *P<0.05.

and Metformin markedly relieved patients' pain compared to HIFU treatment (Fig. 5). These outcomes indicate that combination treatment of HIFU and Metformin improves menstrual flow and dysmenorrhea for patients with adenomyosis.

Efficacy of combination treatment of HIFU and Metformin on uterine volume and menstrual disorder for adenomyosis

patients. Improvements of uterine volume and menstrual disorder were analyzed in adenomyosis patients after combination treatment of HIFU and Metformin. In patients who received HIFU and Metformin treatment decreased uterine volume compared to HIFU treatment (Fig. 6). Notably, menstrual disorder was significantly improved by combination treatment of HIFU and Metformin (Fig. 7). These outcomes indicate that combination treatment of HIFU and Metformin is beneficial for improvements of uterine volume and menstrual disorder.

Combination treatment of HIFU and Metformin decreases recurrence rate of adenomyosis. The recurrence rate of adenomyosis was investigated in adenomyosis patients after 12 months. We found that serum levels of CA125 were recovered to normal levels after combination treatment of HIFU and Metformin (Fig. 8). Recurrence rate of adenomyosis was significantly decreased for patients received HIFU and Metformin therapy compared to single HIFU treatment (Fig. 9). These outcomes suggest that combination treatment of HIFU and Metformin decreases recurrence rate of adenomyosis.

Discussion

Clinical effects of HIFU for dysmenorrhea in patients with adenomyosis have been investigated and HIFU appears to be effective and safe in the management of symptomatic adenomyosis, which can be considered as an alternative uterine-sparing option for women with this disease (13,14). In addition, Metformin is beneficial for the treatment of adenomyosis (10). This study confirmed that HIFU is an efficient therapeutic method for the treatment option for an adenomyosis patient and further explored combined treatment of HIFU and Metformin in patients with adenomyosis. Outcomes in the current study indicated that combination treatment of HIFU and Metformin reduced uterine volume and menstrual disorder effectively. We observed that combination treatment of HIFU and Metformin significantly improved menstrual flow and dysmenorrhea for adenomyosis patients. Notably, findings have showed that combination treatment of HIFU and Metformin decreased inflammatory cytokines in serum in patients with adenomyosis. Follow-up 12 months after treatment, recurrence rate of adenomyosis was significantly decreased for patients received HIFU and Metformin therapy compared to single HIFU treatment.

Our findings suggest that combination treatment of HIFU and Metformin was able to regulate state of the uterus and effectively treated adenomyosis. A retrospective study has indicated that clinical predictors of long-term success in ultrasound-guided HIFU is effective uterus-conserving ablation therapeutic way for adenomyosis (15). Another retrospective study suggested that inflammatory factors, angiogenesis and apoptosis in endometriosis, adenomyosis and uterine myoma influenced the ablative efficiency of HIFU treatment for adenomyosis (16). The outcomes in the current study are similar to that of many previous reports in which the administration of HIFU reduced blood loss, pain and menstrual flow (17-20). However, Metformin cooperated with HIFU treatment had returned to the size of uterine volume at baseline, which may be attributed to decreasing of inflammatory cytokines.

In this study, outcomes have showed that the patients' uterine volumes were so big that Metformin pretreatment and

post-treatment contributed to the efficacy of HIFU treatment. After cooperated treatment of Metformin and HIFU, an expulsion rate was recovered 15.2% in patients with adenomyosis. The combined Metformin and HIFU therapy also decreased serum levels of CA125 in patients with adenomyosis.

In conclusion, we delineated further the effects of Metformin and HIFU in patients with adenomyosis. Our findings indicate that combined Metformin and HIFU treatment was efficacious in patients with adenomyosis determined by improvements of the IUD expulsion rate, dysmenorrhea, inflammatory cytokines, recurrence rate and menstrual flow. Findings in this clinical study suggest that combined Metformin and HIFU therapy may be a potential therapeutic strategy for the treatment of patient with adenomyosis.

References

1. Barrier BF, Allison J, Hubbard GB, Dick EJ Jr, Brasky KM and Schust DJ: Spontaneous adenomyosis in the chimpanzee (*Pan troglodytes*): A first report and review of the primate literature: Case report. *Hum Reprod* 22: 1714-1717, 2007.
2. Dueholm M: Transvaginal ultrasound for diagnosis of adenomyosis: A review. *Best Pract Res Clin Obstet Gynaecol* 20: 569-582, 2006.
3. Rubod C, Narducci F, Delattre C, Decocq J, Verbert A and Delahousse G: Endometrioid adenocarcinoma arising from adenomyosis. A case report and literature review. *J Gynecol Obstet Biol Reprod (Paris)* 33: 140-144, 2004 (In French).
4. Deffieux X and Fernandez H: Physiopathologic, diagnostic and therapeutic evolution in the management of adenomyosis: Review of the literature. *J Gynecol Obstet Biol Reprod (Paris)* 33: 703-712, 2004 (In French).
5. Garcia L and Isaacson K: Adenomyosis: Review of the literature. *J Minim Invasive Gynecol* 18: 428-437, 2011.
6. Zhou M, Chen JY, Tang LD, Chen WZ and Wang ZB: Ultrasound-guided high-intensity focused ultrasound ablation for adenomyosis: The clinical experience of a single center. *Fertil Steril* 95: 900-905, 2011.
7. Dong X and Yang Z: High-intensity focused ultrasound ablation of uterine localized adenomyosis. *Curr Opin Obstet Gynecol* 22: 326-330, 2010.
8. Yang Z, Cao YD, Hu LN and Wang ZB: Feasibility of laparoscopic high-intensity focused ultrasound treatment for patients with uterine localized adenomyosis. *Fertil Steril* 91: 2338-2343, 2009.
9. Wang W, Wang Y and Tang J: Safety and efficacy of high intensity focused ultrasound ablation therapy for adenomyosis. *Acad Radiol* 16: 1416-1423, 2009.
10. Xue J, Zhang H, Liu W, Liu M, Shi M, Wen Z and Li C: Metformin inhibits growth of eutopic stromal cells from adenomyotic endometrium via AMPK activation and subsequent inhibition of AKT phosphorylation: A possible role in the treatment of adenomyosis. *Reproduction* 146: 397-406, 2013.
11. Kelleni MT, Amin EF and Abdelrahman AM: Effect of metformin and sitagliptin on doxorubicin-induced cardiotoxicity in rats: Impact of oxidative stress, inflammation, and apoptosis. *J Toxicol* 2015: 424813, 2015.
12. Schöndorf T, Musholt PB, Hohberg C, Forst T, Lehmann U, Fuchs W, Löbig M, Müller J and Pfützner A: The fixed combination of pioglitazone and metformin improves biomarkers of platelet function and chronic inflammation in type 2 diabetes patients: results from the PIOfix study. *J Diabetes Sci Technol* 5: 426-432, 2011.
13. Cheung VY: Current status of high-intensity focused ultrasound for the management of uterine adenomyosis. *Ultrasonography* 36: 95-102, 2017.
14. Feng Y, Hu L, Chen W, Zhang R, Wang X and Chen J: Safety of ultrasound-guided high-intensity focused ultrasound ablation for diffuse adenomyosis: A retrospective cohort study. *Ultrason Sonochem* 36: 139-145, 2017.
15. Liu X, Wang W, Wang Y, Wang Y, Li Q and Tang J: Clinical predictors of long-term success in ultrasound-guided high-intensity focused ultrasound ablation treatment for adenomyosis: A retrospective study. *Medicine (Baltimore)* 95: e2443, 2016.

16. Khan KN, Kitajima M, Hiraki K, Fujishita A, Sekine I, Ishimaru T and Masuzaki H: Changes in tissue inflammation, angiogenesis and apoptosis in endometriosis, adenomyosis and uterine myoma after GnRH agonist therapy. *Hum Reprod* 25: 642-653, 2010.
17. Lee JS, Hong GY, Park BJ and Kim TE: Ultrasound-guided high-intensity focused ultrasound treatment for uterine fibroid & adenomyosis: A single center experience from the Republic of Korea. *Ultrason Sonochem* 27: 682-687, 2015.
18. Shui L, Mao S, Wu Q, Huang G, Wang J, Zhang R, Li K, He J and Zhang L: High-intensity focused ultrasound (HIFU) for adenomyosis: Two-year follow-up results. *Ultrason Sonochem* 27: 677-681, 2015.
19. Zhang X, Li K, Xie B, He M, He J and Zhang L: Effective ablation therapy of adenomyosis with ultrasound-guided high-intensity focused ultrasound. *Int J Gynaecol Obstet* 124: 207-211, 2014.
20. Fan TY, Zhang L, Chen W, Liu Y, He M, Huang X, Orsi F and Wang Z: Feasibility of MRI-guided high intensity focused ultrasound treatment for adenomyosis. *Eur J Radiol* 81: 3624-3630, 2012.