

# Pedicle Subtraction Osteotomy with a Cage Prevents Sagittal Translation in the Correction of Kyphosis in Ankylosing Spondylitis

Fan-Qi Hu, Wen-Hao Hu, Hao Zhang, Kai Song, Yao Wang, Tian-Hao Wang, Yan Wang, Xue-Song Zhang

Department of Orthopaedics, Chinese People's Liberation Army General Hospital, Beijing 100853, China

## Abstract

**Background:** Sagittal translation (ST) is an accidental event that surgeons commonly encounter during a spinal osteotomy in the correction of kyphosis in ankylosing spondylitis (AS). However, there is a paucity of effective techniques to prevent ST. The purpose of this study was to propose a pedicle subtraction osteotomy (PSO) with a cage as a method to prevent ST and to explore the efficacy and feasibility of this method in the treatment of kyphosis in AS.

**Methods:** We retrospectively reviewed 89 consecutive patients with AS kyphosis who underwent a PSO (Group B, 46 patients) or a PSO with a cage (Group A, 43 patients) from February 2009 to December 2013. Pre- and post-operative radiographic results were reviewed. ST and complications were analyzed in both groups. Clinical assessment was performed using the Scoliosis Research Society-22 (SRS-22) outcomes metric. The patients were followed up for at least 2 years.

**Results:** Group A achieved the same re-alignment of the kyphotic spine as Group B. Two (4.7%) of the 43 patients in Group A and 14 (30.4%) of the 46 patients in Group B had intraoperative ST ( $\chi^2 = 10.020$ ,  $P = 0.002$ ). Significant differences were identified between the two groups in the height change of the osteotomized column. SRS-22 scores improved significantly in both groups. Seven patients experienced neurologic complications (1 in Group A and 6 in Group B). Eight patients had cerebrospinal fluid leakage (2 in Group A and 6 in Group B).

**Conclusion:** PSO with a cage significantly avoided ST during the osteotomy procedure and might represent a new, safe, and feasible choice for treating patients with AS kyphosis.

**Key words:** Ankylosing Spondylitis; Kyphosis; Pedicle Subtraction Osteotomy; Pedicle Subtraction Osteotomy with a Cage; Sagittal Translation

## INTRODUCTION

Ankylosing spondylitis (AS) is a chronic inflammatory seronegative arthropathy that progressively affects the axial skeleton, leading to a characteristic spinal kyphotic deformity in its later stages.<sup>[1]</sup> Severe deformities cause muscle fatigue, an inability to look straight ahead, and functional disabilities.<sup>[2-5]</sup> Surgical correction is necessary in many patients with AS kyphosis to restore sagittal balance and improve the quality of life.<sup>[6-9]</sup>

Pedicle subtraction osteotomy (PSO), a V-shaped wedge resection of the vertebral body, is the most popular technique in the surgical treatment of kyphosis in AS patients.<sup>[10,11]</sup> In the PSO procedure, correction is obtained through a closing wedge osteotomy that hinges on the anterior column of the

vertebral body. However, this procedure releases all the three columns of the spine, leading to unrestricted movement of the anterior column hinge. If the hinge moves during surgery, displacement of the vertebral column, or sagittal translation (ST), may occur at the osteotomy site [Figure 1a]. ST is an accidental event commonly encountered during spinal osteotomies to correct kyphosis in AS, and it

**Address for correspondence:** Prof. Xue-Song Zhang, Department of Orthopaedics, Chinese People's Liberation Army General Hospital, Beijing 100853, China  
E-Mail: zhangxuesong301@163.com

This is an open access article distributed under the terms of the Creative Commons Attribution-NonCommercial-ShareAlike 3.0 License, which allows others to remix, tweak, and build upon the work non-commercially, as long as the author is credited and the new creations are licensed under the identical terms.

**For reprints contact:** reprints@medknow.com

© 2018 Chinese Medical Journal | Produced by Wolters Kluwer - Medknow

**Received:** 18-10-2017 **Edited by:** Li-Shao Guo

**How to cite this article:** Hu FQ, Hu WH, Zhang H, Song K, Wang Y, Wang TH, Wang Y, Zhang XS. Pedicle Subtraction Osteotomy with a Cage Prevents Sagittal Translation in the Correction of Kyphosis in Ankylosing Spondylitis. Chin Med J 2018;131:200-6.

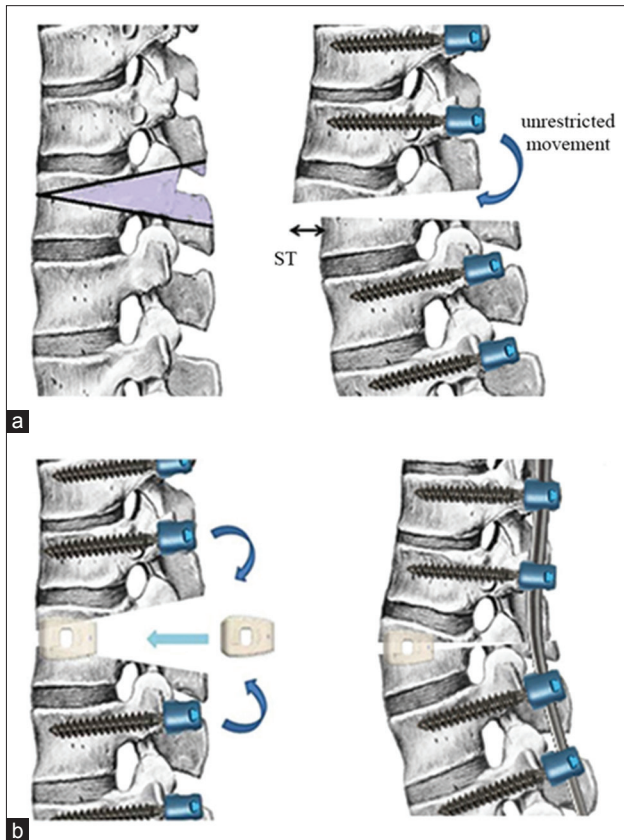
### Access this article online

#### Quick Response Code:



**Website:**  
www.cmj.org

**DOI:**  
10.4103/0366-6999.222342



**Figure 1:** Mechanism of ST in PSO. (a) A V-shaped wedge is resected and the osteotomy gap is unrestricted and ST happens after sagittal movement of the osteotomy site during closure. (b) Illustration of the cage method. It involves inserting a cage large enough into the anterior of the osteotomy gap to restrict the sagittal movement of the osteotomy site. ST: Sagittal translation; PSO: Pedicle subtraction osteotomy.

dramatically increases the potential risk of neurovascular complications.<sup>[12-18]</sup>

To the best of our knowledge, there are few methods to prevent ST effectively during osteotomy surgery for AS kyphosis at present. We have developed a method of performing a PSO with a cage, a fusion device in the anterior column at the level of the osteotomy, to restrict the sagittal movement of the osteotomy site and to prevent ST during surgery. The goal of this study was to introduce the cage method to prevent ST and to explore the efficacy and feasibility of this method in the treatment of kyphosis in AS.

## METHODS

### Ethical approval

Consent from all patients was received for this study. This study was approved by the institutional review board of our hospital.

### Study subject

Between February 2009 and December 2013, 263 consecutive AS patients who underwent a spinal osteotomy for sagittal imbalance at our institution were retrospectively reviewed. All the patients were diagnosed with AS with

spinal kyphosis by radiographic examinations and laboratory tests according to New York standards.<sup>[19]</sup> Inclusion criteria were patients who underwent a one-level PSO or PSO with a cage to correct sagittal deformity, with a follow-up period of at least 2 years. Exclusion criteria were patients with cervical kyphosis, revision surgery, coronal deformity, and dislocation of the sacroiliac and hip joints. A total of 89 patients were included in this study.

Eighty-nine patients were divided into two groups based on the surgical methods applied as follows: Group A (PSO with a cage) and Group B (PSO). Group A consisted of 43 patients (36 men and 7 women), with a mean age of 43.1 years (range, 26–58 years). Group B was composed of 46 patients (41 men and 5 women), with a mean age of 46.5 years (range, 28–54 years). The mean follow-up time was 34 months (range, 24–54 months).

### Radiologic assessment

Pre- and post-operative full-length spinal radiographs with the patients standing unsupported were available for all patients. Radiographic parameters included sagittal Cobb angle (from T1 to S1), sagittal vertical axis (SVA), lumbar lordosis (LL), and pelvic tilt (PT), which were documented as key parameters for surgical evaluation.<sup>[11,20-22]</sup> The local radiographic parameters at the osteotomy site, including the height of the anterior and posterior columns of the vertebral osteotomy segment (AC and PC), were documented pre- and postoperatively.<sup>[23]</sup> Postoperative radiographs were performed before hospital discharge, at the 6- and 12-month postoperative period, and at the final follow-up.

ST was measured as the distance between the posterior superior edge of the caudal vertebral body to the posterior inferior edge of the cranial body at the osteotomy level in postoperative standing lateral radiographs.<sup>[12]</sup> The ST was considered positive if the displacement distance was  $>2$  mm. Otherwise, it was negative.

### Surgical technique

All patients were continuously monitored intraoperatively by somatosensory-evoked potentials and motor-evoked potentials. Following the induction of general anesthesia, each patient was placed in the prone position. The thoracolumbar spine was exposed through a posterior midline incision, and the posterior elements were exposed through a subperiosteal approach. Pedicle screw fixation was performed by a freehand technique.

The osteotomy was initiated by probing the pedicles of the osteotomized vertebrae on both sides using a pedicle probe. Then, the pedicles were dilated by incrementally increasing the probe or bone tap size. A high-speed drill was used to enlarge the pedicle holes as necessary. After this, the vertebral bone was adequately removed. The decancellation procedure carefully created a triangular wedge. Before the closing procedure, a temporary rod was used to avoid intraoperative ST in one side in all of the patients when the other side of the osteotomy was completed. After the osteotomy, the cage method was performed with a polyetheretherketone

cage [Figure 2] (Weigao Orthopedic, Shandong, China) and bone autograft packed into the osteotomy space at the anterior column of the vertebral body. Thus, the cage sank into the cancellous bone of the vertebral body to stabilize it, and the correction hinge was located at the anterior column without an unpredictable ST. The size ranged from 12 cm × 10 cm × 22 cm to 14 cm × 10 cm × 22 cm, based on the width of the osteotomy gap after removing the vertebral bone. A cantilever maneuver with contoured rods was used to close the osteotomy [Figure 1b]. The patient's position and the operating table were simultaneously adjusted. After closure, evoked potentials were performed to assess spinal cord and nerve root function. Then, the screw nuts were tightened, a posterior fusion bed was prepared, and local bone was grafted to create a fusion. C-arm fluoroscopy was used to examine the magnitude of the correction [Figure 3]. Postoperatively, the patients were allowed to mobilize using a custom-made plastic thoracolumbosacral orthosis during the first 3 months.

### Outcomes

Operating time, blood loss, and fused levels were recorded in detail. Clinical outcomes were evaluated using the Scoliosis Research Society-22 (SRS-22) outcome questionnaire<sup>[24]</sup> preoperatively and at the final follow-up. Complications and other data were also recorded and reviewed.

### Statistical analysis

A paired *t*-test was performed to compare the pre- and postoperative radiographic parameters and the SRS-22 domain scores of each group. An independent sample *t*-test was used to compare results between groups.

Pearson's Chi-squared test was used to evaluate the ST of different osteotomy methods. An odds ratio (*OR*) with a 95% confidence interval (*CI*) was calculated to allow more meaningful interpretation. The *OR* is a way of comparing whether the probability of a certain event (ST) is the same for two groups. An *OR* of 1 implies that the event is equally likely in both groups. An *OR* >1 implies that the event is more likely in that group. An *OR* <1 implies that the event is less likely in that group.



**Figure 2:** The polyetheretherketone cage used in our study.

All data were analyzed using SPSS (version 17.0, SPSS Inc., Chicago, IL, USA). *P* < 0.05 was considered statistically significant.

## RESULTS

### Surgical results

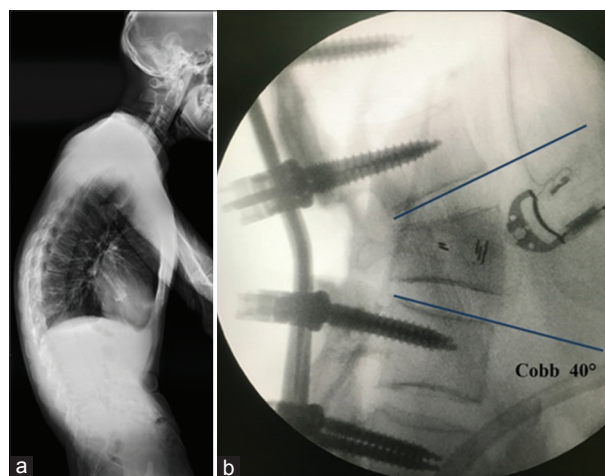
A one-level osteotomy was performed on all patients. In Group A, the most frequent osteotomy level was L2 (17 patients), followed by L3 (14 patients), L1 (9 patients), and T12 (3 patients). In Group B, osteotomies over L1, L2, L3, and T12 were performed in 6, 15, 21, and 4 patients, respectively. The mean number of fused levels was 6.8 (range, 5–10) in Group A and 6.5 (range, 5–10) in Group B. The mean operative time was 305 min (range, 240–360 min) in Group A and 310 min (range, 250–380 min) in Group B. The average estimated blood loss was 700 ml (range, 400–1350 ml) in Group A and 780 ml (range, 550–1400 ml) in Group B.

### Sagittal translation

Two (4.7%) out of 43 patients in Group A and 14 (30.4%) out of 46 patients in Group B had intra- and postoperative ST. The patients who underwent a PSO were associated with a significantly higher risk of ST than those who underwent the cage method ( $\chi^2 = 10.020$ , *P* = 0.002) [Figure 4]. The *ORs* with 95% *CI*s are shown in Table 1.

### Radiographical and clinical results

The pre- and postoperative radiographic parameters of all patients were recorded. Postoperative correction was achieved in all patients. The sagittal parameters significantly improved in both groups [Table 2]. There was no significant difference between the two groups in the correction of Cobb angle, SVA, LL, and PT [Table 3]. No obvious correction loss was observed at the final follow-up in either group [Figure 5].



**Figure 3:** (a) Lateral preoperative radiograph of a 30-year-old male patient who underwent PSO with cage. (b) Intraoperative imaging showing that a correction of 40° at the osteotomy segment was obtained, without sagittal translation. PSO: Pedicle subtraction osteotomy.



**Table 1: The effects of surgical approach on the risk of developing ST in the PSO with a cage group (Group A) and the PSO group (Group B)**

Groups	n	With ST	Without ST	OR (95% CI)	$\chi^2$	P
Group A	43	2	41	0.11 (0.02–0.53)	10.020	0.002
Group B	46	14	32	8.97 (1.90–42.34)		
Total	89	16	73			

ST: Sagittal translation; PSO: Pedicle subtraction osteotomy; CI: Confidence interval; OR: Odds ratio.

**Table 2: Comparison of the pre- and postoperative radiographic parameters in the PSO with a cage group (Group A) and in the PSO group (Group B) (mean  $\pm$  SD)**

Radiographic parameters	Preoperative	Postoperative	t	P
Group A				
Cobb angle ( $^\circ$ )	43.5 $\pm$ 14.8	7.8 $\pm$ 6.7	17.076	<0.01
SVA (cm)	25.1 $\pm$ 15.2	6.8 $\pm$ 7.6	6.454	<0.01
LL ( $^\circ$ )	11.2 $\pm$ 10.3	-30.8 $\pm$ 15.3	15.134	<0.01
PT ( $^\circ$ )	42.3 $\pm$ 15.7	25.3 $\pm$ 11.1	8.237	<0.01
Group B				
Cobb angle ( $^\circ$ )	46.2 $\pm$ 16.7	8.8 $\pm$ 7.3	14.849	<0.01
SVA (cm)	26.4 $\pm$ 14.5	7.5 $\pm$ 8.2	8.822	<0.01
LL ( $^\circ$ )	10.5 $\pm$ 12.3	-28.6 $\pm$ 18.5	11.123	<0.01
PT ( $^\circ$ )	40.6 $\pm$ 18.2	26.5 $\pm$ 13.1	4.770	<0.01

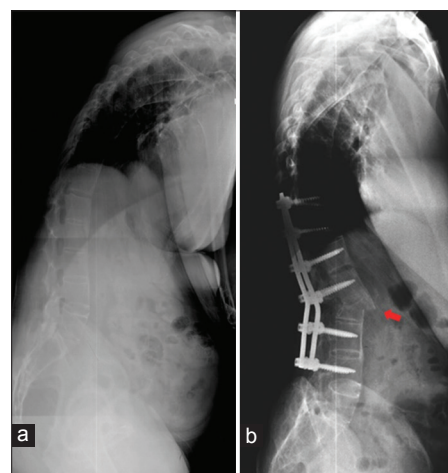
SD: Standard deviation; PSO: Pedicle subtraction osteotomy; Cobb angle: Cobb angle from T1 to S1; SVA: Sagittal vertical axis; LL: Lumbar lordosis; PT: Pelvic tilt.

In Group A, the AC was prolonged from 29.4  $\pm$  2.8 mm preoperatively to 32.6  $\pm$  2.5 mm postoperatively, and the PC was shortened from 31.2  $\pm$  2.4 mm preoperatively to 17.6  $\pm$  3.5 mm postoperatively. In Group B, the PC was shortened from 30.7  $\pm$  2.5 mm preoperatively to 12.7  $\pm$  3.1 mm postoperatively. Significant differences were identified in postoperative PC ( $t = 5.899$ ,  $P < 0.01$ ) and AC ( $t = 5.598$ ,  $P < 0.01$ ) between the two groups [Table 3].

At the final follow-up, the SRS-22 scores improved from preoperative 1.9  $\pm$  0.6 to 4.5  $\pm$  0.5 in Group A and from 2.0  $\pm$  0.7 to 4.6  $\pm$  0.4 in Group B. The SRS-22 scores at the final follow-up did not demonstrate a significant difference between the two groups [Table 4].

### Complications

The complications for each group are shown in Table 5. No fatal complications or aortic injuries occurred in either group. Two patients in Group A experienced cerebrospinal fluid (CSF) leakage secondary to dural tears during the removal of the posterior longitudinal ligament. CSF leakages occurred in six patients in Group B due to dural tears. Three of them experienced it during the resection, and the other three developed it during osteotomy closure. All dural tears were managed uneventfully using muscle and fat graft coverage intraoperatively, and the patients were discharged within 2 weeks of surgery. Superficial infections occurred in both groups and were managed with local wound care and antibiotics (2 in Group A



**Figure 4:** (a) Preoperative radiograph of a 43-year-old male patient of Group B who underwent PSO. (b) The red arrow shows significant ST after closure of the osteotomized vertebra. PSO: Pedicle subtraction osteotomy; ST: Sagittal translation.

and 3 in Group B). Postoperative pneumonia occurred (2 in Group A and 1 in Group B) and was treated without adverse effects. Seven patients experienced neurologic complications (1 in Group A and 6 in Group B), which were characterized by postoperative unilateral leg numbness and weakness. Four of these recovered spontaneously within 3 months.

### DISCUSSION

Late-stage AS patients suffer from thoracolumbar kyphosis, characterized by a round spinal curvature, which requires surgical correction. The PSO has recently become increasingly popular among various osteotomy techniques to correct kyphosis in AS patients. This osteotomy permits the restoration of LL and reduces SVA through a closing wedge osteotomy, thereby leading to good functional results.<sup>[25]</sup> Unfortunately, neurologic complications following PSOs are common. Bridwell *et al.* reported a 15.2% incidence of neurologic complications in a case series of patients treated by PSO.<sup>[17]</sup> Ahn *et al.* found a neurologic complication rate of 12.0%.<sup>[26]</sup> Buchowski *et al.* noted neurologic deficits in 11.1% of patients and 3 patients had permanent deficits.<sup>[27]</sup> In our study, the neurologic complication rate was 13.0% in the PSO group. All authors identified residual dorsal bony impingement combined with dural buckling and intraoperative ST as the main cause of neurologic complications. Preventative measures have been established for these risk factors. Nevertheless, intraoperative ST during osteotomy closure has been deemed a matter of

**Table 3: Radiographic parameter correction comparison between the two groups (mean ± SD)**

Radiographic parameters	Group A (PSO with a cage)	Group B (PSO)	<i>t</i>	<i>P</i>
Correction of Cobb angle (°)	35.7 ± 12.6	37.4 ± 14.3	0.157	0.876
Correction of SVA (cm)	18.3 ± 13.2	18.9 ± 14.8	1.371	0.174
Correction of LL (°)	42.0 ± 11.6	39.1 ± 10.5	-0.629	0.531
Correction of PT (°)	17.0 ± 13.8	14.1 ± 17.8	-1.184	0.240
Change in AC (mm)	3.2 ± 2.7	0.6 ± 1.6	5.598	<0.01
Change in PC (mm)	13.6 ± 3.1	18.0 ± 3.8	5.899	<0.01

SD: Standard deviation; PSO: Pedicle subtraction osteotomy; Cobb angle: Cobb angle from T1 to S1; SVA: Sagittal vertical axis; LL: Lumbar lordosis; PT: Pelvic tilt; AC: Height of the anterior column of osteotomy vertebrae; PC: Height of the posterior column of osteotomy vertebrae.

**Table 4: Comparison of the SRS-22 outcomes between the PSO with a cage group (Group A) and the PSO group (Group B) (mean ± SD)**

SRS-22	Group A	Group B	<i>t</i>	<i>P</i>
Preoperative	1.9 ± 0.6	2.0 ± 0.7	0.788	0.433
Postoperative	4.5 ± 0.5	4.6 ± 0.4	0.691	0.492
Final follow-up	4.4 ± 0.6	4.5 ± 0.4	0.923	0.359

SD: Standard deviation; PSO: Pedicle subtraction osteotomy; SRS-22: Scoliosis Research Society-22.

**Table 5: Complications in the PSO with a cage group (Group A) and the PSO group (Group B)**

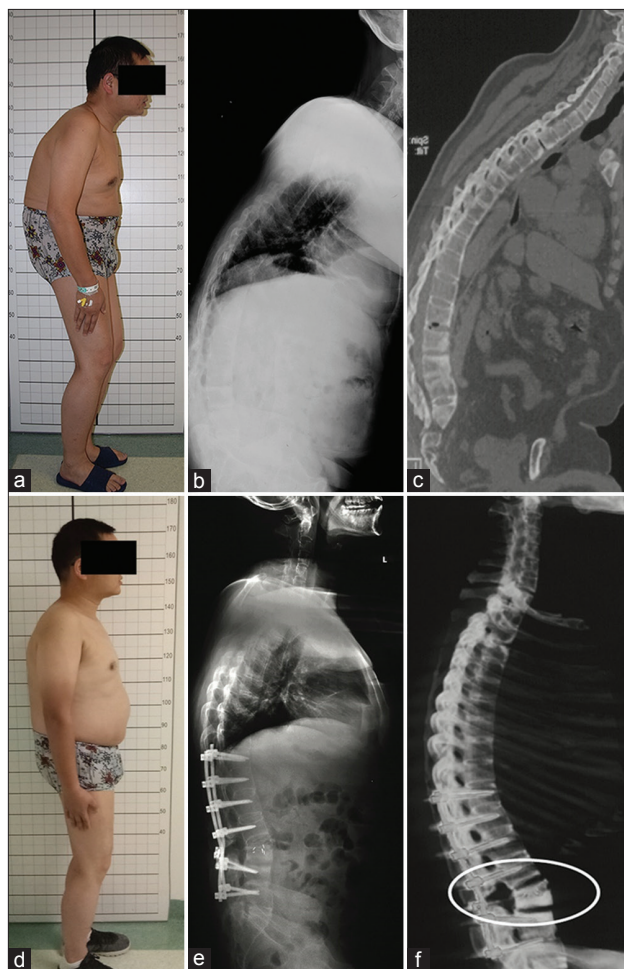
Complications	Group A (n = 43)	Group B (n = 46)
CSF leakage	2	6
Superficial infection	2	3
Pneumonia	2	1
Neurologic complications	1	6

CSF: Cerebrospinal fluid.

concern. Currently, there are few effective measures that have been proposed to prevent ST during osteotomy for AS with kyphosis patients.

In 2011, a method that used temporary malleable rods was reported to prevent ST during osteotomy surgery by Arun *et al.*<sup>[6]</sup> We used this method in most of our patients. We found that this method plays a limited role in preventing ST before the reduction maneuver finished. Based on our experience, most STs occur because of unrestricted movement at the osteotomy site after anterior cortex fractures during the closing procedure. However, the temporary rods should be removed before the osteotomy gap is closed. Using temporary rods in the correction of AS with kyphosis was not able to avert the occurrence of ST, and the neurovascular complications caused by ST could be critical for individual patients.

If the osteotomy site was stable enough during closure, the management of osteotomy surgery could become safer. The PSO with a cage method includes inserting a cage with bone autograft into the osteotomy space in the anterior column of the osteotomized vertebra. The cage immediately sinks into the cancellous bone of the cranial and caudal sides of the osteotomized site. It provides a stable hinge to close the osteotomy gap, restricts the movement of the cranial or caudal



**Figure 5:** (a) Preoperative clinical photograph of a 34-year-old male patient with AS kyphotic deformity of Group A. (b) Preoperative full-length radiograph showing a remarkable kyphosis in thoracolumbar spine with a global kyphosis of 74°. (c) Preoperative computed tomography sagittal reconstruction image of the patient. (d) Postoperative lateral photograph after single-level PSO with a cage at the L3. (e) Two years of follow-up revealed a correction of about 43° and solid fusion at the osteotomy site without ST. (f) Postoperative three-dimensional reconstruction demonstrated that moderate opening of the anterior cortex of the osteotomized vertebrae was obtained after the cage method, as the circle shows. AS: Ankylosing spondylitis; ST: Sagittal translation; PSO: Pedicle subtraction osteotomy.

aspects of the osteotomy site, and reduces the possibility of ST after anterior cortex fractures. In this cage method, the cage must be large enough and we recommend its height up

to 14 mm. It is only in this way that the cage can make the closure process more stable, as the forces on the osteotomy during closure are mainly focused on the cage in the anterior column. This procedure helps to avoid sagittal displacement and ensures procedure safety. Since 2009, the cage method has been used to stabilize the osteotomy site for AS in 43 patients. This method truly improved the safety of the osteotomy surgery. In this retrospective study, the incidence of ST in AS patients treated with the cage method was significantly reduced compared with those managed with the traditional PSO method. The management of PSOs appeared to carry more risk of developing ST, with an observed *OR* of 8.97 compared with an *OR* of 0.11 for the new method.

In our retrospective study, significant differences were identified between the two groups with respect to changes in the height of the anterior (AC) and posterior (PC) vertebral columns. A mean shortening of 0.6 mm of AC and 18 mm of PC was identified in Group B, while a mean elongation of 3.2 mm of AC and a mean shortening of 13.6 mm of PC were identified in Group A. Even though the cage may sink into the cancellous bone of the vertebra in most cases, a moderate opening of the anterior cortex of the osteotomized vertebrae could be obtained with the cage method in the patients of Group A. It decreased the need for posterior column shortening and avoided vertebral compression, thereby preventing dural or spinal cord buckling, which are important causes of neurologic complications.<sup>[28,29]</sup> Theoretically, the risk of CSF leakage during osteotomy closure can be reduced because of less reduction of the spinal column and sufficient stability of the osteotomized vertebra. However, CSF leakage after dural tears during resection cannot be avoided, and it requires a more careful technique by the surgeon. It is worth noting that the cage method cannot improve the degree of operative correction, as most cages sank into the cancellous bone without providing adequate support. In our study, the correction of radiographic parameters was not significantly different between the two groups.

There are a number of limitations to this study. Limitations are mainly tied to the small sample size (single center). There are also many unpredictable surgical factors that may be associated with ST, even though we have excluded these effects as much as possible in our study. Furthermore, to obtain a satisfactory correction, a two-level osteotomy may be required for some patients with severe rigid kyphotic deformities.

In conclusion, the PSO with a cage method represents a new, safe, and feasible choice for treating patients with AS kyphosis. This method achieves appropriate re-alignment of the kyphotic spine, significantly prevents ST during osteotomy, and moderately reduces spinal column shortening.

### Financial support and sponsorship

Nil.

### Conflicts of interest

There are no conflicts of interest.

## REFERENCES

- Braun J, Sieper J. Ankylosing spondylitis. *Lancet* 2007;369:1379-90. doi: 10.1016/S0140-6736(07)60635-7.
- Fu J, Zhang G, Zhang Y, Liu C, Zheng G, Song K, *et al.* Pulmonary function improvement in patients with ankylosing spondylitis kyphosis after pedicle subtraction osteotomy. *Spine (Phila Pa 1976)* 2014;39:E1116-22. doi: 10.1097/BRS.0000000000000441.
- Liu C, Song K, Zhang Y, Fu J, Zheng G, Tang X, *et al.* Changes of the abdomen in patients with ankylosing spondylitis kyphosis. *Spine (Phila Pa 1976)* 2015;40:E43-8. doi: 10.1097/BRS.0000000000000662.
- Zhang G, Fu J, Zhang Y, Zhang W, Zhang X, Wang Z, *et al.* Lung volume change after pedicle subtraction osteotomy in patients with ankylosing spondylitis with thoracolumbar kyphosis. *Spine (Phila Pa 1976)* 2015;40:233-7. doi: 10.1097/BRS.0000000000000717.
- Debarge R, Demey G, Rousouly P. Radiological analysis of ankylosing spondylitis patients with severe kyphosis before and after pedicle subtraction osteotomy. *Eur Spine J* 2010;19:65-70. doi: 10.1007/s00586-009-1158-7.
- Arun R, Dabke HV, Mehdian H. Comparison of three types of lumbar osteotomy for ankylosing spondylitis: A case series and evolution of a safe technique for instrumented reduction. *Eur Spine J* 2011;20:2252-60. doi: 10.1007/s00586-011-1894-3.
- Kiaer T, Gehrchen M. Transpedicular closed wedge osteotomy in ankylosing spondylitis: Results of surgical treatment and prospective outcome analysis. *Eur Spine J* 2010;19:57-64. doi: 10.1007/s00586-009-1104-8.
- Hu WH, Wang Y. Osteotomy techniques for spinal deformity. *Chin Med J* 2016;129:2639-41. doi: 10.4103/0366-6999.192774.
- Tan R, Ma HS, Zou DW, Wu JG, Chen ZM, Zhou XF, *et al.* Surgical treatment of severe scoliosis and kyphoscoliosis by stages. *Chin Med J* 2012;125:81-6. doi: 10.3760/cma.j.issn.0366-6999.2012.01.015.
- Liu H, Yang C, Zheng Z, Ding W, Wang J, Wang H, *et al.* Comparison of Smith-Petersen osteotomy and pedicle subtraction osteotomy for the correction of thoracolumbar kyphotic deformity in ankylosing spondylitis: A systematic review and meta-analysis. *Spine (Phila Pa 1976)* 2015;40:570-9. doi: 10.1097/BRS.0000000000000815.
- Qian BP, Jiang J, Qiu Y, Wang B, Yu Y, Zhu ZZ, *et al.* Radiographical predictors for postoperative sagittal imbalance in patients with thoracolumbar kyphosis secondary to ankylosing spondylitis after lumbar pedicle subtraction osteotomy. *Spine (Phila Pa 1976)* 2013;38:E1669-75. doi: 10.1097/BRS.0000000000000021.
- Chang KW, Chen HC, Chen YY, Lin CC, Hsu HL, Cai YH, *et al.* Sagittal translation in opening wedge osteotomy for the correction of thoracolumbar kyphotic deformity in ankylosing spondylitis. *Spine (Phila Pa 1976)* 2006;31:1137-42. doi: 10.1097/01.brs.0000216479.09250.96.
- Chang KW, Cheng CW, Chen HC, Chang KI, Chen TC. Closing-opening wedge osteotomy for the treatment of sagittal imbalance. *Spine (Phila Pa 1976)* 2008;33:1470-7. doi: 10.1097/BRS.0b013e3181753bcd.
- O'shaughnessy BA, Kuklo TR, Hsieh PC, Yang BP, Koski TR, Ondra SL, *et al.* Thoracic pedicle subtraction osteotomy for fixed sagittal spinal deformity. *Spine (Phila Pa 1976)* 2009;34:2893-9. doi: 10.1097/BRS.0b013e3181c40bf2.
- Gavaskar AS, Naveen Chowdary T. Pedicle subtraction osteotomy for rigid kyphosis of the dorsolumbar spine. *Arch Orthop Trauma Surg* 2011;131:803-8. doi: 10.1007/s00402-010-1224-y.
- Hyun SJ, Kim YJ, Rhim SC. Spinal pedicle subtraction osteotomy for fixed sagittal imbalance patients. *World J Clin Cases* 2013;1:242-8. doi: 10.12998/wjcc.v1.i8.242.
- Bridwell KH, Lewis SJ, Edwards C, Lenke LG, Iffrig TM, Berra A, *et al.* Complications and outcomes of pedicle subtraction osteotomies for fixed sagittal imbalance. *Spine (Phila Pa 1976)* 2003;28:2093-101. doi: 10.1097/01.BRS.0000090891.60232.70.
- Hao CK, Li WS, Chen ZQ. The height of the osteotomy and the correction of the kyphotic angle in thoracolumbar kyphosis. *Chin Med J* 2008;121:1906-10. doi: 10.3760/j.issn.0366-6999.2008.19.010.
- Moll JM. New criteria for the diagnosis of ankylosing spondylitis. *Scand J Rheumatol Suppl* 1987;65:12-24. doi: 10.3109/03009748709102173.



20. Song K, Zheng G, Zhang Y, Cui G, Zhang X, Mao K, *et al.* Hilus pulmonis as the center of gravity for AS thoracolumbar kyphosis. *Eur Spine J* 2014;23:2743-50. doi: 10.1007/s00586-013-3134-5.
21. Debarge R, Demey G, Roussouly P. Sagittal balance analysis after pedicle subtraction osteotomy in ankylosing spondylitis. *Eur Spine J* 2011;20 Suppl 5:619-25. doi: 10.1007/s00586-011-1929-9.
22. Zhang XS, Zhang YG, Wang Z, Chen C, Wang Y. Correction of severe post-traumatic kyphosis by posterior vertebra column resection. *Chin Med J* 2010;123:680-5. doi: 10.3760/cma.j.isn.0366-6999.2010.06.008.
23. Zhang X, Zhang Z, Wang J, Lu M, Hu W, Wang Y, *et al.* Vertebral column decancellation: A new spinal osteotomy technique for correcting rigid thoracolumbar kyphosis in patients with ankylosing spondylitis. *Bone Joint J* 2016;98-B:672-8. doi: 10.1302/0301-620X.98B5.35726.
24. Asher M, Min Lai S, Burton D, Manna B. Scoliosis Research Society-22 patient questionnaire: Responsiveness to change associated with surgical treatment. *Spine (Phila Pa 1976)* 2003;28:70-3. doi: 10.1097/01.BRS.0000047635.95839.2E.
25. Berjano P, Aebi M. Pedicle subtraction osteotomies (PSO) in the lumbar spine for sagittal deformities. *Eur Spine J* 2015;24 Suppl 1:S49-57. doi: 10.1007/s00586-014-3670-7.
26. Ahn UM, Ahn NU, Buchowski JM, Kebaish KM, Lee JH, Song ES, *et al.* Functional outcome and radiographic correction after spinal osteotomy. *Spine (Phila Pa 1976)* 2002;27:1303-11. doi: 10.1097/00007632-200206150-00011.
27. Buchowski JM, Bridwell KH, Lenke LG, Kuhns CA, Lehman RA Jr., Kim YJ, *et al.* Neurologic complications of lumbar pedicle subtraction osteotomy: A 10-year assessment. *Spine (Phila Pa 1976)* 2007;32:2245-52. doi: 10.1097/BRS.0b013e31814b2d52.
28. Murrey DB, Brigham CD, Kiebzak GM, Finger F, Chewning SJ. Transpedicular decompression and pedicle subtraction osteotomy (eggshell procedure): A retrospective review of 59 patients. *Spine (Phila Pa 1976)* 2002;27:2338-45. doi: 10.1097/01.BRS.0000030853.62990.BC.
29. Thomason K, Emran IM, Chan D. Shortening osteotomy for the treatment of spinal neuroarthropathy following spinal cord injury. A case report and literature review. *Eur Spine J* 2007;16 Suppl 3:318-21. doi: 10.1007/s00586-007-0343-9.