

## Case Report

# Treatment of colloid cyst of the third ventricle by stereotactic aspiration followed by radiosurgery: Report of four cases

Jeremy P. Morgan, Steven C. McGraw<sup>1</sup>, Wilson T. Asfora<sup>2</sup>Sanford Research, <sup>1</sup>Sanford Cancer Center, <sup>2</sup>Department of Surgery, Section of Neurosurgery, Sanford Health/USD Sanford School of Medicine, South Dakota, USAE-mail: Jeremy P. Morgan - [Jeremy.morgan@sanfordhealth.org](mailto:Jeremy.morgan@sanfordhealth.org); Steven C. McGraw - [Steven.mcgraw@sanfordhealth.org](mailto:Steven.mcgraw@sanfordhealth.org);\*Wilson T. Asfora - [wilsonandrose@gmail.com](mailto:wilsonandrose@gmail.com)

\*Corresponding author

Received: 17 May 17 Accepted: 20 September 17 Published: 10 January 18

## Abstract

**Background:** Colloid cysts are rare benign lesions with potentially devastating results. Complications intra and posttreatment can result in high rates of recurrence. Stereotactic radiosurgery may present an attractive option for decreasing the rate of recurrence in conjunction with stereotactic aspiration.

**Case Description:** Here, we report four cases of colloid cyst of the third ventricle managed by stereotactic aspiration with the use of the Leksell frame followed by stereotactic radiosurgery with the BrainLab/Novalis linear accelerator. Follow-up ranged from 7 to 10 years. There were no complications related to the treatment and no recurrence of the cysts, to date. All four patients remain asymptomatic.

**Conclusions:** The combination of stereotactic aspiration and radiosurgery may have a role in the management of colloid cysts of the third ventricle.

**Key Words:** Colloid cyst third ventricle, stereotactic aspiration, stereotactic radiosurgery

### Access this article online

**Website:**[www.surgicalneurologyint.com](http://www.surgicalneurologyint.com)**DOI:**

10.4103/sni.sni\_180\_17

**Quick Response Code:**

## INTRODUCTION

Colloid cysts of the third ventricle are benign lesions that account for less than 2% of all intracranial tumors.<sup>[1-3,7,8]</sup> These lesions have the ability to cause acute hydrocephalus and death in patients who were previously asymptomatic. Patients usually present with symptoms of increased intracranial pressure and require prompt intervention. Treatment options include permanent cerebrospinal fluid diversion with a shunt, craniotomy through a transcallosal approach, craniotomy through a transcortical-transventricular approach, endoscopic aspiration or resection, and stereotactic aspiration.<sup>[1]</sup> Each of these procedures has their own inherent benefits and pitfalls. Complications of the different surgical modalities include intraventricular hemorrhage, seizure, memory impairment, hemiparesis,

cranial nerve palsy, dysphasia, infection, and prolonged hospital stay. A simple stereotactic aspiration is very attractive for its low morbidity but is plagued by a high rate of recurrence. The authors believe that stereotactic radiosurgery may decrease the rate of recurrence of the stereotactically-aspirated colloid cysts. More recently, a case report of a symptomatic colloid cyst treated by a

This is an open access article distributed under the terms of the Creative Commons Attribution-NonCommercial-ShareAlike 3.0 License, which allows others to remix, tweak, and build upon the work non-commercially, as long as the author is credited and the new creations are licensed under the identical terms.

**For reprints contact:** [reprints@medknow.com](mailto:reprints@medknow.com)

**How to cite this article:** Morgan JP, McGraw SC, Asfora WT. Treatment of colloid cyst of the third ventricle by stereotactic aspiration followed by radiosurgery: Report of four cases. *Surg Neurol Int* 2018;9:3.

<http://surgicalneurologyint.com/Treatment-of-colloid-cyst-of-the-third-ventricle-by-stereotactic-aspiration-followed-by-radiosurgery:-Report-of-four-cases/>

ventricular peritoneal shunt followed by Gamma knife stereotactic radiosurgery showed no further growth of the cyst at the 43-month follow-up magnetic resonance imaging (MRI).<sup>[5]</sup>

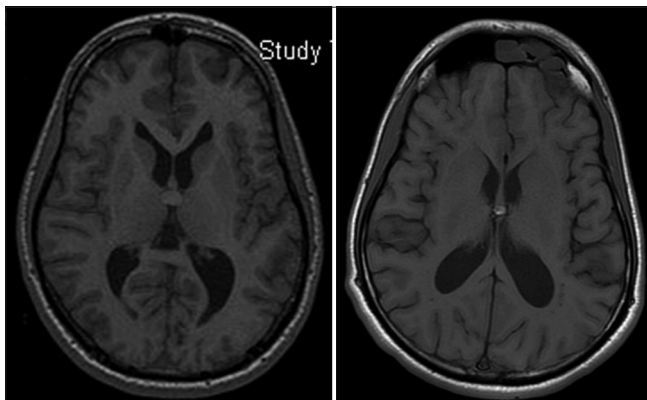
## CASE REPORTS

### Patient #1

A 23-year-old male presented to his primary care provider (PCP) in March 2006 with headaches, blurred vision, and diplopia. A computed tomography (CT) scan indicated mild ventricular dilation and a possible mass lesion in the region of the upper, anterior, third ventricle which was approximately 11 mm in size. A follow-up MRI revealed a hyperintense mass in the region of the foramen of Monro without significant obstructive hydrocephalus suggestive of a colloid cyst of the third ventricle measuring 11.2 mm in diameter. There was additional evidence of a pineal cyst measuring 6.34 mm. The patient was referred to our clinic in regards to operative treatment of the colloid cyst. Stereotactic aspiration of the cyst, followed by radiosurgery a week later was recommended and scheduled.

Accordingly, utilizing the Leksell frame and transaxial MRI scan of the brain without contrast [Figure 1, Left], the X-Y-Z coordinates for the target were calculated. Aspiration of the colloid cyst was performed with a 2.1-mm Sudan needle. Point of entry in the skull was just anterior to the right coronal suture and 2 cm to the right of the midline. A whitish mucoid material was then aspirated from the colloid cyst and sent to pathology. A postoperative CT scan did not reveal any residual proteinaceous material within the anterior third ventricle. The patient was discharged home the following day in excellent condition.

The patient initially declined postoperative radiosurgery. Approximately 6 weeks following stereotactic aspiration of the colloid cyst the patient returned for a follow-up



**Figure 1:** Axial MR images of patient #1. Left: Discovery 3-D FSPGR MRI showing the 11.2-mm colloid cyst lesion. Right: 6-month post-aspiration and radiosurgery T1 MRI demonstrating that the cyst was reduced in size to 7.3 mm

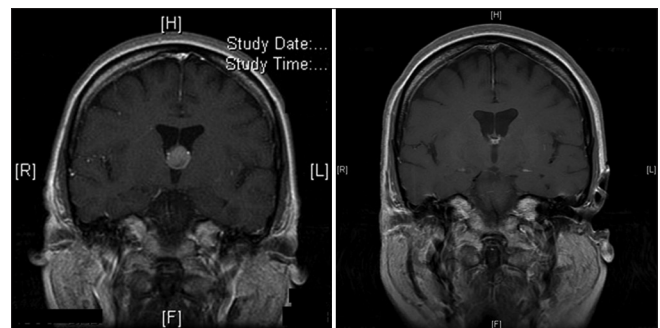
MRI. The MRI indicated a colloid cyst in the region of the foramen of Monro now measuring 5.5 mm in greatest diameter. The patient was again consulted by the radiation oncologist for the possibility of undergoing stereotactic radiosurgery for the recurrent cyst, however, he again elected to go home and discuss it with his friends and family before making a final decision.

Approximately 10 weeks following stereotactic aspiration of the colloid cyst the patient elected to undergo stereotactic radiosurgery of the colloid cyst. The patient was subsequently scheduled to undergo stereotactic radiosurgery 14 weeks after the initial aspiration. Previous MRI scans were used for three-dimensional (3D) treatment planning. Treatment was carried out uneventfully with the Novalis LINAC system (Westchester, IL). The head was mobilized by the stereotactic frame. The total prescribed single dose was 18 Gy delivered with a 6-mm collimator and six arcs.

Six months following stereotactic radiosurgery the patient underwent a follow-up MRI [Figure 1, Right] which revealed a lesion consistent with of a colloid cyst of the third ventricle measuring 7.3 mm in greatest dimension. The patient declined follow-up MRI but has reportedly remained asymptomatic since treatment for the last 10 years.

### Patient #2

The second patient was a 50-year-old woman who presented in October 2006 with numbness in her feet and a history of depression. Previous nerve conduction studies were normal. Due to a familial history of multiple sclerosis, an MRI was recommended. The MRI [Figure 2, Left] was significant for a 12-mm lesion at the anterosuperior aspect of the third ventricle in the region of the foramen of Monro suggestive of a colloid cyst. In January 2007, the patient presented again with severe headaches, dizziness, and memory loss associated with name recall difficulty for the past 5 days. At this point stereotactic aspiration of the colloid cyst was discussed and it was decided that the patient would be admitted

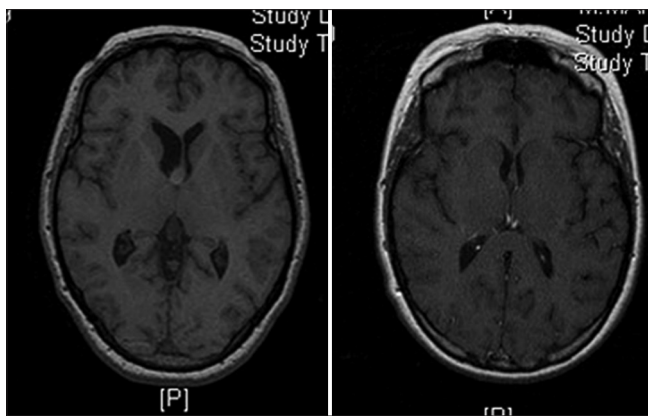


**Figure 2:** Coronal T1 MR images with gadolinium of patient #2. Left: Discovery MRI showing the 12-mm colloid cyst lesion at the anterosuperior aspect of the third ventricle. Right: 4-year post-aspiration and radiosurgery MR images demonstrating only the colloid cyst capsule remnants

to undergo this procedure. Stereotactic aspiration of the colloid cyst was performed, as described in case #1. Postoperatively, the patient indicated that her headache had improved and the dizziness appeared resolved. Five days after stereotactic aspiration of the colloid cyst, the patient underwent stereotactic radiosurgery of the residual lesion of the colloid cyst. The stereotactic radiosurgery was again performed similar to the procedure for patient #1. Following a detailed planning (unable to be recovered) of the procedure the total prescribed dose of 16 Gy was delivered by 5 dynamic conformal arcs utilizing the Novalis micro multileaf collimator for field shaping and blocking to a single isocenter. Treatment was carried out uneventfully and the patient was discharged home with follow-ups scheduled. The most recent MRI [Figure 2, Right] taken in January 2013 showed no evidence of recurrence of the colloid cyst. The patient has remained asymptomatic.

### Patient #3

A 42-year-old female with a significant history of depression with bipolar disorder initially presented to her family physician with complaints of headache, nausea, and vomiting over 2 weeks in January of 2009. An MRI [Figure 3, Left] revealed a mass measuring 7.7 mm × 7.2 mm within the anterior third ventricle at the foramen of Monro indicative of a colloid cyst. Stereotactic aspiration was carried out in a similar procedure as described above. Postoperatively, the patient stated that her headaches had markedly improved. The patient was then scheduled to undergo stereotactic radiosurgery for treatment of the residual cyst to prevent possible regrowth. A planning MRI [Figure 3, Right] revealed a reduction in ventricle size and no identifiable residual lesion of the colloid cyst. Based on the previous MRI, the stereotactic radiosurgical procedure was carried



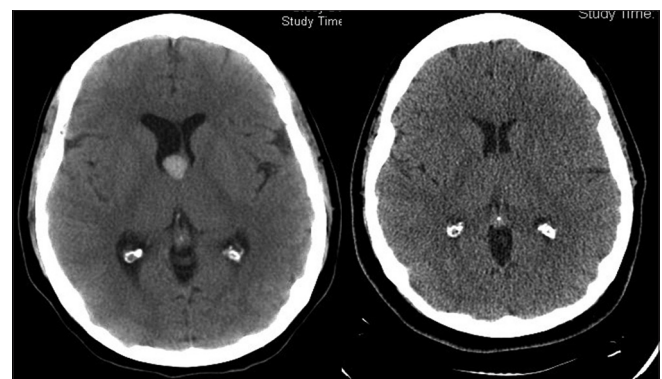
**Figure 3:** Radiologic images of patient #3. Left: Discovery MR image showing a mass within the anterior third ventricle at the foramen of Monro representative of a colloid cyst. Right: 6-week post-stereotactic aspiration and pre-stereotactic radiosurgery planning T1-weighted MRI demonstrating reduction in ventricle size as well as indicating that the colloid cyst is no longer identified by the imaging study

out in a fashion similar to that described above. A custom 5-arc radiosurgery plan with a 12.5-mm collimator using 16 Gy in a single fraction was developed and delivered to the isocenter utilizing the Novalis linear accelerator. Treatment was uneventful and the patient was discharged in excellent condition. The patient has remained asymptomatic since treatment. The patient has declined follow-up MRIs.

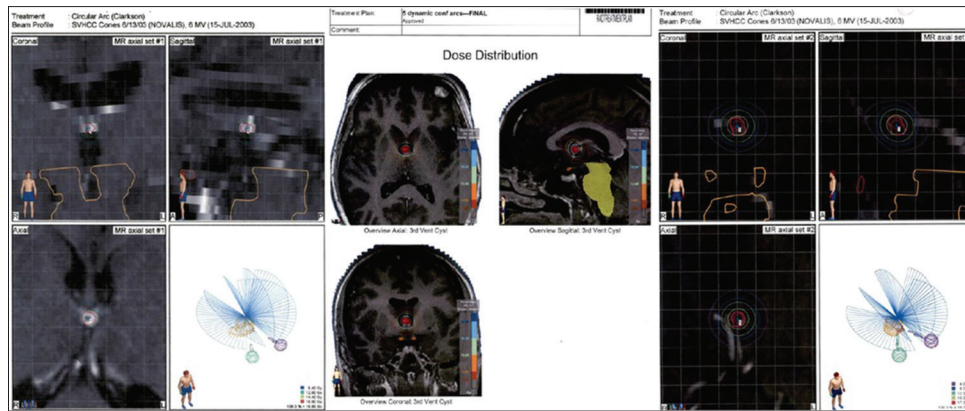
### Patient #4

In June 2009, a 29-year-old female patient presented to her local clinic with complaints of headache, nausea, and vomiting. The patient had experienced migraine headaches since the age of 13. CT scan of the brain [Figure 4, Left] revealed that there was evidence of a hyperdense colloid cyst within the right third ventricle at the junction of the foramen of Monro with mild dilation of the right lateral ventricle. The patient was scheduled for stereotactic aspiration of the colloid cyst to be followed by stereotactic radiosurgery.

Two weeks after aspiration, stereotactic radiosurgery was performed. The planning MRI revealed a small somewhat ovoid area of mixed signal intensity seen along the posterior-inferior margin of the septum pellucida in the expected area of the anterior roof of the third ventricle at a level corresponding to the foramen of Monro. These changes correspond with the area of increased attenuation on prior CTs with the size of residual lesion/cavity measuring 8.6 mm cephalo-caudad × 4.7 mm anterior-posterior × 5.7 mm transverse. The target was outlined, the isocenter was identified, and the total prescribed dose of 16 Gy was delivered by means of 7 dynamic arcs in a single fraction utilizing the Novalis micro multileaf collimator for field shape and field blocking. Treatment was uneventful and the patient was discharged in excellent condition. Three months following stereotactic radiosurgery of the colloid cyst lesion, the patient returned for a follow-up MRI (with and without gadolinium) which showed an area of approximately 6 mm of mixed signal



**Figure 4:** Axial CT scans of patient #4. Left: Discovery CT scan showing a colloid cyst of 13 mm with dilatation of the lateral ventricles and slight asymmetry on the right. Right: CT scan at 6-year follow-up demonstrating absence of the colloid cyst



**Figure 5: Stereotactic radiosurgery planning images for patient #1 (Left), patient #3 (Center), and patient #4 (Right)**

at the anterosuperior aspect of the third ventricle in the region of the foramen of Monro. The appearance was not significantly changed from previous exams and there was no increase in fluid content. The most recent axial CT without contrast [Figure 4, Right] from October 2015 demonstrates that the previously noted hyperdense presumed colloid cyst is no longer present. Though it is well demonstrated the patient has been cleared of the colloid cyst she still experiences migraine headaches.

## DISCUSSION

Stereotactic aspiration of colloid cyst followed by stereotactic radiosurgery with a LINAC system has been very successful in treating four patients. No recurrence or complication related to stereotactic aspiration or radiosurgery has been observed now at a 10-year follow-up in 2 patients and 7-year follow-up in the other 2 patients. This modality of treatment is certainly attractive considering the duration of the procedures, short hospital stay, rapid recovery, and return to work, as opposed to the multitude of possible complications reported with surgical resection, including loss of short-term memory secondary to fornix injury.<sup>[5]</sup> The authors have more recently treated two other patients utilizing the same technique, but these were not included in the present report as follow-up is less than 2 years.

The partial re-accumulation of the colloid cyst in the first patient is probably secondary to the fact that radiosurgery was only performed 14 weeks following stereotactic aspiration. Following radiosurgery, the tumor size remained stable and the patient is asymptomatic now at 10 years following treatment. The above suggests that, in patients who are asymptomatic but cyst size is enlarging on follow-up radiological investigation, radiosurgery may be an option to arrest growth and prevent symptoms.

The choice of dose was somewhat arbitrary as there was no report regarding the utilization of stereotactic

radiosurgery for the treatment of colloid cysts, however, dose prescription was calculated based on the work of Dr. Raymond Kjellberg<sup>[4]</sup> related to the risk of radiation necrosis according to target volume (isoeffective centile curve) and experience accumulated from the radiosurgical treatment of other benign lesions, such as acoustic neuromas, meningiomas, and craniopharyngiomas, which have been successfully treated with doses ranging from 12–20 Gy. Craniopharyngioma is most analogous to colloid cyst as both are cystic-type lesions. In craniopharyngiomas it is important to cover the cyst wall with the prescription dose to prevent recurrence and/or progression. The Radiation Therapy Oncology Group stereotactic radiosurgery dose escalation protocol demonstrated that for a lesion under 3 cm, that the threshold for a 10% risk of neurotoxicity was 16 Gy, and for a lesion under 2 cm was 21 Gy. In the four reported patients, the dose prescribed was between 16–21 Gy to cover the cyst wall to at least the 90% isodose line, [Figure 5] anticipating a local control of at least 80%.<sup>[6]</sup>

It is unclear as to exactly why the colloid cysts in our patients have not re-occurred. However, radiation is well-known to cause changes in the mucous production of goblet cells, which is likely the mechanism of action. It is also possible that de-vascularization of the cyst or damage to the epithelial cells from the radiosurgery is what prevents fluid re-accumulation. Another issue is the fact that colloid cysts may move according to body position. To minimize this factor all investigations, stereotactic aspiration, and radiosurgery were performed in a supine position with the head mildly flexed. The cyst might be isodense on the CT scan or isointense on T1 and T2 images of the MRI. The flair sequence usually demonstrates the lesion well and we could aspirate the colloid cyst contents in all cases without technical difficulty using a 2.1 Sudan needle and Leksell frame. Likewise, the radiation dose prescribed to the relatively small cyst volume was safe and not associated with any radiation-induced changes to the adjacent neural structures.



## CONCLUSION

In conclusion, the combination of stereotactic aspiration and radiosurgery may have a role in the management of colloid cysts of the third ventricle.

### Declaration of patient consent

The authors certify that they have obtained all appropriate patient consent forms. In the form the patient has given their consent for their images and other clinical information to be reported in the journal. The patient understands that name and initial will not be published and due efforts will be made to conceal identity, but anonymity cannot be guaranteed.

### Financial support and sponsorship

Nil.

### Conflicts of interest

There are no conflicts of interest.

## REFERENCES

1. Berger MS, Prados M. Textbook of neuro-oncology, 1<sup>st</sup> ed. Philadelphia: Elsevier Saunders; 2005. pp. 854.
2. Hernesniemi J, Leivo S. Management outcome in third ventricular colloid cysts in a defined population: A series of 40 patients treated mainly by transcallosal microsurgery. *Surg Neurol* 1996;45:2-14.
3. Kahn EA. Correlative neurosurgery. In: Thomas CC, editor. 2<sup>nd</sup> ed. Springfield, Ill.: Thomas; 1969. pp. 693.
4. Kjellberg RN. Isoeffective dose parameters for brain necrosis in relation to proton radiosurgical dosimetry. In: Szikla G, editor. Stereotactic Cerebral Radiation. Amsterdam: Elsevier Press; 1979. pp. 157-66.
5. Lustgarten L. Is there room for stereotactic radiosurgery as an option for third ventricular colloid cysts in patients refusing surgery? A case report and some therapeutic considerations. *Surg Neurol Int* 2015;6(Suppl 15):S402-5.
6. Shaw E, Scott C, Souhami L, Dinapoli R, Kline R, Loeffler J, et al. Single dose radiosurgical treatment of recurrent previously irradiated primary brain tumors and brain metastases: Final report of RTOG protocol 90-05. *Int J Radiat Oncol Biol Phys* 2000;47:294-8.
7. Yenermen MH, Bowerman CI, Haymaker W. Colloid cyst of the third ventricle; a clinical study of 54 cases in the light of previous publications. *Acta Neuroveg (Wien)* 1958;17:211-77.
8. Zülch KJ. Brain tumors: Their biology and pathology. 3<sup>rd</sup> ed. Berlin Heidelberg: Springer-Verlag; 1986.