

## CASE REPORT

## Cases Diagnosed with Swyer James Macleod Syndrome in Adulthood

Emine Aksoy<sup>1</sup>, Oğuz Aktaş<sup>1</sup>, Fatma Tokgöz<sup>1</sup>, Nilufer Kongar<sup>1</sup>, Nezihe Gökşenoğlu<sup>1</sup>, Yasemin Bodur<sup>1</sup>, Salih Güran<sup>2</sup>, Tülin Sevim<sup>1</sup>

<sup>1</sup>Clinic of Chest Diseases, Süreyyapaşa Chest Diseases Hospital, İstanbul, Turkey

<sup>2</sup>Department of Radiology, Sonomed Imaging Centre, İstanbul, Turkey

## Abstract

Swyer-James-MacLeod syndrome or unilateral hyperlucent lung syndrome is a rare disease characterised by hypoplasia of the pulmonary artery, unilateral hyperlucent lung and usually bronchiectasis. The syndrome was first described by Swyer and James in 1953 in a child case, and in the following year 9 adult cases were reported by MacLeod. We retrospectively reviewed 6 adult cases, five female and one male, who were followed-up with the diagnosis of Swyer-James-MacLeod syndrome between 2005 and 2012 in our clinic. The clinical and radiological features of these 6 cases are presented in the light of the literature.

**KEY WORDS:** Bronchiectasis, hyperlucent lung, pulmonary artery

**Received:** 13.11.2013

**Accepted:** 17.02.2014

**Available Online Date:** 11.07.2014

### INTRODUCTION

Swyer-James-MacLeod syndrome (SMJS, unilateral hyperlucent lung) is a rare disease characterized by pulmonary artery hypoplasia, unilateral hyperlucency, and frequently, bronchiectasis. It was first defined in 1953 by Swyer and James in a 6-year-old boy. Angiocardiography of the patient, who was investigated due to frequent respiratory tract infections and unilateral hyperlucent lung, demonstrated notable hypoplasia in the right pulmonary artery [1]. One year later, Macleod defined this syndrome in 9 adult cases with unilateral pulmonary hyperlucency [2]. The prevalence of this syndrome was reported to be 0.01% in a study that evaluated 17,450 chest x-rays [3].

The present study retrospectively evaluated clinical and radiological characteristics of 6 adult cases (5 females, 1 male) diagnosed with Swyer-James-MacLeod syndrome at our clinic between 2005 and 2012. Verbal consent was obtained from all participants.

### CASE PRESENTATIONS

#### Case 1

A 27-year-old female patient presented with cough and sputum mixed with blood lasting for 1 month. She had had measles infection at the age of 1 year. Posteroanterior (PA) chest x-ray demonstrated a small right hilum and hyperaeration in the inferior lobe of the right lung; high resolution computed tomography (HRCT) of thorax demonstrated bilateral cystic bronchiectasis at the inferior lobes (Figure 1). Ventilation perfusion (V/Q) scintigraphy revealed that perfusion and ventilation was remarkably decreased in the right inferior lobe. Upon detecting hypoplasia in the descending branch of the right pulmonary artery on magnetic resonance (MR) angiography of the chest, the patient was diagnosed with SJMS. She was then diagnosed with cystic fibrosis on further analyses performed for bilateral bronchiectasis.

#### Case 2

A 32-year-old female patient presented with cough and hemoptysis lasting for 9 days. Her anamnesis revealed that she had had pneumonia at the age of 2 years and has had hemoptysis for 8 years at intervals. Severe obstruction and moderate restriction was determined on spirometric examinations. Chest x-ray revealed a small right hilum and increased aeration in the right lung; HRCT demonstrated varicose bronchiectasis in the right superior lobe and cylindrical bronchiectasis in the right inferior lobe (Figure 2). Upon detecting hypoplasia beginning from the proximal of the right main pulmonary artery on thoracic MR angiography, the patient was diagnosed with SJMS.

#### Case 3

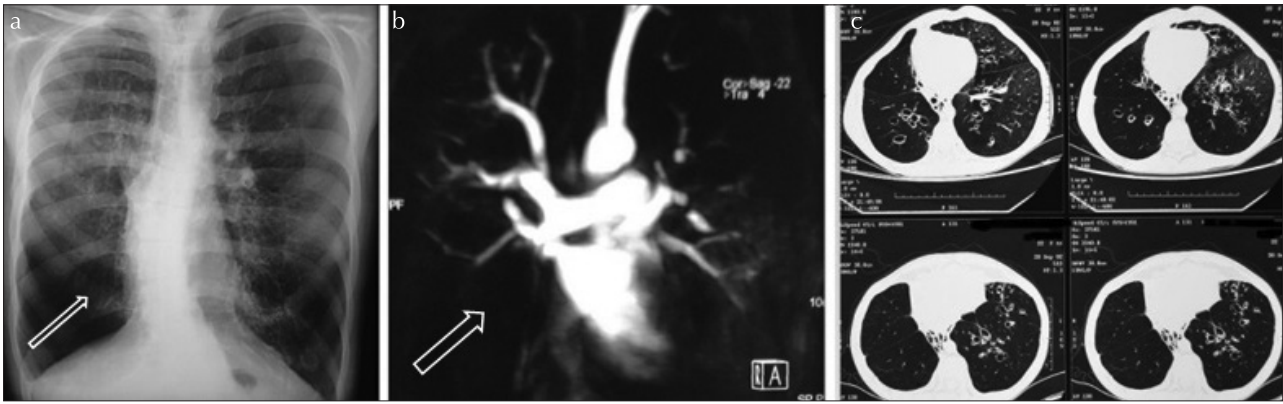
A 37-year-old female patient presented with gradually worsening shortness of breath in the last several months. She had no history of previous pulmonary disease. Spirometric evaluation revealed moderate-severe obstruction and moderate



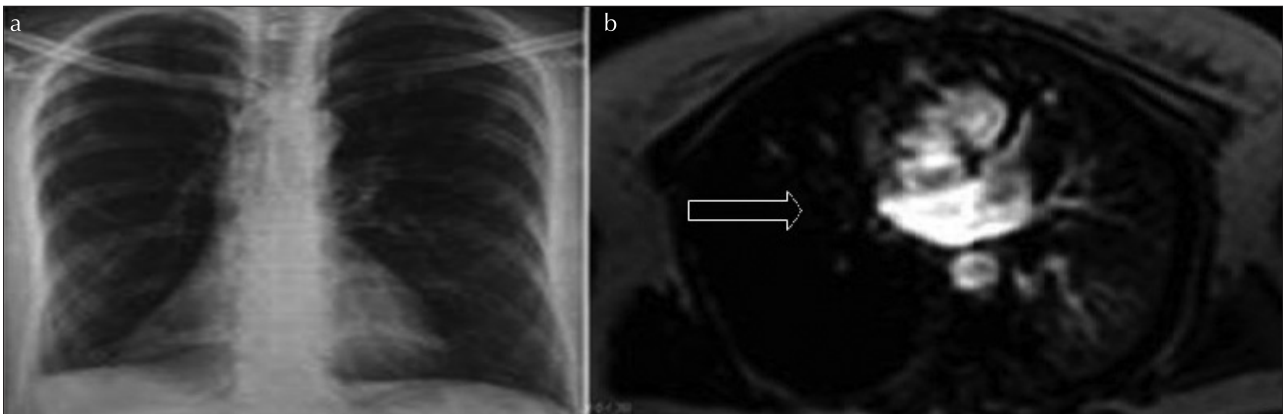
**Address for Correspondence:** Tülin Sevim, Clinic of Chest Diseases, Süreyyapaşa Chest Diseases Hospital, İstanbul, Turkey

Phone: +90 532 327 08 02 E-mail: tsevim2001@gmail.com

©Copyright 2015 by Turkish Thoracic Society - Available online at [www.toraks.dergisi.org](http://www.toraks.dergisi.org)



**Figure 1. a-c.** Case 1, PA chest x-ray: small right hilum, increased aeration in the inferior lobe of the right lung (arrow); MR angiography: hypoplasia in the descending branch of the right pulmonary artery (arrow); HRCT: bilateral cystic bronchiectasis



**Figure 2. a, b.** Case 2, PA chest x-ray: small right hilum and increased aeration in the right lung; MR angiography: hypoplasia in the right pulmonary artery (arrow), decrease in vascularization as compared to the left lung

restriction. On her PA chest x-ray, mediastinum was displaced towards the left, left lung volume was decreased with increased hyperlucency (Figure 3). Thoracic CT demonstrated ground glass opacity areas in the inferior lobe of the right lung and varicose bronchiectasis in the inferior lobe of the left lung, whereas perfusion scintigraphy revealed that pulmonary perfusion in the left lung was 5%. Detecting hypoplasia in the arising portion of the left pulmonary artery on MR angiography, the patient was diagnosed with SJMS.

#### Case 4

A 45-year-old female patient presented with weight loss. The patient, who has had recurrent lower respiratory tract infections since early childhood, had undergone left inferior lobectomy at the age of 12 years due to bronchiectasis. Her PA chest x-ray demonstrated mediastinal shift towards left and decreased left lung volume. On her thoracic CT, there were lesions consistent with sequel and cylindrical bronchiectasis in the left lung (Figure 4). Detecting hypoplastic left main pulmonary artery on MR angiography, the patient was diagnosed with SJMS.

#### Case 5

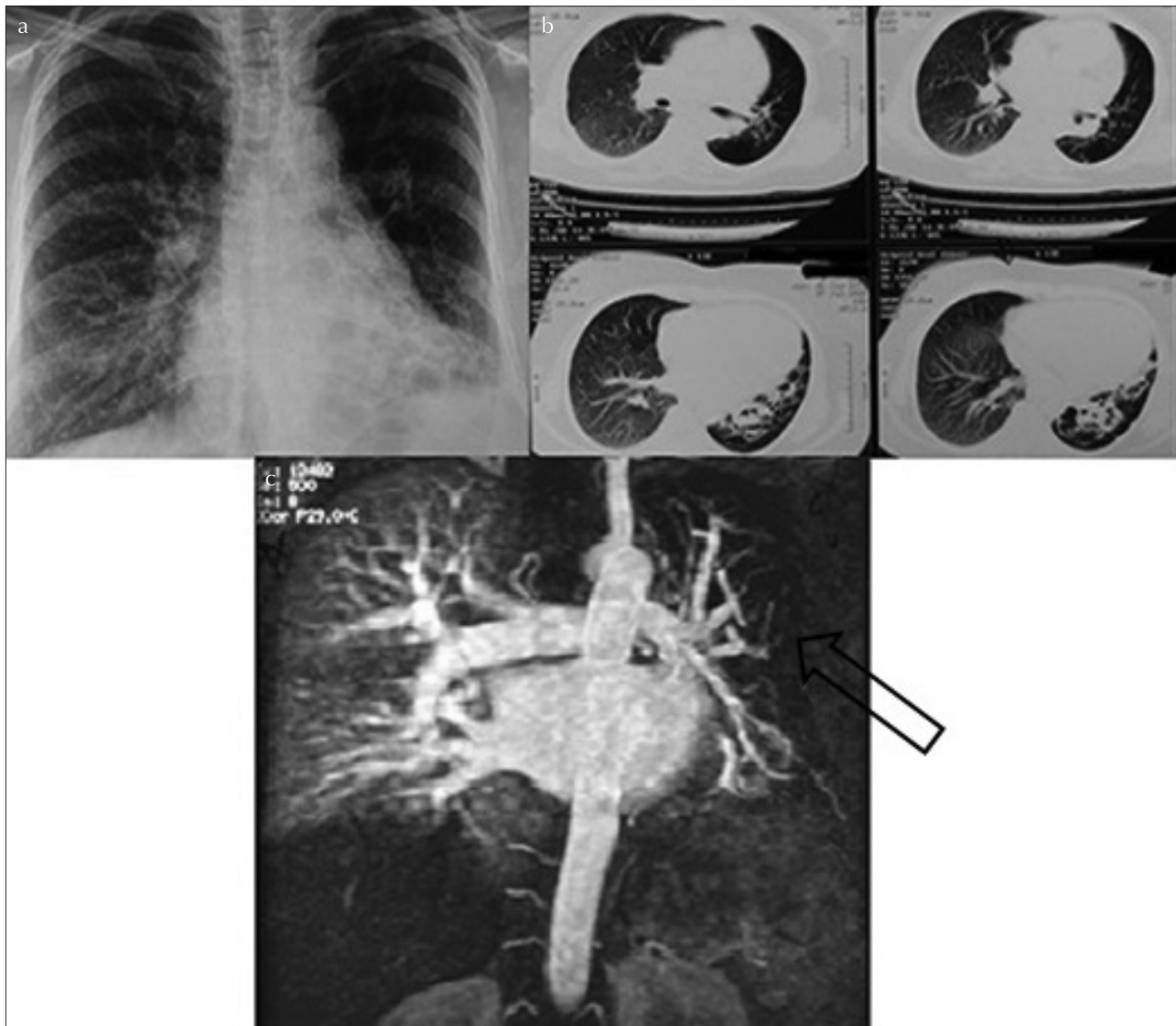
A 60-year-old female patient presented with shortness of breath. She had had pneumonia in early childhood and has been receiving bronchodilator therapy for asthma since her youth. She had normal respiratory function test results. PA chest x-ray revealed a small left hilum and hyperlucency in the left lung; V/Q scintigraphy revealed decreased ventilation

and perfusion in the left lung (87% perfusion in the right lung and 13% perfusion in the left lung) (Figure 5). Detecting hypoplasia beginning from the arising portion of the left main pulmonary artery on CT angiography, she was diagnosed with SJMS.

#### Case 6

A 63-year old male patient presented with shortness of breath that has worsened for the last one week. He has been receiving bronchodilator therapy for 20 years with a diagnosis of chronic obstructive pulmonary disease (COPD). He had had pneumonia in his childhood, and had a history of hospitalization for once or twice in a year due to lower respiratory tract infections and COPD exacerbations. Severe obstruction and restriction were determined on spirometric evaluation. PA chest x-ray demonstrated a small right hilum and increased aeration in the right lung; V/Q scintigraphy revealed decreased ventilation and perfusion in the right lung (15% perfusion in the right lung and 85% perfusion in the left lung) (Figure 6). Detecting cystic bronchiectasis in the right superior lobe and hypoplasia at the distal aspect of the right pulmonary artery on contrast enhanced thoracic CT; the patient was diagnosed with SJMS.

Except for Case 1 who had fever and high white blood cell count, vital signs and laboratory data of the other cases were normal and extra-pulmonary system examination was unremarkable. They had no significant history of smoking. At diagnostic phase, fiberoptic bronchoscopy was performed in



**Figure 3. a-c.** Case 3, PA chest x-ray: displacement of the mediastinum towards left, small left hilum, volume loss and increase in aeration in the left lung. Thoracic CT: varicose bronchiectasis in the left inferior lobe; MR angiography: hypoplasia in the left pulmonary artery (arrow)

Cases 2 and 4, but the result was unremarkable. The general characteristics of the cases are demonstrated in Table 1, and PA chest x-ray findings are demonstrated in Table 2.

After the diagnosis was made, patients were informed about the syndrome and were taken to follow-up.

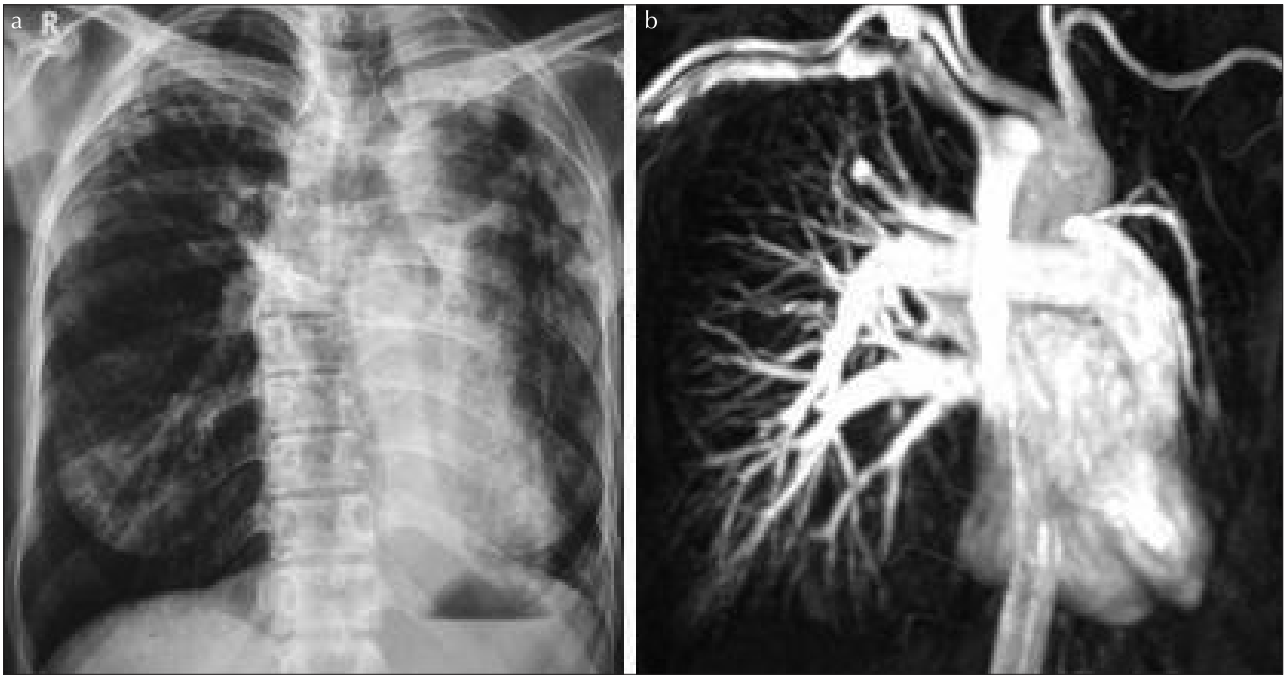
### DISCUSSION

Swyer-James-MacLeod syndrome is defined as bronchiolitis obliterans following pneumonia in early childhood. Bronchiolitis obliterans usually occurs due to viral lower respiratory tract infections, particularly to adenovirus, influenza, *Bordetella pertussis* infection and measles. *M.tuberculosis* and *M. pneumoniae* are as well detected, although less frequently [4]. However, some series reported cases without a history of significant infection. For example, in a 4-case series, 3 patients had no history of infection in childhood [5].

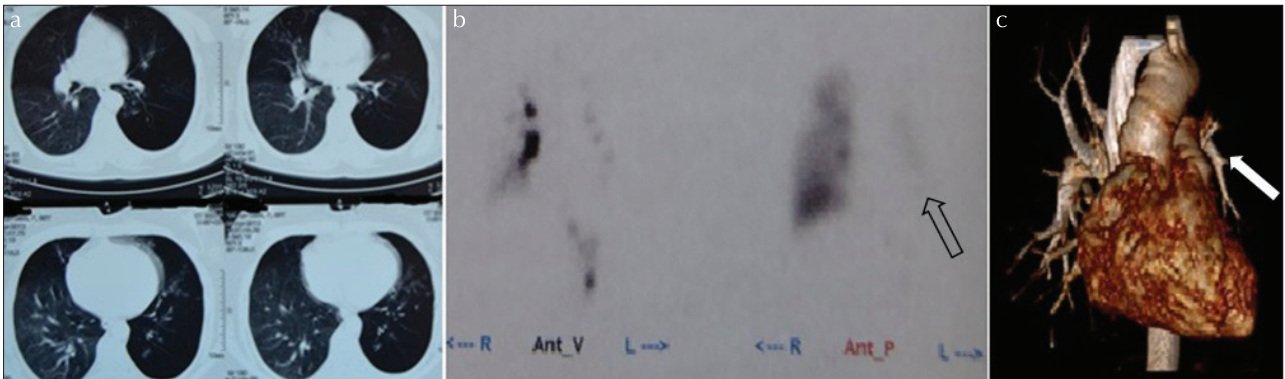
Pulmonary infection in early childhood leads to destruction in bronchial epithelium and elastic tissue. There is submucosal

fibrosis leading to luminal narrowing and irregularity in the airways. There is hypoplasia in the vascular structures and hyperinflation and panacinar emphysematous changes occur in the distal aspect of the involved bronchiole. Loss of ciliary motility enhances tendency to secondary infections [6,7]. As the consequence, it has been demonstrated that cases with SJMS histopathologically develop emphysema, cystic cavities that indicate cystic bronchiectasis, interstitial chronic inflammatory changes, bronchial lymphatic tissue hyperplasia, diffuse obliteration in the pulmonary capillary bed, pulmonary arterial hypertrophy, bronchitis, bronchiolitis, peribronchial fibrosis, and smooth muscle proliferation [8]. In the present series, 5 of the cases had a history of infection in childhood, one of which was pneumonia secondary to measles, whereas no specific agent was identified in the remaining four.

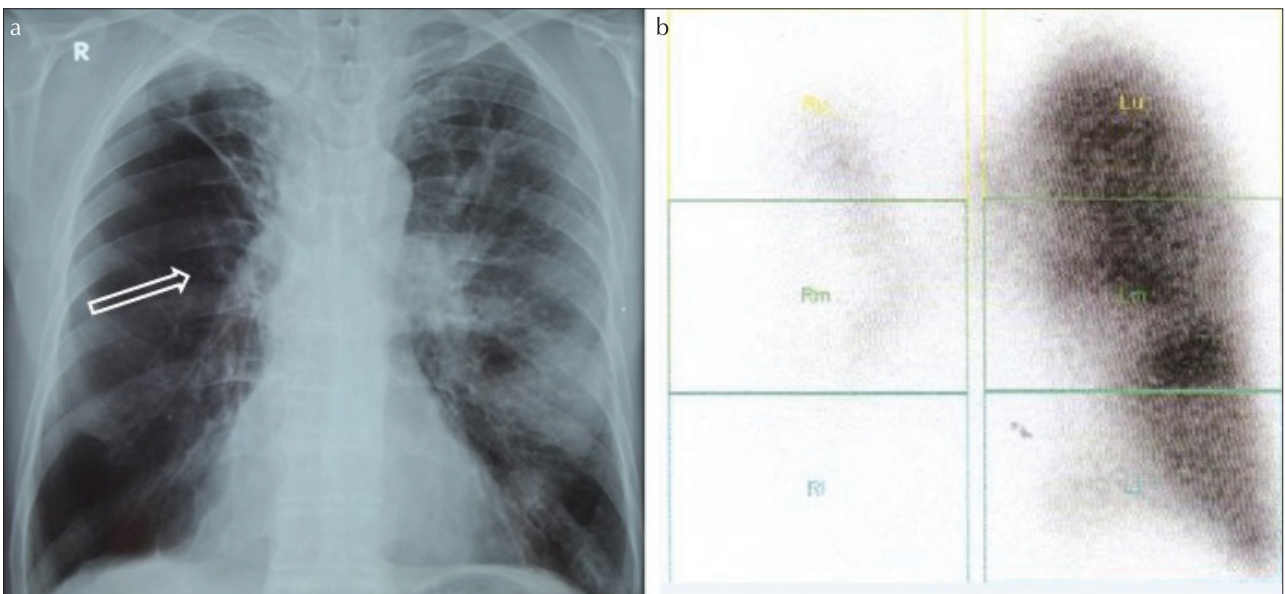
Diagnosis of the syndrome can be made from 7 to 70 years [9,10] and primarily suspect is necessary for diagnosis. Adult cases are generally asymptomatic. It may be accidentally detected on chest x-ray performed for another reason. However, some patients may complain about cough, recur-



**Figure 4. a, b.** Case 4, PA chest x-ray: displacement of the mediastinum towards left, decrease in the volume of left lung and changes consistent with sequel. MR angiography: hypoplasia in the left pulmonary artery



**Figure 5. a-c.** Case 5, V/Q scintigraphy: decrease in ventilation and perfusion of the left lung (arrow), CT angiography: hypoplasia beginning from the arising portion of the left main pulmonary artery (arrow)



**Figure 6. a, b.** Case 6, PA chest x-ray: small right hilum (arrow) and increased aeration in the right lung. V/Q scintigraphy: decrease in ventilation and perfusion of the right lung

**Table 1. General characteristics of the cases**

Case no	Age/gender	Complaint	Duration of complaint	Concomitant disease	Respiratory system examination	History of LRTI	Bronchiectasis	Involved artery
1	27/F	Cough, bloody sputum	1 month	-	Bilateral rales in the middle and inferior lobes, finger clubbing	Measles (at the age of 1 years)	Bilateral, cystic, extensive	Right pulmonary artery inferior branch
2	32/F	Cough hemoptysis	9 days Hemoptysis at intervals for 8 years	Asthma	Bilateral sibilant rhonchi, rales in the right basal area	Pneumonia (at the age of 2 years)	Right lung, varicose and cylindrical	Right pulmonary artery
3	37/F	Shortness of breath	2-3 months	HT	Decreased breathing sounds in the left basal area, end-inspiratory rales	-	Left inferior lobe, varicose	Left pulmonary artery
4	45/F	Weight loss	5-6 months	-	Normal	Pneumonia (early childhood)	Left lung, cylindrical	Left pulmonary artery
5	60/F	Shortness of breath	Several months	Asthma	Normal	Pneumonia (early childhood)	-	Left pulmonary artery
6	62/M	Shortness of breath	20 years	COPD, CAD	Decreased breathing sounds, prolonged expiratory phase	Pneumonia (early childhood)	Right superior lobe, cystic	Left pulmonary artery

F: female; M: male; HT: hypertension; COPD: chronic obstructive pulmonary disease; CAD: coronary artery disease; LRTI: lower respiratory tract infection; Early childhood: 0-5 years

**Table 2. PA chest x-ray findings of the cases**

Case	Mediastinal Displacement	Small hilar Shadow	Increase in lucency	Decrease in vascularization
1	No	Yes	Yes	Yes
2	No	Yes	Yes	Yes
3	Yes	Yes	Yes	Yes
4	Yes	No	No	No
5	No	Yes	Yes	Yes
6	No	Yes	Yes	Yes

rent pulmonary infections, decrease in exercise capacity, and hemoptysis [11]. In the present series, the ages of the patients were changing between 27 and 64 years and they have not been diagnosed with SJMS until today. One of the cases was being investigated due to weight loss and had no respiratory complaint, whereas two of the cases had cough and hemoptysis and three had shortness of breath. Two of the cases were under treatment for asthma and one case was treated for COPD. A more detailed anamnesis revealed that three cases had had recurrent lower respiratory tract infections.

The most significant findings detected on chest x-rays were a small hilar shadow, decreased pulmonary vascularity at the involved side, increased lucency of one lung and mediastinal displacement towards the involved side [4,12]. X-rays obtained during expiration reveal that movement of the diaphragm of the involved side is restricted and the difference in lucency between two lungs becomes remarkable [2]. In

the present series, the most common PA chest x-ray findings were decreased vascular shadows and increased lucency. Displacement of the mediastinum was determined in only one case (Table 2).

When difference in aeration between two lungs is seen on chest x-ray, primarily the patient's position must be evaluated. Differential diagnosis of unilateral hyperlucent lung includes parenchymal lung diseases (unilateral emphysema or bullous lung), airway diseases (foreign body aspiration, endobronchial mass, congenital lobar emphysema, bronchial atresia), vascular diseases (pulmonary agenesis or hypoplasia, scimitar syndrome, unilateral central pulmonary embolus), pleural diseases (pneumothorax), and chest wall diseases (Poland syndrome, scoliosis) [13]. In a series comprising 40 patients that were investigated for unilateral hyperlucent lung, prevalence of SJMS was 45%, local emphysema was 20%, congenital pulmonary artery hypoplasia was 10%, pulmonary embolus was 10%, bronchial carcinoma was 7.5%, radiotherapy sequel was 5%, and endobronchial tumour was 2.5% [14]. All of the present cases underwent CT or MR angiography due to suspicious PA chest x-ray. SJMS was considered because of aeration differences and small hilar shadow in 5 and due to mediastinal displacement in one case on chest x-ray. Angiography reveals that main pulmonary artery and branches are smaller than normal, there are filling defects, and decreased peripheral branching [4,15]. In the present series, vascular structure was evaluated by MR angiography in 4 cases, by CT angiography in one case, and by contrast-enhanced CT in another case.

Pulmonary artery hypoplasia and agenesis are the other vascular diseases in the differential diagnosis. Whilst volume decrease is detected in pulmonary artery hypoplasia, lung volume is decreased in the involved side, no air trapping is observed on radiographs obtained during expiration, almost no perfusion is observed in the involved side on V/Q scintigraphy, and ventilation is normal in the pulmonary artery agenesis [16,17]. Moreover, pulmonary artery agenesis is usually seen together with other cardiovascular anomalies. None of the present cases had additional cardiovascular abnormalities, perfusion was notably low in scintigraphy, and the involved vessel was observed to be hypoplastic on angiography.

On computed tomography, there may be patchy, low-attenuated and hypovascular areas among normal parenchyma, bronchiectasis, bronchiolectasis, atelectasis, and sequel changes [18,19]. Although bronchiectasis is not present in all patients, it influences clinical course and prognosis. In their 13-case series, Lucaya et al. reported 9 patients with bronchiectasis, 5 cystic and 4 cylindrical, and determined that pneumonia was more prevalent in cases with cystic bronchiectasis [20]. In the present case series, two cases had cystic bronchiectasis areas, whereas three cases had varicose and/or cylindrical bronchiectasis. Of the three cases with frequent respiratory tract infections, two had cystic bronchiectasis, and one had cylindrical bronchiectasis, and had undergone lobectomy. Bronchiectasis was not present in one of the cases.

Ventilation perfusion scintigraphy demonstrates decreased ventilation and perfusion in the involved areas [21]. Distal airway obstruction (asthma, congenital lobar emphysema) as well, displays similar outcomes [22]. V/Q scintigraphy was performed in 4 cases and decreased perfusion, particularly in the involved side was detected.

Restrictive pattern is the expected spirometric finding, but obstructive pattern may also be seen due to bronchiolitis and bronchiectasis [7]. In the present series, one out of 4 cases that underwent respiratory function testing was considered normal and 3 were considered to have mixed type dysfunction.

Treatment is usually symptomatic and prognosis is good. However, surgical resection may be required if infections secondary to bronchiectasis cannot be improved with anti-biotherapy or if there is uncontrollable hemoptysis [22,23].

In the present series, one case had undergone lobectomy at the age of 12 years due to frequent infections, whereas bronchial artery embolization was performed due to hemoptysis in one case. Diagnosed cases have remained stable until today; all cases have been informed about SJMS and are being clinically followed up at certain intervals.

In conclusion, Swyer James MacLeod syndrome should be kept in mind in cases with unilateral hyperlucent lung and small hilar shadow, even if they are at advanced age.

**Informed Consent:** Written informed consent was obtained from patients who participated in this case.

**Peer-review:** Externally peer-reviewed.

**Author Contributions:** Concept - E.A., O.A., F.T., N.K., N.G., Y.B., T.S., S.G.; Design - E.A., O.A., F.T., N.K., N.G., Y.B., T.S., S.G.; Supervision - E.A., O.A., F.T., N.K., N.G., Y.B., T.S., S.G.; Funding - E.A., F.T., T.S.; Data Collection and/or Processing - E.A., O.A., F.T., N.K., N.G., Y.B., T.S., S.G.; Analysis and/or Interpretation - E.A., O.A., F.T., N.K., T.S.; Literature Review - E.A., O.A., F.T., N.K., N.G., Y.B., T.S., S.G.; Writer - E.A., O.A., F.T., N.K., T.S., S.G.; Critical Review - E.A., O.A., F.T., N.K., T.S.

**Conflict of Interest:** No conflict of interest was declared by the authors.

**Financial Disclosure:** The authors declared that this study has received no financial support.

## REFERENCES

- Swyer PR, James GCW. A case of unilateral pulmonary emphysema. *Thorax* 1953;8:133. [\[CrossRef\]](#)
- Macleod WM. Abnormal transradiancy of one lung. *Thorax* 1954;9:147. [\[CrossRef\]](#)
- Tortajada M, Gracia M, García E, Hernández R. Diagnostic considerations in unilateral hyperlucency of the lung (Swyer-James-MacLeod Syndrome). *Allergol Immunopathol (Madr)* 2004;32:265-70. [\[CrossRef\]](#)
- Piquette CA, Rennard SI, Snider GL. Chronic bronchitis and emphysema. In: Murray JF, Nadel JA. *Textbook of Respiratory Medicine*. Third edition. Philadelphia:W.B.Saunders Company; 2000:1187-245.
- Sen SH, Taylan M, Abakay Ö, et al. Adult diagnosis of Swyer-James-Macleod Syndrome: Retrospective Analysis of Four Cases. *Respir Care* 2013 Sep 11 [Epub ahead of print].
- Chopra S, Aggarwal N, Suri S, Thami MR. Successful pregnancy outcome in Swyer-James-Macleod syndrome. *Ann Thorac Med* 2008;3:26-7. [\[CrossRef\]](#)
- Collins J, Stern EJ. Unilateral hyperlucent lung. In: Collins J, Stern EJ (edi). *Chest radiology: the essentials*. Philadelphia:Lippincott Williams & Wilkins, 1999:207-8.
- Koyama T, Osada H, Kitanaka Y, et al. Surgically treated Swyer-James syndrome. *Jpn J Thorac Cardiovasc Surg* 2001;49:671-4. [\[CrossRef\]](#)
- Wang W, Shen KL, Zeng JJ. Clinical studies of children with bronchiolitis obliterans. *Zhonghua Er Ke Za Zhi* 2008;46:732-8.
- Yıldız F, Sever M, Kömür N, et al. Macleod Syndrome accompanied by right middle lobe agenesis. *Türk Thorac J* 2010;11:87-9. [\[CrossRef\]](#)
- Şentürk E, Ekici A, Bulcun E, et al. The rare cause of effort dyspnea: swyer james (mac leod) syndrome. *Journal of Izmir Chest Diseases Hospital* 2009;23:101-5.
- Gopinath A, Strigun D, Banyopadhyay T. Swyer-James syndrome. *Conn Med* 2005;69:325-7.
- Dillman JR, Sanchez R, Ladino-Torres MF, et al. Expanding upon the unilateral hyperlucent hemithorax in children. *Radio Graphics* 2011;31:723-41. [\[CrossRef\]](#)
- Hekali P, Halnunen P, Kurlioğlu O, et al. Chronic unilateral translucent lung. A consecutive series of 40 patients. *Radiographics* 1999;23:1-3.
- Günen H, Kızkın O, Hacıevliyagil SS, Kotuk M. Unilateral hyperlucent lung syndrome - Swyer- James (Mac Leod ) syndrome- a case report. *Eurasian Journal of Pulmonology* 2003;200:37-40.
- Bouros D, Pare P, Panagou P, et al. The varied manifestation of pulmonary artery agenesis in adulthood. *Chest* 1995;108:670-6. [\[CrossRef\]](#)
- Ghossain MA, Achkar A, Buy JN, et al. Swyer James syndrome documented by spiral CT angiography and high resolution inspiratory and expiratory CT: an accurate single modality exploration. *J Comput Assist Tomogr* 1997;21:616-8. [\[CrossRef\]](#)

18. Moore AD, Godwin JD, Dietrich PA, et al. Swyer-James syndrome: CT findings in eight patients. *Am J Roentgenol* 1992;158:1211-5. [\[CrossRef\]](#)
19. Marti-Bonmati L, Ruiz Perales F, Catala F, et al. CT findings in Swyer-James syndrome. *Radiology* 1989;172:477-80. [\[CrossRef\]](#)
20. Lucaya J, Gartner S, García-Peña P, et al. Spectrum of manifestations of Swyer-James-MacLeod syndrome. *J Comput Assist Tomogr* 1998;22:592-7. [\[CrossRef\]](#)
21. Mera A, Ichikado K, Wada M, et al. A case of Swyer-James syndrome with interesting chest radiographs. *Nihon Kokyuki Gakkai Zasshi* 2006;44:354-8.
22. Kaplanoglu H, Kaplanoglu V, Toprak U, et al. A case of swyer-james-macleod syndrome associated with middle lobe hypoplasia and arteriovenous malformation. *Case Rep Med* 2012;2012:959153.
23. Vishneusky AA, Nikoladse GD. New approach at surgical treatment of S. James syndrome. *Ann Thoracic Surg* 1990;50:130-4.