

Anesthesia for patients with mucopolysaccharidoses: Comprehensive review of the literature with emphasis on airway management

Brittney M. Clark, Juraj Sprung*, Toby N. Weingarten, Mary E. Warner

Department of Anesthesiology and Perioperative Medicine, Mayo Clinic, Rochester, Minnesota, USA

ABSTRACT

Mucopolysaccharidoses (MPS) are rare, inherited, lysosomal storage diseases that cause accumulation of glycosaminoglycans, resulting in anatomic abnormalities and organ dysfunction that can increase the risk of anesthesia complications. We conducted a systematic review of the literature in order to describe the anesthetic management and perioperative outcomes in patients with MPS. We reviewed English-language literature search using an OVID-based search strategy of the following databases: 1) PubMed (1946-present), 2) Medline (1946-present), 3) EMBASE (1946-present), and 4) Web of Science (1946-present), using the following search terms: Mucopolysaccharidosis, Hurler, Scheie, Sanfilippo, Morquio, Maroteaux, anesthesia, perioperative, intubation, respiratory insufficiency, and airway. The review of the literature revealed nine case series and 27 case reports. A substantial number of patients have facial and oral abnormalities posing various challenges for airway management, however, evolving new technologies that include videolaryngoscopy appears to substantially facilitate airway management in these patients. The only type of MPS that appears to have less difficulty with airway management are MPS III patients, as the primary site of glycosaminoglycan deposition is in the central nervous system. All other MPS types have facial and oral characteristics that increase the risk of airway management. To mitigate these risks, anesthesia should be conducted by experienced anesthesiologists with expertise in using of advanced airway intubating devices.

KEY WORDS: General anesthesia; lysosomal storage diseases; tracheal intubation; laryngoscopy

DOI: <http://dx.doi.org/10.17305/bjbms.2017.2201>

Bosn J Basic Med Sci. 2018;18(1):1-7. © 2018 ABMSFBH

INTRODUCTION

Mucopolysaccharidoses (MPS) are rare, inherited, lysosomal storage diseases characterized by deficiencies in 11 different lysosomal enzymes involved in the metabolism of glycosaminoglycans, previously known as mucopolysaccharides. These enzyme deficiencies result in progressive, widespread accumulation of partially degraded glycosaminoglycans in the lysosomes of various tissues and organs; the characteristic patterns of accumulation form the basis of MPS classification into seven types of progressive MPS diseases (Table 1) [1-5]. With the exception of MPS II which is inherited as an X-linked recessive disorder, all other MPS disorders are inherited in an autosomal recessive pattern; therefore, affecting males and females equally [1]. MPS can be grouped into four broad categories according to their dominant clinical features: 1) MPS

I, II, and VII affect soft tissue storage and the skeleton with or without brain disease; 2) MPS VI affects both soft tissues and the skeleton; 3) MPS IVA, IVB are primarily associated with skeletal disorders; and 4) MPS III A-D primarily with central nervous system disorders. Table 1 summarizes enzymatic defects, prevalence, and clinical presentation of various MPS types. The published prevalence estimates vary widely between different studies (<http://emedicine.medscape.com/article/1115193-overview> accessed May 29, 2017). Depending on MPS type, glycosaminoglycan accumulations can occur in various organs resulting in cardiovascular, pulmonary, gastrointestinal, neurologic, and musculoskeletal dysfunction [1]. Glycosaminoglycan accumulation in the upper airway results in hypertrophy of adenoids, tonsils, tongue, and laryngopharynx, which may all pose difficulty for anesthetic airway management. This is especially important because MPS patients frequently require surgical interventions with anesthesia. For example, one MPS I registry showed that 75% of patients underwent at least one procedure requiring anesthesia [6]. The Hunter Outcome Survey that included 527 patients with

*Corresponding author: Juraj Sprung, Department of Anesthesiology and Perioperative Medicine, Mayo Clinic, 200 First St. SW, Rochester, MN 55905, USA. Phone: 507-255-3298. E-mail: sprung.juraj@mayo.edu

Submitted: 31 May 2017/Accepted: 01 June 2017

TABLE 1. Genotype, phenotype, and clinical manifestations of patients with MPS

Disorder	Eponym	Accumulated product	Enzyme	Gene/locus	Prevalence	Clinical manifestations
MPS I H	Hurler	Heparan sulfate, dermatan sulfate	α -L-Iduronidase	<i>IDUA</i> /4p16.3	1:100,000-1:500,000	Intellectual disability, facial dysmorphism dwarfism, cardiomegaly, valvular disease, OSA, and hepatosplenomegaly
MPS I S	Scheie					
MPS I HS	Hurler-Scheie					
MPS II	Hunter	Heparan sulfate, dermatan sulfate	Iduronate 2-sulfatase	<i>IDS</i> /Xq28	1:100,000-1:300,000	Macroglоссия, vocal cord enlargement, hydrocephalus, narrow airway, spinal stenosis, cardiomegaly, valvular disease, OSA, and hepatosplenomegaly
MPS III A	Sanfilippo A	Heparan sulfate	Heparan N-sulfatase	<i>SGSH</i> /17q25.3	From= 1:100,000-1:1,065,000	Dementia, seizures, language skills, deafness, blindness, enlarged tonsils, adenoids, and respiratory infections
MPS III B	Sanfilippo B		α -acetylglucosaminidase	<i>NAGLU</i> /17q21.2		
MPS III C	Sanfilippo C		α -glucosaminide acetyl transferase	<i>HGSNAT</i> /8p11.21		
MPS III D	Sanfilippo D		N-acetylglucosamine 6-sulfatase	<i>GNS</i> /12q14.2		
MPS IV A	Morquio A	Keratan sulfate, chondroitin-6-sulfate	Galactose-6-sulfate sulfatase	<i>GALNS</i> /16q24.3	Combined 1:170,000-1:263,000	Short stature, atlantoaxial instability, odontoid hypoplasia, pectus carinatum, spine deformities, hepatomegaly, and restrictive lung disease
MPS IV B	Morquio B	Keratan sulfate	β -galactosidase	<i>GLBI</i> /3p22.3	1:230,000-1:432,000	Short trunk, crouched stance, restricted joint movements, and heart disease
MPS VI	Maroteaux-Lamy	Dermatan sulfate	N-acetylgalactosamine-4-sulfatase	<i>ARSB</i> /5q14.1		
MPS VII	Sly	Heparan sulfate, dermatan sulfate, chondroitin 4,6-sulfate	β -glucuronidase	<i>GLUS1</i> /7q11.21	? 1:2,000,000	Skeletal dysplasia, short stature, nerve entrapment, developmental delay, and hepatomegaly

Information on prevalence widely differs from various reports; given values are from estimates obtained from three sources: Wikipedia <https://en.wikipedia.org/wiki/Mucopolysaccharidosis>. [Last accessed on 2017 May 29], Frawley et al. [8], and <http://emedicine.medscape.com/article/1115193-overview>. [Last accessed on 2017 May 29]. MPS: Mucopolysaccharidosis; OSA: Obstructive sleep apnea

MPS II reported that 83.7% of patients required a surgical intervention at some point [7].

Because altered anatomy of the airway and facial structures can complicate airway management [2-5], both mask ventilation and endotracheal intubation, the primary aim of the present study was to perform a comprehensive systematic review of the literature and summarize the published experience of airway management in patients with MPS.

MATERIALS AND METHODS

We reviewed the literature for reports of perioperative course and airway-related anesthetic complications in patients with MPS. We conducted an English language literature search using an OVID-based search strategy of the following databases: 1) PubMed (1946-present), 2) Medline (1946-present), 3) EMBASE (1946-present), and 4) Web of Science (1946-present). We used the following search terms: Mucopolysaccharidosis, Hurler, Scheie, Sanfilippo, Morquio, Maroteaux, anesthesia, perioperative, intubation, respiratory insufficiency, and airway. Reference lists of identified reports were searched for additional relevant publications.

RESULTS

The systematic review of the literature identified nine case series, and their airway management is summarized in Table 2 [5,8-15]. In addition, we identified 27 individual case reports and these patients' characteristics and their airway management is summarized in Tables 3 and 4 [7-10,16-38]. Figure 1 is a pie chart that summarizes airway management in a case series of MPS patients who underwent anesthesia at Mayo Clinic between years 2000 and 2015, which was reported in the Canadian Journal of Anaesthesia [15]. In that report, we described 18 MPS patients who underwent 49 procedures (there were 2, 1, 4, 7, and 4 patients with MPS Type I, II, III, IV, and VI, respectively) [15]. Finally, there is an isolated description of a 5-year-old boy with MPS II who underwent an inguinal hernia repair under a spinal anesthetic out of concern that the airway management would be difficult [39].

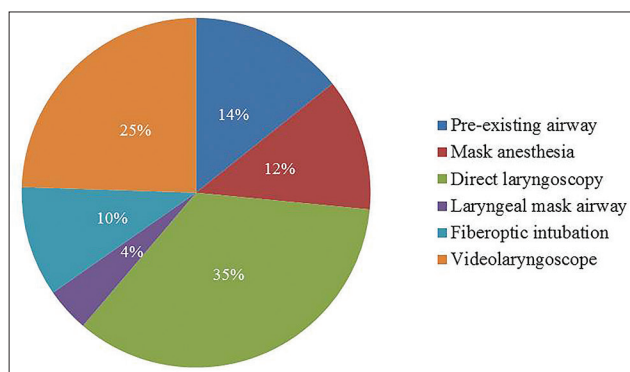
DISCUSSION

Patients with MPS have multiple comorbidities, many of which require surgical interventions. Because MPS is associated with specific phenotypic facial and airway characteristics, substantial challenges for perioperative airway management may be expected. Such challenges were confirmed in our recently reported MPS case series [15], as well as in earlier reports [3,5,8,9]. In addition, failed tracheal intubations requiring emergency tracheostomy have also been reported [3,5,8].

TABLE 2. Outcomes of airway management in various MPS phenotypes from case series

Study	Number of patients/Number of anesthetics	Difficult mask	Difficult intubation	Failed intubation
Mixed MPS type				
Frawley et al. [8]	17/141	Total: 20/141 (14%) MPS I: 2/50 MPS II: 16/60 MPS III: 0/8 MPS IV: 0/8 MPS VI: 2/15	Total: 40/141 (28%) MPS I: 6/50 MPS II: 21/60 MPS III: 0/8 MPS IV: 0/8 MPS VI: 13/15	Total: 2 MPS I 1 MPS II 1
Moore et al. [10]	28/99	Total: 11/44 (25%) MPS I: 4/8 MPS II: 5/8 MPS III: 0/13 MPS IV: 0/6 MPS VI: 2/9	Total: 23/52 (44%) MPS I: 6/7 MPS II: 2/5 MPS III: 2/17 MPS IV: 1/7 MPS VI: 12/16	Total: 2 MPS I: 2/7
Walker et al. [5]	34/89	8 ^a	Total: 20/60 (33%) (15/29 patients) MPS I: 8/13 MPS II: 3/7 MPS IV: 2/4 MPS VI: 1/2 Mucopolipidosis: 1/2	Total: 5 MPS I: 3/15
Megens et al. [9]	19/136	Total: 9/130 (7%)	Total: 24/67 (34%)	Total: 7/67 MPS I: 6 MPS VI: 1
Clark et al. [15]	18/49	Total: 4/6 MPS VI: 2	Total: 3/36 MPS II 1 MPS III 1 MPS VI 1	Total: 3/36 MPS II 1 MPS III 1 MPS VI 1
MPS I Type				
Cingi et al. [42]	25/73	0	0	0
Osthaus et al. [43]	10/41	Total: 5/41	Total: 11/29	Total: 3/29
MPS III Type				
Cohen and Stuart [12]	34/86	0/86	2/63	1/63
Kamata et al. [13]	25/43	0	N/A	N/A

^aDenominator was not clearly defined, although difficult mask applied to "most cases"; 6 difficulties were due to anatomic abnormalities and 2 due to excessive secretions. MPS: Mucopolysaccharidosis; N/A: Not applicable

**FIGURE 1.** Anesthetic airway management in a series of 49 Mayo Clinic patients with various types of mucopolysaccharidoses.

In two case series difficulty with mask ventilation has ranged to 7% and 14% of MPS patients [8,9]. Furthermore, our literature review suggests that mask ventilation is less likely encountered in MPS III patients. Kamata et al. [13] reported no difficulties in mask ventilation in a cohort of MPS III patients, albeit mild upper airway obstruction was noted during 14 procedures (33%), which was resolved with simple head/jaw maneuvering/positioning. Another review of a large MPS III series reported no problems with mask ventilation in 86 anesthetics [12]. All nine MPS III patients in our recent series from

Mayo Clinic had uneventful mask ventilation during anesthetic induction [15].

The overall incidence of difficult tracheal intubation, in case series of various types of MPS, ranges between 28% and 44% [5,8,9]. Management of endotracheal intubations in MPS III patients appears to be less difficult. Specifically, Cingi et al. [14] reported 25 children with MPS III who underwent 73 anesthetic with no case of difficult intubation, and all intubations views were graded as Cormack-Lehane 1-2. This may not be surprising because MPS III is associated mostly with central nervous system disorders and less with glycosaminoglycan accumulation in oral soft tissues. Mayo Clinic experience with MPS patients since year 2000 includes 18 MPS patients who underwent 49 procedures (Figure 1) [15]. In seven instances, the patients presented for surgical procedures were already tracheally intubated or presented with tracheostomy (all were MPS IV and VI). Six anesthetics were conducted with mask ventilation as a primary airway management, and ventilation was difficult in two patients on two occasions (both were Type IV MPS [Morquio syndrome]). In 15 procedures, tracheal intubation was electively secured with either fiberoptic intubation or

TABLE 3. Airway characteristics in patients with MPS I and II with details of airway management from individual case reports

Age (years); Sex; Surgery	Clinical manifestations and airway management
MPS I	
18/M, HR [17]	*CFA, CSA, chest wall abnormalities, short stature. AM: Desaturation (bronchospasm) during DL improved with positive-pressure ventilation; DL (×1) → LMA (×1)
7/F ENT [19]	*CFA and CSA, intellectual disability. AM: Difficult ventilation → bronchospasm → albuterol → able to ventilate again, DL (×3)
3/M, NS [20]	MG, CTLSA. AM: DL (×2) with gum elastic bougie
4/F, NS [20]	*MG, CSA, intellectual disability. AM: Difficult mask with jaw lift; DL (×2) with blind placement of ETT
21/M, NS [21]	*LMO; CSA, spastic quadriplegia, OSA, asthma. AM: Awake FOI → tracheostomy
17/M, ENT [44]	CFA, OSA. AM: Difficulty anticipated → FOI with LMA using a guide wire and airway exchange catheter; Extubated → airway obstruction → improvement with LMA → reintubated with FOI via LMA and ETT exchange → pulmonary edema → elective tracheostomy
7/M HR and ENT [44]	*Spinal abnormalities, short stature, OSA. AM: DL (×1) → FOI via LMA; extubated → stridor → nebulized epinephrine → complete obstruction → LMA inserted and FOI performed → hypoxia and bradycardia → pulmonary edema → elective tracheostomy
16/F, NS [22]	*MG, LMO, CSA, dwarfism, quadriparesis. AM: Difficult mask → LMA → fiberoptic bronchoscope → guide wire → bronchoscope removed → taper ureteral dilator passed over guide wire → LMA removed → ETT
12/F, HR [23]	*MG, LMO, CFA, CSA, heart failure; paroxysmal atrial tachycardia. AM: Difficult FOI → difficulty ventilating after intubation → frothy fluid from ETT → extubated on POD 3
27/M, NS [45]	MG, cervical myelopathy, OSA, restricted lung disease. AM: Awake FOI → postoperative tongue/lip swelling → extubated on POD 2
25/F, MVR [45]	Narrowed glottis. AM: FOI for planned tracheostomy → 5 days mechanical ventilation → decannulated after 6 weeks.
18/M, ENT [45]	Subglottic and distal tracheal narrowing, OSA. AM: desaturation with LMA → awake FOI → tracheostomy
MPS II	
14/F, HR, ENT [25]	MG, CFA, and CSA, short stature, OSA. AM: DL (×3) with LMA for ventilation between intubating attempts
11/M, HR [24]	*MG, tracheal narrowing, CFA, intellectual disability, short stature. AM: Rigid bronchoscopy revealed large, pedunculated polyp above the epiglottis → LMA (×6) → mask ventilated

*Patients with cardiac valvular abnormalities. AM: Airway management; NS: Neurosurgery; ENT: Ear, nose/throat procedure; AVR: Aortic valve replacement; MVR: Mitral valve replacement; HR: Hernia repair; mo: Months; DL: Direct laryngoscopy; ETT: Endotracheal tube; F: Female; M: Male; FOI: Fiberoptic intubation; ICU: Intensive care unit; LMA: Laryngeal mask airway; M: Male; MPS: Mucopolysaccharidosis; LMO: Limited mouth opening; OSA: Obstructive sleep apnea; →: Progressed to; CSA: Cervicospinal abnormalities; CFA: Craniofacial abnormalities; CTLSA: Cervicothoracolumbar spinal abnormalities; MG: Macroglossia; POD: Post-operative day

TABLE 4. Airway characteristics in patients with MPS IV and MPS of unknown type with details of airway management from individual case reports

Age, y/Sex/Surgery type	Clinical manifestations and airway management
MPS IV	
3/M, NS [26]	MG, buck teeth, CFA, CSA, barrel chest. AM: Supraglottic airway device → ETT → bronchoscope → ETT → airway edema
7/M, NS [27]	CFA, chest wall abnormalities, short stature, asthma, OSA. AM: Difficult mask ventilation, DL (×1)
9/M, NS [28]	CTLSA, restrictive pulmonary disease, dwarfism. AM: Awake FOI
6/M, HR, ENT [46]	*CFA and CSA. AM: Mask ventilation difficult; LMA → FOI → guide wire → ureteral dilator → wire removed → LMA removed → ETT railroaded over dilator
42/F, NS [29]	Tracheal stenosis, CTLSA. AM: Refused awake FOI; oral fiberscope unable to visualize glottis opening → asleep nasal FOI
3/F, Radiology [30]	CTLSA. AM: FOI through LMA
31/M, Orthopedic [31]	MG, CFA and CSA, and lumbar abnormalities (scoliosis). AM: Awake FOI
17/M, Dental [32]	MG, large uvula, short stature, CFA, CTLSA, barrel chest, lumbar kyphosis AM: Anticipated difficulty → nasal ETT intubation
26/M, Orthopedic [33]	MG, enlarged uvula and tonsils, short stature, CFA and CSA, kyphosis, barrel chest, OSA AM: Awake FOI
31/F, AVR [34]	*Short stature; CSA; pectus carinatum; thoracolumbar kyphosis; mild restrictive and obstructive lung disease. AM: Awake FOI
31/F, NS [16]	*CFA and CSA, restrictive lung disease, OSA. AM: Awake FOI
9/F, MVR [35]	MG, gum hypertrophy, CFA, CTLSA. AM: DL (4) → video laryngoscope
9 mo/M, NS [36]	*MG, upper airway thickening, CFA and CSA. Airway management: Anticipated difficulty → DL → endotracheal intubation
10/M, NS [44]	MG, enlarged tonsils, craniofacial, chest wall, CFA and CSA; short stature. AM: DL (×1) → LMA → FOI → guide wire inserted → airway exchanger over guide wire → LMA removed and ETT railroaded over exchanger; Extubated → desaturation → LMA → unable to ventilate → FOB through LMA → pulmonary edema → elective tracheostomy
MPS type unknown	
15/M, HR [37]	MG, CSA, and intellectual disability. AM: DL (1)
2/M, HR [18]	*LMO, MG, CFA and CSA, psychomotor retardation. AM: Difficult DL → LMA

*Patients with cardiac valvular abnormalities. AM: Airway management; NS: Neurosurgery; ENT: Ear, nose/throat procedure; AVR: Aortic valve replacement; MVR: Mitral valve replacement; HR: Hernia repair; mo: Months; DL: Direct laryngoscopy; ETT: Endotracheal tube; F: Female; M: Male; FOI: Fiberoptic intubation; ICU: Intensive care unit; LMA: Laryngeal mask airway; M: Male; MPS: Mucopolysaccharidosis; LMO: Limited mouth opening; OSA: Obstructive sleep apnea; →: Progressed to; CSA: Cervicospinal abnormalities; CFA: Craniofacial abnormalities; CTLSA: Cervicothoracolumbar spinal abnormalities; MG: Macroglossia

videolaryngoscope (VLG), and VLG was used as a rescue technique in two additional patients who failed the initial planned approach. In 19/36 (53%) procedures, airway management was successful with primary planned approach: direct laryngoscopy or laryngeal mask supraglottic airway. In our series of patients, there were nine patients with MPS III, and while all were “easy masks” one was describe as “difficult direct laryngoscopy”, suggesting that even in this MPS group caution should be exercised when managing the airway. Facial characteristics of one our patient with MPS VI (known as Maroteaux-Lamy syndrome) was deceiving, as it did not predict difficult mask ventilation (Figure 2). This 15-year-old female had obstructive sleep apnea, maxillary hypoplasia, high-arched palate, macroglossia, narrow hypopharynx, and compromise of the cervical spinal cord at the foramen magnum. Mask ventilation required two hands and a jaw thrust. Three attempts to place a laryngeal mask airway failed. Endotracheal intubation was successful with a VLG, albeit aided by a fiberoptic bronchoscope. The fiberoptic bronchoscope was used by a second anesthesia provider to locate the glottic opening, as VLG provided only a view of the epiglottis. After inserting the fiberoptic bronchoscope through the glottic opening, our endotracheal tube was guided over the scope into the trachea. In our report, 16.7% (3/18) patients had a true difficult airway (failed primary technique) [15]. This percentage likely represents an underestimate of difficult airway in MPS patients because anesthesiologists electively used a fiberoptic bronchoscope or VLG in 15 out of 36 procedures, suggesting a concern for potential difficult intubation. VLG-assisted intubations have been introduced only recently as an alternative intubation method, and in our series of MPS patients we found that since its introduction in 2009, the majority of cases were intubated using VLG, and all attempts were successful [15]. Theroux *et al.* [40] retrospectively examined intubations of 28 MPS patients undergoing 108 anesthetics and similarly observed that VLG became a preferred method for tracheal intubation for MPS patients. Megens *et al.* [9] reviewed the success rate of tracheal intubation using different tools: direct laryngoscopy was difficult in 16 out of 55 anesthetics, VLG was successful in 8 out of 9 anesthetics, and fiberoptic intubations were performed without difficulty in only 2 out of 10 cases. With the more widespread availability of VLG, this technique may become a preferred technique for endotracheal intubation in patients with MPS.

Besides various airway issues, patients with MPS have other comorbidities that may have an impact on ventilation. Specifically, they frequently have restrictive or obstructive lung disease, recurrent lung infections, and obstructive sleep apnea [5]. Propensities for bronchospasm and oxyhemoglobin desaturation may complicate

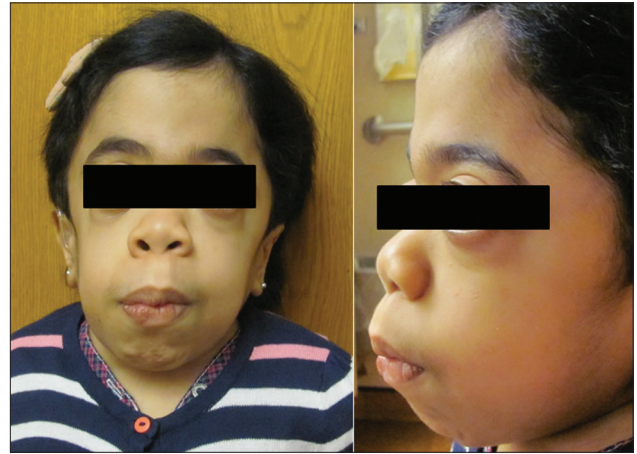

FIGURE 2. (A and B) A 15-year-old girl with mucopolysaccharidosis Type VI. Despite the fact that her facial characteristics gave impression that her airway is “manageable,” she had difficult mask ventilation, and 3 failed attempts to place a laryngeal mask airway. Placement of endotracheal tube was successful with a video laryngoscope aided by fiberoptic bronchoscope (see discussion for details). Published with the consent of patient’s legal representative.

airway management in MPS patients. Furthermore, skeletal dysplasia such as atlantoaxial instability, spinal cord compression, limited neck mobility, pectus carinatum, and scoliosis is common [16]. Finally, there may be a high degree of tracheal narrowing in patients with MPS IV A (Morquio A). Evaluation of 28 MPS IV A patients with sagittal magnetic resonance imaging (MRI) scans found 68% had at least 25% tracheal narrowing and 29% had >75% narrowing due to a combination of a narrow thoracic inlet, tracheal growth, and tortuous brachiocephalic artery [41].

CONCLUSION

Patients with MPS have multiple comorbidities requiring frequent surgical procedures with anesthesia. With an exception of MPS III, all other MPS types have facial and airway characteristics which may create a challenge for anesthetic airway management. To mitigate the risks of airway mismanagement in patients with MPS, anesthetic planning should include experienced anesthesiologists and expertise in using a full array of advanced airway devices.

ACKNOWLEDGMENTS

This project was supported by the Department of Anesthesiology and Perioperative Medicine, College of Medicine, Mayo Clinic, Rochester, MN 55905, USA.

DECLARATION OF INTERESTS

The authors declare no conflict of interests.

REFERENCES

- [1] Muenzer J. Overview of the mucopolysaccharidoses. *Rheumatology (Oxford)* 2011;50(Suppl 5):v4-12. <https://doi.org/10.1093/rheumatology/ker394>.
- [2] Baines D. Suxamethonium in mucopolysaccharidosis. *Anaesth Intensive Care* 1989;17(3):382.
- [3] Kempthorne PM, Brown TC. Anaesthesia and the mucopolysaccharidoses: A survey of techniques and problems. *Anaesth Intensive Care* 1983;11(3):203-7.
- [4] King DH, Jones RM, Barnett MB. Anaesthetic considerations in the mucopolysaccharidoses. *Anaesthesia* 1984;39(2):126-31. <https://doi.org/10.1111/j.1365-2044.1984.tb09499.x>.
- [5] Walker R, Belani KG, Braunlin EA, Bruce IA, Hack H, Harmatz PR, et al. Anaesthesia and airway management in mucopolysaccharidosis. *J Inher Metab Dis* 2013;36(2):211-9. <https://doi.org/10.1007/s10545-012-9563-1>.
- [6] Arn P, Wraith JE, Underhill L. Characterization of surgical procedures in patients with mucopolysaccharidosis Type I: Findings from the MPS I Registry. *J Pediatr* 2009;154(6):859-64.e3. <https://doi.org/10.1016/j.jpeds.2008.12.024>.
- [7] Mendelsohn NJ, Harmatz P, Bodamer O, Burton BK, Giugliani R, Jones SA, et al. Importance of surgical history in diagnosing mucopolysaccharidosis Type II (Hunter syndrome): Data from the hunter outcome survey. *Genet Med* 2010;12(12):816-22. <https://doi.org/10.1111/j.1460-9592.2012.03825.x>.
- [8] Frawley G, Fuenzalida D, Donath S, Yapliito-Lee J, Peters H. A retrospective audit of anesthetic techniques and complications in children with mucopolysaccharidoses. *Paediatr Anaesth* 2012;22(8):737-44. <https://doi.org/10.1111/j.1460-9592.2012.03825.x>.
- [9] Megens JH, de Wit M, van Hasselt PM, Boelens JJ, van der Werff DB, de Graaff JC. Perioperative complications in patients diagnosed with mucopolysaccharidosis and the impact of enzyme replacement therapy followed by hematopoietic stem cell transplantation at early age. *Paediatr Anaesth* 2014;24(5):521-7. <https://doi.org/10.1111/pan.12370>.
- [10] Moores C, Rogers JG, McKenzie IM, Brown TC. Anaesthesia for children with mucopolysaccharidoses. *Anaesth Intensive Care* 1996;24(4):459-63.
- [11] Cohen-Levy J. Orthodontic treatments of pediatric obstructive sleep apnea syndrome. *Med Sommeil* 2011;8(2):61-8. <https://doi.org/10.1016/j.msom.2011.03.001>.
- [12] Cohen MA, Stuart GM. Delivery of anesthesia for children with Mucopolysaccharidosis Type III (Sanfilippo syndrome): A review of 86 anesthetics. *Paediatr Anaesth* 2017;27(4):363-9. <https://doi.org/10.1111/pan.13075>.
- [13] Kamata M, McKee C, Truxal KV, Flanigan KM, McBride KL, Aylward SC, et al. General anesthesia with a native airway for patients with mucopolysaccharidosis Type III. *Paediatr Anaesth* 2017;27(4):370-6. <https://doi.org/10.1111/pan.13108>.
- [14] Cingi EC, Beebe DS, Whitley CB, Belani KG. Anesthetic care and perioperative complications in children with Sanfilippo Syndrome Type A. *Paediatr Anaesth* 2016;26(5):531-8. <https://doi.org/10.1111/pan.12876>.
- [15] Clark BM, Sprung JJ, Weingarten TN, Warner ME. Airway management changes in patients with mucopolysaccharidoses: The role of videolaryngoscopy. *Can J Anaesth* 2017 [Epub ahead of print]. <https://doi.org/10.1007/s12630-017-0906-0>.
- [16] Cade J, Jansen N. Anesthetic challenges in an adult with mucopolysaccharidosis Type VI. *A&A Case Rep* 2014;2(12):152-4. <https://doi.org/10.1213/XAA.0000000000000031>.
- [17] Gurumurthy T, Shailaja S, Kishan S, Stephen M. Management of an anticipated difficult airway in Hurler's syndrome. *J Anaesthesiol Clin Pharmacol* 2014;30(4):558-61. <https://doi.org/10.4103/0970-9185.142862>.
- [18] Ziyaeifard M, Azarfarin R, Ferasatkish R, Dashti M. Management of difficult airway with laryngeal mask in a child with mucopolysaccharidosis and mitral regurgitation: A case report. *Res Cardiovasc Med* 2014;3(2):e17456. <https://doi.org/10.5812/cardiovascmed.17456>.
- [19] Nadeem A, Siddiqui K. Anaesthesia challenges in a patient with Hurler syndrome: A case report. *Anaesth Pain Intensive Care* 2012;16(1):100-1.
- [20] Gupta N, Rath GP, Bala R, Reddy BK, Chaturvedi A. Anesthetic management in children with Hurler's syndrome undergoing emergency ventriculoperitoneal shunt surgery. *Saudi J Anaesth* 2012;6(2):178-80. <https://doi.org/10.4103/1658-354X.97036>.
- [21] Ard JL Jr, Bekker A, Frempong-Boadu AK. Anesthesia for an adult with mucopolysaccharidosis I. *J Clin Anesth* 2005;17(8):624-6. <https://doi.org/10.1016/j.jclinane.2005.01.012>.
- [22] Walker RW, Dearlove OR. Anaesthesia for children with mucopolysaccharidoses. *Anaesth Intensive Care* 1997;25(2):197-8.
- [23] Wilder RT, Belani KG. Fiberoptic intubation complicated by pulmonary edema in a 12-year-old child with Hurler syndrome. *Anesthesiology* 1990;72(1):205-7. <https://doi.org/10.1097/0000542-199001000-00033>.
- [24] Busoni P, Fognani G. Failure of the laryngeal mask to secure the airway in a patient with Hunter's syndrome (mucopolysaccharidosis Type II). *Paediatr Anaesth* 1999;9(2):153-5. <https://doi.org/10.1046/j.1460-9592.1999.9220289.x>.
- [25] Kaur J, Swami AC, Kumar A, Lata S. Anesthetic management of a child with Hunter's syndrome. *J Anaesthesiol Clin Pharmacol* 2012;28(2):255-7. <https://doi.org/10.4103/0970-9185.94914>.
- [26] Dhanger S, Adinarayanan S, Vinayagam S, Kumar MP. I-gel assisted fiberoptic intubation in a child with Morquio's syndrome. *Saudi J Anaesth* 2015;9(2):217-9. <https://doi.org/10.4103/1658-354X.152893>.
- [27] Morgan KA, Rehman MA, Schwartz RE. Morquio's syndrome and its anaesthetic considerations. *Paediatr Anaesth* 2002;12(7):641-4. <https://doi.org/10.1046/j.1460-9592.2002.00838.x>.
- [28] Bartz HJ, Wiesner L, Wappler F. Anaesthetic management of patients with mucopolysaccharidosis IV presenting for major orthopaedic surgery. *Acta Anaesthesiol Scand* 1999;43(6):679-83. <https://doi.org/10.1034/j.1399-6576.1999.430614.x>.
- [29] Nielsen RM, Pedersen NA, Olsen KS. Airway management in a patient with Morquio-Brailsford syndrome. *Eur J Anaesthesiol* 2013;30(3):133-4. <https://doi.org/10.1097/EJA.0bo13e32835c8dc5>.
- [30] Chaudhuri S, Duggappa AK, Mathew S, Venkatesh S. Safe intubation in Morquio-Brailsford syndrome: A challenge for the anesthesiologist. *J Anaesthesiol Clin Pharmacol* 2013;29(2):258-61. <https://doi.org/10.4103/0970-9185.111666>.
- [31] Kadic L, Driessen JJ. General anaesthesia in an adult patient with Morquio syndrom with emphasis on airway issues. *Bosn J Basic Med Sci* 2012;12(2):130-3.
- [32] Shivajirao TP, Wasmatkar NP, Gore PG, Lakhe JN, Vinayak SR. Anesthetic considerations in Morquio syndrome: A case report. *Anaesth Pain Intensive Care* 2013;17(1):75-8.
- [33] McLaughlin AM, Farooq M, Donnelly MB, Foley K. Anaesthetic considerations of adults with Morquio's syndrome - A case report. *BMC Anesthesiol* 2010;6:10:2.
- [34] Pagel PS, Almassi GH. Perioperative implications of Morquio syndrome in a 31-year-old woman undergoing aortic valve replacement. *J Cardiothorac Vasc Anesth* 2009;23(6):855-7. <https://doi.org/10.1053/j.jvca.2008.12.009>.
- [35] Sayilgan C, Yuceyar L, Akbas S, Erolcay H. Anesthesia in a child with Maroteaux-Lamy syndrome undergoing mitral valve replacement. *Clinics (Sao Paulo)* 2012;67(6):693-6. [https://doi.org/10.6061/clinics/2012\(06\)26](https://doi.org/10.6061/clinics/2012(06)26).
- [36] Suh SH, Okutani R, Nakasuji M, Nakata K. Anesthesia in a patient with mucopolysaccharidosis Type VI (Maroteaux-Lamy syndrome). *J Anesth* 2010;24(6):945-8. <https://doi.org/10.1007/s00540-010-1029-8>.
- [37] Barbosa FT, Borges EL, Brandão RR. General anesthesia after failed spinal block for emergency surgery in a patient with

- mucopolysaccharidosis: Case report. [Article in Portuguese]. *Rev Bras Anesthesiol* 2007;57(6):658-64.
- [38] Arn P, Whitley C, Wraith JE, Webb HW, Underhill L, Rangachari L, et al. High rate of postoperative mortality in patients with mucopolysaccharidosis I: Findings from the MPS I Registry. *J Pediatr Surg* 2012;47(3):477-84.
<https://doi.org/10.1016/j.jpedsurg.2011.09.042>.
- [39] Kumar KR, Kumar H, Baidya DK, Arora MK. Successful use of spinal anesthesia for inguinal hernia repair in a child with Hunter syndrome with difficult airway. *J Clin Anesth* 2016;30:99-100.
<https://doi.org/10.1016/j.jclinane.2015.08.025>.
- [40] Theroux MC, Nerker T, Ditro C, Mackenzie WG. Anesthetic care and perioperative complications of children with Morquio syndrome. *Paediatr Anaesth* 2012;22(9):901-7.
<https://doi.org/10.1111/j.1460-9592.2012.03904.x>.
- [41] Tomatsu S, Averill LW, Sawamoto K, Mackenzie WG, Bober MB, Pizarro C, et al. Obstructive airway in Morquio A syndrome, the past, the present and the future. *Mol Genet Metab* 2016;117(2):150-6.
<https://doi.org/10.1016/j.ymgme.2015.09.007>.
- [42] Cingi E, Belani K, Beebe D, Apostolidou I, Whitley C. Anesthetic care and outcome in children with Sanfilippo syndrome type A. *Mol Gen Metab* 2013;108(2):S30.
<http://dx.doi.org/10.1016/j.ymgme.2012.11.056>.
- [43] Osthaus WA, Harendza T, Witt LH, Jüttner B, Dieck T, Grigull L, et al. Paediatric airway management in mucopolysaccharidosis 1: A retrospective case review. *Eur J Anaesthesiol* 2012;29(4):204-7.
<https://doi.org/10.1097/EJA.0b013e328350677b>.
- [44] Walker PP, Rose E, Williams JG. Upper airways abnormalities and tracheal problems in Morquio's disease. *Thorax* 2003;58(5):458-9.
<https://doi.org/10.1136/thorax.58.5.458>.
- [45] Hack HA, Walker R, Gardiner P. Anesthetic implications of the changing management of patients with mucopolysaccharidosis. *Anaesth Intensive Care* 2016;44(6):660-8.
- [46] Walker RW, Allen DL, Rothera MR. A fiberoptic intubation technique for children with mucopolysaccharidoses using the laryngeal mask airway. *Paediatr Anaesth* 1997;7(5):421-6.
<https://doi.org/10.1046/j.1460-9592.1997.d01-102.x>.