

Association between structural and functional brain alterations in drug-free patients with schizophrenia: a multimodal meta-analysis

Xin Gao, MS*; Wenjing Zhang, PhD*; Li Yao, PhD; Yuan Xiao, PhD; Lu Liu, MS; Jieke Liu, PhD; Siyi Li, MS; Bo Tao, MS; Chandan Shah, MS; Qiyong Gong, MD, PhD; John A. Sweeney, PhD; Su Lui, MD, PhD*

Background: Neuroimaging studies have shown both structural and functional abnormalities in patients with schizophrenia. Recently, studies have begun to explore the association between structural and functional grey matter abnormalities. By conducting a meta-analysis on morphometric and functional imaging studies of grey matter alterations in drug-free patients, the present study aims to examine the degree of overlap between brain regions with anatomic and functional changes in patients with schizophrenia. **Methods:** We performed a systematic search of PubMed, Embase, Web of Science and the Cochrane Library to identify relevant publications. A multimodal analysis was then conducted using Seed-based d Mapping software. Exploratory analyses included jackknife, subgroup and meta-regression analyses. **Results:** We included 15 structural MRI studies comprising 486 drug-free patients and 485 healthy controls, and 16 functional MRI studies comprising 403 drug-free patients and 428 controls in our meta-analysis. Drug-free patients were examined to reduce pharmacological effects on the imaging data. Multimodal analysis showed considerable overlap between anatomic and functional changes, mainly in frontotemporal regions, bilateral medial posterior cingulate/paracingulate gyrus, bilateral insula, basal ganglia and left cerebellum. There were also brain regions showing only anatomic changes in the right superior frontal gyrus, left supramarginal gyrus, right lingual gyrus and functional alternations involving the right angular gyrus. **Limitations:** The methodological aspects, patient characteristics and clinical variables of the included studies were heterogeneous, and we cannot exclude medication effects. **Conclusion:** The present study showed overlapping anatomic and functional brain abnormalities mainly in the default mode (DMN) and auditory networks (AN) in drug-free patients with schizophrenia. However, the pattern of changes differed in these networks. Decreased grey matter was associated with decreased activation within the DMN, whereas it was associated with increased activation within the AN. These discrete patterns suggest different pathophysiological changes impacting structural and functional associations within different neural networks in patients with schizophrenia.

Introduction

The neuropathology of schizophrenia is believed to involve widespread alterations in brain areas and circuits.¹ Although structural and functional brain abnormalities are well established in this disorder, these regional alterations early in the course of illness have not been consistent within or across imaging modalities.^{2,3} This inconsistency resulted in part from small samples and from studying patients treated with antipsychotic medications, which are known to alter brain anatomy and function.⁴⁻⁶

Structural MRI (sMRI) studies have reported grey matter volume reduction and cortical mantle thinning across thalamocortical circuitry in patients with first-episode and chronic schizophrenia.^{2,7-11} Potential underlying causes have been thought to include shrinkage of neuropil, reduced neuron size and cell loss.⁷⁻⁹ These anatomic changes are believed to be a potential substrate of abnormal integration of information in neocortical systems and symptom expression.

By contrast, functional MRI (fMRI) has been used to identify brain functional or physiologic abnormalities evoked by specific tasks or in the resting state. Previous functional

Correspondence to: S. Lui, Radiology Department, the Second Affiliated Hospital and Yuying Children's Hospital of Wenzhou Medical University, Wenzhou, Zhejiang, China; Department of Radiology, the Center for Medical Imaging, West China Hospital of Sichuan University, Chengdu, Sichuan, China, 610041; lusuwcums@tom.com

*These authors contributed equally to this work.

Submitted Nov. 9, 2016; Revised Aug. 29, 2017; Accepted Sept. 9, 2017; Online first Dec. 5, 2017

DOI: 10.1503/jpn.160219

imaging studies have reported dysfunction of frontotemporal and frontoparietal networks in patients with schizophrenia at rest and during cognitive and emotion processing;^{10–14} these findings were associated with clinical behavioural characteristics in affected individuals. At present, as few studies have directly examined functional and structural alterations together, little is known about the association between them, especially without the confounding effects of medications that impact both anatomic and functional measures.^{4,5,15} This confound is especially important for considering the association between functional and structural indices, because drugs could induce parallel alterations in a region or disparate changes in different brain regions.

Although many studies have examined functional or structural brain parameters in the early course of schizophrenia, the pattern for convergence or divergence in regional findings remains unclear. Therefore, we performed a meta-analysis of anatomic and functional neuroimaging studies of drug-free patients with schizophrenia (patients were either untreated or underwent a period of medication wash-out early during the course of illness) to examine the location and patterns of functional and anatomic changes before acute or chronic antipsychotic treatment effects might confound their association. We performed exploratory analyses to find the potential influences of demographic and clinical variables on identified patterns of abnormalities.

Methods

Selection procedures

Two experienced researchers (L.Y. and Y.X.) independently conducted the literature review from the PubMed, Embase, Web of Science and the Cochrane Library databases for papers published before March 2017. We used the following key words to identify suitable studies: “schizophrenia,” “*free” or “*naive” (e.g., drug-free, antipsychotic-free, neuroleptic-free, medication-free, drug-naive, antipsychotic-naive, neuroleptic-naive, treatment-naive, never-medicated), and “magnetic resonance imaging” or “MRI.”

We included all the studies that were original papers published in peer-reviewed journals; explored grey matter abnormalities with functional or anatomic imaging at the whole brain level in patients with schizophrenia compared with controls; investigated drug-free patients who either had never received medications or who were not taking psychiatric medications at the time of scanning; and that localized effects using Montreal Neurological Institute (MNI) or Talairach coordinates.

We excluded review articles and meta-analyses, studies that exclusively used a region-of-interest (ROI) approach and studies from which peak coordinates could not be retrieved. We also excluded studies whose data overlapped those of other studies (e.g., from the same institution or authors); the paper with the largest sample among these was included in our meta-analysis.

In addition, we manually searched the reference lists of the selected articles and prior schizophrenia-related meta-analyses for additional qualifying studies. We contacted the

corresponding authors as needed to seek out study details not mentioned in the published versions of their papers. Our search pattern is shown in Figure 1.

Data abstraction

For each study, we recorded diagnosis, sample size, sex, mean age, drug treatment status, illness duration, Positive and Negative Syndrome Scale (PANSS) scores and imaging methodology parameters (i.e., slice thickness, full width at half maximum [FWHM] of spatial filtering, correction steps, and the paradigm of task-based fMRI). We followed the guidelines for Meta-analysis Of Observational Studies in Epidemiology (MOOSE).¹⁵

Quality assessment

The quality of each study was assessed using a 12-point checklist that was adapted from previous meta-analyses.^{16–18} We modified this checklist to reflect critical variables that were important to our studies. The checklist was divided into 3 categories: participants (items 1–4), methods for image acquisition and analysis (items 5–10) and results and conclusions (items 11 and 12). Each item received a score of 1, 0.5 or 0 according to the criteria that were fully, partially or not met, respectively. We used this checklist to rate the completeness of published studies, not to criticize the investigators or the work itself.

Meta-analysis of regional structural and functional differences in grey matter

We used Seed-based d Mapping (SDM; formerly Signed Differential Mapping, www.sdmproject.com) software version 4.31 as the primary toolbox for the analyses. It is a coordinate-based method for meta-analysis of brain abnormalities in function or structure.¹⁹ This method has been successfully used and validated in previous studies.^{19–22} We conducted a multimodal meta-analysis to simultaneously evaluate significant alternations in functional and structural modalities.²²

The basic aim of voxel-wise meta-analysis is counting (i.e., for each voxel, how many times is it close enough to the reported maxima?) and subsequently associating a probability of its being close enough to other demonstrated effects to be considered a single source of effect.²⁰ The SDM method achieves this by combining reported peak coordinates with statistical parametric maps, thus allowing more exhaustive inclusion of studies and more accurate estimations. First, SDM weighs calculations for intrastudy variance (i.e., large sample studies contribute more), interstudy heterogeneity and other optional weights, providing statistical advantages over some previous meta-analysis methods. Second, different specific masks for fMRI, sMRI and cerebrospinal fluid (CSF), are used to increase the accuracy of statistical parameter mapping (SPM; t-maps). Third, both positive and negative group differences are reconstructed in the same map. Furthermore, complementary analyses provided by SDM, such as jackknife, subgroup, and meta-regression analyses, are used to assess the robustness and heterogeneity of results.²⁰

Multimodal analysis

Multimodal analysis examines convergence in findings from different modalities. The multimodal approach, proposed by Nichols and colleagues²³ and improved by Radua and colleagues,²⁴ focuses on overlapping regions that are significant in 2 modalities, while aiming to ensure that the false-positive rate is not increased compared with that in studies of any single modality. In a separate meta-analysis, we obtained a probability map of grey matter volume (p_{GMV}) and functional response (p_{FR}) alterations to identify regions with alterations in only 1 modality. Thus, multimodal analysis combined the 2 probabilities maps, incorporating p values to identify a union of alterations in both modalities (U). The estimation of U is straightforward: $U = p_{\text{GMV}} + p_{\text{FR}} - p_{\text{GMV}} \times p_{\text{FR}}$. However, the U statistic in its raw form is overtly conservative. To reduce the imbalance between the false-positive and negative rates, the U was adjusted according to the following formula, as suggested by Radua and colleagues:²⁴ $p = U + (1 - U) \times \ln(1 - U)$.

Sensitivity and subgroup analysis

We used a jackknife analysis to find replicable abnormalities. It involved repeating the analysis several times, discarding different studies in each step, aiming to establish that alterations in a brain area remain significant in all or

most combinations of studies. Subgroup analyses were performed to both establish consistency of findings and to identify methodological or clinical factors associated with divergent findings. Studies reporting a slice thickness of 1.5 mm or less at acquisition, a smoothing kernel of 8 mm or less, 1.5 T MRI, use of an additional correction step and inclusion of drug-naïve patients were chosen for our subgroup analysis of structural studies. Studies reporting task performance versus resting state, slice thickness less than 5 mm at acquisition, a smoothing kernel of 9 mm or less, 1.5 T MRI, use of an additional correction step and inclusion of drug-naïve patients were used in subgroup analyses of functional studies.

Analysis of heterogeneity and publication bias

We examined the statistical (between-studies) heterogeneity of individual clusters using a random-effects model with Q statistics (χ^2 distribution converted to z values) and tested with a permutation approach (uncorrected $p < 0.005$, peak height $z = 1$, cluster extent = 100 voxels). The forest plots of the main findings of structure and function separately were created in R (www.r-project.org/). We also created funnel plots of the peaks of the main findings of structure and function separately and examined the possibility of publication bias for altered regions using the Egger test in SDM.

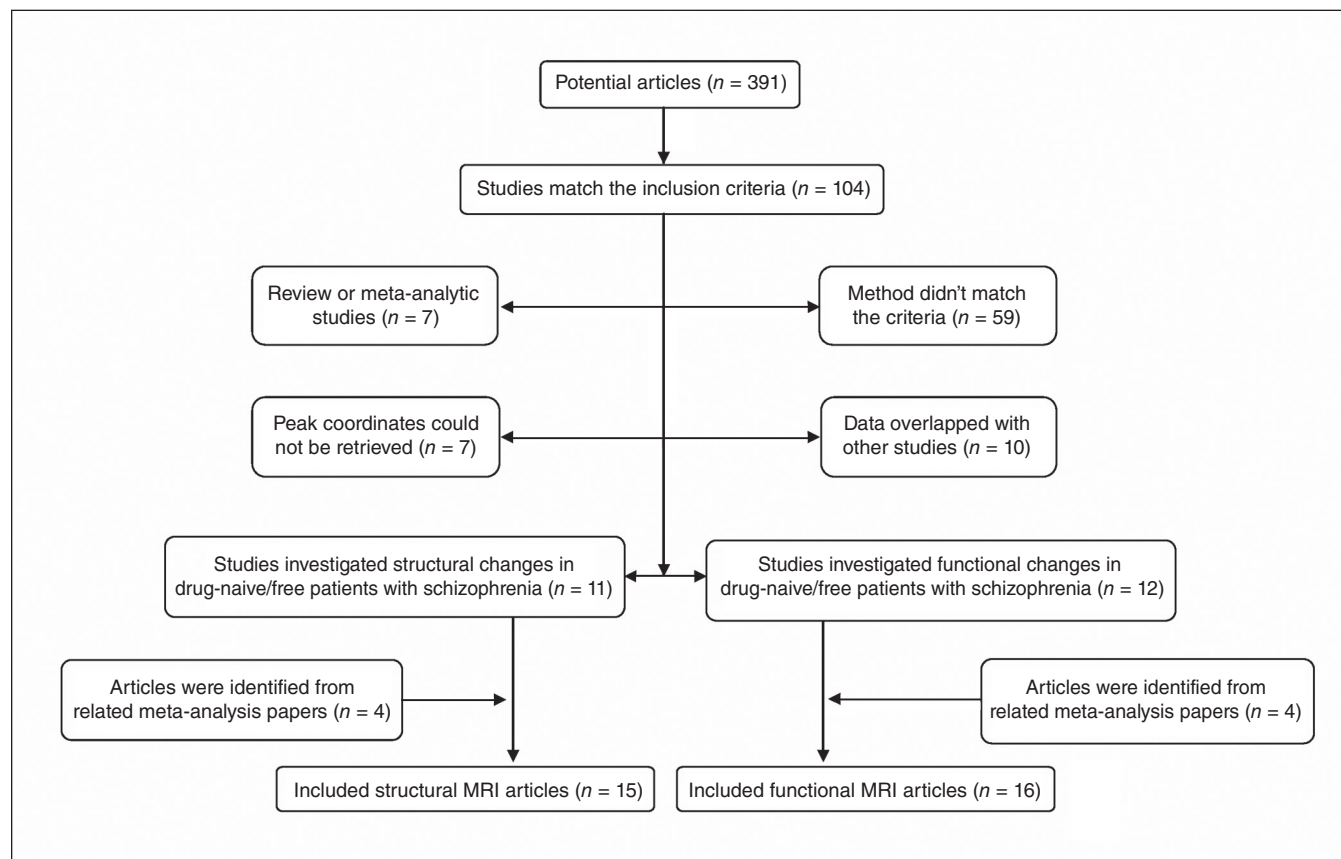


Fig. 1: Inclusion and exclusion criteria for the meta-analysis.

Meta-regression analysis

To find the potential effects of sociodemographic and clinical variables, several variables (e.g., duration of illness, PANSS scores) were examined by means of simple linear regression.

Default SDM kernel size and thresholds, selected to balance sensitivity and specificity and to approximate a corrected $p = 0.05$, were used (FWHM 20 mm, uncorrected $p = 0.005$, peak height $z = 1$, cluster extent = 100 voxels). We used a more stringent probability threshold ($p = 0.0025$) than that used in unimodal meta-analyses for our multimodal analysis, and we used a more conservative threshold ($p = 0.0005$) for meta-regression analyses.^{19,25,26}

Results

Included studies

We selected 15 sMRI studies comprising 486 drug-free patients (mean age 26.00 ± 3.22 yr) and 485 healthy controls (mean age 25.87 ± 2.78 yr) and 16 fMRI studies comprising 403 drug-free patients (mean age 24.93 ± 6.53 yr) and 428 controls (mean age 24.81 ± 5.94 yr) for inclusion in our meta-analysis. The percentage of drug-naïve patients in the inclusive structural and functional studies was 96.5% and 85.6%, respectively. Only 1 study didn't report the duration of medication wash-out.²⁷ The wash-out period in the remaining studies ranged from 3 days to 1 month. The percentage of patients with first-episode schizophrenia in the selected structural and functional studies was 86.8% and 88.8%, respectively. And the mean duration of sMRI and fMRI studies was 18.9 (range 4.0–63.3) months and 17.8 (range 6.25–52.5) months, respectively.

One of the structural studies divided patients with schizophrenia into 2 subgroups according to duration of illness and conducted 2 voxel-based morphometry (VBM) comparisons, so 2 sets of data were obtained from that paper.²⁸ One functional study scanned participants using 2 different tasks, and results were treated as separate data sets.²⁹ Another functional study divided patients into 2 data sets according to different symptoms and conducted 2 comparisons.³⁰ There are 6 resting-state fMRI studies among the included articles. Three of them^{30–32} used the amplitude of low-frequency fluctuations (ALFF) as the main effect between patients and controls, 2 of them^{33,34} used the fractional amplitude of low-frequency fluctuations (fALFF), and 1 study³⁵ examined cerebral perfusion using continuous arterial spin labelling (CASL). Both the ALFF and fALFF of resting-state fMRI signal have been suggested to reflect the intensity of regional spontaneous brain activity,³⁶ and CASL is used to compare the cerebral perfusion between patients and healthy controls.³⁵ All in all, resting-state fMRI could reflect regional brain activity.

The mean quality score of structural studies and functional studies was 11.3 (range 9.5–12) and 11.5 (range 9.5–12), respectively, showing that the included studies were of high quality, which in turn ensures a more exhaustive and accurate meta-analysis. Demographic and clinical characteristics of study participants as well as methodological aspects and quality scores of included studies are summarized in Table 1 and Table 2.

Regional grey matter volume and regional brain activity changes in patients with schizophrenia

Compared with healthy controls, significant reductions of grey matter volume was seen in 4 main clusters in patients with schizophrenia: the left fusiform gyrus, left inferior frontal gyrus, right superior temporal gyrus and left supramarginal gyrus (Fig. 2 and Appendix 1, Table S2, available at jpn.ca/160219-a1). Two additional clusters, the right lingual gyrus and right superior frontal gyrus (orbital part), showed significantly increased grey matter volume in patients with schizophrenia.

Clusters with increased activation in patients with schizophrenia were located in the left and right striatum and in the left inferior occipital gyrus, and clusters of decreased activation were seen in the right inferior frontal gyrus, right angular gyrus and right insula (Fig. 3 and Appendix 1, Table S4).

Brain regions exhibited decreased grey matter in the left supramarginal gyrus, increased grey matter in the right lingual gyrus and right superior frontal gyrus, and decreased activation involving the right angular gyrus.

Multimodal analysis

Multimodal analysis showed significant decreases of grey matter volume and reduced functional activity in the left medial posterior cingulate/paracingulate gyrus, right temporal pole, superior temporal gyrus, left fusiform gyrus, left inferior parietal gyrus and left caudate nucleus. We also observed decreased grey matter volume with increased physiologic activity in the left superior temporal gyrus, right superior temporal gyrus, left fusiform gyrus and right lingual gyrus. Increased grey matter volumes were associated with either reduced or increased functional activity in the left cerebellum, right gyrus rectus, right inferior parietal gyrus and left insula (Table 3 and Fig. 4).

Consistency analysis

Jackknife analysis showed that both increased and decreased grey matter volume effects were preserved throughout study combinations. For functional results, the clusters of the left striatum, right inferior frontal gyrus and right insula were also preserved. The right striatum, left inferior occipital gyrus and right angular gyrus remained significant in all combinations but 1. More details about these findings are presented in supplementary materials (Appendix 1, Table S3 and Table S5).

Subgroup analysis

Subgroup of methodological aspects

In structural findings, when analyses were repeated and limited to methodologically homogeneous groups of studies, those reporting a slice thickness of 1.5 mm or less at acquisition did not observe decreased grey matter volume in the left fusiform gyrus or left inferior frontal gyrus, as seen when pooling all studies. Studies that used a smoothing kernel of 8 mm or less did not observe decreased grey matter volume in the left inferior frontal gyrus or right superior temporal gyrus. Studies

Table 1: Demographics and clinical characteristics from structural studies included in the meta-analysis

Study	No. of participants		Mean age, yr		Clinical data			Methodological aspects			Quality scores	
	Patients/ men	Controls/ men	Patients	Controls	Diagnosis	Illness duration, mo	PANSS, T/P/N	Intensity	Slice thickness, mm	FWHM, mm		Correction step
Salgado-Pineda et al ³⁷	13/13	13/13	23.76	23.36	FES	NA	NA/NA/NA	1.5 T	1	8	No	10.5
Jayakumar et al ³⁸	18/9	18/9	24.90	25.70	FES	10.30	79.00/19.00/23.00	1.5 T	1	12	Yes	12
Prasad et al ³⁹	15/NA	12/NA	NA	NA	FES	27.80	NA/NA/NA	1.5 T	1.5	12	No	10.5
Chua et al ⁴⁰	26/12	38/18	32.00	33.00	FES	4.00	72.00/NA/NA	1.5 T	3	4.4	Na	10.5
Meda et al ⁴¹	22/14	21/13	25.09	26.24	SCZ	NA	NA/NA/NA	1.5 T	1.5	8	Yes	11.5
Withaus et al ⁴²	23/16	29/17	26.40	25.70	FES	NA	NA/19.30/18.00	1.5 T	1	12	Yes	11.5
Venkatasubramanian et al ⁴³	30/21	27/9	30.10	27.40	FES	41.70	NA/22.00/23.00	1.5 T	1	12	Yes	12
Berge et al ⁴⁴	21/12	20/8	24.81	25.30	FES	NA	84.43/26.19/17.48	NA	1.4	8	No	9.5
Suazo et al ^{45*}	17/10	13/10	33.29	30.92	10, FES	63.30	74.20/20.93/16.53	1.5 T	1.5	NA	No	11
Ren et al ³¹	100/41	100/41	24.30	24.39	FES	6.25	97.88/25.11/18.84	3.0 T	1	6	Yes	12
Guo et al ^{28 (1)†}	27/16	30/16	25.10	25.60	SCZ	1.66	73.70/24.30/13.80	1.5 T	1.8	8	Yes	12
Guo et al ^{28 (2)}	30/16	30/16	25.70	25.60	SCZ	14.05	75.30/23.00/16.00	1.5 T	1.8	8	Yes	12
Guo et al ³⁴	49/30	50/23	22.69	23.48	FES	22.45	91.31/22.27/22.82	3.0 T	1	8	Yes	12
Guo et al ⁴⁶	51/33	41/24	22.50	22.80	FES	8.40	91.30/22.80/22.40	3.0 T	1.1	8	Yes	12
Nenadic et al ⁴⁷	24/12	49/23	24.90	23.80	FES	4.10	53.20/30.40/29.10	3.0 T	1	12	No	11
Yue et al ⁴⁸	20/10	24/13	24.45	24.79	FES	22.92	88.95/21.25/19.10	3.0 T	1	8	No	11

FES = first-episode schizophrenia; FWHM = full width at half maximum; N = negative; NA = not available; P = positive; PANSS = Positive And Negative Syndrome Scale; SCZ = schizophrenia; T = total.

*All patients included in the structural studies were drug-free except for those in this study, who underwent a medication wash-out period of longer than 1 month.

†This study divided patients into 2 data sets according to different duration of illness.

Table 2: Demographics and clinical characteristics from functional studies included in the meta-analysis

Study	No. of participants			Mean age, yr		Clinical data			Methodological aspects					
	Patients/ men	Controls/ men	Patients	Controls	Diagnosis	Drug status	Illness duration, mo	PANSS, T/P/N	Task	Intensity	Slice thickness, mm	FWHM, mm	Correction step	Quality score
Hofer et al ²⁷	10/NA	10/NA	30.9	29.2	SCZ	drug-free†	52.5	40/21.4/19.3	RM	1.5 T	3	9	Yes	12
Jones et al ⁴⁹	7/6	8/6	28.4	27.2	FES	drug-naive	NA	79.1/NA/NA	VF	1.5 T	3	7.2	NA	9.5
Weiss et al ⁵⁰	8/8	8/8	29.5	26.89	6, FES	drug-free‡	28.25	72.25/20/17.01	ST	1.5 T	3	8	Yes	11
Boksmann et al ⁵¹	10/9	10/9	22	23	FES	drug-free§	17	NA/NA/NA	WF	4.0 T	6	8	Yes	10.5
Scheuerecker et al ²⁹	23/19	23/19	31.6	32.6	FES	drug-free¶	26.4	NA/21.7/28.1	WM	1.5 T	4	8	Yes	12
Scheef et al ³⁵	11/8	25/12	32	30	8, FES	drug-free**	NA	43.1/20.2/21.4	RS	1.5 T	8	12	Yes	11.5
De la Fuente-Sandoval et al ⁵²	12/10	13/10	23.6	26.1	6, FES	drug-free††	17	86.7/20.5/22.5	PS	3.0 T	5	8	Yes	12
Nejad et al ⁵³	23/18	35/11	26.18	26.84	FES	drug-naive	NA	82.96/19.52/22.91	WM	3.0 T	3	8	Yes	11.5
Ren et al ³¹	100/41	100/41	24.3	24.39	FES	drug-naive	6.25	97.88/25.11/18.84	RS	3.0 T	5	6	Yes	12
Bin et al ⁵⁴	15/9	15/8	26.27	24.73	FES	drug-naive	7.1	96.45/32.27/18.91	AS	1.5 T	6	8	No	11
Hadley et al ⁵³	21/17	21/11	36	35.5	6, FES	drug-free‡‡	13.3	NA/NA/NA	RS	3.0 T	4	6	Yes	11.5
Schlagenhauf et al ⁵⁵	24/22	24/22	27.5	27.2	15, FES	drug-free§§	28.8	85.6/22.2/21.6	RL	3.0 T	4	8	Yes	12
Guo et al ⁵⁴	49/30	50/23	22.69	23.48	FES	drug-naive	22.45	91.31/22.27/22.82	RS	3.0 T	4	8	Yes	12
Lesh et al ⁵⁶	23/18	37/27	20.2	19.7	FES	drug-free¶¶	7	NA/NA/NA	CPT	1.5 T	4	10	Yes	11.5
Zheng et al ⁵²	35/20	30/13	15.5	15.43	FES	drug-naive	6.6	74.62/20.42/20.91	RS	3.0 T	4	6	Yes	12
Cui et al ^{30 (1)*}	17/10	19/10	13.71	14.74	FES	drug-naive	6.51	106.24/31.12/25.53	RS	3.0 T	4	4	Yes	12
Cui et al ^{30 (2)}	15/8	19/10	13.4	14.71	FES	drug-naive	10.2	88.07/17.93/22.73	RS	3.0 T	4	4	Yes	12

AS = auditory stimuli; CPT = Continuous Performance Task; FES = first-episode schizophrenia; FWHM = full width at half maximum; N = negative; NA = not available; P = positive; PANSS: Positive And Negative Syndrome Scale; PS = pain-tolerance stimuli; RL = Reversal Learning Task; RM = Warrington's Recognition Memory Test; RS = resting state; SCZ = schizophrenia; ST = Stroop task; T = total; VF = verbal fluency; WF = word fluency; WM: working memory.

*This study divided patients into 2 data sets according to different symptoms.

†Except anxiolytics or benzodiazepine derivatives, which were paused on the day of the study, none of the patients received any psychotropic medication at the time of the study.

‡Six patients were neuroleptic-naive and 2 were experiencing an acute exacerbation of positive symptoms due to noncompliance with antipsychotic medication.

§None of the patients had received antipsychotic medication, but 1 patient had received 20 mg of citalopram for 2 months that was stopped after 2 weeks.

¶Twenty patients were drug-naive, 3 patients were scanned after a wash-out period of 3 days.

**Patients have not taken or have been taking medication for a minimum of 2 weeks.

††Antipsychotic-free for at least 1 month.

‡‡All patients were off antipsychotic medications for at least 10 days.

§§The 15 first-episode patients were drug-naive; the remaining 9 received antipsychotic treatment with second-generation antipsychotics and had stopped for at least 3 weeks.

¶¶Seventeen were antipsychotic-naive and the remaining 5 had discontinued medication more than 1 month before the study.

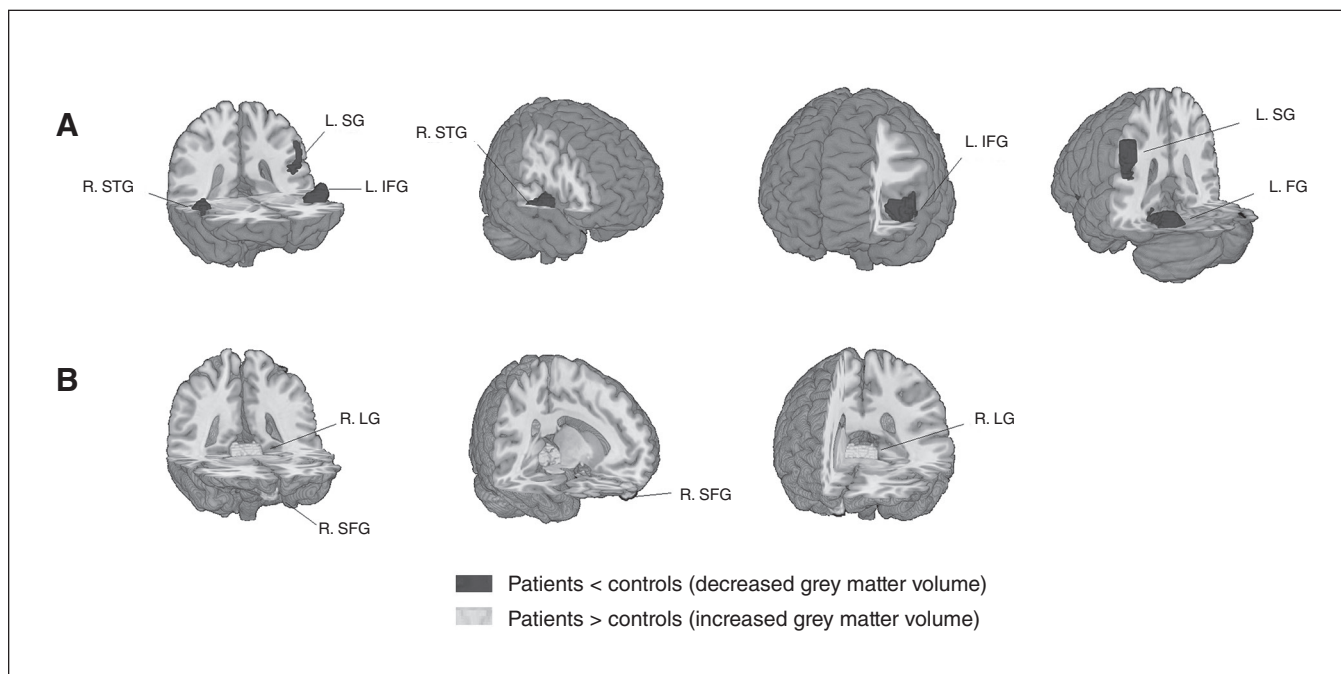


Fig. 2: Meta-analysis of structural abnormalities in drug-free patients with schizophrenia. The clusters with significant differences between diagnostic groups mainly showed (A) decreased grey matter volume in the right superior temporal gyrus (R. STG), left supramarginal gyrus (L. SG), left inferior frontal gyrus (L. IFG) and left fusiform gyrus (L. FG) and (B) increased grey matter volume in the right lingual gyrus (R. LG) and right superior frontal gyrus (R. SFG).

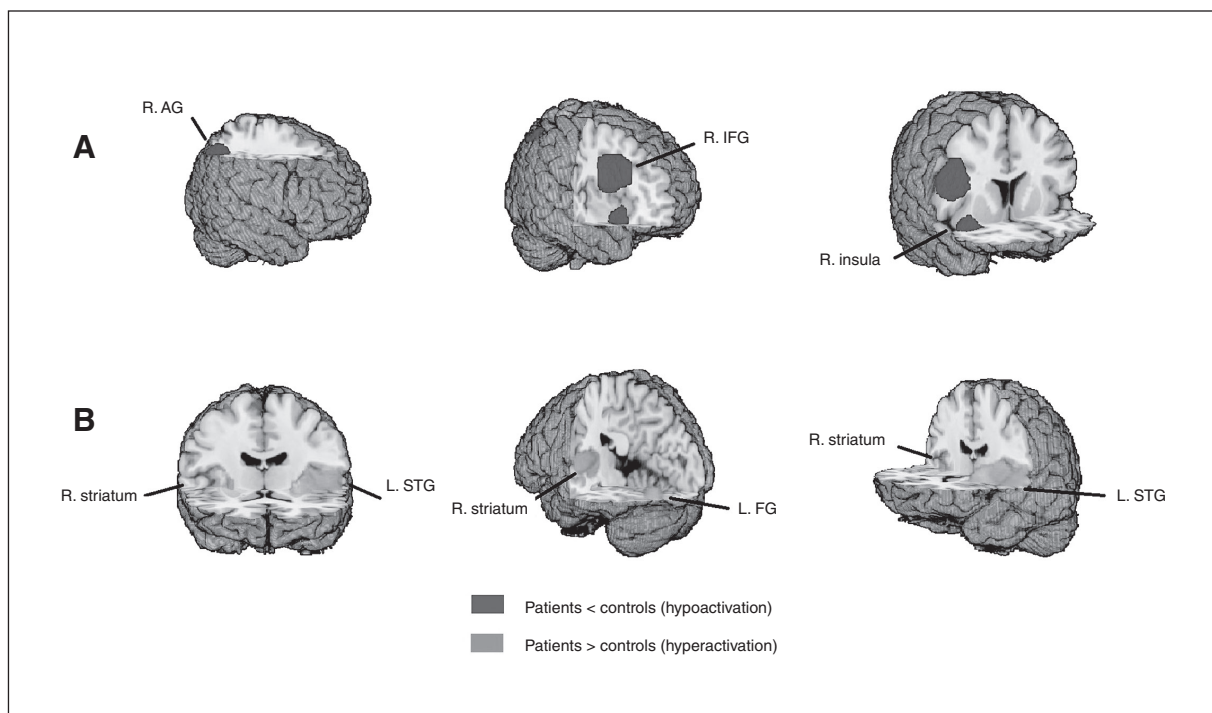


Fig. 3: Meta-analysis of functional abnormalities in drug-free patients with schizophrenia. The clusters with significant differences between diagnostic groups mainly showed (A) hypoactivation in the right angular gyrus (R. AG), right inferior frontal gyrus (R. IFG) and right insula (R. insula) and (B) hyperactivation in the left superior temporal gyrus (L. STG), right striatum (R. striatum) and left fusiform gyrus (L. FG).

using 1.5 T MRI did not show increased grey matter volume of the right lingual gyrus and right superior frontal gyrus or decreased grey matter volume in the left supramarginal gyrus. All the regions were preserved in the subgroup of studies that used an additional correction step (Appendix 1, Table S3).

In functional results, all regions were maintained in the subgroup of studies using a smoothing kernel of 8 mm or less and in those with an additional correction step. Functional studies reporting a slice thickness less than 5 mm at acquisition and that performed imaging during a task did not find activation in the right striatum and left inferior occipital gyrus or reduced

activation in the right angular gyrus. Studies using 1.5 T MRI did not observe activation alterations in the right striatum and left inferior occipital gyrus or reduced activation in the right angular gyrus or right insula (Appendix 1, Table S5).

Subgroup of studies with only drug-naive patients

All the structural findings were maintained in the studies including only drug-naive patients (Appendix 1, Table S3). In functional findings, the results remained largely unchanged except for the right insula for the subgroup analysis of drug-naive patients (Appendix 1, Table S5).

Table 3: Results of the multimodal analysis

Observation; region	MNI, x, y, z	SDM-Z*	p value†	Voxels‡	Cluster breakdown (no. of voxels)§
Decreased grey matter volume with hypoactivation					
L medial posterior cingulate/paracingulate gyrus	-4, -24, 42	2.139	< 0.001	1499	L medial posterior cingulate/paracingulate gyrus (637); R medial posterior cingulate/paracingulate gyrus (455); L paracentral lobule (100); R supplementary motor area (29); R anterior cingulate/paracingulate gyrus (28); L anterior cingulate/paracingulate gyrus (16)
R temporal pole, superior temporal gyrus	34, 8, -22	2.221	< 0.001	1446	R inferior frontal gyrus (519); R temporal pole, superior temporal gyrus (336); R insula (161); R parahippocampal gyrus (36); R amygdala (30); R rolandic operculum (24); R temporal pole, middle temporal gyrus (21)
L fusiform gyrus	-34, -54, -22	2.174	< 0.001	1075	L cerebellum, hemispheric lobule IV/V, VI, crus I (556); L fusiform gyrus (325); L middle temporal gyrus (173)
L inferior parietal gyrus	-52, -44, 44	2.401	< 0.001	333	L inferior parietal (300)
L caudate nucleus	-10, 0, 12	1.748	< 0.001	111	L caudate nucleus (21)
Decreased grey matter volume with hyperactivation					
L superior temporal gyrus	-56, -32, 20	2.902	< 0.001	4575	L superior temporal gyrus (1032); L insula (626); L rolandic operculum (523); L postcentral gyrus (370); L inferior frontal gyrus (351); L temporal pole, superior temporal gyrus (325); L supramarginal gyrus (284); L heschl gyrus (179); L precentral gyrus (102); L middle temporal gyrus (23); L middle temporal gyrus (23)
R superior temporal gyrus	46, -16, -2	2.131	< 0.001	1583	R superior temporal gyrus (356); R insula (333); R rolandic operculum (125); R lenticular nucleus, putamen (122); R middle temporal gyrus (101); R heschl gyrus (95)
L fusiform gyrus	-36, -68, -12	2.771	< 0.001	307	L fusiform gyrus (140); L inferior occipital gyrus (34); L cerebellum, hemispheric lobule VI (30)
R lingual gyrus	18, -70, -12	1.465	< 0.001	123	Right lingual gyrus (96)
Increased grey matter volume with hypoactivation					
L cerebellum	-6, -28, -18	2.432	< 0.001	1170	L cerebellum, hemispheric lobule III (165); Cerebellum, vermic lobule I/II (150); L pons (72); R lingual gyrus (44); R precuneus (39); L parahippocampal gyrus (25); L lingual gyrus (18); L calcarine fissure/surrounding cortex (12)
R gyrus rectus	2, 60, -18	3.088	< 0.001	934	R superior frontal gyrus (242); L superior frontal gyrus (196); L gyrus rectus (182); R gyrus rectus (158)
R inferior parietal gyrus	42, -56, 46	1.425	< 0.001	100	R inferior parietal (46); R angular gyrus (44)
Increased grey matter volume with hyperactivation					
L insula	-30, 0, 12	2.137	< 0.001	234	L insula (78); L striatum (57); L lenticular nucleus, putamen (55); L rolandic operculum (12)
L cerebellum, hemispheric lobule IX	-12, -56, -46	1.282	< 0.001	327	Left cerebellum, hemispheric lobule IX (223)

L = left; MNI = Montreal Neurological Institute; R = right; SDM-Z = Seed-based d Mapping Z score.

*Voxel probability threshold: $p = 0.0025$.

†Peak height threshold: $z = 0.00025$.

‡Cluster extent threshold: 100 voxels.

§Regions with fewer than 10 voxels are not reported in the cluster breakdown.

Heterogeneity and publication bias

We found statistical heterogeneity among studies that reported decreased grey matter in the right insula and left fusiform gyrus ($p < 0.005$; Appendix 1, Table S6). Also, hyperactivation in the left insula was statistically heterogeneous among studies ($p < 0.005$; Appendix 1, Table S7). The forest plots are shown in Appendix 1, Figures S1 and S2. The shape of funnel plots revealed asymmetry for all effects (Appendix 1, Table S8). Analysis of publication bias showed that the Egger test was nonsignificant for the left fusiform gyrus ($p = 0.47$), right superior temporal gyrus ($p = 0.36$), right inferior frontal gyrus ($p = 0.63$) and right insula ($p = 0.16$; Appendix 1, Table S8).

Meta-regression analysis

In the linear regression analysis, neither structural nor functional changes were associated with PANSS total score and subscale scores or duration of illness.

Discussion

This meta-analysis investigated the association between structural and functional changes in grey matter in a cohort of drug-

free patients with schizophrenia. We found largely overlapping anatomic and functional changes involving frontotemporal regions, the bilateral medial posterior cingulate/paracingulate gyrus, the bilateral insula and basal ganglia and the left cerebellum. However, the nature of regional anatomic and functional abnormalities in affected networks exhibited different patterns, including decreased grey matter with decreased activation within the default mode network (DMN) and decreased grey matter with increased activation within the auditory network (AN). Given that the medication effects were minimized and that the subgroup analyses of drug-naïve patients further enhanced the replicability across sMRI and fMRI results, these findings provide important novel insights into the pathophysiological substrate of schizophrenia. Clinical parameters, including duration of illness and PANSS scores, did not show significant associations with brain alterations, suggesting a relative stability of identified brain alterations in the early course of the disorder.

Our findings are generally consistent with previous observations and extend them in 2 important ways. First, we observed decreased grey matter with decreased activation and decreased grey matter with increased neural activation in different regions. Second, these different regions appeared to affect different neural networks. Thus, the most important and interesting observation from our meta-analysis was that opposite patterns

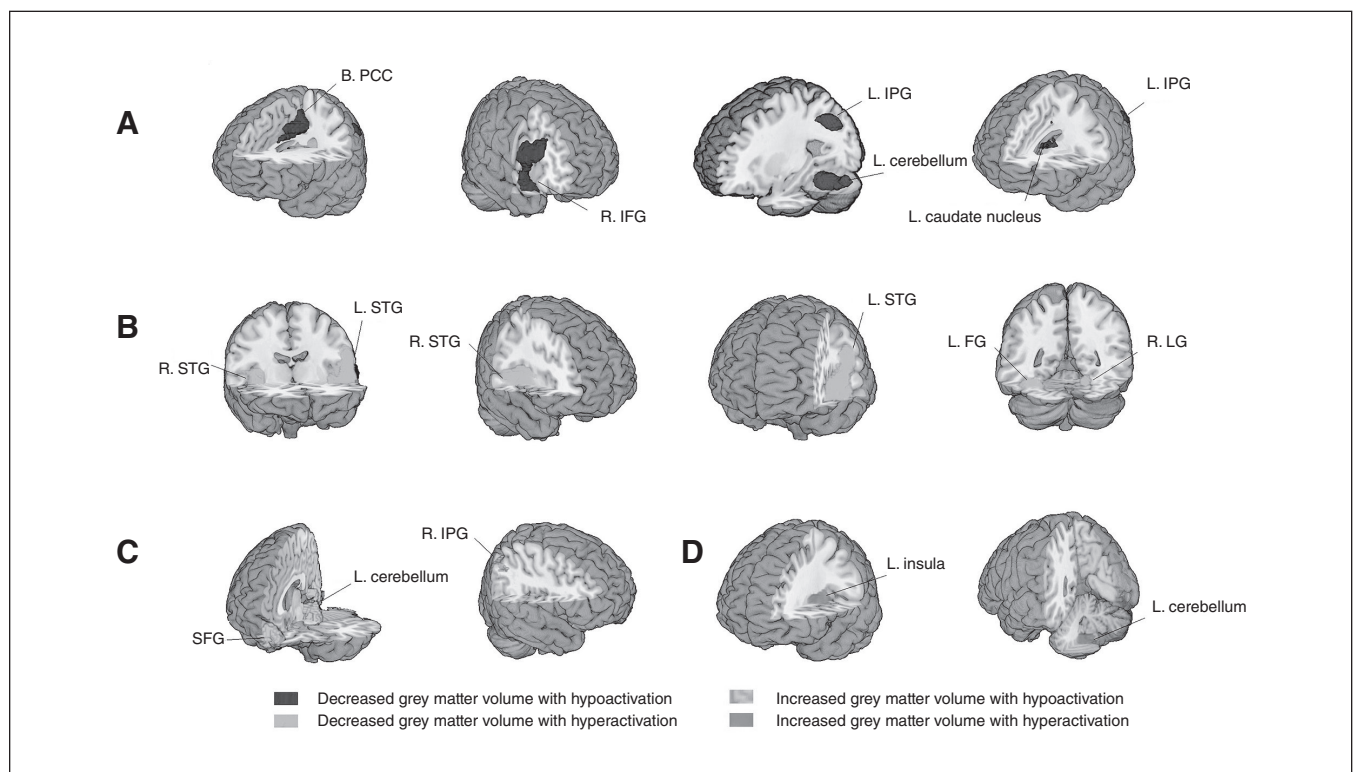


Fig. 4: Multimodal meta-analysis of structural and functional abnormalities in drug-free patients with schizophrenia. The clusters with significant differences in both structural and functional changes between diagnostic groups mainly showed (A) decreased grey matter volume with hypoactivation in the bilateral posterior cingulate cortex (B. PCC), right inferior frontal gyrus (R. IFG), left inferior parietal gyrus (L. IPG), left cerebellum (hemispheric lobule IV/V, VI, crus1) and left caudate nucleus (L. caudate nucleus); (B) decreased grey matter volume with hyperactivation in the bilateral superior temporal gyrus (STG), left fusiform gyrus (L. FG) and right lingual gyrus (R. LG); (C) increased grey matter volume with hypoactivation in the superior frontal gyrus (SFG), left cerebellum (hemispheric lobule III) and right inferior parietal gyrus (R. IPG); and (D) increased grey matter volume with hyperactivation in the left insula (L. insula) and left cerebellum (hemispheric lobule IX).

of association between structure and function manifest their characteristics in the DMN and AN. This pattern of functional and structural alterations may have significant implications for understanding brain changes evident early in the course of schizophrenia. We also observed that small parts of some brain regions exhibited either only structural or functional changes.

The largely parallel changes in structure and function in drug-free patients with schizophrenia are consistent with the findings of Radua and colleagues,²⁵ whose study included treated patients, which also found decreased grey matter volume with decreased or increased activity in the insula/superior temporal gyrus and the medial frontal/anterior cingulate cortex bilaterally in patients with first-episode schizophrenia. These findings suggest largely overlapping structural and functional deficits in both treated and untreated patients, though some other studies showed a dissociation between grey matter volume and resting-state functional changes in drug-naïve patients.³¹ However, we also found decreased grey matter volume with hypoactivation in the medial frontal/anterior cingulate gyrus and decreased grey matter volume with hyperactivation in the left anterior insula, which is opposite to the findings of Radua and colleagues. These inconsistencies may be due to the treatment effect or different samples. For example, previous studies have revealed hypoactivation before treatment, but hyperactivation after treatment in the medial frontal/anterior cingulate gyrus in patients with first-episode schizophrenia.^{56,57}

Though the regions with structural and functional changes largely overlapped, the patterns were complicated in different neural networks. We found decreased grey matter volume along with hypoactivation in the posterior cingulate and right inferior parietal cortex mainly within the DMN — one of the most consistent findings in both anatomic and functional studies.^{2,58} Reduced activation in the DMN nodes has been repeatedly observed in task-based studies and resting-state studies of schizophrenia,^{27,31,35,51,53,59,60} and is associated with impairment of emotional and cognitive processes.⁵¹ However, there was another pattern of changes within the DMN involving increased grey matter volume with deactivation in the bilateral superior frontal gyrus. This pattern was repeated in the subgroup analysis within drug-naïve patients and was consistent with our previous findings in drug-naïve patients with first-episode schizophrenia.^{31,61} The potential cause might be the preapoptotic osmotic changes or hypertrophy of the superior frontal cortex in such patients, which could increase regional volumes.⁶²

In the AN, a different pattern of findings was observed involving decreased grey matter volume coupled with hyperactivation in the bilateral superior and middle temporal gyrus, bilateral insula and Heschl gyrus. Our observation of altered bilateral superior and middle temporal gyri is similar to findings reported in previous functional and structural meta-analyses.^{63,64} The AN included primary and secondary auditory areas, and the deficits in these regions — especially in the superior and middle temporal gyrus — have been associated with auditory hallucinations and thought disorder in patients with schizophrenia.^{65,66}

Previous neuropathological studies have identified 2 important pathological changes that might account for opposite

patterns of structural/functional changes. The first set of findings suggested that grey matter volume may be associated with reduced neuron size or cell loss,^{7,67,68} with possible secondary effects including reduction in resting and evoked neural activity.^{69–71} A second set of observations document neuroinflammatory processes from studies of cytokines and microglial activation, which might induce glial cell activation.^{72,73} Inflammatory mediators could link themselves to the dopaminergic system through microglia and kynurenine metabolism to increase regional neural activity.⁵⁶ Taken together, these 2 types of neuropathological changes may underlie our observation of 2 main patterns of altered anatomic and functional associations. However, the precise mechanisms underlying divergent structural/functional associations in different brain regions remain unclear, and future work is needed to determine their cause and clinical implications.

Our study also found a small number of regions exhibiting either structural or functional brain changes only. Such structural and functional abnormalities were found separately in previous studies,^{74,75} which reflected a dissociation pattern between structural and functional changes in patients with schizophrenia.³¹ A possible explanation for the dissociations could be the classic phenomenon of crossed cerebellar diaschisis, which refers to a depression of blood flow and metabolism affecting the cerebellar hemisphere occurring as a result of a supratentorial focal lesion. The most likely mechanism behind it should be the abnormal interaction through the fibre tracts. This observation has also been reported in a previous schizophrenia study,⁷⁶ which found decreased grey matter volume in the left planum temporale, but found that the severity of thought disorder was mediated by activation in another part of the temporal lobe (posterior temporal lobe). Another possible explanation is that drugs may induce disparate changes in different brain regions. This possibility is supported by previous findings that functional changes were normalized after treatment and remission of clinical symptoms,⁵ whereas structural changes were more stable and showed slightly progressive alterations over the course of disease.^{2,36} Thus, this could extend our understanding of all possible pathophysiological processes underlying schizophrenia. Although such an observation is relatively uncommon in neuroimaging studies of schizophrenia, more work is needed to elucidate the precise mechanism.

Limitations

There are several noteworthy limitations to our study. First, the heterogeneity among different studies in participant characteristics; scan modalities, acquisition and analysis methods; behavioural tasks; and more inevitably leads to some imprecision in estimating anatomic and especially physiologic study findings. However, we conducted a series of complementary analyses, including subgroup analyses, and for the most part found consistent patterns of effect. Second, some patients enrolled in this study were not drug-naïve but had undergone a period of medication discontinuation, and some effects of chronic drug treatment might be evident in the MRI data.

However, because the subgroup analysis of drug-naive patients yielded similar findings as data from the whole group analysis, the effects we observed seem most likely to be illness-related rather than treatment-related. Multimodal analysis, as conducted in our study, did not directly detect correlations between structural and functional abnormalities, but rather showed brain regions in which schizophrenia is associated with structural and functional changes. Our findings thus point to brain regions in which such direct comparisons of structural and functional studies in the same patient sample in future studies via multimodal imaging may be informative.

Conclusion

The present study showed overlapping anatomic and functional brain abnormalities mainly in the DMN and AN in drug-free patients with schizophrenia. However, the complicated associations between the anatomic and functional findings (e.g., decreased grey matter with decreased activation within the DMN, decreased grey matter with increased activation within the AN) might suggest different pathophysiological changes implicated in different neural networks in patients with schizophrenia that need to be investigated further to clarify their causes and clinical implications.

Acknowledgements: This research was partially supported by the National Natural Science Foundation of China (Grant Nos. 81371527, 81671664, 81621003), Program for Changjiang Scholars and Innovative Research Team (PCSIRT, Grant No. IRT1272), University of China.

Affiliations: From the Department of Radiology, Second Affiliated Hospital of Wenzhou Medical University, Wenzhou, China (Gao, Lui); the Department of Radiology, the Centre for Medical Imaging, West China Hospital of Sichuan University, Chengdu, Sichuan, China (Gao, Zhang, Yao, Xiao, Liu, Li, Tao, Shah, Gong, Lui); and the Department of Psychiatry, University of Texas Southwestern, Dallas, Tex, USA (Sweeney).

Competing interests: None declared.

Contributors: Q. Gong and S. Lui designed the study. X. Gao, L. Yao, L. Liu, J. Liu, S. Li and B. Tao acquired the data, which all authors analyzed. X. Gao, W. Zhang and S. Lui wrote the article which all authors reviewed. All authors approved the final version to be published and can certify that no other individuals not listed as authors have made substantial contributions to the paper.

References

- Owen MJ, Sawa A, Mortensen PB. Schizophrenia. *Lancet* 2016;388:86-97.
- Chan RC, Di X, McAlonan GM, et al. Brain anatomical abnormalities in high-risk individuals, first-episode, and chronic schizophrenia: an activation likelihood estimation meta-analysis of illness progression. *Schizophr Bull* 2011;37:177-88.
- Minzenberg MJ, Laird AR, Thelen S, et al. Meta-analysis of 41 functional neuroimaging studies of executive function in schizophrenia. *Arch Gen Psychiatry* 2009;66:811-22.
- Deng MY, McAlonan GM, Cheung C, et al. A naturalistic study of grey matter volume increase after early treatment in anti-psychotic naive, newly diagnosed schizophrenia. *Psychopharmacology (Berl)* 2009;206:437-46.
- Lui S, Li T, Deng W, et al. Short-term effects of antipsychotic treatment on cerebral function in drug-naive first-episode schizophrenia revealed by "resting state" functional magnetic resonance imaging. *Arch Gen Psychiatry* 2010;67:783-92.
- Keshavan MS, Bagwell WW, Haas GL, et al. Changes in caudate volume with neuroleptic treatment. *Lancet* 1994;344:1434.
- Benes FM, McSparren J, Bird ED, et al. Deficits in small interneurons in prefrontal and cingulate cortices of schizophrenic and schizoaffective patients. *Arch Gen Psychiatry* 1991;48:996-1001.
- Rajkowska G, Selemon LD, Goldman-Rakic PS. Neuronal and glial somal size in the prefrontal cortex: a postmortem morphometric study of schizophrenia and Huntington disease. *Arch Gen Psychiatry* 1998;55:215-24.
- Selemon LD, Goldman-Rakic PS. The reduced neuropil hypothesis: a circuit based model of schizophrenia. *Biol Psychiatry* 1999;45:17-25.
- Egashira K, Matsuo K, Nakashima M, et al. Blunted brain activation in patients with schizophrenia in response to emotional cognitive inhibition: a functional near-infrared spectroscopy study. *Schizophr Res* 2015;162:196-204.
- Lui S, Yao L, Xiao Y, et al. Resting-state brain function in schizophrenia and psychotic bipolar probands and their first-degree relatives. *Psychol Med* 2015;45:97-108.
- Keedy SK, Bishop JR, Weiden PJ, et al. Disease and drug effects on internally generated and externally elicited responses in first episode schizophrenia and psychotic bipolar disorder. *Schizophr Res* 2014;159:101-6.
- Choi JS, Park JY, Jung MH, et al. Phase-specific brain change of spatial working memory processing in genetic and ultra-high risk groups of schizophrenia. *Schizophr Bull* 2012;38:1189-99.
- Wolf DH, Gur RC, Valdez JN, et al. Alterations of fronto-temporal connectivity during word encoding in schizophrenia. *Psychiatry Res* 2007;154:221-32.
- Stroup DF, Berlin JA, Morton SC, et al. Meta-analysis of observational studies in epidemiology: a proposal for reporting. Meta-analysis Of Observational Studies in Epidemiology (MOOSE) group. *JAMA* 2000;283:2008-12.
- Jiang J, Zhao YJ, Hu XY, et al. Microstructural brain abnormalities in medication-free patients with major depressive disorder: a systematic review and meta-analysis of diffusion tensor imaging. *J Psychiatry Neurosci* 2016;42:150341.
- Baiano M, David A, Versace A, et al. Anterior cingulate volumes in schizophrenia: a systematic review and a meta-analysis of MRI studies. *Schizophr Res* 2007;93:1-12.
- Brambilla P, Hardan A, di Nemi SU, et al. Brain anatomy and development in autism: review of structural MRI studies. *Brain Res Bull* 2003;61:557-69.
- Radua J, Mataix-Cols D, Phillips ML, et al. A new meta-analytic method for neuroimaging studies that combines reported peak coordinates and statistical parametric maps. *Eur Psychiatry* 2012;27:605-11.
- Radua J, Mataix-Cols D. Voxel-wise meta-analysis of grey matter changes in obsessive-compulsive disorder. *Br J Psychiatry* 2009;195:393-402.
- Radua J, Via E, Catani M, et al. Voxel-based meta-analysis of regional white-matter volume differences in autism spectrum disorder versus healthy controls. *Psychol Med* 2011;41:1539-50.
- Radua J, Mataix-Cols D. Meta-analytic methods for neuroimaging data explained. *Biol Mood Anxiety Disord* 2012;2:6.
- Nichols T, Brett M, Andersson J, et al. Valid conjunction inference with the minimum statistic. *Neuroimage* 2005;25:653-60.
- Radua J, Romeo M, Mataix-Cols D, et al. A general approach for combining voxel-based meta-analyses conducted in different neuroimaging modalities. *Curr Med Chem* 2013;20:462-6.
- Radua J, Borgwardt S, Crescini A, et al. Multimodal meta-analysis of structural and functional brain changes in first episode psychosis and the effects of antipsychotic medication. *Neurosci Biobehav Rev* 2012;36:2325-33.
- Wise T, Radua J, Nortje G, et al. Voxel-based meta-analytical evidence of structural disconnectivity in major depression and bipolar disorder. *Biol Psychiatry* 2015;79:293-302.
- Hofer A, Weiss EM, Golaszewski SM, et al. Neural correlates of episodic encoding and recognition of words in unmedicated patients during an acute episode of schizophrenia: a functional MRI study. *Am J Psychiatry* 2003;160:1802-8.
- Guo X, Li J, Wei Q, et al. Duration of untreated psychosis is associated with temporal and occipitotemporal gray matter volume decrease in treatment naive schizophrenia. *PLoS ONE* 2013;8:e83679.
- Scheuerecker J, Ufer S, Zipse M, et al. Cerebral changes and cognitive dysfunctions in medication-free schizophrenia — an fMRI study. *J Psychiatr Res* 2008;42:469-76.
- Cui LB, Liu K, Li C, et al. Putamen-related regional and network functional deficits in first-episode schizophrenia with auditory verbal hallucinations. *Schizophr Res* 2016;173:13-22.

31. Ren W, Lui S, Deng W, et al. Anatomical and functional brain abnormalities in drug-naive first-episode schizophrenia. *Am J Psychiatry* 2013;170:1308-16.
32. Zheng J, Zhang Y, Guo X, et al. Disrupted amplitude of low-frequency fluctuations in antipsychotic-naive adolescents with early-onset schizophrenia. *Psychiatry Res* 2016;249:20-6.
33. Hadley JA, Nenert R, Kraguljac NV, et al. Ventral tegmental area/midbrain functional connectivity and response to antipsychotic medication in schizophrenia. *Neuropsychopharmacology* 2014;39:1020-30.
34. Guo W, Liu F, Xiao C, et al. Dissociation of anatomical and functional alterations of the default-mode network in first-episode, drug-naive schizophrenia. *Clin Neurophysiol* 2015;126:2276-81.
35. Scheef L, Manka C, Daamen M, et al. Resting-state perfusion in nonmedicated schizophrenic patients: a continuous arterial spin-labeling 3.0-T MR study. *Radiology* 2010;256:253-60.
36. Zou QH, Zhu CZ, Yang Y, et al. An improved approach to detection of amplitude of low-frequency fluctuation (ALFF) for resting-state fMRI: fractional ALFF. *J Neurosci Methods* 2008;172:137-41.
37. Salgado-Pineda P, Baeza I, Pérez-Gómez M, et al. Sustained attention impairment correlates to gray matter decreases in first episode neuroleptic-naive schizophrenic patients. *Neuroimage* 2003;19:365-75.
38. Jayakumar PN, Venkatasubramanian G, Gangadhar BN, et al. Optimized voxel-based morphometry of gray matter volume in first-episode, antipsychotic-naive schizophrenia. *Prog Neuropsychopharmacol Biol Psychiatry* 2005;29:587-91.
39. Prasad KM, Shirts BH, Yolken RH, et al. Brain morphological changes associated with exposure to HSV1 in first-episode schizophrenia. *Mol Psychiatry* 2007;12:105-13.
40. Chua SE, Cheung C, Cheung V, et al. Cerebral grey, white matter and CSF in never-medicated, first-episode schizophrenia. *Schizophrenia Res* 2007;89:12-21.
41. Meda SA, Giuliani NR, Calhoun VD, et al. A large scale ($n=400$) investigation of gray matter differences in schizophrenia using optimized voxel-base morphometry. *Schizophrenia Res* 2008;101:95-105.
42. Witthaus H, Kaufmann C, Bohner G, et al. Gray matter abnormalities in subjects at ultra-high risk for schizophrenia and first-episode schizophrenic patients compared to healthy controls. *Schizophrenia Res* 2009;173:163-9.
43. Venkatasubramanian G. Neuroanatomical correlates of psychopathology in antipsychotic-naive schizophrenia. *Indian J Psychiatry* 2010;52:28-36.
44. Berge D, Carmona S, Rovira M, et al. Gray matter volume deficits and correlation with insight and negative symptoms in first-psycho-epic subjects. *Acta Psychiatrica Scandinavica* 2011;123:431-9.
45. Suazo V, Diez A, Montes C, et al. Structural correlates of cognitive deficit and elevated gamma noise power in schizophrenia. *Psychiatry Clin Neurosci* 2014;68:206-15.
46. Guo X, Li J, Wang J, et al. Hippocampal and orbital inferior frontal gray matter volume abnormalities and cognitive deficit in treatment-naive, first-episode patients with schizophrenia. *Schizophrenia Res* 2014;152:339-43.
47. Nenadic I, Dietzek M, Schonfeld N, et al. Brain structure in people at ultra-high risk of psychosis, patients with first-episode schizophrenia, and healthy controls: a VBM study. *Schizophrenia Res* 2015;161:169-76.
48. Yue Y, Kong L, Wang J, et al. Regional abnormality of grey matter in schizophrenia: Effect from the illness or treatment? *PLoS One* 2016;11:e0147204.
49. Jones HM, Brammer MJ, O'Toole M, et al. Cortical effects of quetiapine in first-episode schizophrenia: a preliminary functional magnetic resonance imaging study. *Biol Psychiatry* 2004;56:938-42.
50. Weiss EM, Siedentopf C, Golaszewski S, et al. Brain activation patterns during a selective attention test — a functional MRI study in healthy volunteers and unmedicated patients during an acute episode of schizophrenia. *Psychiatry Res* 2007;154:31-40.
51. Boksman K, Theberge J, Williamson P, et al. A 4.0-T fMRI study of brain connectivity during word fluency in first-episode schizophrenia. *Schizophr Res* 2005;75:247-63.
52. De la Fuente-Sandoval C, Favila R, Gomez-Martin D, et al. Functional magnetic resonance imaging response to experimental pain in drug-free patients with schizophrenia. *Psychiatry Res* 2010;183:99-104.
53. Nejad AB, Ebdrup BH, Siebner HR, et al. Impaired temporoparietal deactivation with working memory load in antipsychotic-naive patients with first-episode schizophrenia. *World J Biol Psychiatry* 2011;12:271-81.
54. Ji B, Mei W, Zhang JX, et al. Abnormal auditory sensory gating-out in first-episode and never-medicated paranoid schizophrenia patients: an fMRI study. *Exp Brain Res* 2013;229:139-47.
55. Schlagenhauf F, Huys QJ, Deserno L, et al. Striatal dysfunction during reversal learning in unmedicated schizophrenia patients. *Neuroimage* 2014;89:171-80.
56. Lesh TA, Tanase C, Geib BR, et al. A multimodal analysis of antipsychotic effects on brain structure and function in first-episode schizophrenia. *JAMA Psychiatry* 2015;72:226-34.
57. Meisenzahl EM, Scheuerecker J, Zipse M, et al. Effects of treatment with the atypical neuroleptic quetiapine on working memory function: a functional MRI follow-up investigation. *Eur Arch Psychiatry Clin Neurosci* 2006;256:522-31.
58. Broyd SJ, Demanuele C, Debener S, et al. Default-mode brain dysfunction in mental disorders: a systematic review. *Neurosci Biobehav Rev* 2009;33:279-96.
59. De la Fuente-Sandoval C, Favila R, Gomez-Martin D, et al. Functional magnetic resonance imaging response to experimental pain in drug-free patients with schizophrenia. *Psychiatry Res* 2010;183:99-104.
60. Andreasen NC, O'Leary DS, Flaum M, et al. Hypofrontality in schizophrenia: distributed dysfunctional circuits in neuroleptic-naive patients. *Lancet* 1997;349:1730-4.
61. Huang XQ, Lui S, Deng W, et al. Localization of cerebral functional deficits in treatment-naive, first-episode schizophrenia using resting-state fMRI. *Neuroimage* 2010;49:2901-6.
62. Adler CM, Levine AD, DelBello MP, et al. Changes in gray matter volume in patients with bipolar disorder. *Biol Psychiatry* 2005;58:151-7.
63. Modinos G, Costafreda SG, van Tol MJ, et al. Neuroanatomy of auditory verbal hallucinations in schizophrenia: a quantitative meta-analysis of voxel-based morphometry studies. *Cortex* 2013;49:1046-55.
64. Jardri R, Pouchet A, Pins D, et al. Cortical activations during auditory verbal hallucinations in schizophrenia: a coordinate-based meta-analysis. *Am J Psychiatry* 2011;168:73-81.
65. Barta PE, Pearlson GD, Powers RE, et al. Auditory hallucinations and smaller superior temporal gyral volume in schizophrenia. *Am J Psychiatry* 1990;147:1457-62.
66. Shenton ME, Kikinis R, Jolesz FA, et al. Abnormalities of the left temporal lobe and thought disorder in schizophrenia. A quantitative magnetic resonance imaging study. *N Engl J Med* 1992;327:604-12.
67. Kreczmanski P, Heinsen H, Mantua V, et al. Volume, neuron density and total neuron number in five subcortical regions in schizophrenia. *Brain* 2007;130:678-92.
68. Pakkenberg B. Pronounced reduction of total neuron number in mediodorsal thalamic nucleus and nucleus accumbens in schizophrenics. *Arch Gen Psychiatry* 1990;47:1023-8.
69. Bersani FS, Minichino A, Fojanesi M, et al. Cingulate cortex in schizophrenia: its relation with negative symptoms and psychotic onset. A review study. *Eur Rev Med Pharmacol Sci* 2014;18:3354-67.
70. Haznedar MM, Buchsbaum MS, Hazlett EA, et al. Cingulate gyrus volume and metabolism in the schizophrenia spectrum. *Schizophr Res* 2004;71:249-62.
71. Roberts RC, Barksdale KA, Roche JK, et al. Decreased synaptic and mitochondrial density in the postmortem anterior cingulate cortex in schizophrenia. *Schizophr Res* 2015;168:543-53.
72. Watkins CC, Andrews SR. Clinical studies of neuroinflammatory mechanisms in schizophrenia. *Schizophr Res* 2016;176:14-22.
73. Muller N. Immunology of schizophrenia. *Neuroimmunomodulation* 2014;21:109-16.
74. Shah C, Zhang W, Xiao Y, et al. Common pattern of gray-matter abnormalities in drug-naive and medicated first-episode schizophrenia: a multimodal meta-analysis. *Psychol Med* 2016;47:1-13.
75. Lui S, Deng W, Huang X, et al. Association of cerebral deficits with clinical symptoms in antipsychotic-naive first-episode schizophrenia: an optimized voxel-based morphometry and resting state functional connectivity study. *Am J Psychiatry* 2009;166:196-205.
76. Weinstein S, Woodward TS, Ngan ET. Brain activation mediates the association between structural abnormality and symptom severity in schizophrenia. *Neuroimage* 2007;36:188-93.