

Glycogenic hepatopathy: A narrative review

Jagannath M Sherigar, Joline De Castro, Yong Mei Yin, Debra Guss, Smruti R Mohanty

Jagannath M Sherigar, Joline De Castro, Debra Guss, Smruti R Mohanty, Department of Gastroenterology and Hepatology, NYP-Brooklyn Methodist Hospital, Brooklyn, NY 11215, United States

Yong Mei Yin, NYP-Brooklyn Methodist Hospital, Brooklyn, NY 11215, United States

ORCID number: Jagannath M Sherigar (0000-0003-4405-4126); Joline De Castro (0000-0002-8183-5872); Yong Mei Yin (0000-0001-6698-98610); Debra Guss (0000-0002-3292-9602); Smruti R Mohanty (0000-0003-4887-5837).

Author contributions: All authors have equally contributed to this paper with conception and design of the study, literature review, drafting, editing and final approval of the manuscript.

Conflict-of-interest statement: No potential conflicts of interest or financial support related to this paper.

Open-Access: This article is an open-access article which was selected by an in-house editor and fully peer-reviewed by external reviewers. It is distributed in accordance with the Creative Commons Attribution Non Commercial (CC BY-NC 4.0) license, which permits others to distribute, remix, adapt, build upon this work non-commercially, and license their derivative works on different terms, provided the original work is properly cited and the use is non-commercial. See: <http://creativecommons.org/licenses/by-nc/4.0/>

Manuscript source: Unsolicited manuscript

Correspondence to: Smruti R Mohanty, MD, MS, FACP, Chief, Department of Gastroenterology and Hepatology, NYP-Brooklyn Methodist Hospital, 5841 S. Maryland Avenue, 506, 6th Street, Brooklyn, NY 11215, United States. srm9006@nyp.org
Telephone: +1-718-7803851
Fax: +1-718-7803478

Received: November 12, 2017

Peer-review started: November 12, 2017

First decision: December 4, 2017

Revised: December 22, 2017

Accepted: January 22, 2018

Article in press: January 24, 2018

Published online: February 27, 2018

Abstract

Glycogenic hepatopathy (GH) is a rare complication of the poorly controlled diabetes mellitus characterized by the transient liver dysfunction with elevated liver enzymes and associated hepatomegaly caused by the reversible accumulation of excess glycogen in the hepatocytes. It is predominantly seen in patients with longstanding type 1 diabetes mellitus and rarely reported in association with type 2 diabetes mellitus. Although it was first observed in the pediatric population, since then, it has been reported in adolescents and adults with or without ketoacidosis. The association of GH with hyperglycemia in diabetes has not been well established. One of the essential elements in the pathophysiology of development of GH is the wide fluctuation in both glucose and insulin levels. GH and non-alcoholic fatty liver disease (NAFLD) are clinically indistinguishable, and latter is more prevalent in diabetic patients and can progress to advanced liver disease and cirrhosis. Gradient dual-echo MRI can distinguish GH from NAFLD; however, GH can reliably be diagnosed only by liver biopsy. Adequate glycemic control can result in complete remission of clinical, laboratory and histological abnormalities. There has been a recent report of varying degree of liver fibrosis identified in patients with GH. Future studies are required to understand the biochemical defects underlying GH, noninvasive, rapid diagnostic tests for GH, and to assess the consequence of the fibrosis identified as severe fibrosis may progress to cirrhosis. Awareness of this entity in the medical community including specialists is low. Here we briefly reviewed the English literature on pathogenesis involved, recent progress in the evaluation, differential diagnosis, and management.

Key words: Glycogenic hepatopathy; Diabetes mellitus; Hepatomegaly; Mauriac syndrome; Elevated liver enzymes; Liver biopsy; Gradient dual-echo MRI

© The Author(s) 2018. Published by Baishideng Publishing Group Inc. All rights reserved.

Core tip: Glycogenic hepatopathy (GH) is considered as a benign reversible condition. Elevation in transaminases is a common finding in patients with diabetes mellitus, and non-alcoholic fatty liver disease (NAFLD) and GH are the two primary underlying pathologies in most cases. It is essential to distinguish NAFLD from GH as this can progress to advanced liver disease. However, recent studies have identified the varying degree of fibrosis in glycogen hepatopathy as well, further emphasizing the need for future studies. We briefly reviewed the literature on mechanisms involved in the development of GH, evaluation of these patients, recent progress made on diagnostic tests and management.

Sherigar JM, Castro JD, Yin YM, Guss D, Mohanty SR. Glycogenic hepatopathy: A narrative review. *World J Hepatol* 2018; 10(2): 172-185 Available from: URL: <http://www.wjgnet.com/1948-5182/full/v10/i2/172.htm> DOI: <http://dx.doi.org/10.4254/wjh.v10.i2.172>

INTRODUCTION

GH is a rare clinical condition that develops due to excessive accumulation of glycogen in the hepatocytes predominantly seen in pediatric patients and young adults with poorly controlled type 1 diabetes mellitus (T1DM), and rarely observed in a patient with type 2 diabetes mellitus (T2DM)^[1-48] (Tables 1-3). GH is characterized by transient liver dysfunction with elevated liver enzymes and associated hepatomegaly caused by a reversible accumulation of excess glycogen in hepatocytes. The collection of glycogen seen on a liver biopsy is critical for the diagnosis. It is an underrecognized entity, and awareness of this clinical condition by clinicians, including gastroenterologists, is low.

GH was initially described in 1930 by Pierre Mauriac in a pediatric patient with poorly controlled T1DM (brittle DM), who presented with hepatomegaly, cushingoid features, and poor growth and development, a condition known as Mauriac Syndrome^[30,45]. Since then, more cases have been reported without the full spectrum of Mauriac Syndrome, both in adults and children with T1DM and rarely in T2DM. Various terms have been used to describe this entity, including hepatic glycogenesis, glycogen hepatopathy, glycogen storage hepatomegaly and hepatic glycogen storage^[2,4-7,9,14,47]. In 2006, Torbenson and colleagues proposed the term "Glycogenic Hepatopathy" due to hepatocyte glycogen overload but without showing extrahepatic features of Mauriac Syndrome. This term has been used universally since then to describe this unique pathologic feature^[44].

The pathophysiology of GH is incompletely understood, and clinical characteristics have not been fully

characterized yet. It is believed to be the consequence of recurrent fluctuations in glucose level with hyperglycemia, hypoglycemia, and hyperinsulinization. In addition to glycogen accumulation, steatosis with varying degree of fibrosis may be evident in liver biopsy^[38,45]. Intensive insulin regimens with glycemic control provide full resolution of clinical symptoms, laboratory abnormalities, and histological abnormalities.

GH remains underrecognized in adults, as most clinicians mistake it for NAFLD, a more common hepatic abnormality associated with DM. The clinical or radiological distinction between GH and NAFLD is difficult. It is essential that primary care physicians and other specialists be aware of this entity, as differentiating this condition from NAFLD is vital, given its associated comorbidities such as cardiovascular disease, progressive liver fibrosis, and cirrhosis. The focus of this review is to provide an update on recent development in understanding the pathophysiology and the progress in the noninvasive evaluation of differentiating nonalcoholic fatty liver disease from glycogenic hepatopathy.

LITERATURE SEARCH

A literature search was conducted using PubMed using search terms "glycogen" (MeSH Terms) OR "glycogen" (All Fields) AND ["liver diseases" (MeSH Terms) OR "liver" (All Fields) AND "diseases" (All Fields)] OR "liver diseases" (All Fields) OR "hepatopathy" (All Fields)". A total of fifty-one studies involving adolescents or adults were included for this review.

INCIDENCE

Much of the knowledge on GH that has been accumulated over the decades since GH was first reported in 1930, are from case reports, case series, a retrospective cohort study, or more recently, a case-control study^[45,46]. It has been estimated that about 8% of American adults have elevated serum aminotransferases^[49]. Following a negative initial serologic evaluation, 90% of patients with chronically elevated abnormal aminotransferases are due to NAFLD^[50]. The prevalence of liver disease among people with diabetes is estimated to be 17% to 100%^[51], with nonalcoholic fatty liver disease and hepatic glycogenesis being the predominant pathologies.

True incidence and prevalence of GH are unknown. Sixty-two percent of the reported cases are female patients, indicating a slight female predominance. Thirty-eight percent of reported cases are male patients, with most cases occurring in adolescence. Based on published reports in English literature, approximately 98% of GH cases were reported in T1DM, while the remaining 2% is caused by T2DM. The incidence of this syndrome has decreased significantly with the introduction of long-acting insulin and better control of

Table 1 Summary of the major case reports in English (pub med indexed) on Glycogenic hepatopathy in type 1 diabetes mellitus

Ref.	Study design	Age/sex	HbA1C	Keto acidosis	Hepatomegaly	AST/ALT/ALP/T bili	Normalization of LFTs
Ruschhaupt <i>et al</i> ^[1] , 1970	Case report	13/M	NA	Yes	Yes	9/14/115/128/NA	5 d
Berman <i>et al</i> ^[2] , 1973	Case report	21/F	NA	Yes	Yes	UK	Expired (5 d)
Olsson <i>et al</i> ^[3] , 1989	Case report	15/F	NA	Yes	Yes	535/417/570/NA	10 d
		20/F	NA	No	Yes	1117/1235/941/NA	18 mo
		24/F	NA	Yes	No	323/276/429/NA	NA
		13/M	14.1	No	Yes	132/135/170/NA	4 wk
Munns <i>et al</i> ^[4] , 2000	Case reports	17/F	13.3	No	Yes	102/147/175/NA	2 wk
		16/F	12.2	No	Yes	567/316/196/NA	2 wk
		18/F	NA	Yes	Yes	Elevated/N	After pancreatic transplant
Fridell <i>et al</i> ^[5] , 2007	Case report	21/M	NA	No	Yes	Elevated/N	After pancreatic transplant
		19/F	12.2	Yes	Yes	NA/800/132/N	NA
Cuthbertson <i>et al</i> ^[6] , 2007	Case report	19/F	8.1	Yes	Yes	98/49/147/0.5	NA
Sayuk <i>et al</i> ^[7] , 2007	Case report	37/M	16.0	Yes	Yes	226/399/326/0.9	NA
		10/F	10.1	No	No	143/147/137/N	NA
		16/M	11.1	No	Yes	66/58/431/0.8	3 mo
Abaci <i>et al</i> ^[9] , 2008	Case report	20/F	13.3	No	Yes	249/383/NA/NA	5 mo
Hudacko <i>et al</i> ^[10] , 2008	Case report	27/M	15.0	No	Yes	6720/2549/529/1.7	3 mo
Sweetser <i>et al</i> ^[11] , 2010	Case report	29/F	15.3	No	No	2500/1000/316/NA	NA
Van Den Brand ^[12] , 2009	Case report	33/F	13.7	No	No	428/404/205/N	12 mo
Saxena <i>et al</i> ^[13] , 2010	Case report	17/F	12.0	No	Yes	138/164/NA/NA	12 mo
Bua <i>et al</i> ^[14] , 2010	Case report	13/F	13.0	No	Yes	NA/500/137/N	3 mo
Aljabri <i>et al</i> ^[15] , 2011	Case report	14/F	11.0	No	Yes	Elevated	Few days
Dantuluri <i>et al</i> ^[16] , 2012	Case report	10/F	12.8	Yes	Yes	121/194/185/NA	6 mo
Lin <i>et al</i> ^[17] , 2012	Case report	31/F	10.3	No	Yes	225/258/375/0.54	2 mo
Messeri <i>et al</i> ^[18] , 2012	Case report	21/M	6.2	Yes	No	119/122/NA/NA	25 d
Murata <i>et al</i> ^[19] , 2012	Case report	22/F	13.8	No	Yes	1028/365/346/0.5	8 wk
		26/F	12.9	Yes	Yes	914/307/189/0.5	4 wk
		20/F	13.6	No	No	1310/346/132/0.2	16 wk
		18/M	11.0	No	Yes	144/92/123/1.4	3 mo
Saadi T ^[21] , 2012	Case report	13/M	12.0	No	Yes	100/191/NA/NA	NA
Saikusa <i>et al</i> ^[22] , 2012	Case report	19/F	14.6	Yes	Yes	NA/199/139/NA	5 mo
Intiaz <i>et al</i> ^[23] , 2013	Case report	13/F	8.8	Yes	Yes	NA/113/NA/NA	NA
Butts <i>et al</i> ^[24] , 2014	Case report	13/F	10.7	Yes	Yes	105/84/NA/NA	3 mo
Jeong <i>et al</i> ^[25] , 2014	Case report	13/M	10.4	Yes	Yes	3969/1196/NA/NA	16 d
Martin <i>et al</i> ^[26] , 2014	Case report	21/F	NA	Yes	Yes	4202/973/N/N	1 wk
Parmar <i>et al</i> ^[27] , 2015	Case report	22/M	14.6	No	Yes	331/223/223/0.3	NA
Xu <i>et al</i> ^[28] , 2015	Case report	28/F	10.5	No	Yes	1600/534/N/N	NA
Garcia-Suarez <i>et al</i> ^[29] , 2015	Case report	19/M	NA	Yes	Yes	603/570/921/NA	3 wk
Atmaca <i>et al</i> ^[30] , 2015	Case report	19/M	12.0	Yes	Yes	505/345/145/N	NA
Irani <i>et al</i> ^[31] , 2015	Case report	19/F	9.5	No	Yes	Elevated	NA
		19/F	13.3	No	Yes	Elevated	NA
		17/M	12.7	No	Yes	Elevated	NA
		20/F	14.7	No	Yes	Elevated	NA
		5/F	16.1	Yes	Yes	53/20/NA/0.7	NA
Charndrasekaran <i>et al</i> ^[33] , 2015	Case report	21/F	9.0	Yes	Yes	110/120/190/0.74	Few days
		20/F	10.1	Yes	Yes	270/423/179/1	Few days
		29/F	10.9	No	Yes	910/461/172/0.35	3 mo
		22/M	15.7	Yes	Yes	226/109/79/0.64	2 wk
Deemer <i>et al</i> ^[35] , 2016	Case report	18/F	11.3	Yes	Yes	NA/36/120/N	NA
Saracho <i>et al</i> ^[36] , 2016	Case report	14/M	12.8	Yes	Yes	Elevated	NA
Chandel <i>et al</i> ^[37] , 2017	Case report	12/F	10.5	Yes	Yes	690/356/158/0.2	3 mo
Ikarashi <i>et al</i> ^[38] , 2017	Case report	21/M	11.7	No	Yes	2723/956/NA/NA	1 mo
		24/F	11.0	Yes	Yes	658/216/NA/NA	Few days
		19/F	13.6	Yes	Yes	737/266/NA/NA	Few days
		29/F	16.5	Yes	Yes	469/243/NA/NA	6 mo
		23/F	12.3	Yes	Yes	127/199/160/2.7	Few days
Maharaj <i>et al</i> ^[39] , 2017	Case report	6/M	11.6	Yes	Yes	367/205/221/N	Few days
Al Sarkhy <i>et al</i> ^[40] , 2017	Case report	31/F	NA	Yes	Yes	627/185/280/0.7	NA
Shah <i>et al</i> ^[41] , 2017	Case report	14/M	11.0	Yes	Yes	Normal	NA
Omer ^[42] , 2017	Case report						

HbA1C: Hemoglobin A1c; AST: Aspartate transferase; ALT: Alanine transferase; ALP: Alkaline phosphatase; T bili: Total bilirubin; M: Male; F: Female; NA: Not available.

Table 2 Summary of the major studies in English (pub med indexed) on Glycogenic hepatopathy in type 1 diabetes mellitus

Ref.	Study design	Age/sex	HbA1C	Keto acidosis	Hepatomegaly	Liver abnormality	Normalization of LFTs
Chatila <i>et al</i> ^[43] , 1996	Retrospective Study	Mild Fibrosis (14%)	11patients (8-A and 3-P)				
		41/F	NA	NA	No	20/45/1.4 x ULN/0.35	Few days to weeks
		21/F	NA	NA	NA	282/404/0.4 x ULN/0.28	Few days to weeks
		58/F	NA	NA	NA	35/56/3.2 x ULN/0.40	Few days to weeks
		70/F	NA	NA	NA	76/NA/NA/1.28	Few days to weeks
		36/F	NA	NA	NA	40/86/2.1 x ULN/0.28	Few days to weeks
		46/F	NA	NA	NA	22/20/1.7 x ULN/N	Few days to weeks
		23/F	NA	NA	NA	265/410/9.5 x ULN/0.40	Few days to weeks
		19/F	NA	NA	NA	344/532/2.6 x ULN/0.8	Few days to weeks
		13/M	NA	NA	NA	940/910/2 x ULN/0.30	Few days to weeks
		13/M	NA	NA	NA	85/NA/0.3 x ULN/0.48	Few days to weeks
		15/M	NA	NA	NA	NA/NA/1.9 x ULN/0.08	Few days to weeks
		Torbenson <i>et al</i> ^[44] , 2006	Retrospective Study	14 patients			
19/F	NA			Yes	Yes	97/83/80/NA	NA
1/2M	13.5			Yes	Yes	49/47/182/NA	NA
22/F	NA			No	Yes	48/77/62/NA	NA
8/M	NA			No	Yes	Elevated/NA	NA
15/F	NA			No	NA	Normal	NA
22/M	16			Yes	Yes	1100/360/251/NA	NA
25/M	10.8			NA	NA	1629/1128/298/NA	NA
16/M	NA			Yes	NA	Elevated/NA	NA
20/M	9.9			No	yes	N/120/147/NA	NA
18/F	10.8			No	NA	N/57/N/NA	NA
28/M	NA			No	NA	1099/1544/384/NA	NA
34/M	10.1			No	Yes	N/NA/N/NA	NA
16/M	NA	No	Yes	1413/1354/476/NA	NA		
23/F	NA	No	Yes	255/224/307/NA	NA		
Fitzpatrick <i>et al</i> ^[45] , 2014	Retrospective	31 patients	11(Mean)	Yes-all	76/76/NA/NA(M)	NA	14 (73%) Fibrosis
		16M/15F	12Mild and 2Bridging Fibrosis				
Mukewar <i>et al</i> ^[46] , 2017	Case control study	20 patients	11.4(Mean)	88.90%	301/308/170/0.5(M)	8 mo	10% Mild fibrosis but no bridging fibrosis
		16F/4M	55%				
		24-A, 12-P					

T1DM: Type 1 diabetes mellitus; HbA1C: Hemoglobin A1c; AST: Aspartate transferase; ALT: Alanine transferase; ALP: Alkaline phosphatase; T bili: Total bilirubin; M: Male; F: Female; NA: Not available; A: Adults; P: Pediatrics.

blood sugar, but unfortunately, it still exists^[52].

PATHOGENESIS

The hallmark of the GH is severe fluctuation in levels of glucose and administration of supraphysiologic levels of insulin to control the hyperglycemia. While first described in association with recurrent hyper- and hypoglycemia with ketoacidosis in T1DM, it has since been reported without ketosis or acidosis in patients with T2DM and with variable insulin requirements^[3,4,8-16,42]. The excess glycogen accumulation has also been reported in diabetic patients without previous episodes of hypoglycemia^[44,53]. Rapid onset of hyperglycemia causing GH was reported in a case by Murata and colleagues in which the initial Hemoglobin A1C was only 6.2%; however, the patient presented with severe hyperglycemia with ketoacidosis and blood glucose of 1495 mg/dL^[19].

Physiologically, the liver takes up glucose after feeding and either utilizes it for fuel or stores it as glycogen. Stored mainly in the liver and skeletal muscles, glycogen is a polymer of glucose that acts as a reservoir for glucose. The hepatic glycogen level is maintained by the balance between glycogenesis and glycogenolysis. High glucose levels cause an influx of glucose into the hepatocytes *via* facilitated diffusion through the glucose transporter 2 (GLUT2), independent of insulin^[43]. Once the glucose is present within the hepatocytes, the enzyme glucokinase irreversibly phosphorylates glucose to glucose-6-phosphate, trapping it within the hepatocytes (Figure 1). Subsequent treatment of hyperglycemia with the high dose of insulin enhances further conversion of trapped glucose to polymerize into glycogen^[43]. Glucose-6-phosphate is converted to glycogen by the enzyme glycogen synthase, which exists in an active dephosphorylated form and in an inactive

Table 3 Summary of the major case reports in English (PubMed indexed) on Glycogenic hepatopathy in type 2 diabetes mellitus

Ref.	Study design	Age/sex	Type of DM/insulin	A1C	Keto acidosis	Hepatomegaly	AST/ALT/ALP/T bili	normalization fibrosis of LFTs
Olson <i>et al</i> ^[3] , 1989	Case report	39/M	Type 2/insulin	NA	Yes	No	429/764/1882/NA	21 d
Tsujimoto <i>et al</i> ^[47] , 2006	Case report	41/M	Type 2/insulin	10	No	Yes	1064/1024/202/2.3	17 d
Umpaichitra ^[48] , 2016	Case report	15/M	T2DM/metformin	6.5	No	Yes	245/330/N/N	18 mo

T2DM: Type 2 diabetes mellitus; HbA1C: Hemoglobin A1c; AST; Aspartate transferase; ALT: Alanine transferase; ALP: Alkaline phosphatase; T bili: Total bilirubin; M: Male; F: Female; NA: Not available.

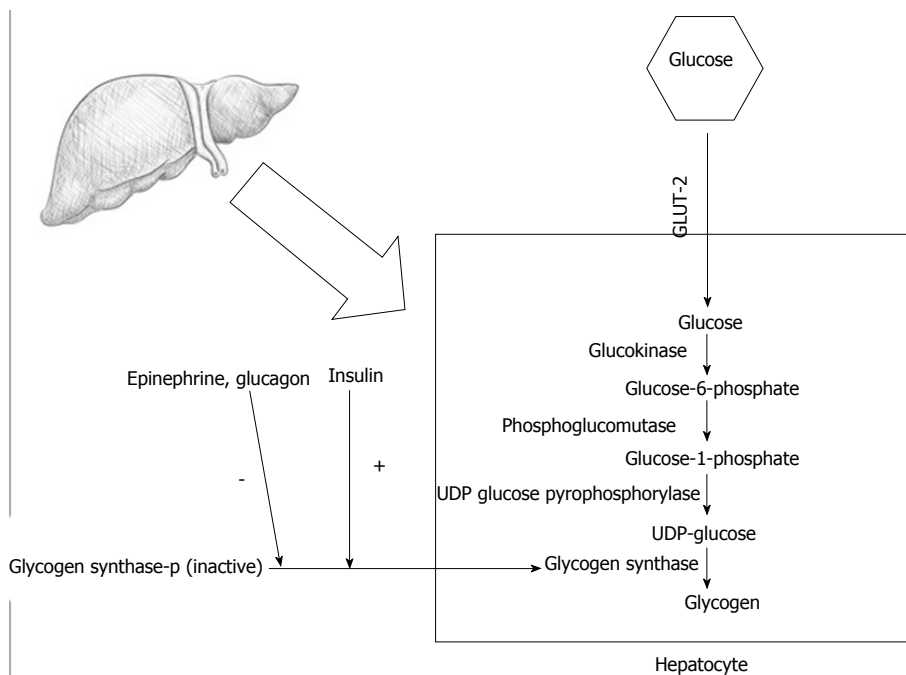


Figure 1 Steps of glycogenesis; effects of hyperglycemia and insulin treatment in glycogenic hepatopathy and formation of glycogen.

phosphorylated form. The active dephosphorylated structure of glycogen synthase is produced by the action of a phosphatase enzyme. The phosphatase enzyme is stimulated by elevated glucose and insulin levels. Glycogen production persists for some time after insulin levels have declined while inhibiting the glycogenolysis^[15]. Hepatomegaly can sometimes develop within days to weeks and can improve rapidly once the hyperglycemia is controlled^[54].

The reason for excessive accumulation of glycogen in hepatocytes with GH in contrast with the reduced glycogen stores observed in diabetes mellitus (DM) patients is unknown. Even more intriguing is why only a small subset of patients with DM develops GH. GH was first reported after short-acting insulins became available for the treatment of DM. Initially when short-acting insulins were used for the treatment of DM, large doses of insulin were required to control hyperglycemia, causing consequent hypoglycemia. This vicious cycle of excessive doses of short-acting insulin and subsequent administration of glucose to counteract the resulting hypoglycemia could have led to the continued accumulation of glycogen in the liver, a proposed

mechanism by various authors^[3,19,54]. These findings are infrequently observed today due to widespread use of long-acting insulin and possibly the decreased frequency of hypoglycemic events in this patient cohort.

Another hypothesis is that there is a defect in the genes that code for the proteins which regulate glycogen synthase or glucose 6-phosphatase activity. Although minor abnormalities have been identified in enzymes that control glycogen metabolism, these changes were not considered enough to explain hepatic glycogen storage in GH in the setting of DM^[4]. A study by MacDonald and colleagues of an adolescent boy with Mauriac syndrome identified a mutation in PHKG2, is the catalytic subunit of glycogen phosphorylase kinase^[55]. Expression of the mutant PHKG2 in a human liver cell line inhibited the enzyme activity of the phosphokinase complex and increased glycogen levels^[55]. The mother of the boy with Mauriac syndrome also had the mutant PHKG2 but did not have diabetes or hepatomegaly. These findings do not explain all the cases of GH in adults, as most cases resolved with optimizing the hyperglycemia. Tomihira and colleagues investigated the gene structure of phosphorylase enzyme to define

Table 4 Summary of the published articles in English (PubMed indexed) on Glycogenic hepatopathy without DM

Ref.	Pathology	Study design	Age/sex	Hepatomegaly	AST/ALT/ALP/ T bili	Normalization	Fibrosis of LFTs
Resnick <i>et al</i> ^[56] , 2011	Dumping syndrome	Case report	2/M	No	NA/199/NA/NA	16 mo	No fibrosis
Kransdorf <i>et al</i> ^[57] , 2015	Anorexia nervosa	Case report	26/F	NA	75/101/108/	NA	No fibrosis
Iancu <i>et al</i> ^[58] , 1986	Steroids use	Retrospective	6 mo-14 yr	Yes	Normal	3-5 d	No fibrosis

AST: Aspartate transferase; ALP: Alanine transferase; ALT: Alkaline phosphatase; T bili: Total bilirubin; M: Male; F: Female; NA: Not available.

possible mutations; however, they could not determine a probable gene defect that might cause hepatic glycogenosis^[53]. Although no direct evidence is available so far, Berman MC hypothesized that the cause of GH is excess glycogen deposits in an intracellular location inaccessible to normal metabolic mechanisms, a phenomenon like that occurring in type II glycogenesis in which glycogen deposits within the lysosomes, rendering them unavailable for phosphorylation activity^[2]. In patients with a classic presentation of Mauriac syndrome, the wide fluctuations between hyper- and hypoglycemia—a pattern suggestive of under- and over-insulinization with secondary hyperadrenalism—possibly caused the cushingoid features. The pathogenesis of growth retardation in those initial cases reported in children was thought to be multifactorial^[52].

The association of ketoacidosis in T1DM and GH not well understood. There could be some mechanisms account for excess deposition of glycogen or failure to mobilize during periods of hypoglycemia. Hormones like adrenaline, cortisol, or growth hormones released due to hypoglycemia, could synergistically act and release large quantities of non-esterified fatty acids from adipose tissue. This high concentration of free fatty acids inhibits glucose oxidation in muscles, and they may have similar effects on liver promoting excess storage of glycogen^[2]. Other theory is that extremely low inorganic serum phosphate level in diabetic ketoacidosis may limit recovery from the acute diabetic state by acting as rate limiting factor for hexokinase and phosphokinase reactions. Depletion of intracellular inorganic phosphate for which there is an absolute requirement may be responsible for limitation of phosphorylase activity. Poorly controlled T1DM patients would be expected to have similar recurrent bouts of hypophosphatemia with the consequent entry of large amounts of glucose and inorganic phosphate into the cells^[2].

GH in T2DM

The exact mechanism of development of GH in T2DM with insulin resistance is poorly understood and has yet to be clarified. Upon review of previously reported cases of GH, most cases were found in patients who were on an insulin regimen for T1DM, except two instances reported in T2DM^[3,47,48] (Table 3). Pathophysiology of GH in T2DM is unclear and could have a different mechanism than that seen in T1DM. Umpaichitra V reported a case of GH in an adolescent male with T2DM whose liver enzymes returned to normal after

treatment with metformin^[48]. In T2DM, metformin is typically the first-line of treatment. The fact that the patient was in the early stages of diabetes and had not decompensated enough to cause total insulin resistance might explain the preserved effect of insulin on glycogenesis^[48]. The mechanism which metformin may have alleviated the glycogenesis, in this case, is also not precise. It was possible that once he was started on metformin, his hepatic gluconeogenesis decreased and glucose uptake in peripheral tissues increased, possibly leading to a paucity of glucose as a substrate for glycogenesis^[48].

OTHER DISORDERS ASSOCIATED WITH GH

Excessive hepatic accumulation of glycogen causing GH occurs not only in patients with DM but also in other conditions, including dumping syndrome after gastrectomy, anorexia nervosa, high-dose glucocorticoid use, azathioprine use, and insulin overdose^[56-58] (Table 4).

Dumping syndrome after gastric bypass

One of the inherent functions of insulin is to stimulate glycogenesis. Hyperglycemia and hyperinsulinemia are thought to be the etiology for hepatic glycogen deposition in dumping syndrome. Dumping syndrome is a complication of gastric surgery, such as gastric bypass surgery. In patients who had gastric surgery, chyme rapidly “dumped” from the stomach into the small bowel without complete digestion. Resnick *et al*^[56] reported a case of a toddler fed *via* gastrostomy tube, who developed GH secondary to Dumping syndrome after Nissen fundoplication. Like GH, it involves fluctuation between hyperglycemia from the rapid nutrition glucose load and hyperinsulinemia. The pathophysiology of Dumping syndrome can resemble that of GH seen in people with diabetes, eventually causing the hepatic accumulation of glycogen.

Anorexia nervos

Anorexia nervos (AN) is characterized by the obsessive fear of gaining weight, distorted body image, and a significantly low body weight. Lisa Kransdorf and colleagues reported a case of anorexia nervosa with glycogen deposition with elevated liver enzymes^[57]. It has been reported that 1 in 10 patients with AN will have abnormal liver enzymes. A series of cases of AN with liver failure was reported by Rautou *et al*^[59]; about

50% of them presented with hypoglycemia. Again, this lack of glycogen deposits supports the hypothesis that hepatic glycogen accumulation is potentially a protective mechanism. Hepatic glycogenosis is thought to be an adaptive response that protects against potentially fatal hypoglycemia in malnutrition. It is essential to be aware of this association when treating patients with AN.

Short-term high dose steroid therapy

Steroids promote elevation in glucose, gluconeogenesis, and glycogen deposition. Current available evidence regarding GH with steroid use was gathered from pediatric patients. Hepatic glycogen deposition has been described in several experimental models. In a study by Iancu *et al.*^[58] 141 patients had received steroid therapy: 13% had hepatomegaly, and three patients were noted to have glycogenic hepatopathy. It is unclear whether they had any elevation in liver enzymes. Hepatomegaly resolved soon after discontinuing the steroid therapy in all patients with hepatomegaly. Several mechanisms were involved in the pathogenesis of GH in steroid use. Following hyperglycemia induced by steroids, increased glycogen deposition occurs by the activation of phosphorylase by glucose and the subsequent activation of glycogen synthase. Glycogen synthase is activated by insulin, which increases following steroid-induced hyperglycemia. The knowledge that the hepatomegaly in patients taking steroids could be GH-related will aid in the management of these patients.

Insulin overdose

Excessive insulin levels associated with exogenous insulin administration augments the glycogen deposition. This is evident from a case reported by Tsujimoto *et al.*^[47] in which a patient with T2DM self-administered a massive dose of long-acting insulin in a suicide attempt. He became hypoglycemic and was later administered a large dose of intravenous glucose to counteract the persistent hypoglycemia. Prior to the suicide attempt, his baseline liver enzymes were initially normal. After the administration of insulin and intravenous glucose the patient developed acute glycogen storage hepatomegaly. His liver enzymes increased significantly to more than 30 times the upper limit of normal.

CLINICOPATHOLOGICAL FEATURES

Clinical manifestations

Clinical presentation of GH varies from asymptomatic patients with elevated liver enzymes to various symptoms associated with hyperglycemia. Patients can present with symptoms of diabetic ketoacidosis (DKA), such as polyuria, polydipsia, marked dehydration, as well as abdominal pain, nausea, or vomiting or may occasionally present with signs of acute hepatitis, jaundice, and pruritus. Pediatric patients may present with extreme hepatomegaly along with growth failure

and delayed puberty. The rapid enlargement of the liver causes stretching of the liver capsule, resulting in visceral pain. Although a few reported cases had normal liver sizes on imaging studies, hepatomegaly was observed in more than 90% of the reported cases, with varying degrees of elevation in transaminases and rarely an elevation in alkaline phosphatase (ALP) level. Excessive glycogen with swollen hepatocytes eventually could cause sinusoidal compression and subsequent ascites^[34]; therefore, ascites can also be a part of the clinical presentation, albeit rarely^[34,44]. Physical examination of patients with GH generally exhibits tender hepatomegaly without splenomegaly.

Biochemical features

Most patients with GH present with hepatocellular abnormality with a predominant elevation in aspartate transaminase (AST) and alanine transaminase (ALT) levels, although a mixed or predominantly cholestatic pattern can rarely occur^[3,11,20,30,44]. For patients not experiencing a DKA episode, laboratory studies may show mild elevations in ALT, AST, and ALP. Marked elevations of transaminases and sometimes in the range of more than 100 folds' increase from normal were reported in several reports, mimicking acute hepatitis^[26]. However, liver synthetic functions were usually preserved. No histological evidence was identified that suggested the increased enzymes were due to liver necrosis. Elevations in liver enzymes were thought to be due to enzyme leakage from hepatocyte membrane injury, not cell death. However, the exact mechanism is unknown. AST elevations were found to be significantly higher than the ALT elevations. Although ischemic hepatitis is the result of hypotension and hypoperfusion, subjects with inadequate perfusion without the hypotension can also produce a significant elevation in transaminases without liver necrosis^[26]. Likewise, patients with DKA will have severe dehydration, which could contribute to these massive elevations in transaminases on top of the GH causing enzyme elevation. In a case-control study by Mukewar *et al.*^[46] analyzing 36 patients with T1DM, more than half of patients with GH had recurrent episodes of DKA, and these patients had higher levels of HbA1c than patients with T1DM without GH. Patients with GH could have elevated levels of plasma lactate, with or without the presence of a DKA episode, although the mechanism is still poorly understood^[35,45]. In a retrospective review by Fitzpatrick of 31 patients with Mauriac syndrome, almost half the patients had elevated lactic acid level despite no signs of DKA^[45]. One of the proposed theories is that a reduction in gluconeogenesis in the liver may raise lactate levels in the body. Therefore, lactic acidosis could be secondary to reduced gluconeogenesis and a lack of conversion of pyruvate to glucose^[35].

The elevation in amylase and lipase levels less than three times the upper limit of normal without the evidence of acute pancreatitis on imaging has been

seen in some patients with GH^[34]. Elevation in these enzymes even in the presence of abdominal pain should not be considered diagnostic of acute pancreatitis, since high levels of amylase and lipase can be seen in patients with DKA without evidence of pancreatitis on CT scan^[34]. Hence in patients with GH, elevations of amylase and lipase less than three times the upper limit of normal may be nonspecific yet present. Additionally, antinuclear antibody was positive in some cases, showing a mostly homogeneous speckled pattern. These may be nonspecific as well, as there were no reports of any associated systemic disease^[18,26,38,41,48].

DIAGNOSIS

Laboratory evaluation

No single serologic test can diagnose GH. Most patients with GH will have elevated transaminases. It is challenging to diagnose GH solely based on clinical features alone, and liver biopsy is crucial for definitive diagnosis. Typically, the increase in liver enzymes is transient and normalizes in a short period ranging from few days to few weeks^[38]. Several laboratory tests may be done initially to rule out other causes of hepatomegaly and chronic hepatitis. Because there is an association between T1DM and autoimmune hepatitis, testing for autoimmune antibodies, such as ANA, anti-smooth muscle antibody and antimitochondrial antibody is essential. The signs and symptoms of Wilson disease often begin during the teenage years and should be ruled out. Glycogen storage diseases (GSDs) are caused by congenital deficiencies in various enzymes and clinically present in the neonatal period or infancy. These patients may already start to present with hypoglycemia and hepatomegaly during infancy^[60]. As expressed by Umpaichitra, glucagon stimulation test in children can be tried to rule out GSD^[48]. As an up-regulator of glycogenolysis and a down-regulator of glycogenesis, glucagon would facilitate the breakdown of glycogen to allow the release of glucose into the bloodstream. Patients who can demonstrate an increase in serum glucose levels after stimulation by glucagon efficiently rule out a glycogen storage disease^[48]. However, the best modality to accurately diagnose a GSD is next-generation genetic sequencing.

Imaging studies

Different imaging studies can be used to support or refute the diagnosis of GH. One of the principal differential diagnoses is NAFLD. In patients with GH, abdominal ultrasound would show hepatomegaly with uniform echogenicity, indicative of glycogen storage, like the fatty change seen in NAFLD. Ultrasound of abdomen is not a useful modality to differentiate NAFLD from GH, as the mildly bright liver can be observed in both. A bright liver compared to the spleen in CT scan imaging can be the clue to diagnosing GH. The liver density on CT scan of the abdomen in patients with GH is increased (hyper dense), compared to a patient

with NAFLD in whom it is decreased (hypodense); this subtle difference can give a clue to GH, as reported by Sweetser^[11].

Neither CT abdomen nor liver US is a useful test for the definitive diagnosis of GH; however, gradient dual-echo MRI sequence was reported to be able to distinguish fat deposition from an edematous condition such as acute tissue injury; both of which appears as low-density areas on CT. MRI imaging in GH shows low intensities on T2 weighted images. Gradient dual-echo MRI is a powerful tool to distinguish GH from NAFLD. T1 weighted gradient-dual-echo MRI images with in-phase and opposed-phase conditions could efficiently differentiate hepatic glycogen from the fat seen in NAFLD^[11,22]. If there is no significant difference in the signal intensities between the two phases then the results are not consistent with intrahepatic fat storage (NAFLD) and are more consistent with GH^[19,22] (Figure 2). A few recent reports have shown the presence of varying degrees of fibrosis in patients with GH^[45,46]. Presence or absence of liver fibrosis in GH patients can be measured using noninvasive tests such as Fibroscan. Magnetic resonance elastography may have a role in evaluating the degree of fibrosis with GH and needs further studies. Several authors have also demonstrated elevated hepatic glycogen concentration in subjects with glycogen storage disease using 13C MRS (Magnetic Resonance Spectroscopy), which has the advantage of assessing the entire liver while avoiding the risks of liver biopsy^[61]. However, these tests may not yet be readily available in most centers.

Liver biopsy and Histological features

A liver biopsy typically shows swollen hepatocytes with an accumulation of glycogen in the cytoplasm. Associated steatosis may be mild to absent in most cases. Although some authors recommended the therapeutic trial of intensive insulin therapy for four weeks preceding any invasive investigations, liver biopsy is the gold standard for diagnosing GH. A hematoxylin and eosin (HE) stain of the biopsy specimen in a patient with GH would show pale and enlarged hepatocytes with prominent plasma membranes, increased cytoplasmic volume, and numerous glycogenated nuclei, which are empty nuclei with ring-like chromatin elements (Figures 3 and 4). Sinusoidal compression by the swollen hepatocytes can produce a paved appearance to the liver parenchyma. The architectural structure of the liver parenchyma likewise remains intact. Furthermore, an addition of diastase to the Periodic-Acid Schiff (PAS) stained specimen would cause enzymatic breakdown of glycogen in the hepatocytes, causing these hepatocytes to turn into "ghost cells"^[41] (Figure 4). Histological examination of hepatocytes from patients with GH normally does not exhibit significant portal inflammation, steatosis, or significant fibrosis. In fact, only a minority of cases reported had fibrosis, which was minimal except two cases reported by Fitzpatrick and colleague showed bridging fibrosis^[44-46]. In a review

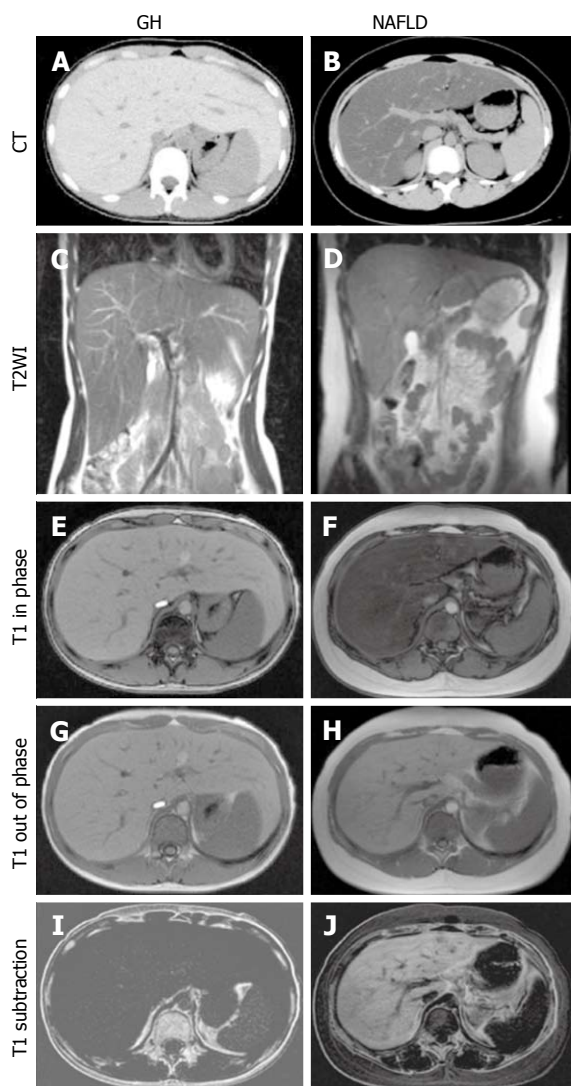


Figure 2 Computed tomography (CT) and magnetic resonance imaging (MRI) of (A, C, E, G, I) glycogenic hepatopathy (GH) in a 13-year-old girl and (B, D, F, H, J) non-alcoholic fatty liver disease (NAFLD) in a 13-year-old boy. On CT, GH was (A) high density, but NAFLD was typically (B) low density; On T2-weighted imaging (T2WI), both enlarged livers were (C) 19.1 cm and (D) 16.8 cm along the right midclavicular line; On gradient dual-echo MRI, the GH liver was iso-intense between the (E) in-phase and (G) out-of-phase images, namely; I: Low intensity on subtraction. The NAFLD liver, however, had low intensity on the (F) in-phase image, and high intensity on the (H) out-of-phase image, namely; J: High intensity on subtraction. With permission from Saikusa *et al*^[22], John Wiley and Sons publications.

of cases of GH by Torbenson *et al*^[44], mild steatosis was noted in 14% of cases, mild steatohepatitis in 7% of cases, and mild fibrosis in 14% of cases with GH. Histopathology of a case reported by Shah *et al*^[41], also showed GH with focal portal tract fibrosis. Future studies warranted to further assess for development of fibrosis in GH as it can progress to cirrhosis.

DIFFERENTIAL DIAGNOSIS

For patients with DM who present with hepatomegaly and elevated transaminase levels, there are several differential diagnoses apart from glycogenic

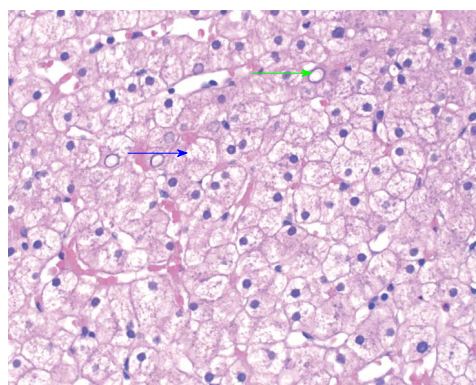


Figure 3 Percutaneous liver biopsy section of a patient with glycogenic hepatopathy. HE stain showing enlarged hepatocytes with cytoplasmic pallor with reddish pink globules consistent with glycogen accumulation (blue arrow), and prominent glycogenated nuclei (green arrow).

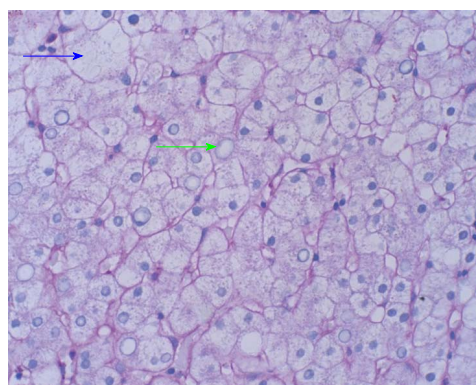


Figure 4 D-Periodic-Acid Schiff stain remove glycogen leaving empty looking cytoplasm (blue arrow) and nuclei (green arrow).

hepatopathy, including NAFLD. Among T2DM patients, hepatic enlargement with elevated transaminases is usually the result of NAFLD, while GH is the most likely pathology in patients with T1DM^[25]. Other potential causes of liver damage in people with diabetes include celiac disease and autoimmune hepatitis. Hepatitis A, Hepatitis B, Hepatitis C, hemochromatosis, and Wilson’s disease should all be considered in the list of differential diagnoses, depending on extent and pattern of liver abnormality on presentation (Table 5).

NAFLD

The most common etiology for elevated live enzymes in general population including patients with DM is NAFLD. NAFLD is more typically found in obese adults with T2DM secondary to insulin resistance, while GH is more common in patients with lower body mass index and pediatric patients. Upon assessment of laboratory studies from a patient with NAFLD, steatohepatitis would show mild elevations in AST, ALT, and ALP, just like in most cases of GH. CT scan imaging of a patient with NAFLD would show hepatomegaly with decreased liver density, while the gradient-dual-echo MRI would show low intensity in phase and high

Table 5 Summary of the main differential diagnosis for glycogenic hepatopathy

	Main etiology	Clinical presentation	Imaging characteristics	Key, liver biopsy pathological features	Diagnosis	Management	Cirrhosis
GH	Acquired excessive glycogen deposition in the liver mostly seen in patients with T1DM	Hyperglycemia with hyperglycemic symptoms; could be asymptomatic. Liver enzyme elevation is mild to extreme range in some case	US and CT shows increased echogenicity. Dual-Echo MRI; iso-intense between the in-phase and out-of-phase images, and low intensity on subtraction	Glycogen deposition in the cytoplasm with swollen hepatocytes, with or without mild steatosis and fibrosis. Diastase digestion of glycogen cause hepatocytes to turn into “ghost cells”	Radiologic and liver biopsy	Optimal control of DM	May have mild fibrosis, severe fibrosis is very rare and seen in only a few reported cases
GSD	Inborn errors of glucose and glycogen metabolism results in abnormal deposition of glycogen	Presentation varies depend on types of GSDs They will have manifestations of a liver, kidney, and skeletal muscle involvement with hypoglycemia, hepatomegaly, muscle cramps, and weakness, <i>etc</i>	Like GH	Findings vary in different type of GSDs; Nonspecific histologic findings to PAS positive glycogen deposition which could be diastase sensitive or resistant	Biochemical tests and molecular testing	Symptomatic treatment to dietary changes to maintain the blood glucose level and pharmacologic therapy in different types of GSDs. May need liver transplantation in selected cases	Some GSD can progress to cirrhosis
NAFLD	Hepatic steatosis	Most patients asymptomatic and some may have minor symptoms, Liver enzymes elevation usually < 5 times upper limit of normal	US and CT shows increased echogenicity. Dual-Echo MRI; low intensity on the in-phase image, and high intensity on the out-of-phase image and high intensity on subtraction.	Steatosis with or without lobular inflammation and hepatocyte ballooning. May have varying degrees of fibrosis	Radiologic and liver biopsy	Lifestyle modification and pharmacologic therapies. May need liver transplant in advanced cirrhosis	Can progress to cirrhosis
Hepatosclerosis	Is a hepatic manifestation of microangiopathic disease seen in long-standing DM	Often clinically silent, Serum aminotransferases are normal or minimally elevated. ALP, Total bilirubin may be elevated	No specific imaging characteristics	Extensive dense perisinusoidal fibrosis	Liver biopsy	Unknown	Unknown
AIH	Chronic Hepatitis of unknown etiology	Spectrum of clinical manifestations ranges from asymptomatic patients to those with considerable symptoms, and rarely presents with acute liver failure	No characteristic imaging features, may show cirrhotic liver in advance case	Interface hepatitis and portal lymphoplasmacytic infiltrate with varying degree of fibrosis	Characteristic biochemical tests and liver biopsy	Glucocorticoid monotherapy or in combination with immunomodulators. Rarely may require liver transplantation	Can progress to cirrhosis
Hemochromatosis	Autosomal recessive disorder. Mutations cause increased iron absorption and excessive deposition in the liver, heart, pancreas, and pituitary	Asymptomatic or chronic liver disease with elevated transaminases, skin pigmentation, DM, arthropathy, impotence and cardiac enlargement, <i>etc</i>	MRI is most sensitive and can estimate iron concentration in the liver. Dual-Echo MRI; demonstrates decreased signal intensity in the affected tissues on the in-phase images compared with the out-of-phase images (opposite of steatosis)	A liver biopsy will reveal iron overload. Presence of cirrhosis can be determined	Biochemical tests including genetic testing, radiologic, and liver biopsy	Phlebotomy or Chelation therapy if unable to tolerate phlebotomy	Can progress to cirrhosis

Wilson disease	Autosomal recessive disorder with impaired cellular copper transport and impaired biliary copper excretion results in accumulation of copper most notably the liver, brain, and cornea.	Predominantly hepatic, neurologic, and psychiatric manifestations. Elevated transaminases mild to moderate and ALP may be markedly subnormal	US, CT, may show signs of cirrhosis and normal caudate lobe which is contrary to other types cirrhosis	Vary largely from fatty changes to cirrhosis and occasionally fulminant hepatic necrosis. Can be stained for copper	Biochemical tests and slit lamp examination with or without genetic testing and liver biopsy	Treatment with a chelating agent. Some cases may require liver transplantation	Can progress to cirrhosis
Acute viral hepatitis A, B, C, D and E. Rarely, HSV, VZ, EBV and CMV	Hepatitis A and E are transmitted by feco-oral route; Rest of the viruses spread either by sexual contact, contact with body fluids or blood or from birth from an infected mother	Many of the symptoms are nonspecific; May have marked elevation in transaminases often > 15 times the normal	US or CT findings are nonspecific; Could be used to rule out other causes	Liver biopsy shows hepatocyte necrosis with a portal, periportal and lobular lymphocytic infiltration; Plasma cells present during resolving phase	Diagnosis by biochemical tests	Treatment conservative or antiviral therapy	Acute infection may progress to chronic, and that may progress to cirrhosis

PAS: Periodic-acid Schiff; T1DM: Type 1 diabetes mellitus; US: Ultrasound; CT: Computed tomography; GH: Glycogenic hepatopathy; GSD: Glycogen storage disease; NAFLD: Non-alcoholic fatty liver disease; AIH: Auto immune hepatitis; DM: Diabetes mellitus; ALP: Alkaline phosphatase; HSV: Herpes simplex virus; VZ: Varicella zoster virus; CMV; Cytomegalovirus.

intensity out of phase^[22]. Histological examination of a liver biopsy specimen from a patient with NAFLD could likewise show macro vesicular steatosis, mild lobular and portal inflammation, and varying degrees of fibrosis. Evidence of hepatocellular injury and fibrosis would indicate increased severity and progression to actual steatohepatitis. NAFLD is likewise more likely to progress to fibrosis, cirrhosis and or hepatocellular carcinoma. Because of the potential for progressive liver disease and liver failure in NAFLD, it is crucial to distinguish NAFLD from GH, generally considered a more benign and reversible condition.

Hepatosclerosis

Hepatosclerosis is an underrecognized form of hepatic diabetic microangiopathy that needs to be differentiated from GH. It occurs in patients with T1DM more often than in T2DM and is associated with severe microvascular disease in other organs. Hepatosclerosis is characterized by an indolent course and is seen predominantly in female diabetic patients, although actual prevalence of this remains unknown. Generally, ALP is elevated with or without an elevation in total bilirubin, and serum aminotransferase levels may be normal or minimally elevated^[62]. Liver biopsy may show extensive, dense, perisinusoidal fibrosis, and immunostaining reveals basement membrane components in a perisinusoidally distribution^[62]. It is unclear whether hepatosclerosis plays any role in pathogenesis of NAFLD or cirrhosis in patients with DM. Long-term follow-up and future studies are required to examine the natural history and to explore treatment options for this form of microvascular complication involving the liver.

GSD

GSD is a group of inherited disorders in which excess glycogen accumulates in different tissues including liver, skeletal muscles, or both due to the deficiency of enzymes that regulate glycogenolysis or gluconeogenesis. Glycogen accumulation is not only caused by mutations in enzymes directly involved with glycogen catabolism or glucose metabolism, but it can also be caused by mutations in proteins that have an indirect impact on glycogen metabolism. It is vital to differentiate GH and GSDs with genetic testing, as management would vary vastly between the two pathologies. The hepatocytes in both conditions are markedly swollen and filled with glycogen, while the subtle difference can be the presence of higher cytoplasmic clumping of glycogen in GSD^[44]. A clinical parameter such as the response to diabetic control in patients with poorly controlled DM is an important component to distinguish GH from GSD^[44]. Management for GSDs revolves around management of complex carbohydrate intake and surveillance for complications, whereas management for GH centers on proper glycemic control with insulin and prevention of hyperglycemic episodes.

Drug induced liver injury and GH

Should a diabetic patient be on additional medications and the course of management be complicated by continued elevations in transaminases despite fluid resuscitation and treatment with insulin, it would be wise to drug induced liver injury (DILI) along with associated GH. Maharaj *et al*^[39] published the case of a patient who initially presented with DKA, hepatomegaly, and elevated transaminases but was later diagnosed

with GH accompanied by DILI. He had a past medical history of T1DM and bipolar disorder that was being treated with the antipsychotic drugs paliperidone and asenapine. The author recommended DILI as a possibility whenever GH is suspected with concomitant use of hepatotoxic medications.

MANAGEMENT, PROGNOSIS AND FOLLOW UP

Once the diagnosis is made, improved glycemic control is the mainstay of management. Although there has not yet been any research in support of any pharmacological treatment strictly targeting or preventing glycogen deposits in the liver, it is regarded that resolution of the hyperglycemia would cause a decrease in transaminases level back to normal. GH can resolve with both clinical and biochemical resolution as quickly as it develops within days to weeks with good glycemic control^[40]. Due to the autoimmune destruction of beta-islet cells in the pancreas, type 1 diabetics are unable to secrete endogenous insulin inherently. As such, exogenous insulin therapy is necessary to maintain their serum glucose levels. The mainstay of treatment for GH is strict control of glucose levels, close supervision of Hemoglobin A1C and prevention of recurrence of episodes of DKA. Prognosis with improved glycemic control is excellent. Reversal of GH has also been reported following pancreatic transplantation in people with diabetes, further consolidating the fact that it is entirely reversible by treating the diabetes^[18].

Pathology results of majority of the cases reported in the literature did not show any significant fibrosis of the liver; however, further long-term studies are required to assess for the consequence of the mild fibrosis identified in some reports, and few cases of bridging fibrosis as severe fibrosis may further progress to cirrhosis. Despite showing a benign clinical course with strict glycemic control, GH could recur and relapse with uncontrolled glycemic levels^[38]. Therefore, patients with a history of GH may still need to be followed up for any relapse of symptoms if persistent control of hyperglycemia is not maintained.

CONCLUSION

In conclusion, GH should be one of the differential diagnoses upon examination of a patient with uncontrolled DM presenting with elevated transaminases and hepatomegaly. GH should not be overlooked as a differential diagnosis solely due to its underrepresentation in diabetic patients. Compared to other liver diseases associated with DM, GH is a favorable diagnosis due to its benign nature and good prognosis.

Future progress is required in understanding the biochemical defects underlying GH and development of fibrosis. Further research is needed for an ideal

noninvasive, rapid diagnostic test to avoid the extensive workup and associated costs in evaluating suspected cases of GH. For now, a more aggressive pursuit of liver biopsy in the evaluation of elevated transaminases could identify additional cases of GH, allowing for continued elucidation of prevalence and natural history of this entity. Clinicians should also continue to pool patient data from case studies of patients with GH, to better understand the underlying risk factors and characteristics of this disease.

ACKNOWLEDGEMENTS

The authors acknowledge John Wiley and Sons publications for providing the images.

REFERENCES

- 1 **Ruschhaupt DG**, Rennert OM. Recurrent hepatomegaly and transient alteration of liver functions in an adolescent with diabetic acidosis. *Clin Pediatr (Phila)* 1970; **9**: 122-124 [PMID: 4984319 DOI: 10.1177/000992287000900223]
- 2 **Berman MC**. Hepatic glycogen storage during uncontrolled diabetes mellitus. A case report. *S Afr Med J* 1973; **47**: 184-186 [PMID: 4684248]
- 3 **Olsson R**, Wesslau C, William-Olsson T, Zettergren L. Elevated aminotransferases and alkaline phosphatases in unstable diabetes mellitus without ketoacidosis or hypoglycemia. *J Clin Gastroenterol* 1989; **11**: 541-545 [PMID: 2507626]
- 4 **Munns CF**, McCrossin RB, Thomsett MJ, Batch J. Hepatic glycogenesis: reversible hepatomegaly in type 1 diabetes. *J Paediatr Child Health* 2000; **36**: 449-452 [PMID: 11036799]
- 5 **Fridell JA**, Saxena R, Chalasani NP, Goggins WC, Powelson JA, Cummings OW. Complete reversal of glycogen hepatopathy with pancreas transplantation: two cases. *Transplantation* 2007; **83**: 84-86 [PMID: 17220798 DOI: 10.1097/01.tp.0000239510.27872.07]
- 6 **Cuthbertson DJ**, Brennan G, Walsh S, Henry E. Hepatic glycogenesis: abnormal liver function tests in Type 1 diabetes. *Diabet Med* 2007; **24**: 322-323 [PMID: 17305792 DOI: 10.1111/j.1464-5491.2007]
- 7 **Sayuk GS**, Elwing JE, Lisker-Melman M. Hepatic glycogenesis: an underrecognized source of abnormal liver function tests? *Dig Dis Sci* 2007; **52**: 936-938 [PMID: 17342391 DOI: 10.1007/s10620-006-9430-8]
- 8 **Bassett JT**, Veerappan GR, Lee DH. Glycogenic hepatopathy: a rare cause of increased aminotransferase levels in a diabetic patient. *Clin Gastroenterol Hepatol* 2008; **6**: A26 [PMID: 18691943 DOI: 10.1016/j.cgh.2008.04.034]
- 9 **Abaci A**, Bekem O, Unuvar T, Ozer E, Bober E, Arslan N, Ozturk Y, Buyukgebiz A. Hepatic glycogenesis: a rare cause of hepatomegaly in Type 1 diabetes mellitus. *J Diabetes Complications* 2008; **22**: 325-328 [PMID: 18413182 DOI: 10.1016/j.jdiacomp.2007.11.002]
- 10 **Hudacko RM**, Manoukian AV, Schneider SH, Fyfe B. Clinical resolution of glycogenic hepatopathy following improved glycemic control. *J Diabetes Complications* 2008; **22**: 329-330 [PMID: 18413180 DOI: 10.1016/j.jdiacomp.2007.11.004]
- 11 **Sweetser S**, Kraichely RE. The bright liver of glycogenic hepatopathy. *Hepatology* 2010; **51**: 711-712 [PMID: 19957373 DOI: 10.1002/hep.23402]
- 12 **van den Brand M**, Elving LD, Drenth JP, van Krieken JH. Glycogenic hepatopathy: a rare cause of elevated serum transaminases in diabetes mellitus. *Neth J Med* 2009; **67**: 394-396 [PMID: 20009116]
- 13 **Saxena P**, Turner I, McIndoe R. Education and Imaging. Hepatobiliary and pancreatic: Glycogenic hepatopathy: a reversible condition. *J Gastroenterol Hepatol* 2010; **25**: 646 [PMID:

- 20370736 DOI: 10.1111/j.1440-1746.2010.06178.]
- 14 **Bua J**, Marchetti F, Faleschini E, Ventura A, Bussani R. Hepatic glycogenosis in an adolescent with diabetes. *J Pediatr* 2010; **157**: 1042 [PMID: 20638077 DOI: 10.1016/j.jpeds.2010.06.018]
 - 15 **Aljabri KS**, Bokhari SA, Fageeh SM, Alharbi AM, Abaza MA. Glycogen hepatopathy in a 13-year-old male with type 1 diabetes. *Ann Saudi Med* 2011; **31**: 424-427 [PMID: 21727748]
 - 16 **Dantuluri S**, Karthik V, Stahlschmidt J, Davison S. Glycogenic hepatopathy. *J Pediatr Gastroenterol Nutr* 2012; **54**: 307 [PMID: 21975962 DOI: 10.1097/MPG.0b013e31823972bb]
 - 17 **Lin YC**, Kao CH. Glycogenic hepatopathy in type 1 diabetes mellitus. *Liver Int* 2012; **32**: 1294 [PMID: 22731940 DOI: 10.1111/j.1478-3231.2012.]
 - 18 **Messeri S**, Messerini L, Vizzutti F, Laffi G, Marra F. Glycogenic hepatopathy associated with type 1 diabetes mellitus as a cause of recurrent liver damage. *Ann Hepatol* 2012; **11**: 554-558 [PMID: 22700639]
 - 19 **Murata F**, Horie I, Ando T, Isomoto E, Hayashi H, Akazawa S, Ueki I, Nakamura K, Kobayashi M, Kuwahara H, Abiru N, Kawasaki E, Yamasaki H, Kawakami A. A case of glycogenic hepatopathy developed in a patient with new-onset fulminant type 1 diabetes: the role of image modalities in diagnosing hepatic glycogen deposition including gradient-dual-echo MRI. *Endocr J* 2012; **59**: 669-676 [PMID: 22673296]
 - 20 **Cha JH**, Ra SH, Park YM, Ji YK, Lee JH, Park SY, Baik SK, Kwon SO, Cho MY, Kim MY. Three cases of glycogenic hepatopathy mimicking acute and relapsing hepatitis in type 1 diabetes mellitus. *Clin Mol Hepatol* 2013; **19**: 421-425 [PMID: 24459648 DOI: 10.3350/cmh.2013.19.4.421]
 - 21 **Saadi T**. Glycogenic hepatopathy: a rare disease that can appear and resolve rapidly in parallel with glycemic control. *Isr Med Assoc J* 2012; **14**: 269-270 [PMID: 22675850]
 - 22 **Saikusa M**, Yatsuga S, Tonan T, Koga Y. Glycogenic hepatopathy and non-alcoholic fatty liver disease in type 1 diabetes patients. *Pediatr Int* 2013; **55**: 806-807 [PMID: 24330296 DOI: 10.1111/ped.12235]
 - 23 **Imtiaz KE**, Healy C, Sharif S, Drake I, Awan F, Riley J, Karlson F. Glycogenic hepatopathy in type 1 diabetes: an underrecognized condition. *Diabetes Care* 2013; **36**: e6-e7 [PMID: 23264308 DOI: 10.2337/dc12-1134]
 - 24 **Butts GT**, Hairston FJ, Bishop PR, Nowicki MJ. Massive hepatomegaly in poorly controlled insulin-dependent diabetes mellitus. *J Pediatr* 2014; **164**: 214-214.e1 [PMID: 24070830 DOI: 10.1016/j.jpeds.2013.08.027]
 - 25 **Jeong YJ**, Kang B, Choi SY, Ki CS, Lee SY, Park HD, Choe YH. Does type 1 truly dominate hepatic glycogen storage diseases in Korea?: a single center study. *Pediatr Gastroenterol Hepatol Nutr* 2014; **17**: 239-247 [PMID: 25587524 DOI: 10.5223/ghn.2014.17.4.239]
 - 26 **Martin J**, Tomlinson P. Hepatic complications in poorly controlled type 1 diabetes mellitus: a case report. *N Z Med J* 2014; **127**: 95-97 [PMID: 24806252]
 - 27 **Parmar N**, Atiq M, Austin L, Miller RA, Smyrk T, Ahmed K. Glycogenic Hepatopathy: Thinking Outside the Box. *Case Rep Gastroenterol* 2015; **9**: 221-226 [PMID: 26269698 DOI: 10.1159/000437048]
 - 28 **Xu J**, Dhall D, Sundaram V. An enlarging liver in a young diabetic male. *Gastroenterology* 2015; **149**: e8-e10 [PMID: 26433109 DOI: 10.1053/j.gastro.2015.02.024]
 - 29 **García-Suárez C**, Álvarez Suárez B, Castro Ortiz E, González Soler R, Dacal Rivas A, Martí Marques E, Tardáguila García D, Lancho Seco Á, González Ramírez A, Santos Blanco E, Ávila Nasi S, López Rosés L. Glycogenic hepatopathy: a rare and reversible cause of elevated transaminases in diabetic patients. Case report. *Rev Esp Enferm Dig* 2015; **107**: 111-112 [PMID: 25659393]
 - 30 **Atmaca M**, Ucler R, Kartal M, Seven I, Alay M, Bayram I, Olmez S. Glycogenic Hepatopathy in Type 1 Diabetes Mellitus. *Case Reports Hepatol* 2015; **2015**: 236143 [PMID: 26347835 DOI: 10.1155/2015/236143]
 - 31 **Irani NR**, Venugopal K, Kontorinis N, Lee M, Sinniah R, Bates TR. Glycogenic hepatopathy is an under-recognized cause of hepatomegaly and elevated liver transaminases in type 1 diabetes mellitus. *Intern Med J* 2015; **45**: 777-779 [PMID: 26134697 DOI: 10.1111/imj.12807]
 - 32 **Brouwers MC**, Ham JC, Wisse E, Misra S, Landewe S, Rosenthal M, Patel D, Oliver N, Bilo HJ, Murphy E. Elevated lactate levels in patients with poorly regulated type 1 diabetes and glycogenic hepatopathy: a new feature of Mauriac syndrome. *Diabetes Care* 2015; **38**: e11-e12 [PMID: 25614691 DOI: 10.2337/dc14-2205]
 - 33 **Chandrasekaran V**, Baineni R, Rangan S. Mauriac Syndrome in the Age of Newer Insulin Analogues. *J Pediatr Care* 2015; **1**: 1 [DOI: 10.21767/2471-805X.100003]
 - 34 **Silva M**, Marques M, Cardoso H, Rodrigues S, Andrade P, Peixoto A, Pardal J, Lopes J, Carneiro F, Macedo G. Glycogenic hepatopathy in young adults: a case series. *Rev Esp Enferm Dig* 2016; **108**: 673-676 [PMID: 26900767 DOI: 10.17235/reed.2016.3934/2015]
 - 35 **Deemer KS**, Alvarez GF. A Rare Case of Persistent Lactic Acidosis in the ICU: Glycogenic Hepatopathy and Mauriac Syndrome. *Case Rep Crit Care* 2016; **2016**: 6072909 [PMID: 27699071 DOI: 10.1155/2016/6072909]
 - 36 **Diego Gaytan-Saracho**, Luz Elena Mejía-Carmona and Leticia Margarita García-Morales. Mauriac Syndrome: A Rare Complication of Poorly Controlled Diabetes Mellitus. Abstract, Endocrine Society's 98th Annual Meeting and Expo, April 1-4, 2016, Boston
 - 37 **Chandel A**, Scarpato B, Camacho J, McFarland M, Mok S. Glycogenic Hepatopathy: Resolution with Minimal Glucose Control. *Case Reports Hepatol* 2017; **2017**: 7651387 [PMID: 28529811 DOI: 10.1155/2017/7651387]
 - 38 **Ikarashi Y**, Kogiso T, Hashimoto E, Yamamoto K, Kodama K, Taniai M, Torii N, Takaie H, Uchigata Y, Tokushige K. Four cases of type 1 diabetes mellitus showing sharp serum transaminase increases and hepatomegaly due to glycogenic hepatopathy. *Hepatol Res* 2017; **47**: E201-E209 [PMID: 27027269 DOI: 10.1111/hepr.12713]
 - 39 **Maharaj V**, Fitz M, Ding X. Drug-Induced Liver Injury in the Setting of Glycogenic Hepatopathy. *J Gen Intern Med* 2017; **32**: 714-717 [PMID: 28224373 DOI: 10.1007/s11606-017-3996-z]
 - 40 **Al Sarkhy AA**, Zaidi ZA, Babiker AM. Glycogenic hepatopathy, an underdiagnosed cause of relapsing hepatitis in uncontrolled type 1 diabetes mellitus. *Saudi Med J* 2017; **38**: 89-92 [PMID: 28042636 DOI: 10.15537/smj.2017.1.15934]
 - 41 **Shah ND**, Sasatomi E, Baron TH. Acute and Relapsing Hepatitis Caused by Glycogenic Hepatopathy. *Clin Gastroenterol Hepatol* 2017; **15**: A23-A24 [PMID: 28189697 DOI: 10.1016/j.cgh.2017.02.004]
 - 42 **Ilham Mohammed Omer**. Mauriac Syndrome: a diagnosis that still exists. *Acad J Ped Neonatol* 2017; **3** Suppl 1: AJPN. MS.ID.555647
 - 43 **Chatila R**, West AB. Hepatomegaly and abnormal liver tests due to glycogenosis in adults with diabetes. *Medicine (Baltimore)* 1996; **75**: 327-333 [PMID: 8982149]
 - 44 **Torbenson M**, Chen YY, Brunt E, Cummings OW, Gottfried M, Jakate S, Liu YC, Yeh MM, Ferrell L. Glycogenic hepatopathy: an underrecognized hepatic complication of diabetes mellitus. *Am J Surg Pathol* 2006; **30**: 508-513 [PMID: 16625098]
 - 45 **Fitzpatrick E**, Cotoi C, Quaglia A, Sakellariou S, Ford-Adams ME, Hadzic N. Hepatopathy of Mauriac syndrome: a retrospective review from a tertiary liver centre. *Arch Dis Child* 2014; **99**: 354-357 [PMID: 24412980 DOI: 10.1136/archdischild-2013-304426]
 - 46 **Mukewar S**, Sharma A, Lackore KA, Enders FT, Torbenson MS, Kamath PS, Roberts LR, Kudva YC. Clinical, Biochemical, and Histopathology Features of Patients With Glycogenic Hepatopathy. *Clin Gastroenterol Hepatol* 2017; **15**: 927-933 [PMID: 28043933 DOI: 10.1016/j.cgh.2016.11.038]
 - 47 **Tsujimoto T**, Takano M, Nishiofuku M, Yoshiji H, Matsumura Y, Kuriyama S, Uemura M, Okamoto S, Fukui H. Rapid onset of glycogen storage hepatomegaly in a type-2 diabetic patient after

- a massive dose of long-acting insulin and large doses of glucose. *Intern Med* 2006; **45**: 469-473 [PMID: 16679704]
- 48 **Umpaichitra V.** Unusual glycogenic hepatopathy causing abnormal liver enzymes in a morbidly obese adolescent with well-controlled type 2 diabetes: resolved after A1c was normalized by metformin. *Clin Obes* 2016; **6**: 281-284 [PMID: 27400632 DOI: 10.1111/cob.12154]
- 49 **Clark JM,** Brancati FL, Diehl AM. The prevalence and etiology of elevated aminotransferase levels in the United States. *Am J Gastroenterol* 2003; **98**: 960-967 [PMID: 12809815 DOI: 10.1111/j.1572-0241.2003.]
- 50 **Daniel S,** Ben-Menachem T, Vasudevan G, Ma CK, Blumenkehl M. Prospective evaluation of unexplained chronic liver transaminase abnormalities in asymptomatic and symptomatic patients. *Am J Gastroenterol* 1999; **94**: 3010-3014 [PMID: 10520861 DOI: 10.1111/j.1572-0241.1999.]
- 51 **Al-Hussaini AA,** Sulaiman NM, Alzahrani MD, Alenizi AS, Khan M. Prevalence of hepatopathy in type 1 diabetic children. *BMC Pediatr* 2012; **12**: 160 [PMID: 23039762 DOI: 10.1186/1471-2431-12-160]
- 52 **Gutch M,** Philip R, Saran S, Tyagi R, Gupta KK. Re-emergence of a rare syndrome: A case of mauriac syndrome. *Indian J Endocrinol Metab* 2013; **17**: S283-S285 [PMID: 24251187 DOI: 10.4103/2230-8210.119611]
- 53 **Tomihira M,** Kawasaki E, Nakajima H, Imamura Y, Sato Y, Sata M, Kage M, Sugie H, Nunoi K. Intermittent and recurrent hepatomegaly due to glycogen storage in a patient with type 1 diabetes: genetic analysis of the liver glycogen phosphorylase gene (PYGL). *Diabetes Res Clin Pract* 2004; **65**: 175-182 [PMID: 15223230 DOI: 10.1016/j.diabres.2003.12.004]
- 54 **Stone BG,** Van Thiel DH. Diabetes mellitus and the liver. *Semin Liver Dis* 1985; **5**: 8-28 [PMID: 3885402 DOI: 10.1055/s-2008-1041754]
- 55 **MacDonald MJ,** Hasan NM, Ansari IH, Longacre MJ, Kendrick MA, Stoker SW (2016). "Discovery of a genetic metabolic cause for Mauriac syndrome in type 1 diabetes". *Diabetes* 2016; **65**: 2051-2059 [PMID: 27207549 DOI: 10.2337/db16-0099]
- 56 **Resnick JM,** Zador I, Fish DL. Dumping syndrome, a cause of acquired glycogenic hepatopathy. *Pediatr Dev Pathol* 2011; **14**: 318-321 [PMID: 21338321 DOI: 10.2350/10-07-0876-CR.1]
- 57 **Kransdorf LN,** Millstine D, Smith ML, Aqel BA. Hepatic glycogen deposition in a patient with anorexia nervosa and persistently abnormal transaminase levels. *Clin Res Hepatol Gastroenterol* 2016; **40**: e15-e18 [PMID: 26066296 DOI: 10.1016/j.clinre.2015.05.001]
- 58 **Iancu TC,** Shiloh H, Dembo L. Hepatomegaly following short-term high-dose steroid therapy. *J Pediatr Gastroenterol Nutr* 1986; **5**: 41-46 [PMID: 3944744]
- 59 **Rautou PE,** Cazals-Hatem D, Moreau R, Francoz C, Feldmann G, Lebre C, Ogier-Denis E, Bedossa P, Valla D, Durand F. Acute liver cell damage in patients with anorexia nervosa: a possible role of starvation-induced hepatocyte autophagy. *Gastroenterology* 2008; **135**: 840-848, 848.e1-848.e3 [PMID: 18644371 DOI: 10.1053/j.gastro.2008.05.055]
- 60 **Burda P,** Hochuli M. Hepatic glycogen storage disorders: what have we learned in recent years? *Curr Opin Clin Nutr Metab Care* 2015; **18**: 415-421 [PMID: 26001652 DOI: 10.1097/MCO.0000000000000181]
- 61 **Roser W,** Beckmann N, Wiesmann U, Seelig J. Absolute quantification of the hepatic glycogen content in a patient with glycogen storage disease by ¹³C magnetic resonance spectroscopy. *Magn Reson Imaging* 1996; **14**: 1217-1220 [PMID: 9065913]
- 62 **Harrison SA,** Brunt EM, Goodman ZD, Di Bisceglie AM. Diabetic hepatosclerosis: diabetic microangiopathy of the liver. *Arch Pathol Lab Med* 2006; **130**: 27-32 [PMID: 16390234 DOI: 10.1043/1543-2165(2006)130[27:DHDMDOT]2.0.CO;2]

P- Reviewer: Dinc M, Duan ZJ, Hudacko R, Katuchova J, Liu DY, Saisho Y, Savopoulos CG

S- Editor: Cui LJ **L- Editor:** A **E- Editor:** Li D





Published by **Baishideng Publishing Group Inc**
7901 Stoneridge Drive, Suite 501, Pleasanton, CA 94588, USA
Telephone: +1-925-223-8242
Fax: +1-925-223-8243
E-mail: bpgoffice@wjgnet.com
Help Desk: <http://www.f6publishing.com/helpdesk>
<http://www.wjgnet.com>

