



# Plug-Assisted Retrograde Transvenous Obliteration for the Treatment of Gastric Varices: The Role of Intra-Procedural Cone-Beam Computed Tomography

Dong Il Gwon, MD, Gi-Young Ko, MD, Young Baek Kwon, RT, Hyun-Ki Yoon, MD, Kyu-Bo Sung, MD

All authors: Department of Radiology and Research Institute of Radiology, University of Ulsan College of Medicine, Asan Medical Center, Seoul 05505, Korea

**Objective:** To investigate the technical and clinical outcomes of plug-assisted retrograde transvenous obliteration (PARTO) for the treatment of gastric varices (GV) and to evaluate the role of intra-procedural cone-beam computed tomography (CBCT) performed during PARTO to confirm its technical success.

**Materials and Methods:** From January 2016 to December 2016, 17 patients with GV who had undergone PARTO were retrospectively evaluated. When the proximal part of the afferent vein was identified on a fluoroscopy, non-contrast CBCT images were obtained. In patients with incomplete embolization of GV, an additional injection of gelatin sponges was performed. Follow-up data from contrast-enhanced CT and upper intestinal endoscopy, as well as clinical and laboratory data were collected.

**Results:** Plug-assisted retrograde transvenous obliteration procedures were technically successful in all 17 patients. Complete embolization of GV was detected on CBCT images in 15 patients; whereas, incomplete embolization was detected in two. Complete embolization of GV was then achieved after an additional injection of gelatin sponges in these two patients as demonstrated on the 2nd CBCT image. The mean follow-up period after PARTO was 193 days (range, 73–383 days). A follow-up CT obtained 2–4 months after PARTO demonstrated marked shrinkage or complete obliteration of GV and portosystemic shunts in all 17 patients. There were no cases of variceal bleeding during the follow-up.

**Conclusion:** Plug-assisted retrograde transvenous obliteration is technically and clinically effective for the treatment of GV. In addition, intra-procedural CBCT can be an adjunct tool to fluoroscopy, because it can provide an immediate and accurate evaluation of the technical success of PARTO.

**Keywords:** *Vascular plug; Gastric varices; Plug-assisted retrograde transvenous obliteration (PARTO); Cone-beam computed tomography (CBCT)*

## INTRODUCTION

Bleeding from gastroesophageal varices is a major

Received June 21, 2017; accepted after revision August 7, 2017.

**Corresponding author:** Dong Il Gwon, MD, Department of Radiology and Research Institute of Radiology, University of Ulsan College of Medicine, Asan Medical Center, 88 Olympic-ro 43-gil, Songpa-gu, Seoul 05505, Korea.

• Tel: (822) 3010-5665 • Fax: (822) 476-0090

• E-mail: radgwon@amc.seoul.kr

This is an Open Access article distributed under the terms of the Creative Commons Attribution Non-Commercial License (<http://creativecommons.org/licenses/by-nc/4.0>) which permits unrestricted non-commercial use, distribution, and reproduction in any medium, provided the original work is properly cited.

complication that can cause death in patients with portal hypertension due to liver cirrhosis (1). Although the incidence of bleeding from gastric varices (GV) is rarer than that from esophageal varices, the outcome is more likely to be fatal for ruptured GV because they cause greater blood loss and have higher re-bleeding rates. Indeed, mortality rates of approximately 55% have been reported for bleeding of GV (1-3).

Balloon-occluded retrograde transvenous obliteration (BROTO) has been shown to be a suitable therapeutic option for the control of GV (4-15). Recently, plug-assisted retrograde transvenous obliteration (PARTO) was proposed and reported, where a balloon occlusion catheter and

sclerosants were replaced with a vascular plug/coil and a gelatin sponge to minimize some of the complications and logistical issues associated with balloon catheters and sclerosants (16-19). Previous studies of PARTO have demonstrated that important factors for the obliteration of GV and shunts are complete thrombosis of the GV and portosystemic shunt immediately after PARTO and permanent embolization of the shunt (16, 17). Therefore, the complete filling of gelatin sponges in the entire variceal complex is essential for a successful PARTO. Currently, there are no angiographic protocols for evaluating the endpoint of a gelatin sponge injection during the PARTO procedure. In previous studies of PARTO, the endpoint was determined by visualization of the GV, shunt, veins, and its collaterals that was guided by fluoroscopy images only. However, it can be sometimes very difficult to determine the proper endpoint of a gelatin sponge injection using fluoroscopic guidance especially in cases with a complex venous anatomy or large GV and shunt.

In recent years, the availability of intra-procedural cone-beam computed tomography (CBCT) has revolutionized problem solving during a variety of procedures including transcatheter arterial chemoembolization, BRTO, modified BRTO, and others (20-24). CBCT generates substantially more information than fluoroscopy because the image delineates the exact location of the embolized veins and varices and its relationship to surrounding soft-tissue structures. In addition, CBCT provides CT-like cross-sectional and three-dimensional (3D) images that can be obtained during the procedure. Thus, the purposes of this study were to examine the technical and clinical outcomes of PARTO for the treatment of GV and to evaluate the role of intra-procedural CBCT performed during PARTO to confirm its technical success.

## MATERIALS AND METHODS

### Patient Population

This study was approved by the Institutional Review Board of our institution and written informed consent was waived because of its retrospective nature. From January 2016 to December 2016, 17 patients with GV who had undergone PARTO were retrospectively evaluated. Ten patients had GV in danger of rupture, four had experienced recent bleeding, and three had active variceal bleeding. GV showing marked protrusion or red spots and progressive enlargement within a 6-month period as seen by an endoscopy were judged to

**Table 1. Patient Characteristics**

Patient demographics	
Male:female	15:2
Age, years (range)	61 (46–87)
Underlying liver disease (%)	
HBV LC	8 (47)
Alcoholic LC	8 (47)
HCV LC	1 (6)
Concomitant malignancy (%)	
HCC	6 (35)
Child-Pugh classification	
A	8
B	7
C	2

HBV = hepatitis B virus, HCC = hepatocellular carcinoma, HCV = hepatitis C virus, LC = liver cirrhosis

be in danger of rupturing. The baseline demographic and clinical characteristics of the 17 patients are presented in Table 1.

### Technique

Prior to undergoing PARTO, contrast-enhanced CT scans of the abdomen were obtained for all patients and they confirmed the presence of a portosystemic shunt. Briefly, the right common femoral vein was punctured initially, after which a 6- or 7-F sheath (Flexor Check-Flo sheath; Cook, Bloomington, IN, USA) was inserted. When insertion of a sheath into the portosystemic shunt was not possible through the right common femoral vein due to an acute angle, the right internal jugular vein was accessed. After negotiation of the left adrenal vein or shunt using a 0.035-inch, 180-cm-long hydrophilic guide wire (Terumo, Tokyo, Japan) and a 4-F angled-tip catheter (Cobra; Terumo), the sheath was then inserted into the shunt. The type II vascular plug (AGA medical, Golden valley, MN, USA) was deployed at the most dilated portion of the shunt. The size of the vascular plug was chosen based on the diameter of the narrowest shunt, as measured by the CT scans. The plugs ranged in size from 8–20 mm in diameter or were 20% larger than the targeted shunt so as to prevent migration and gelatin sponge reflux. The shunt proximal to the vascular plug was then negotiated using the guide wire and the 4-F angled-tip catheter between the vascular plug and the shunt wall. The vascular plug was then pulled down to the narrowest part of the shunt while maintaining the position of the catheter. An additional embolization was then performed using a mixture of diluted contrast medium (normal saline: contrast medium = 0.5–1:1) and gelatin

sponges (ranging in size from approximately 1 mm<sup>3</sup> to 8 mm<sup>3</sup>) through the catheter in order to embolize the shunt, efferent veins, afferent veins, and GV.

When the proximal part of the afferent vein was identified on a fluoroscopy, non-contrast CBCT images were performed according to the protocol described below in order to evaluate the embolized area in detail. For patients with incomplete embolization of GV after meticulous comparison between the axial images of the pre-PARTO contrast-enhanced axial CT and non-contrast CBCT, additional gelatin sponges were injected into GV. Once the complete embolization of GV, efferent veins, and afferent veins was confirmed by a non-contrast CBCT image, a retrograde venography was performed through the sheath in order to confirm the occlusion of the shunt. The catheter was subsequently removed, and the delivery cable attached to the end of the vascular plug was then detached. Fluoroscopic time was measured from the point of sheath insertion after the puncture of the common femoral vein to the time of the retrograde venography and the detachment of the delivery cable of the vascular plug.

#### **Intra-Procedural Cone-Beam CT**

All patients underwent non-contrast CBCT immediately after a gelatin sponge injection. All CBCT images were acquired under 7 seconds with a flat-panel detector angiographic system (AXIOM Artis Zee; Siemens, Erlangen, Germany) using the following parameters: total scanning angle, 200°; rotation speed, 30°/s; total of 396 projections (30 frames per second), matrix size, 512 × 512; isotropic voxel size, 0.49 mm; and effective field of view, 382 × 296 mm<sup>2</sup>. The raw data sets were transferred to an external workstation (Syngo VX91C, Siemens), where images were reconstructed to 3D volumetric images.

#### **Follow-Up**

Patients were evaluated by contrast-enhanced CT during their hospital admission within three days after PARTO in order to evaluate thrombosis of GV and the portosystemic shunt. Subsequently, an upper gastrointestinal endoscopy or CT was performed at the discretion of the referring physician. Follow-up clinical data were collected from all 17 patients' medical records or from the electronic patient information data. Information regarding their current status or death was obtained by telephone from all patients or their families.

## **RESULTS**

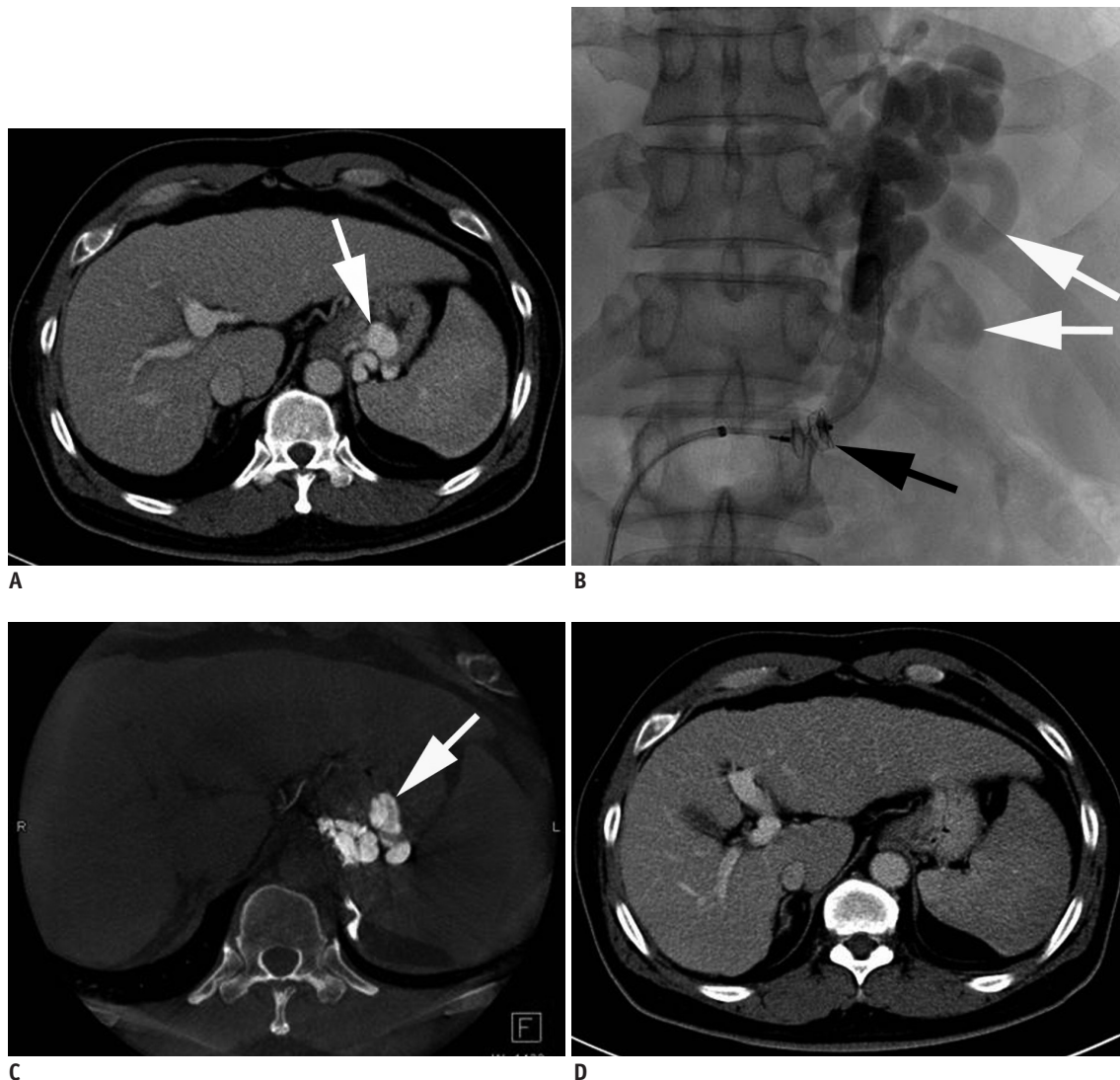
#### **Technical Outcomes**

The transfemoral approach was used in 16 patients and the transjugular approach was applied in one patient. A PARTO was successful technically in all 17 patients (Fig. 1). A total of 19 vascular plug IIs was used in 17 patients (i.e., 8 mm diameter [n = 7], 10 mm [n = 5], 12 mm [n = 6], and 14 mm [n = 1]). A single vascular plug II was sufficient to occlude the efferent shunt in 15 patients and two vascular plugs were used to occlude the two dominant efferent shunts in one patient. In the remaining patient, the vascular plug migrated into the renal vein during the gelatin sponge injection. Some gelatin sponges migrated into the inferior vena cava; however, this patient did not have any respiratory symptoms or signs. We then exchanged it with a 2 mm larger vascular plug and successfully placed it into the left adrenal vein and performed PARTO.

Subsequent injection of gelatin sponges (mean, 3.7 sheets; range, 2–8) through the 4-F catheter was technically successful in all patients. During embolization, all 17 patients demonstrated single or multiple collateral veins. These collaterals were sufficiently occluded with an injection of gelatin sponges in 16 patients. An additional embolization of one dominant collateral vein was performed in one patient using two microcoils. In two patients, a minimal degree of contrast leakage into the retroperitoneal space appeared around the shunt while performing a gelatin sponge injection. Therefore, an additional injection of gelatin sponges was performed after the catheter advanced into a more proximal portion of the shunt. The mean fluoroscopic time was 27 minutes and range was 13–47 minutes.

#### **The Role of CBCT in Determining Technical Success**

All non-contrast CBCT images accurately determined whether to continue or stop injecting gelatin sponges. The complete embolization of GV was detected on the CBCT images in 15 patients; whereas incomplete embolization of the GV was detected in two patients. Those two patients required an additional injection of gelatin sponges and a repeat CBCT to confirm that the gelatin sponges completely filled the area. A complete embolization of GV was then achieved in these two patients as demonstrated by the 2nd CBCT image (Fig. 2). In two unstable patients, although motion artifacts on respiration degraded images were used, there were no difficulties comparing pre-PARTO CT and CBCT images.



**Fig. 1.** 52-year-old man with GV.

**A.** Contrast-enhanced CT image obtained before PARTO shows GV (white arrow). **B.** After vascular plug (black arrow) placement in narrowest portion of portosystemic shunt via left adrenal vein, additional embolization of splenorenal shunt, GV, and afferent vein (white arrows) from splenic vein was performed using gelatin sponges through 4-F catheter. **C.** Non-contrast CBCT image obtained immediately after injection of gelatin sponges showed complete embolization of GV (white arrow). **D.** Contrast-enhanced CT image obtained three months after PARTO showed complete obliteration of GV. CBCT = cone-beam computed tomography, GV = gastric varices, PARTO = plug-assisted retrograde transvenous obliteration

### Complications

A fever occurred in five patients within 24 hours after the procedure. Among the five patients, one had a fever without elevated leukocyte counts and responded to antipyretic medication only. Her body temperature was normalized the next day. Four patients had a fever with elevated leukocyte counts. They responded to antibiotics and antipyretic medications and their body temperature and leukocyte counts were normalized within 4 days.

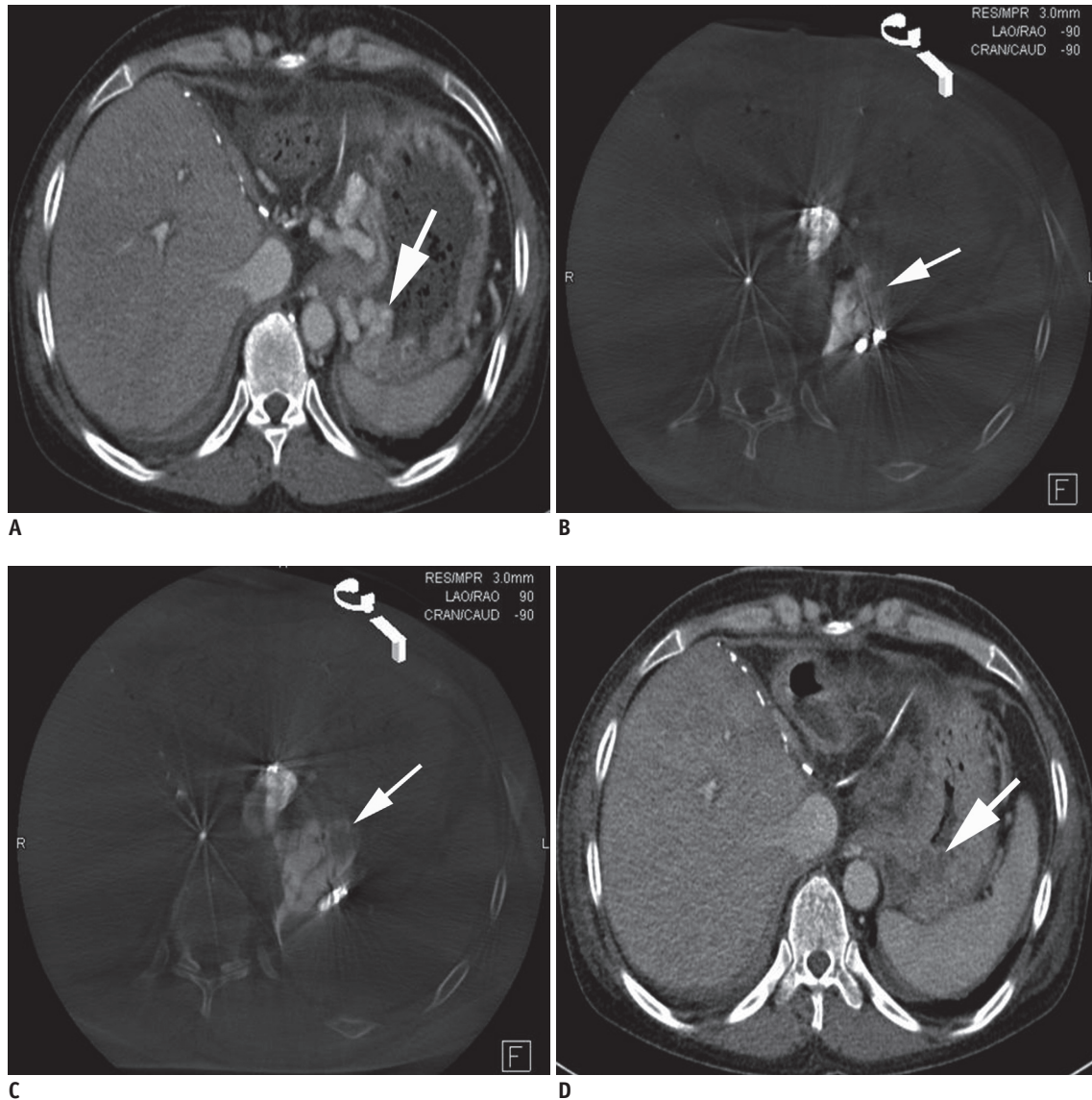
### Clinical Outcomes

Follow-up CTs obtained within 3 days after PARTO

showed complete thrombosis of the treated GV and the portosystemic shunts in 15 patients. In two patients, a small residual intamural GV (less than 10% of the entire pre-procedural GV volume) was demonstrated; however, these residual varices were completely thrombosed at a one-month follow-up CT.

All 17 patients remained alive and were being clinically followed until the end of the study period on February 28, 2017. The mean follow-up period after PARTO was 193 days (range, 73–383 days). Follow-up CT scans obtained 2–4 months after PARTO demonstrated marked shrinkage or complete obliteration of GV and the portosystemic shunts





**Fig. 2. 48-year-old woman with GV.**

**A.** Contrast-enhanced CT image obtained before PARTO shows GV (arrow). **B.** Non-contrast CBCT image obtained immediately after injection of gelatin sponges showed incomplete embolization of GV (arrow). **C.** Second non-contrast CBCT image obtained immediately after additional injection of gelatin sponges shows complete embolization of GV (arrow). **D.** Contrast-enhanced CT image obtained one day after PARTO shows complete thrombosis of GV (arrow).

in all 17 patients. There were no cases of variceal bleeding during the follow-up. A follow-up endoscopy was performed in all 17 patients. The endoscopy results revealed marked shrinkage or disappearance of GV.

Ascites newly developed in 2 (11.8%) of the 17 patients who did not have ascites prior to PARTO, and ascites progressed to a larger amount in 1 (5.9%) patient who had ascites prior to PARTO. Three (17.6%) patients experienced a worsening of their esophageal varices. One of the three patients with worsening esophageal varices was successfully treated endoscopically. The other two patients who had

small esophageal varices did not undergo prophylactic endoscopic treatment.

## DISCUSSION

Balloon-occluded retrograde transvenous obliteration has a high efficacy in stopping acute gastric variceal bleeding and has shown to have a significantly lower re-bleeding rate of GV compared to transjugular intrahepatic portosystemic shunts or endoscopic treatments (10-15). However, the obliteration of the large shunts and GV is challenging with

the BRT0 procedure due to the large dose of sclerosants that is used (5, 7). The risk of complications is well documented and is especially dependent on the volume of the sclerosants used, which can make their use inappropriate in these large shunts and GV. Moreover, to prevent sclerosant-related complications caused by excess sclerosants, repeat BRT0 procedures should be required in order to achieve a complete thrombosis of GV (5, 7, 25). Previous studies have shown that 10–44% of patients required a second or third BRT0 procedure to completely obliterate GV (4-15). These repeated BRT0 procedures are considered burdensome for patients and result in longer hospitalization. However, in the PARTO procedure, embolization of these large shunts and GV using a gelatin sponge was technically feasible and safe because gelatin sponges are composed of a safer embolic material than other sclerosants (16-19).

Therefore, a complete filling of the gelatin sponge in the entire variceal complex is essential for a successful PARTO. CBCT is performed after the gelatin sponge injection, and can differentiate between soft tissue and the embolized lesion. When used to compare with pre-procedural contrast-enhanced CT scans, non-contrast CBCT images can easily define the extent of embolization in the shunt and GV. Moreover, to determine the endpoint of the gelatin sponge injection, an intra-procedural CBCT had several advantages in practice compared with fluoroscopy. Assessing the filling of the gelatin sponge in GV at the time of the PARTO allowed for intra-procedural feedback regarding the injection endpoint. In addition, CBCT was superior to fluoroscopy in identifying the unfilled varices and veins. Therefore, to avoid missed opportunities due to an incomplete variceal filling, a CBCT is necessary immediately after a gelatin sponge injection, especially in cases with complex variceal anatomy. In cases with large varices and a shunt, it is sometimes very difficult to determine the proper endpoint of the gelatin sponge injection because the contrast media can be diluted by pure blood from the large afferent vein. Therefore, by immediately assessing the PARTO procedure to confirm the embolization of GV while the patient is still in the procedure room, we can evaluate the success of PARTO and determine whether another gelatin sponge injection is needed in one single session. In the present study, intra-procedural non-contrast CBCT images demonstrated an incomplete embolization of GV compared with the pre-procedural contrast-enhanced CT in two patients. Another injection of the gelatin sponge was performed and a repeat CBCT confirmed the complete embolization of GV. Therefore,

PARTO becomes more feasible due to the development of CBCT which enables us to perform PARTO more completely in the entire variceal complex by providing detailed information.

In the present study, we found that the technical success rate (100%) was aligned with the results of previous BRT0 and modified BRT0 studies. The mean fluoroscopic time was 27 minutes and ranged from 13 minutes to 47 minutes. The reported technical success rates of BRT0 and modified BRT0 ranged from 79.6% to 100% (4-19, 24, 26). We believe this technical success can be further improved using an intra-procedural CBCT. The utility of the CBCT in conventional and modified BRT0 has been described in several studies (20-24). In these studies, investigators concluded that CBCT can provide enough information to either terminate or continue the procedure. Moreover, CBCT can help assess the immediate progress and potentially predict the outcomes of the procedure. In the present study, we also found that there was a complete thrombosis of the GV and the portosystemic shunt in all 17 patients within 3 days after PARTO and marked shrinkage or complete obliteration of GV and the portosystemic shunt in all 17 patients 2–4 months after PARTO. Therefore, the intra-procedural determination of the technical success of PARTO correlated with the clinical success of PARTO, which resulted in the immediate cessation of variceal bleeding or no recurrent bleeding during the follow-up period.

The present study was a retrospective design with a relatively small number of patients and involved some inherent flaws. Prospective, randomized, comparative trials with a large number of patients and a long follow-up period are necessary.

In conclusion, PARTO is a technically and clinically effective treatment for GV. In addition, an intra-procedural CBCT can be an adjunct tool to fluoroscopy, because it can provide immediate and accurate assessment of the technical success of PARTO.

## REFERENCES

1. de Franchis R, Primignani M. Natural history of portal hypertension in patients with cirrhosis. *Clin Liver Dis* 2001;5:645-663
2. Trudeau W, Prindiville T. Endoscopic injection sclerosis in bleeding gastric varices. *Gastrointest Endosc* 1986;32:264-268
3. Sarin SK, Lahoti D, Saxena SP, Murthy NS, Makwana UK. Prevalence, classification and natural history of gastric varices: a long-term follow-up study in 568 portal

- hypertension patients. *Hepatology* 1992;16:1343-1349
4. Kanagawa H, Mima S, Kouyama H, Gotoh K, Uchida T, Okuda K. Treatment of gastric fundal varices by balloon-occluded retrograde transvenous obliteration. *J Gastroenterol Hepatol* 1996;11:51-58
  5. Chikamori F, Kuniyoshi N, Shibuya S, Takase Y. Eight years of experience with transjugular retrograde obliteration for gastric varices with gastrosplenic shunts. *Surgery* 2001;129:414-420
  6. Fukuda T, Hirota S, Sugimura K. Long-term results of balloon-occluded retrograde transvenous obliteration for the treatment of gastric varices and hepatic encephalopathy. *J Vasc Interv Radiol* 2001;12:327-336
  7. Cho SK, Shin SW, Lee IH, Do YS, Choo SW, Park KB, et al. Balloon-occluded retrograde transvenous obliteration of gastric varices: outcomes and complications in 49 patients. *AJR Am J Roentgenol* 2007;189:W365-W372
  8. Choi SY, Won JY, Kim KA, Lee DY, Lee KH. Foam sclerotherapy using polidocanol for balloon-occluded retrograde transvenous obliteration (BROTO). *Eur Radiol* 2011;21:122-129
  9. Chang IS, Park SW, Kwon SY, Choe WH, Cheon YK, Shim CS, et al. Efficacy and safety of balloon-occluded retrograde transvenous obliteration with sodium tetradecyl sulfate liquid sclerotherapy. *Korean J Radiol* 2016;17:224-229
  10. Ninoi T, Nishida N, Kaminou T, Sakai Y, Kitayama T, Hamuro M, et al. Balloon-occluded retrograde transvenous obliteration of gastric varices with gastrosplenic shunt: long-term follow-up in 78 patients. *AJR Am J Roentgenol* 2005;184:1340-1346
  11. Kim SK, Lee KA, Sauk S, Korenblat K. Comparison of transjugular intrahepatic portosystemic shunt with covered stent and balloon-occluded retrograde transvenous obliteration in managing isolated gastric varices. *Korean J Radiol* 2017;18:345-354
  12. Akahoshi T, Hashizume M, Tomikawa M, Kawanaka H, Yamaguchi S, Konishi K, et al. Long-term results of balloon-occluded retrograde transvenous obliteration for gastric variceal bleeding and risky gastric varices: a 10-year experience. *J Gastroenterol Hepatol* 2008;23:1702-1709
  13. Sabri SS, Swee W, Turba UC, Saad WE, Park AW, Al-Osaimi AM, et al. Bleeding gastric varices obliteration with balloon-occluded retrograde transvenous obliteration using sodium tetradecyl sulfate foam. *J Vasc Interv Radiol* 2011;22:309-316; quiz 316
  14. Kim MY, Um SH, Baik SK, Seo YS, Park SY, Lee JI, et al. Clinical features and outcomes of gastric variceal bleeding: retrospective Korean multicenter data. *Clin Mol Hepatol* 2013;19:36-44
  15. Imai Y, Nakazawa M, Ando S, Sugawara K, Mochida S. Long-term outcome of 154 patients receiving balloon-occluded retrograde transvenous obliteration for gastric fundal varices. *J Gastroenterol Hepatol* 2016;31:1844-1850
  16. Gwon DI, Ko GY, Yoon HK, Sung KB, Kim JH, Shin JH, et al. Gastric varices and hepatic encephalopathy: treatment with vascular plug and gelatin sponge-assisted retrograde transvenous obliteration--a primary report. *Radiology* 2013;268:281-287
  17. Gwon DI, Kim YH, Ko GY, Kim JW, Ko HK, Kim JH, et al. Vascular plug-assisted retrograde transvenous obliteration for the treatment of gastric varices and hepatic encephalopathy: a prospective multicenter study. *J Vasc Interv Radiol* 2015;26:1589-1595
  18. Kim T, Yang H, Lee CK, Kim GB. Vascular plug assisted retrograde transvenous obliteration (PARTO) for gastric varix bleeding patients in the emergent clinical setting. *Yonsei Med J* 2016;57:973-979
  19. Chang MY, Kim MD, Kim T, Shin W, Shin M, Kim GM, et al. Plug-assisted retrograde transvenous obliteration for the treatment of gastric variceal hemorrhage. *Korean J Radiol* 2016;17:230-238
  20. Deschamps F, Solomon SB, Thornton RH, Rao P, Hakime A, Kuoch V, et al. Computed analysis of three-dimensional cone-beam computed tomography angiography for determination of tumor-feeding vessels during chemoembolization of liver tumor: a pilot study. *Cardiovasc Intervent Radiol* 2010;33:1235-1242
  21. Hirota S, Nakao N, Yamamoto S, Kobayashi K, Maeda H, Ishikura R, et al. Cone-beam CT with flat-panel-detector digital angiography system: early experience in abdominal interventional procedures. *Cardiovasc Intervent Radiol* 2006;29:1034-1038
  22. Koizumi J, Hashimoto T, Myojin K, Fukushima T, Ichikawa T, Kagawa T, et al. C-arm CT-guided foam sclerotherapy for the treatment of gastric varices. *J Vasc Interv Radiol* 2010;21:1583-1587
  23. Yamagami T, Yoshimatsu R, Miura H, Tanaka O, Yasui K, Yagi N, et al. Usefulness of cone-beam computed tomography during balloon-occluded retrograde transvenous obliteration. *Minim Invasive Ther Allied Technol* 2013;22:359-363
  24. Lee EW, So N, Chapman R, McWilliams JP, Loh CT, Busuttill RW, et al. Usefulness of intra-procedural cone-beam computed tomography in modified balloon-occluded retrograde transvenous obliteration of gastric varices. *World J Radiol* 2016;8:390-396
  25. Hashizume M, Kitano S, Yamaga H, Sugimachi K. Haptoglobin to protect against renal damage from ethanolamine oleate sclerosant. *Lancet* 1988;2:340-341
  26. Lee EW, Saab S, Gomes AS, Busuttill R, McWilliams J, Durazo F, et al. Coil-assisted retrograde transvenous obliteration (CARTO) for the treatment of portal hypertensive variceal bleeding: preliminary results. *Clin Transl Gastroenterol* 2014;5:e61