

Evaluation of the patient with pleural effusion

Stéphane Beaudoin MD, Anne V. Gonzalez MD MSc

■ Cite as: *CMAJ* 2018 March 12;190:E291-5. doi: 10.1503/cmaj.170420

Evaluation of the patient with pleural effusion is challenging, because the differential diagnosis is broad and includes both benign and life-threatening conditions. Moreover, the invasive and noninvasive tests required to make an etiological diagnosis may not be readily available in a primary care setting, and patients may require symptomatic management before the cause of the effusion is identified. Despite the challenges inherent to different settings, an organized approach to diagnosis and treatment is necessary to orient care adequately. The evidence-based guideline for the evaluation of unilateral pleural effusions published in 2010 by the British Thoracic Society is useful.¹ However, there is a paucity of data to guide decision-making in many areas. This article provides a pragmatic approach to the evaluation of a patient with pleural effusion, based on the evidence gathered with the approach outlined in Box 1.

What causes pleural effusion and how do patients present?

Excess fluid accumulation in the pleural space can be caused by both benign and serious conditions. The widely accepted separation of effusions into transudates and exudates is convenient (Box 2). A transudate occurs when systemic factors influencing formation and absorption of pleural fluid (hydrostatic and oncotic pressures) are altered so that fluid accumulates.² An example is the effusion from heart failure. An exudate occurs when pleural surfaces or adjacent lung show increased vascular permeability,² (e.g., because of pleural malignant growth). For transudates, no specific investigation is necessary; management should focus on the mechanism causing fluid accumulation, such as treating the underlying heart failure. For exudates, more investigations are usually required to identify the cause and guide specific therapy, because there are many serious causes. The frequency of each type of effusion depends on the clinical setting, but large series have shown that cancer, heart failure and parapneumonic infections account for most cases.³ Although symptoms specific to the underlying cause may be present, pleural effusions usually present with nonspecific symptoms such as dyspnea, cough and chest pain (dull or pleuritic in nature); the severity of these symptoms depends on effusion size and the patient's cardiopulmonary reserve.

KEY POINTS

- Gathering of initial clinical data guided by the differential diagnosis can orient care by identifying patients in need of urgent evaluation and by highlighting possible etiologies.
- The initial assessment of the patient with a pleural effusion should include an ultrasonography-guided thoracentesis to categorize the effusion as a transudate or an exudate, and obtain specimens for microbiology and cytology.
- If a parapneumonic effusion is suspected, a diagnostic aspiration must be promptly performed to identify patients with a complicated effusion that requires drainage.
- Because the initial assessment with a thoracentesis and a computed tomographic scan cannot rule out malignant disease or tuberculosis, a pleural biopsy is indicated for recurrent, undiagnosed exudative effusions.

What is the approach to a patient with pleural effusion?

Information gathered on history and physical examination can identify those patients who require urgent referral for specialist evaluation and prompt effusion drainage. We suggest that any of the following should prompt an urgent evaluation: recent trauma, respiratory distress or hypoxemia, fever or purulent sputum, and symptoms or signs suggestive of venous thromboembolic disease. A patient's degree of dyspnea, comorbidities, the size of the effusion (a very large or rapidly expanding effusion requires a more rapid assessment) and the suspected diagnosis should otherwise guide the speed of evaluation. Suggested criteria for referral to a specialist can be found in Box 3.

History

The patient's history will inform the working differential diagnosis. It should include a review of medications, risk factors for tuberculosis (TB) and identify symptoms suggestive of respiratory infection, malignant disease and autoimmune diseases, as well as heart, liver and renal diseases. A thorough occupational history, with specific questioning about asbestos exposure, is important: even minimal exposure to asbestos can cause mesothelioma, which will occur several decades later.⁴ Asbestos exposure can also cause a benign reactive effusion, which can be differentiated from mesothelioma only with a pleural biopsy.

Box 1: Evidence used in this review

We reviewed existing guidelines on pleural effusion. For questions regarding the use of various tests of pleural fluid for effusion characterization, we searched Medline from earliest date available to March 2017 using terms such as “pleural effusion” and “Light’s criteria” or “biochemical tests.” We repeated the search for other components of the review, such as the use of ultrasonography, computed tomography, positron emission tomography, cultures of pleural fluid, cytology and tuberculosis. We considered both original articles and relevant reviews, and we examined their reference lists to identify additional pertinent articles. In many areas, randomized controlled trials were lacking or were small in size and conducted in a single centre.

Box 2: Differential diagnosis of pleural effusion

Transudate

- Congestive heart failure
- Cirrhosis
- Nephrotic syndrome
- Urinothorax
- Hypothyroidism
- Hypoalbuminemia
- Cerebrospinal fluid leak

Exudate

- Malignant disease: carcinoma of any origin but especially lung and breast; lymphoma; mesothelioma
- Infections: parapneumonic effusion; tuberculous pleurisy; fungal, parasitic or viral infections
- Autoimmune inflammatory diseases: systemic lupus erythematosus and other connective tissue diseases; rheumatoid arthritis
- Pulmonary embolism
- Intra-abdominal processes: pancreatitis; subphrenic/hepatic abscess
- Drugs: amiodarone, dasatinib, methotrexate, nitrofurantoin and others
- Miscellaneous: benign asbestos reactive effusion; traumatic hemothorax; chylothorax and pseudochylothorax; postcardiac bypass surgery; post-cardiac injury syndrome (Dressler syndrome); postradiation therapy; familial Mediterranean fever

*This is a nonexhaustive list; only the most commonly encountered causes are listed. The relative frequency of each depends on the clinical setting. A more exhaustive list can be found in the article by Light.²

Box 3: When to refer patients with pleural effusion to a respirologist (suggested criteria)

- An undiagnosed effusion after initial assessment and thoracentesis
- A parapneumonic effusion, especially if it is complicated
- A proven or suspected malignant effusion and symptom palliation is required
- Recurrent effusions of any etiology
- An effusion in the outpatient primary care setting where basic investigations may not be accessible

Obtaining a sample of fluid

The goal of the initial evaluation is to establish whether an exudate is present or not and alleviate dyspnea if present. Because clinical judgment is inferior to biochemical parameters to classify effusions,⁵ initial assessment should include a thoracentesis, which can also be therapeutic to alleviate dyspnea (suggested analyses in Table 1). Based on a small randomized controlled trial⁷ and a well-conducted 2010 systematic review and meta-analysis,⁸ the British Thoracic Society guideline recommends performing thoracentesis with guidance by ultrasonography to reduce the rate of pneumothorax and dry aspiration.¹ In the systematic review, risk of pneumothorax was 9.3% without and 4% with ultrasonography guidance.⁸ Minimal fluid depths of 10 mm⁹ to 15 mm¹⁰ have been recommended as safe thresholds for aspiration, but no comparative data exists.

Ultrasonography cannot reliably distinguish exudates from transudates because their characteristics substantially overlap. For example, although an anechoic ultrasonography pattern is encountered in most transudates, one-third of exudates may also have an anechoic appearance based on small single-centre series.^{11,12}

A detailed discussion of the periprocedural management of antiplatelet therapy, anticoagulation and abnormal coagulation parameters is beyond the scope of this review. However, in the presence of respiratory distress or a high suspicion of infection, a thoracentesis could be performed, if the expected benefits outweigh the potential risks.

In some situations, thoracentesis may be deferred. A mediastinal or tracheal shift toward the effusion on radiography (Figure 1B) suggests an endobronchial obstruction. In that context, unless signs of infection are present, diagnostic efforts should focus on the endobronchial obstruction. In patients with heart failure, nephrotic syndrome or cirrhosis with ascites, unless clinical clues suggestive of an exudate are present, thoracentesis may be deferred until the outcome of a trial of diuretic therapy is known.

Analysis of pleural fluid

The appearance of pleural fluid can suggest specific causes, such as pus with an empyema, or milky fluid with a chylothorax or pseudochylothorax. A blood-tinged appearance can be seen in a variety of conditions, including heart failure, and thus carries little diagnostic value.¹³ The presence of a true hemothorax can be confirmed by a pleural fluid hematocrit of at least 50% of the peripheral blood value.

Pleural fluid cell count and differential may help narrow the differential diagnosis: a lymphocytic predominance is classically seen in cancer, TB and rheumatoid effusions, whereas a neutrophilic profile is seen in parapneumonic effusions. However, there is no evidence that pleural fluid cell count and differentials substantially alter management, and overlapping profiles of various effusion types reduce their discriminative power.¹³

Although various methods have been proposed to separate exudates from transudates, Light’s criteria have been the standard tool for the past four decades.⁶ According to these criteria, an effusion with any of the following characteristics is an exudate: pleural-to-serum protein ratio greater than 0.5, pleural-to-serum

lactate dehydrogenase ratio greater than 0.6 and pleural lactate dehydrogenase greater than two-thirds of the upper limit of normal for the serum; an effusion meeting none of these criteria is classified as a transudate. The original description had a sensitivity to rule out exudates of 99% and a specificity to rule in exudates of 98%.⁶ Although the ability of Light's criteria to rule out exudates has been confirmed in multiple series^{5,14,15} and in a well-conducted meta-analysis,¹⁶ specificity is lower than initially described: true transudates are misclassified as exudates in 15% to 30% of cases.^{5,16} Alternative tests with higher specificity have been proposed (pleural-to-serum albumin gradient, pleural-to-serum protein gradient, pleural cholesterol and pleural-to-serum cholesterol ratio), but the ability of Light's criteria to rule out exudates has been higher consistently.^{5,14,16} Because the goal of the initial evaluation is to exclude an exudate, Light's criteria remain the tool of choice.

The misclassification of transudates using Light's criteria usually occurs in patients with heart failure or cirrhosis who are taking diuretics (up to one-third of patients).^{15,17} A small series showed that diuretic therapy can raise pleural fluid protein and lactate dehydrogenase so that criteria for an exudate are met¹⁸ but usually only by a small margin.¹⁷ Several methods were proposed in a single-centre retrospective series to classify such effusions correctly,¹⁹ but there is no good evidence to guide decision-making in this situation. The gold standard in studies of pleural

Table 1: Useful basic clinical tests

Clinical test	Rationale
Routine tests	
Complete blood cell count	Abnormal blood cell counts can suggest infection or cancer*
Serum LDH, protein	To apply Light's criteria
Pleural LDH, protein	To apply Light's criteria
Pleural pH, glucose	To identify complicated parapneumonic effusions
Pleural fluid culture	To identify infectious agents
Pleural fluid cytology	To diagnose malignant disease
Contrast chest CT for exudates	To identify mediastinal/pleural/lung lesions

Note: CT = computed tomography, LDH = lactate dehydrogenase. Light's criteria: An effusion with any of the following characteristics is classified as an exudate: pleural:serum ratio > 0.5, pleural:serum LDH ratio > 0.6 or pleural LDH > 2/3 of the upper limit of normal for the serum. An effusion with none of these characteristics is classified as a transudate.⁶
*For a more detailed discussion on the value of cellular counts and differentials, readers should consult the guideline published by the British Thoracic Society.¹

fluid analyses are clinical judgment and response to therapy. Therefore, if a patient with heart failure has an effusion classified as an exudate by a small margin and there are no clues to an underlying exudative cause, it is reasonable to treat heart failure and determine whether more investigations are required if the effusion fails to improve.

What if a parapneumonic effusion is suspected?

In the context of pneumonia, a thoracentesis should be performed for any effusion large enough to sample; the goal is to identify complicated parapneumonic effusions and empyemas, which require prompt drainage.²⁰ Effusions too small to be sampled can be followed radiologically and sampled if they enlarge.

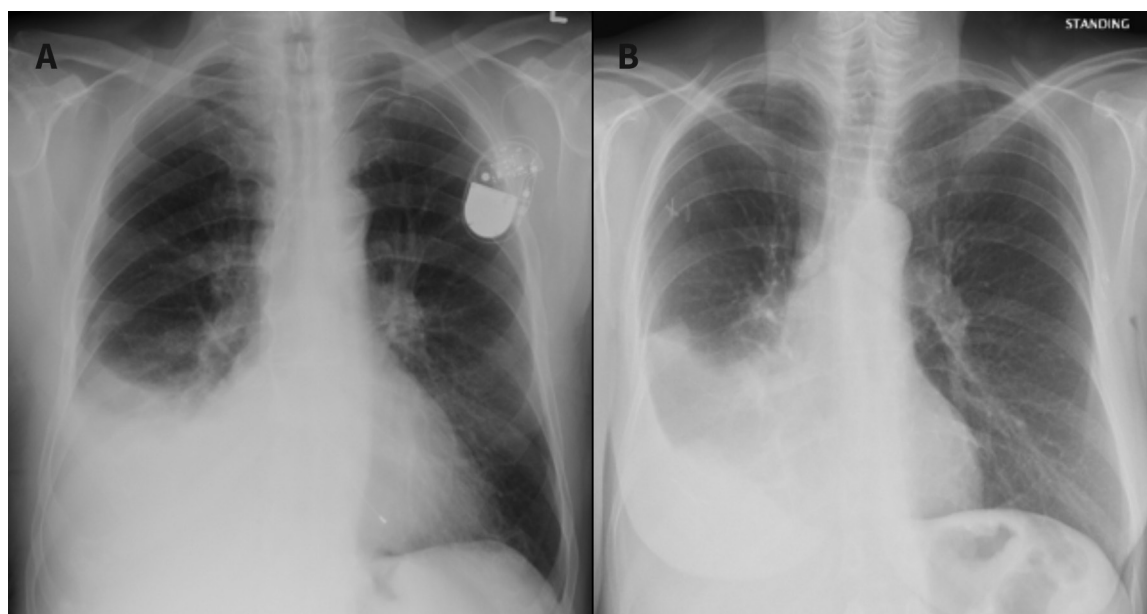


Figure 1: The effect of endobronchial obstruction in patients with pleural effusion on chest radiography. (A) A right pleural effusion without endobronchial obstruction. The trachea is midline. However, the trachea may be shifted to the contralateral side in a large effusion. (B) A right pleural effusion with obstruction of the right mainstem and intermediate bronchi by tumour. The trachea and mediastinum are shifted toward the effusion owing to atelectasis caused by the obstruction.

According to a British Thoracic Society guideline on the management of pleural infection,²⁰ a complicated parapneumonic effusion is defined as an effusion in the context of pneumonia with a pH of less than 7.2 (or a glucose level of less than 3.4 mmol/L), a positive fluid culture or pus (the latter indicating an empyema). This definition is based on a rigorous meta-analysis that showed that pleural pH is the best marker of complicated parapneumonic effusions (pleural glucose being the second-best marker).²¹ A sample of pleural fluid for this should be acquired using a blood gas syringe, avoiding fluid contact with air.²² In addition to obtaining peripheral blood cultures, pleural fluid should be placed in blood culture bottles and a sterile container, because a small but well-conducted series showed a 20% absolute increase in microbiologic yield with this strategy.^{20,23} Although management details are beyond the scope of this review, complicated parapneumonic effusions must be promptly and completely evacuated with a chest drain to avoid uncontrolled sepsis, the need for surgery, prolonged stays in hospital or death. Early consultation with respiratory or thoracic surgery is also recommended by the guideline.²⁰

What should be done if the initial evaluation is nondiagnostic?

Imaging

If an exudate is identified but no cause is obvious, further investigations are necessary to identify the etiology. Contrast-enhanced computed tomography (CT) of the chest is recommended by the British Thoracic Society guideline to guide further diagnostic testing.¹ This may show signs of specific etiologies and help determine the next best step. Whether to obtain the scan before or after fluid drainage is controversial. In a retrospective series involving 32 patients who underwent imaging before and after drainage, management was not altered by the postdrainage scan.²⁴ Although certain CT features are suggestive of malignant disease (pleural nodularity, pleural thickening of 1 cm or more, mediastinal pleural thickening and circumferential pleural thickening),²⁵ their absence does not exclude malignant disease. In a retrospective series involving 370 patients who had both a CT scan and a pleural biopsy for undiagnosed effusions, the sensitivity and specificity of the CT scan for malignant disease were 68% and 78%, respectively.²⁶ Although a prediction score has been developed to differentiate benign from malignant effusions,²⁷ it was derived and validated in a single centre and requires further study.

Some experts suggest routinely investigating to exclude pulmonary embolism as a cause of an undiagnosed effusion,²⁸ because pleural effusions have been reported to occur in about half of pulmonary emboli.²⁹ However, a prospective study in which CT pulmonary angiography was performed in 141 consecutive patients with an undiagnosed effusion showed a pulmonary embolism in only nine patients (6.4%).³⁰ In no patient was the embolism thought to have caused the effusion. Thus, whether a pulmonary CT angiogram is warranted in all patients with an undiagnosed effusion remains to be determined.

Regarding the role of positron emission tomography, three different meta-analyses have yielded different conclusions.³¹⁻³³

Because of multiple methodological issues and suboptimal discriminative characteristics of current image analysis techniques,³³ positron emission tomography is not part of the routine evaluation of the patient with a pleural effusion.¹

Additional investigations

Pleural malignant disease and tuberculous pleurisy are challenging to identify, yet they are important conditions to exclude when faced with a recurrent undiagnosed exudate. A negative fluid cytology does not exclude malignant disease; large series found that the sensitivity of pleural fluid cytology is only 60% to 70%.^{1,34} Although a second thoracentesis improves the diagnostic yield somewhat,^{13,35} a third fluid sample rarely does. For tuberculosis, the sensitivity of pleural fluid culture is below 40% consistently.³⁶ Although sputum cultures may prove diagnostic despite a normal radiograph in a small proportion of patients, negative sputum cultures cannot rule out pleural tuberculosis.³⁷ Adenosine deaminase is a pleural fluid marker that can exclude tuberculosis in low-incidence settings based on meta-analysis data,³⁸ but it is not readily available in many centres. Unfortunately, no pleural fluid marker for malignant disease is currently available for clinical use.

Patients with an undiagnosed recurrent exudative pleural effusion should be referred to respiratory for further evaluation, as recommended by the British Thoracic Society guideline.¹ In patients with reasonable functional status, a pleural biopsy is indicated.¹ Options include CT- or ultrasonography-guided percutaneous biopsy, medical thoracoscopy (an ambulatory procedure performed with conscious sedation) or video-assisted thoracoscopic surgery. There is a paucity of studies comparing these options; the choice should be guided by patient factors (level of fitness, pleura appearance on CT, presence of loculations, patient preferences), as well as local expertise. Although the management of recurrent pleural effusions is beyond the scope of this review (resources can be found in Box 4), clinicians should strive to clarify the cause before invasive therapeutic measures, such as pleurodesis or indwelling pleural catheter insertion, are proposed.

Box 4: Management resources

- Video on how to perform a thoracentesis: Thomsen TW, DeLapenna J, Setnik GS. Videos in clinical medicine. Thoracentesis. *N Engl J Med* 2006;355:e16.
- British Thoracic Society Pleural Disease Guideline, available at www.brit-thoracic.org.uk/standards-of-care/guidelines/bts-pleural-disease-guideline/
- Review on the management of parapneumonic effusions: Bhatnagar R, Maskell NA. Treatment of complicated pleural effusions in 2013. *Clin Chest Med* 2013; 34: 47-62.
- Review on the management of malignant effusions: Thomas R, Francis R, Davies HE, et al. Interventional therapies for malignant pleural effusions: the present and the future. *Respirology* 2014; 19: 809-22.
- Online database for drug-induced respiratory diseases, including pleural effusions, available at www.pneumotox.com/

Conclusion

The differential diagnosis of pleural effusion can be daunting, but an organized approach that begins with the patient's history and focuses on identification of conditions that require urgent evaluation can guide appropriate care. Physicians investigating a pleural effusion should understand the limitations of the available diagnostic tools and refer patients for specialist evaluation when the initial assessment fails to reveal a cause. Other unanswered questions are outlined in Box 5.

Box 5: Unanswered questions

- Could categorization of pleural effusions as transudates versus exudates using only pleural fluid samples, without the use of serum samples, lead to lower costs and preserved diagnostic ability?
- Could novel pleural fluid markers be used to exclude pleural malignancy?
- What is the best method to obtain a pleural biopsy to optimize diagnostic yield, safety and cost-effectiveness?

References

- Hooper C, Lee YCG, Maskell N; BTS Pleural Guideline Group. Investigation of a unilateral pleural effusion in adults: British Thoracic Society pleural disease guideline 2010. *Thorax* 2010;65(Suppl 2):ii4-17.
- Light RW. *Pleural diseases*. 6th ed. London (UK): Wolters Kluwer; 2013.
- Porcel JM, Esquerda A, Vives M, et al. Etiology of pleural effusions: analysis of more than 3,000 consecutive thoracenteses. *Arch Bronconeumol* 2014; 50:161-5.
- Lanphear BP, Buncher CR. Latent period for malignant mesothelioma of occupational origin. *J Occup Med* 1992;34:718-21.
- Romero-Candeira S, Hernández L, Romero-Brufo S, et al. Is it meaningful to use biochemical parameters to discriminate between transudative and exudative pleural effusions? *Chest* 2002;122:1524-9.
- Light RW, Macgregor MI, Luchsinger PC, et al. Pleural effusions: the diagnostic separation of transudates and exudates. *Ann Intern Med* 1972;77:507-13.
- Grogan DR, Irwin RS, Channick R, et al. Complications associated with thoracentesis. A prospective, randomized study comparing three different methods. *Arch Intern Med* 1990;150:873-7.
- Grogan DR, Irwin RS, Channick R, et al. Complications associated with thoracentesis. A prospective, randomized study comparing three different methods. *Arch Intern Med* 1990;150:873-7.
- Mayo PH, Goltz HR, Tafreshi M, et al. Safety of ultrasound-guided thoracentesis in patients receiving mechanical ventilation. *Chest* 2004;125:1059-62.
- Lichtenstein D, Hulot JS, Rabiller A, et al. Feasibility and safety of ultrasound-aided thoracentesis in mechanically ventilated patients. *Intensive Care Med* 1999;25:955-8.
- Chen HJ, Tu CY, Ling SJ, et al. Sonographic appearances in transudative pleural effusions: not always an anechoic pattern. *Ultrasound Med Biol* 2008;34:362-9.
- Yang PC, Luh KT, Chang DB, et al. Value of sonography in determining the nature of pleural effusion: analysis of 320 cases. *AJR Am J Roentgenol* 1992;159:29-33.
- Light RW, Erozan YS, Ball WC Jr. Cells in pleural fluid. Their value in differential diagnosis. *Arch Intern Med* 1973;132:854-60.
- Romero S, Martinez A, Hernandez L, et al. Light's criteria revisited: consistency and comparison with new proposed alternative criteria for separating pleural transudates from exudates. *Respiration* 2000;67:18-23.
- Burgess LJ, Maritz FJ, Taljaard JJJ. Comparative analysis of the biochemical parameters used to distinguish between pleural transudates and exudates. *Chest* 1995;107:1604-9.
- Heffner JE, Brown LK, Barbieri CA. Diagnostic value of tests that discriminate between exudative and transudative pleural effusions. Primary Study Investigators. *Chest* 1997;111:970-80.
- Bielsa S, Porcel JM, Castellote J, et al. Solving the Light's criteria misclassification rate of cardiac and hepatic transudates. *Respirology* 2012;17:721-6.
- Chakko SC, Caldwell SH, Sforza PP. Treatment of congestive heart failure. Its effect on pleural fluid chemistry. *Chest* 1989;95:798-802.
- Porcel JM. Identifying transudates misclassified by Light's criteria. *Curr Opin Pulm Med* 2013;19:362-7.
- Davies HE, Davies RJ, Davies CW; BTS Pleural Disease Guideline Group. Management of pleural infection in adults: British Thoracic Society Pleural Disease Guideline 2010. *Thorax* 2010;65(Suppl 2):ii41-53.
- Heffner JE, Brown LK, Barbieri C, et al. Pleural fluid chemical analysis in parapneumonic effusions. A meta analysis. *Am J Respir Crit Care Med* 1995;151:1700-8.
- Rahman NM, Mishra EK, Davies HE, et al. Clinically important factors influencing the diagnostic measurement of pleural fluid pH and glucose. *Am J Respir Crit Care Med* 2008;178:483-90.
- Menzies SM, Rahman NM, Wrightson JM, et al. Blood culture bottle culture of pleural fluid in pleural infection. *Thorax* 2011;66:658-62.
- Corcoran JP, Acton L, Ahmed A, et al. Diagnostic value of radiological imaging pre- and post-drainage of pleural effusions. *Respirology* 2016;21:392-5.
- Leung AN, Müller NL, Miller RR. CT in differential diagnosis of diffuse pleural disease. *AJR Am J Roentgenol* 1990;154:487-92.
- Hallifax RJ, Haris M, Corcoran JP, et al. Role of CT in assessing pleural malignancy prior to thoracoscopy. *Thorax* 2015;70:192-3.
- Porcel JM, Pardina M, Bielsa S, et al. Derivation and validation of a CT scan scoring system for discriminating malignant from benign pleural effusions. *Chest* 2015;147:513-9.
- Light RW. Pleural effusions. *Med Clin North Am* 2011;95:1055-70.
- Porcel JM, Madroñero AB, Pardina M, et al. Analysis of pleural effusions in acute pulmonary embolism: radiological and pleural fluid data from 230 patients. *Respirology* 2007;12:234-9.
- Hooper C, Laurence I, Harvey J, et al. The role of CT pulmonary angiography in the investigation of unilateral pleural effusions. *Respiration* 2014;87:26-31.
- Treglia G, Sadeghi R, Annunziata S, et al. Diagnostic accuracy of 18F-FDG-PET and PET/CT in the differential diagnosis between malignant and benign pleural lesions: a systematic review and meta-analysis. *Acad Radiol* 2014;21:11-20.
- Treglia G, Sadeghi R, Annunziata S, et al. Diagnostic performance of fluorine-18-fluorodeoxyglucose positron emission tomography in the assessment of pleural abnormalities in cancer patients: a systematic review and a meta-analysis. *Lung Cancer* 2014;83:1-7.
- Porcel JM, Hernández P, Martínez-Alonso M, et al. Accuracy of fluorodeoxyglucose-PET imaging for differentiating benign from malignant pleural effusions: a meta-analysis. *Chest* 2015;147:502-12.
- Rivera MP, Mehta AC, Wahidi MM. Establishing the diagnosis of lung cancer: Diagnosis and management of lung cancer, 3rd ed: American College of Chest Physicians evidence-based clinical practice guidelines. *Chest* 2013;143 (Suppl):e142S-65S.
- Garcia LW, Ducatman BS, Wang HH. The value of multiple fluid specimens in the cytological diagnosis of malignancy. *Mod Pathol* 1994;7:665-8.
- Valdés L, Alvarez D, San José E, et al. Tuberculous pleurisy: a study of 254 patients. *Arch Intern Med* 1998;158:2017-21.
- Conde MB, Loivos AC, Rezende VM, et al. Yield of sputum induction in the diagnosis of pleural tuberculosis. *Am J Respir Crit Care Med* 2003;167:723-5.
- Liang QL, Shi HZ, Wang K, et al. Diagnostic accuracy of adenosine deaminase in tuberculous pleurisy: a meta-analysis. *Respir Med* 2008;102:744-54.

Competing interests:

None declared. This article was solicited and has been peer reviewed.

Affiliation: Division of Respiratory Medicine, McGill University Health Centre, Montréal, Que.

Contributors: Stéphane Beaudoin had the original idea for the review, designed the plan for the article, and drafted the first and final versions of the manuscript. Anne Gonzalez reviewed the plan for the manuscript. Both of the authors reviewed the manuscript critically for important intellectual content, gave final

approval of the version to be published and agreed to be accountable for all aspects of the work.

Correspondence to: Stéphane Beaudoin, stephane.beaudoin@mcgill.ca