

A *de novo* and novel mutation in the *EYAI* gene in a Chinese child with branchio-oto-renal syndrome

Guomin Li¹, Qian Shen¹, Li Sun¹, Haimei Liu¹, Yu An², Hong Xu^{1,*}

¹ Children's Hospital of Fudan University, Shanghai, China;

² Institutes of Biomedical Sciences of Fudan University, Shanghai, China.

Summary

Branchio-oto-renal (BOR) syndrome is a rare autosomal dominant disorder characterized by branchial cleft fistulae or cysts, preauricular pits, ear malformations, hearing loss, and renal anomalies. Mutations in the human homologue of the *Drosophila* eyes absent gene (*EYAI*) are the most common cause of BOR syndrome. PCR and direct sequencing were used to investigate all of the exons and exon-intron boundaries in the *EYAI* gene in a patient with BOR syndrome from China. The patient was a child who displayed clinical features of BOR syndrome. Analysis of mutations in the *EYAI* gene revealed a novel single base-pair deletion resulting in a truncated protein (c.1381delA; p.R461fs467X), and an analysis of mutations in the family revealed that this mutation was a *de novo* mutation. This is the first case of BOR syndrome in mainland China to be diagnosed based on clinical manifestations and mutations in the *EYAI* gene. The novel c.1381delA mutation detected here expands the spectrum of known mutations in the *EYAI* gene.

Keywords: *EYAI* gene, branchio-oto-renal syndrome, novel mutation

1. Introduction

Branchio-oto-renal (BOR) syndrome (MIM#113650) is an autosomal dominant disorder that is associated with branchial fistulae or cysts, preauricular pits, ear malformations, hearing impairment, and renal anomalies (1). The incidence of BOR syndrome is approximately 1:40,000 (2). Mutations in the *EYAI* gene, the human homologue of the *Drosophila* eyes absent gene, have been shown to cause BOR syndrome (3,4). The *EYAI* gene consists of 16 exons spanning 156 kb on chromosome 8q13.3 (5). The *EYAI* gene is a member of the EYA family, which is characterized by a divergent N-terminal activation domain and a conserved C-terminal Eya domain, and the gene functions as a transcriptional co-activator in the Eya-Six regulatory network for early development of different organs, including the ear and kidney (3). Over 202 different mutations in the *EYAI*

gene that cause disease have been found in various populations (<http://www.hgmd.cf.ac.uk/>, last updated December 2017). However, few mutations have been identified in the Chinese population (6). Reported here is a *de novo* mutation of the *EYAI* gene first identified in a Chinese child with BOR syndrome.

2. Subjects and Methods

2.1. Patient

A girl was admitted to a local hospital in 2010 because of her short stature at age 3. Proteinuria (2+) and abnormal renal function (BUN 17.2 mmol/L, creatinine level 140 μmol/L) were noted by the local hospital, and renal ultrasound indicated that the left kidney was 24.4 mm × 18.9 mm in size while the right kidney was 55.4 mm × 23.0 mm in size. In March 2011, the girl was referred to this facility for evaluation because of the continuing deterioration of renal function at age 4.6. She underwent surgery to remove a branchial cleft cyst at age 1.1 and surgery to repair pre-auricular fistulae at age 4.

On admission, a clinical examination revealed scars from surgery to repair fistulae in the preauricular region and surgery to remove a branchial cleft cyst in the neck (Figures 1A and 1B). Her height was between the 25th

Released online in J-STAGE as advance publication February 26, 2018.

*Address correspondence to:

Dr. Hong Xu, Department of Nephrology, Children's Hospital of Fudan University, 399 Wanyuan Road, Minhang District, Shanghai 201102, China.

E-mail: hxu@shmu.edu.cn

and 50th percentile, and her body weight was in the 50th percentile. Laboratory tests revealed proteinuria (2+, total urine protein of 0.44 g/24 h), abnormal hemoglobin (7.7 g/100 mL), and renal insufficiency (filtration rate < 15 mL/min/1.73m², creatinine level of 505.0 mol/L, and BUN of 44.9 mmol/L). Blood gases revealed metabolic acidosis (pH 7.303, BE-7.8 mmol/L). Abdominal magnetic resonance urography (MRU) revealed left kidney hypoplasia. However, her hearing test was normal.

The family's medical history was also investigated. Informed consent was obtained from the parents. Ethical approval to conduct this study was obtained from the Ethics Committee of the Children's Hospital of Fudan University.

2.2. Methods

In 2011, genomic DNA was extracted and purified from

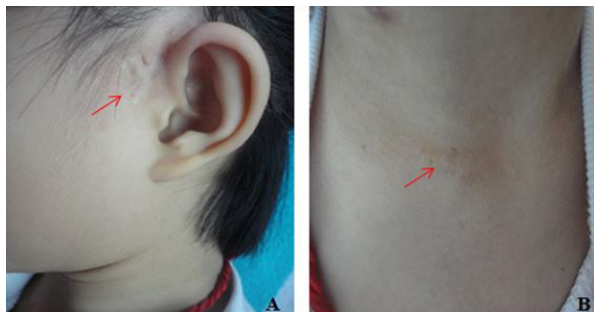


Figure 1. Clinical manifestations of BOR syndrome. (A), scars from surgery to repair fistulae in the preauricular region (B), scars from surgery to remove a branchial cleft cyst in the neck.

peripheral leukocytes in whole-blood samples using a DNA isolation kit (Qiagen, Hilden, Germany). All exons of the *EYA1* gene were amplified using a polymerase chain reaction (PCR). Primers for the *EYA1* gene were designed based on previously published information regarding intron-exon boundaries. The PCR product was purified with a QIA Quick PCR Purification Kit (Qiagen, Hilden, Germany). The purified product was cycle-sequenced with Big-Dye terminators (Applied Biosystems, Foster City, CA, USA), and the cycle sequence product was analyzed with an automated sequencer (ABI Prism 310 Genetic Analyzer). Novel mutations in *EYA1* were investigated in 100 healthy controls using direct sequencing. Mutation nomenclature was based on the *EYA1* cDNA sequence of NM_000503.3 (<http://www.ncbi.nlm.nih.gov>).

3. Results and Discussion

The patient's parents had no consanguinity, and there was no family history of branchial cleft cyst, pre-auricular fistulae, renal disease, or hearing loss. A novel deletion mutation, c.1381delA, was detected in the *EYA1* gene, and the patient was heterozygous for this change (Figure 2A). This deletion causes a frameshift of amino acids and results in a truncated protein

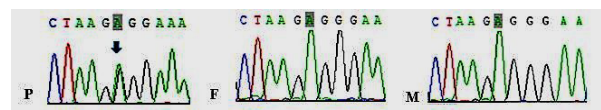


Figure 2. Analysis of mutations in the *EYA1* gene (the arrow indicates the mutation). P: patient; M: mother; F: father.

Table 1. Genotype of 21 patients with BOR syndrome from East Asia

| Nation | Patient | EYA1 gene | | | Year | Ref. |
|--------|---------|-----------|-----------------------|---------------------|------|------|
| | | exon | nucleotide sequence | amino acid sequence | | |
| China* | 1 | 6 | c.446C>T | p.Q156X | 2012 | (7) |
| | 2 | 17 | c.1735del G | p.D579fs | 2012 | (7) |
| Korea | 3 | 14 | c.1474insC | p.R492Pfs | 2005 | (16) |
| | 4 | 7 | c.430C>T | p.Q144X | 2007 | (17) |
| | 5 | 6 | c.321delT | p.A107fs | 2009 | (18) |
| | 6 | - | IVS8-2AG | | 2009 | (19) |
| | 7 | 10 | c.965 A>G | p.E332G | 2013 | (20) |
| | 8 | 6 | c.418G>A | p.G140S | 2014 | (10) |
| Japan | 9 | 7 | c.579C>G | p.Y193fs | 1999 | (21) |
| | 10 | 9 | c.792 | R264X | 2001 | (22) |
| | 11 | 8 | c.625A>G | p.S189G | 2003 | (23) |
| | 12 | 14 | c.1402_1408delACAACTA | p.T468fs | 2004 | (24) |
| | 13 | 6 | c.533C>G | p.S178X | 2004 | (25) |
| | 14 | 6 | c.497T>A | p.Y163X | 2006 | (26) |
| | 15 | 12 | c.1107T>A | p.Y370X | 2006 | |
| | 16 | 10 | c.952G>A | p.D318Y | 2006 | |
| | 17 | - | IVS9-2A>G | | 2006 | |
| | 18 | - | IVS14-1G>A | | 2006 | |
| | 19 | 17 | c.1667insT | p.D556fs | 2007 | (27) |
| | 20 | 5 | Del exons 5 to 7 | | 2010 | (28) |
| | 21 | 8 | c.634C>T | p.R212X | 2015 | (29) |

*: From Taiwan, -: on intron

(p.R461fs467X). An analysis of mutations in the *EYA1* gene in the family revealed that her parents did not carry the c.1381delA mutation. The mutation was not found in controls.

The patient was diagnosed with BOR syndrome based on clinical features and genetic testing. The patient subsequently received peritoneal dialysis. She was switched to hemodialysis in 2015 due to the loss of peritoneal function, and she received a kidney transplant in 2016. She was assessed at this facility every three to six months. The renal allograft is functioning normally.

BOR syndrome is characterized by a wide spectrum of clinical manifestations that represents a combination of branchial, otic, and renal anomalies (7). Individuals with branchio-otic (BO) syndrome (OMIM#602588) are affected by the same branchial and otic anomalies as in BOR without the associated renal anomalies (8). Due to the wide spectrum of phenotypic findings and the phenotypic variability between and within families, phenotypic criteria for clinical diagnosis of BOR syndrome have been proposed (9). The major criteria include branchial anomalies, deafness, preauricular pits, and renal anomalies, while minor criteria include external, middle, and inner ear anomalies and preauricular tags. A definitive diagnosis is based on meeting ≥ 3 major criteria, meeting 2 major criteria and ≥ 2 minor criteria, or meeting 1 major criterion and having a first-degree relative with BOR syndrome. The patient in this study met 3 major criteria, *i.e.* branchial, preauricular, and renal anomalies. The most common manifestation of BOR is hearing loss, which can be conductive, sensorineural, or mixed (10). Some studies estimate that BO/BOR has a prevalence of 2% amongst profoundly deaf children (2). However, the current patient has no hearing loss.

BOR is genetically heterogeneous, although mutations in *EYA1* are most commonly identified and segregate with the BOR phenotype in about 40% of families (9). Causative variants include point mutations as well as large and small deletions (11-13). *EYA1* encodes a transcriptional regulator, and mice heterozygous for the targeted deletion of this gene have renal abnormalities and a conductive hearing loss similar to the human phenotype (14). *EYA1* homozygous null mice lack ears and kidneys (15).

The current patient has a heterozygous deletion mutation (c.1381delA), which causes a frameshift of amino acids and results in a truncated protein (p.R461fs467X). This mutation is novel, and was not detected in controls. Thus, c.1381delA was deemed to be a disease-causing mutation. Over 202 different mutations in the *EYA1* gene that cause disease have been found in various populations (<http://www.hgmd.cf.ac.uk/>, last updated December 2017), but most have been identified in subjects of European ancestry. More than 21 different mutations in the *EYA1* gene have been identified in patients with BOR/BO syndrome

in South Korea and Japan (Table 1) (10,16-29). In contrast, few mutations have been reported before in patients with BOR syndrome in Taiwan, China (Table 1) (7). All of these mutations were scattered through the *EYA1* coding region; complex mutations involving chromosomal rearrangements have not been found in Asians.

Recent studies have found that mutations in both the *SIX1* and *SIX5* genes are also associated with BOR syndrome (19). *SIX1*, the human homologue of the *Drosophila sine oculis* gene, encodes a DNA-binding protein associated with *EYA1* (19,30). Most mutations identified in *SIX1* are missense mutations, but small deletions have also been reported in patients with BOR syndrome (30). *SIX1* plays a role in *EYA-SIX-PAX* interaction in the development of the ears, kidneys, and other organs (31). Evaluation of *SIX1* and its related target genes may provide clues to the mechanisms involved in causing BOR syndrome (13). The role of *SIX5* in BOR is less clear. Although a few missense mutations in *SIX5* have been reported in patients with BOR syndrome, the role of *SIX5* variants in the pathophysiology of BOR has been questioned (13,19).

In conclusion, this case report has described a Chinese child with BOR syndrome and it has identified a novel frameshift mutation caused by a single base-pair deletion in the *EYA1* gene. The novel c.1381delA mutation is a disease-causing mutation, and this finding expands the spectrum of mutations in the *EYA1* gene.

References

1. Kochhar A, Fischer SM, Kimberling WJ, Smith RJ. Branchio-oto-renal syndrome. *Am J Med Genet A*. 2007; 143A:1671-1678.
2. Fraser FC, Sproule JR, Halal F. Frequency of the branchio-oto-renal (BOR) syndrome in children with profound hearing loss. *Am J Med Genet*. 1980; 7:341-349.
3. Abdelhak S, Kalatzis V, Heilig R, *et al.* A human homologue of the *Drosophila eyes absent* gene underlies branchio-oto-renal (BOR) syndrome and identifies a novel gene family. *Nat Genet*. 1997; 15:157-164.
4. Hwang DY, Dworschak GC, Kohl S, Saisawat P, Vivante A, Hilger AC, Reutter HM, Soliman NA, Bogdanovic R, Kehinde EO, Tasic V, Hildebrandt F. Mutations in 12 known dominant disease-causing genes clarify many congenital anomalies of the kidney and urinary tract. *Kidney Int*. 2014; 85:1429-1433.
5. Kumar S, Kimberling WJ, Kenyon JB, Smith RJ, Marres HA, Cremers CW. Autosomal dominant branchio-oto-renal syndrome—localization of a disease gene to chromosome 8q by linkage in a Dutch family. *Hum Mol Genet*. 1992; 1:491-495.
6. Wang SH, Wu CC, Lu YC, Lin YH, Su YN, Hwu WL, Yu IS, Hsu CJ. Mutation screening of the *EYA1*, *SIX1*, and *SIX5* genes in an East Asian cohort with branchio-oto-renal syndrome. *Laryngoscope*. 2012; 122:1130-1136.
7. Gigante M, d'Altilia M, Montemurno E, Diella S, Bruno F,

- Netti GS, Ranieri E, Stallone G, Infante B, Grandaliano G, Gesualdo L. Branchio-Oto-Renal Syndrome (BOR) associated with focal glomerulosclerosis in a patient with a novel EYA1 splice site mutation. *BMC Nephrol.* 2013; 14:60.
8. Vincent C, Kalatzis V, Abdelhak S, Chaib H, Compain S, Helias J, Vanecloo FM, Petit C. BOR and BO syndromes are allelic defects of EYA1. *Eur J Hum Genet.* 1997; 5:242-246.
 9. Chang EH, Menezes M, Meyer NC, Cucci RA, Vervoort VS, Schwartz CE, Smith RJ. Branchio-oto-renal syndrome: The mutation spectrum in EYA1 and its phenotypic consequences. *Hum Mutat.* 2004; 23:582-589.
 10. Kim HR, Song MH, Kim MA, Kim YR, Lee KY, Sonn JK, Lee J, Choi JY, Kim UK. Identification of a novel nonsynonymous mutation of EYA1 disrupting splice site in a Korean patient with BOR syndrome. *Mol Biol Rep.* 2014; 41:4321-4327.
 11. Amrhein P, Sittel C, Spaich C, Kohlhase J, Boppert R, Kohlhof P, Koitschev A. Middle ear salivary gland choristoma related to branchio-oto-renal syndrome diagnosed by array-CGH. *HNO.* 2014; 62:374-377. (in German)
 12. Brophy PD, Alasti F, Darbro BW, Clarke J, Nishimura C, Cobb B, Smith RJ, Manak JR. Genome-wide copy number variation analysis of a Branchio-oto-renal syndrome cohort identifies a recombination hotspot and implicates new candidate genes. *Hum Genet.* 2013; 132:1339-1350.
 13. Krug P, Moriniere V, Marlin S, Koubi V, Gabriel HD, Colin E, Bonneau D, Salomon R, Antignac C, Heidet L. Mutation screening of the *EYA1*, *SIX1*, and *SIX5* genes in a large cohort of patients harboring branchio-oto-renal syndrome calls into question the pathogenic role of *SIX5* mutations. *Hum Mutat.* 2011; 32:183-190.
 14. Xu PX, Adams J, Peters H, Brown MC, Heaney S, Maas R. Eya1-deficient mice lack ears and kidneys and show abnormal apoptosis of organ primordia. *Nat Genet.* 1999; 23:113-117.
 15. Kwon MJ, Boo SH, Kim HJ, Cho YS, Chung WH, Hong SH. A novel splice site mutation in the *EYA1* gene in a Korean family with branchio-oto (BO) syndrome. *Acta Otolaryngol.* 2009; 129:688-693.
 16. Kim SH, Shin JH, Yeo CK, Chang SH, Park SY, Cho EH, Ki CS, Kim JW. Identification of a novel mutation in the *EYA1* gene in a Korean family with branchio-oto-renal (BOR) syndrome. *Int J Pediatr Otorhinolaryngol.* 2005; 69:1123-1128.
 17. Lee KY, Kim S, Kim UK, Ki CS, Lee SH. Novel EYA1 mutation in a Korean branchio-oto-renal syndrome family. *Int J Pediatr Otorhinolaryngol.* 2007; 71:169-174.
 18. Lee JD, Kim SC, Koh YW, Lee HJ, Choi SY, Kim UK. A novel frameshift mutation in the *EYA1* gene in a Korean family with branchio-oto-renal syndrome. *Ann Clin Lab Sci.* 2009; 39:303-306.
 19. Kwon MJ, Boo SH, Kim HJ, Cho YS, Chung WH, Hong SH. A novel splice site mutation in the *EYA1* gene in a Korean family with branchio-oto (BO) syndrome. *Acta Otolaryngol.* 2009; 129:688-693.
 20. Song MH, Kwon TJ, Kim HR, Jeon JH, Baek JI, Lee WS, Kim UK, Choi JY. Mutational analysis of *EYA1*, *SIX1* and *SIX5* genes and strategies for management of hearing loss in patients with BOR/BO syndrome. *PLoS One.* 2013; 8:e67236.
 21. Usami S, Abe S, Shinkawa H, Deffenbacher K, Kumar S, Kimberling WJ. EYA1 nonsense mutation in a Japanese branchio-oto-renal syndrome family. *J Hum Genet.* 1999; 44:261-265.
 22. Fukuda S, Kuroda T, Chida E, Shimizu R, Usami S, Koda E, Abe S, Namba A, Kitamura K, Inuyama Y. A family affected by branchio-oto syndrome with EYA1 mutations. *Auris Nasus Larynx.* 2001; 28:S7-S11.
 23. Yashima T, Noguchi Y, Ishikawa K, Mizusawa H, Kitamura K. Mutation of the *EYA1* gene in patients with branchio-oto syndrome. *Acta Otolaryngol.* 2003; 123:279-282.
 24. Shimasaki N, Watanabe K, Hara M, Kosaki K. EYA1 mutation in a newborn female presenting with cardiofacial syndrome. *Pediatr Cardiol.* 2004; 25:411-413.
 25. Uno T, Sawada M, Kurotaki T, Shinomiya N. *EYA1* gene nonsense mutation in a Japanese family with branchio-oto-renal syndrome. *Pediatr Int.* 2004; 46:615-617.
 26. Okada M, Fujimaru R, Morimoto N, Satomura K, Kaku Y, Tsuzuki K, Nozu K, Okuyama T, Iijima K. *EYA1* and *SIX1* gene mutations in Japanese patients with branchio-oto-renal (BOR) syndrome and related conditions. *Pediatr Nephrol.* 2006; 21:475-481.
 27. Matsunaga T, Okada M, Usami S, Okuyama T. Phenotypic consequences in a Japanese family having branchio-oto-renal syndrome with a novel frameshift mutation in the gene *EYA1*. *Acta Otolaryngol.* 2007; 127:98-104.
 28. Morisada N, Rendtorff ND, Nozu K, Morishita T, Miyakawa T, Matsumoto T, Hisano S, Iijima K, Tranebjaerg L, Shirahata A, Matsuo M, Kusuvara K. Branchio-oto-renal syndrome caused by partial EYA1 deletion due to LINE-1 insertion. *Pediatr Nephrol.* 2010; 25:1343-1348.
 29. Miyagawa M, Nishio SY, Hattori M, Takumi Y, Usami S. Germinal mosaicism in a family with BO syndrome. *Ann Otol Rhinol Laryngol.* 2015; 124:118S-122S.
 30. Xu PX. The EYA-SO/SIX complex in development and disease. *Pediatr Nephrol.* 2013; 28:843-854.
 31. Brodbeck S, Englert C. Genetic determination of nephrogenesis: The *Pax/Eya/Six* gene network. *Pediatr Nephrol.* 2004; 19:249-255.

(Received November 18, 2017; Revised January 28, 2018; Accepted February 1, 2018)