



Open Access

ORIGINAL ARTICLE

Operational Andrology

# A retrospective review of single-institution outcomes with robotic-assisted microsurgical varicocelectomy

Andrew McCullough<sup>1</sup>, Leon Elebyjian<sup>2</sup>, Joseph Ellen<sup>3</sup>, Clay Mechlin<sup>4</sup>

We report the largest single-center experience with robotic-assisted microscopic varicocelectomy (RAMV) in male infertility. From August 2012 to February 2015, men with infertility of at least a year and varicoceles underwent RAMV by a single surgeon. Varicocele was diagnosed on physical examination and confirmed by ultrasound by a single ultrasonographer. Preoperative hormone panel, semen analyses, and testicular Doppler ultrasound were obtained from all men and repeated at 3 months. One hundred and forty consecutive men (258 varicocelectomies) were included. Mean age and duration of infertility was 36.4 and 2.8 years, respectively. Median total and free testosterone increased by 145 ng dl<sup>-1</sup> and 4.3 pcg ml<sup>-1</sup> (44.3%), respectively ( $P < 0.0001$ ). Median sperm concentration increased by 37.3% ( $P < 0.03$ ). Median sperm motility and morphology did not significantly change. Median left and right testicular volume increased by 22.3% ( $P < 0.0001$ ) and 12.6% ( $P < 0.0006$ ), respectively. Hydroceles occurred 0.8% of procedures. We had no testicular artery injuries. Persistence of varicocele by Doppler ultrasound was 9.6%. Only 37.3% of patients required pain medications postoperatively. We concluded that RAMV is a safe and effective alternative for varicocele repair with outcomes comparable to historical traditional microsurgical approach.

*Asian Journal of Andrology* (2018) 20, 189–194; doi: 10.4103/aja.aja\_45\_17; published online: 27 October 2017

**Keywords:** male infertility; reproductive technology; robot-assisted microsurgery; varicocele; varicocelectomy

## INTRODUCTION

A varicocele is a pathologic dilation of the testicular veins within the spermatic cord. Varicoceles can be found in 15% of the adult male population and in over 35% of men presenting for infertility evaluation.<sup>1,2</sup> Varicoceles can also contribute to low testosterone (T), orchialgia, and testicular atrophy.<sup>3</sup>

Many explanations for the pathophysiology have been described to account for testicular dysfunction due to varicoceles. Reflux of adrenal metabolites and increased testicular hypoxia have been demonstrated.<sup>4,5</sup> Contralateral testicular dysfunction has also been shown with histological studies and unilateral varicoceles.<sup>6</sup> Varicoceles are known to disrupt the temperature countercurrent regulation of the testicles, disrupting key enzymes involved in spermatogenesis.<sup>7</sup> DNA damage in spermatids from reactive oxygen species (ROS) is also more prominent with varicoceles.<sup>8–11</sup>

Numerous studies have shown the benefits from varicocele ligation. Improvements in semen analyses with male factor infertility, improvements in orchialgia, increasing T levels, and growth in testicular size have all been reported.<sup>12–21</sup> Recent meta-analyses have confirmed that subinguinal traditional microsurgical varicocele repair has the highest success rate and lowest complication rate as compared to macroscopic inguinal or laparoscopic abdominal approaches.<sup>22</sup> This approach has become the gold standard for varicocelectomy.

Recently, the da Vinci<sup>®</sup> robot (DR; Intuitive Surgical, Inc., Sunnyvale, CA, USA) has been used to successfully perform

microsurgical vasectomy reversals and varicocelectomy.<sup>23,24</sup> Advantages of robotics include elimination of tremor, retraction with third arm, and stable immersive 3D microscopic vision, all contributing to precision of surgery. One of the earliest experiences by Shu *et al.*<sup>23</sup> demonstrated successful robotic-assisted microscopic varicocelectomy (RAMV) without complications in eight patients. Operative times were similar to those of traditional microscopic varicocelectomy (TMV). In another study, RAMV improved sperm counts in 76% of oligospermic patients and converted 18% of azoospermic patients to oligospermic with low failure and low complication rates.<sup>24</sup>

In this study, we aim to describe our outcomes for RAMV in men with infertility. To date, this is the largest series reported for RAMV.

## PATIENTS AND METHODS

We retrospectively reviewed charts of 140 patients who underwent RAMV from March 2012 to July 2014 presenting for symptomatic hypogonadism, testicular atrophy, infertility, or orchialgia. The study was conducted in accordance with the Declaration of Helsinki and was approved by the local ethics committee of the Albany Medical College. This retrospective study was not deemed to require patient consents.

All patients were referred to our men's health clinic for infertility, hypogonadism, and/or symptomatic varicocele. All men had an initial history and physical by a urologist (Andrew McCullough). A morning hormone panel including T, free testosterone ( $T_{\text{free}}$ ), estradiol (E2), follicle-stimulating hormone (FSH), luteinizing hormone (LH), and

<sup>1</sup>Institute of Urology, Lahey Hospital and Medical Center, Burlington, MA 01805, USA; <sup>2</sup>Division of Urology, Albany Medical College, Albany, NY 12208, USA;

<sup>3</sup>Virginia Urology, Richmond, VA 23230, USA; <sup>4</sup>Urology Associates of Central Missouri, Columbia, MO 65201, USA.

Correspondence: Dr. A McCullough (andrew.mccullough@lahey.org)

Received: 09 February 2017; Accepted: 14 August 2017

sex hormone binding globulin (SHBG) was obtained. The laboratory analyses were not done at a single laboratory but were done at reference laboratories approved by the patients' insurance plans. Karyotype and microdeletion studies were performed on men suspected of Klinefelter and sperm counts of  $<5 \times 10^6 \text{ ml}^{-1}$ . Men included in the study had normal karyotype and negative microdeletion studies. Men with an examination suspicious for a varicocele underwent a testicular duplex Doppler ultrasound. They were assessed for the presence of a varicocele, varicocele size, testicular parenchyma, and size. All ultrasounds were performed by a single ultrasonographer (Leon Elebyjian) with the same equipment (Acuson 128 with 7.5 MHz electronic linear probe, Acuson 128 XP10, Siemens Healthcare GmbH, Erlangen, Germany). The ultrasound was performed in a warm room ( $>24^\circ\text{C}$ ). Patients were examined in the supine and standing position with and without Valsalva. The spermatic cord and the testicles were examined bilaterally, recording the maximum diameter of the venous vessels and the presence and speed of retrograde venous flow during Valsalva's maneuver. Gray scale and Doppler evaluation of the testes with measurement of testicular dimensions for volume calculation was performed. Volume was calculated as per Lambert (length  $\times$  width  $\times$  height  $\times$  0.7).<sup>25</sup> Patients with clinical varicoceles but without duplex Doppler corroboration of retrograde blood flow were not offered varicocele repair. Only men with varicoceles documented by ultrasound with hypogonadism or an abnormal sperm concentration, motility, or morphology were offered surgery. All surgeries were performed by the same surgeon (Andrew McCullough).

Patients who presented with infertility underwent pre- and post-operative semen analyses that were obtained at one of two independent *in vitro* fertilization (IVF) center Andrology laboratories. Postoperatively, an ultrasound was repeated at 3 months by the same ultrasonographer. Persistent retrograde flow was documented and considered a failure regardless of the physical examination. All men had a hormone panel repeated 3 months postoperatively. Complications and use of pain medications were recorded.

RAMV was performed in the following fashion. A 2-cm horizontal incision was made 3 cm from the base of the penis and 3 cm lateral to the midline (Figure 1). The spermatic cord was isolated through the incision using 3.5  $\times$  loupe magnification. It was elevated from the incision and suspended extracorporeally using a Penrose drain (Figure 2a). For bilateral varicoceles, both cords were isolated before the robot was docked. The robot was then docked perpendicular to the patient on his left side. The first arm was loaded with black diamond forceps and aligned with the right anterior superior iliac spine toward the incision. The third arm was loaded with black diamond forceps and aligned with the ipsilateral knee to the incision. The second arm was loaded with monopolar scissors and was ninety degrees from the first arm in between arms one and three (Figure 1). A bedside assistant was responsible for irrigation, clipping the veins and presenting sutures and vessel loops to the surgeon. Next, after opening and fastening the cremasteric fascia to the Penrose drain (Figure 2b), the vas deferens was isolated with vessel loop and retracted off the field (Figure 2c). The testicular artery (ies) was/were then located with direct visualization without Doppler ultrasound and isolated with another vessel loop (Figure 2d). The lack of field motion and clear magnification allowed identification of the pulsating arteries. Papaverine was used to enhance pulsations. The veins were then dissected, ligated with titanium clips, and divided (Figure 2d). Lymphatics were preserved (Figure 2e). At completion of the varicocelectomy, only the testicular artery, lymphatics, and vas deferens remained. Vessel loops were removed, cremasteric fascia was

reapproximated with 8-0 nylon sutures (Figure 2f), and the cord was freed of the Penrose drain and allowed to retract into the incision. For bilateral procedures, the robot arms were shifted to the contralateral incision without redraping and an identical procedure was performed on the contralateral side. After completion, the robot was undocked, the perifunicular space was infiltrated with 10 cc of a 50/50 mixture of 1% lidocaine and 0.25% bupivacaine and the skin was closed with subcuticular stitches. Statistics were performed with JMP software (SAS Institute Inc., Cary, NC, USA) by Student's *t*-test.

## RESULTS

Of 214 patients who underwent RAMV during that time period, 140 (65.4%) presented with infertility of at least 1 year and varicoceles. We are presenting only our data on the 140 men who presented with infertility. Baseline comorbidities are shown in Table 1. Mean age  $\pm$  standard deviation (s.d.) and duration of infertility  $\pm$  s.d. was  $34.5 \pm 5.8$  and  $2.8 \pm 2.9$  years, respectively. Oligozoospermia ( $<15 \times 10^6 \text{ ml}^{-1}$ ) was not required if teratozoospermia, asthenozoospermia or hypogonadism was present ( $T < 350 \text{ ng dl}^{-1}$ ). Seventy-three (52.1%) patients were oligozoospermic with a mean sperm count ( $\text{SC}_{\text{mean}}$ ) of  $4.1 \times 10^6 \text{ ml}^{-1}$ . A total of 118 (84.3%) and 22 (15.7%) patients underwent bilateral and unilateral repair, respectively, for a total of 258 varicocelectomies. Fifty-seven men (40.7%), 21 (15.0%), and 62 (44.3%) were eugonadal ( $T > 350 \text{ ng dl}^{-1}$ ), borderline hypogonadal ( $300 \text{ ng dl}^{-1} \leq T \leq 350 \text{ ng dl}^{-1}$ ), and hypogonadal ( $T < 300 \text{ ng dl}^{-1}$ ), respectively. Infertility was primary in 76 (54.3%) patients. Median T and  $T_{\text{free}}$  increased by 44.3% ( $P < 0.001$ ) (Table 2). Testicular volume increased significantly bilaterally by at least 12.5% (Table 2). Whereas median sperm concentration increased by 37.3% ( $P < 0.03$ ), motility, Kruger, and World Health Organization (WHO) morphology were virtually unchanged (Table 2).

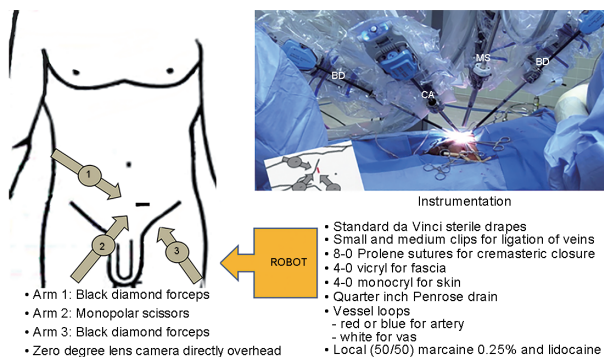
Operative time was recorded in our first 69 cases and compared to TMV. Operative time per side was  $49 \pm 13$  min and  $57 \pm 16$  min for TMV and RMV, respectively, reflecting our learning curve and reaching its nadir at 15 cases. For a bilateral case, robotic dock time averaged  $39 \pm 9$  min. Throughout our series, we had 9/258 complications (3.5%) including 7 (2.7%) hematomas and 2 (0.8%) hydroceles. There were no injuries to the vas deferens or testicular artery on any of the testicular units (Table 3). All of these complications were managed conservatively. Persistent venous flow on postoperative ultrasound was seen in 9.7% (25) of testicular though dramatically reduced (Table 2). Intraoperatively with direct visualization, one testicular artery was identified on 80.7% of testicular units, two arteries on 15.2%, and three arteries on 4.1%. Postoperatively, only 37.3% patients used pain medications  $>24$  h.

## DISCUSSION

We describe our series of RAMV on 140 infertile men, a subset of our larger series. As can be seen from the baseline characteristics, this represents a highly select group of men. With the robotic approach, complication rates were low without any injury to testicular arteries. Minimal persistent flow demonstrated that duplex Doppler was seen in 9.6% of testicular units. Serum T significantly improved.

The incidence of bilaterality of varicoceles in this series is higher than other varicocele surgical series and is most likely a reflection of the author's referral pattern and the use of reflux on ultrasound as a criterion for surgical candidacy. Our high percentage of bilaterality has been previously reported. In a study by Gat *et al.*,<sup>28</sup> 81% of 286 infertile men were confirmed to have bilateral disease by venography. Whereas physical examination detected right-sided varicoceles in 7.3% of men, Doppler ultrasound detected right-sided varicoceles in 66%.<sup>28</sup>

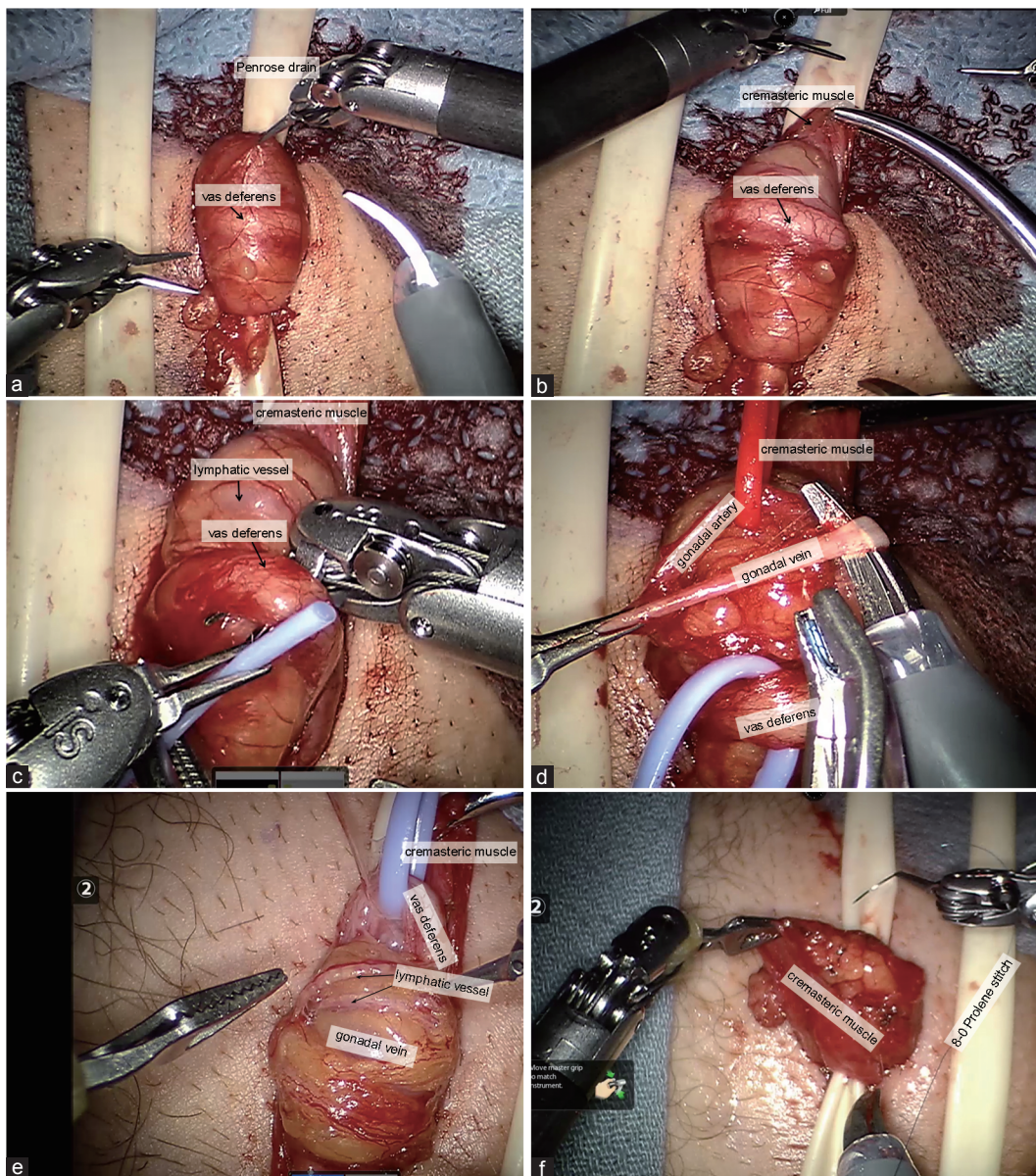




**Figure 1:** Schematic of robot docking position, actual docked robot and instrumentation required. BD: black diamond forceps; CA: zero-degree lens camera; MS: monopolar scissors.

Testis duplex Doppler ultrasonography has 97% sensitivity and 94% specificity when compared to venography, the more invasive “gold standard” for the diagnosis of varicoceles.<sup>29</sup> The European Association of Urology (EAU) guidelines support the use of testis Doppler ultrasound to determine the presence of varicocele and reflux.<sup>30</sup> It is the authors’ opinion that the lack of objectivity in the diagnosis of varicoceles pre- and post-operatively may be contributory to the inconsistent results reported about benefits of varicocele surgery in the literature. The reliance on a classification system described in 1971<sup>31</sup> may be anachronistic in the era of sophisticated and more objective ultrasound imagery.

Most of the men with Doppler documented in our study, did, in fact, have clinical preoperative varicoceles, though the comparison of the clinical versus ultrasound diagnosis was not the objective of the paper.



**Figure 2:** Robotic-assisted microsurgical varicocelectomy surgery. (a) Cord is exposed and suspended extracorporeally with Penrose. (b) Cremasteric muscle fastened to Penrose exposing the vas deferens. (c) Vas being isolated with vessel loop. (d) Vein being isolated with artery and vas identified and individually retracted. (e) Identification and preservation of lymphatic. (f) Closure of cremasteric with 8-0 sutures.

Our recurrence rate is higher than previously reported in series. In our series, we found a 9.6% “failure rate.” This is higher than previously reported for microsurgical subinguinal repair 1.4%,<sup>32</sup> 3%,<sup>33</sup> 2%,<sup>34</sup> 0.82%,<sup>35</sup> and 1.05%.<sup>22</sup> As the presence of documentable venous reflux was a preoperative criterion, we defined recurrence as any measurable postoperative retrograde flow which may account for our higher recurrence rate. As shown in **Table 2**, our residual venous flow is extremely low. Other microsurgical subinguinal series use clinically detectable varicoceles as the definition of success. In addition to the lower sensitivity of clinical examination in the detection of varicoceles, the clinical examination of varicoceles as a postoperative end point is subjective and operator dependent and has never been intra- or inter-observer critically validated.<sup>36</sup>

Our observed T changes are similar to previously published studies involving TMV (**Table 3**). Chan *et al.*<sup>12</sup> reviewed their series of 2012 men who underwent subinguinal TMV. They observed an increased mean T from 362 ng dl<sup>-1</sup> to 493 ng dl<sup>-1</sup>. Hsiao *et al.*<sup>13</sup> noted a similar increase in T from 309 to 431 ng dl<sup>-1</sup> in men with preoperative

T <400 ng dl<sup>-1</sup>. Both of these studies included patients with subinguinal TMV only. Patients were evaluated for symptomatic varicoceles or for infertility in these studies. A meta-analysis by Li *et al.*<sup>14</sup> showed increase in T by 97.5 ng dl<sup>-1</sup> in 814 patients in nine studies. Most, but not all (6 out of 9), of the studies exclusively included subinguinal TMV and have increases in T similar to our findings (**Table 3**).

Two prospective randomized controlled trials showed increased mean sperm concentration after subinguinal TMV by 14.1 × 10<sup>6</sup> and 7.4 × 10<sup>6</sup> ml<sup>-1</sup>.<sup>15,26</sup> A large meta-analysis of 22 studies with various techniques by Baazeem *et al.*<sup>18</sup> showed a significant increase in concentration by 12.3 × 10<sup>6</sup> ml<sup>-1</sup>. Similarly, another meta-analysis observed an increase in concentration by 13.7 × 10<sup>6</sup> ml<sup>-1</sup>; however, this was not statistically significant. This meta-analysis incorporated 3 randomized controlled trials and 4 nonrandomized trials, using various varicocelelectomy techniques.<sup>19</sup> These prospective studies demonstrate findings similar to our mean sperm concentration increase of 14.7 × 10<sup>6</sup> ml<sup>-1</sup> (16.9 × 10<sup>6</sup> ± 23.4 × 10<sup>6</sup> vs 31.6 × 10<sup>6</sup> ± 66.5 × 10<sup>6</sup> ml<sup>-1</sup>).

We observed a significant increase in testicular size bilaterally based on testicular ultrasonography performed by a single ultrasonographer, pre- and post-operatively. A previously reported study examined the change in testicular volume in 44 men after varicocelelectomy and demonstrated an increase of 1.5 ml.<sup>17</sup> While 25 out of 44 of their patients underwent bilateral varicocelelectomy, 21 underwent subinguinal TMV, 17 underwent laparoscopic varicocelelectomy, and 6 underwent sclerotherapy. The study included a population of various techniques and a higher proportion of unilateral repairs; however, it is the only study evaluating testicular size in adults with a portion of patients who underwent subinguinal TMV. Zucchi *et al.*<sup>20</sup> demonstrated only a 0.6 ml increase in testicular size in 43 patients who underwent either sclerotherapy or open inguinal approach. The various surgical techniques, patient selection, and the methodology of testicular size measurement might explain inconsistent reported increases in testicular size.

Hydroceles were observed as 0.8%, which is comparable to other subinguinal TMV series showing 0.44%,<sup>22</sup> 0.4%,<sup>12</sup> 1.6%,<sup>37</sup> 0.3%,<sup>32</sup> and 0.2%<sup>35</sup> rates of postoperative hydroceles. Injury to the testicular artery

**Table 1: Baseline demographics and comorbidities in 140 infertile men with varicoceles**

Comorbidities	n (%)
Hypertension	6 (4.3)
Diabetes	3 (2.1)
Gastro esophageal reflux	7 (5.0)
Anxiety	1 (0.7)
Hyperlipidemia	9 (6.4)
Testis cancer	1 (0.7)
Past or alcohol abuse or alcoholism	21 (15.0)
Past illicit drug use	2 (1.4)
Past or present tobacco smoker	24 (17.1)
History of mumps orchitis	1 (0.7)
GU surgery (hernia repair, orchiopexy, orchiectomy)	28 (20.0)
Testosterone replacement	10 (7.1)

GU: genitourinary surgery

**Table 2: Comparison of pre- and post-operative hormone profile, semen analysis, and ultrasound parameters at 3 months in 140 infertile men with varicoceles**

Variables	Preoperative value (median)	95% CI	Postoperative value (median)	95% CI	P
<b>Hormone panel</b>					
Testosterone (ng dl <sup>-1</sup> )	327	328–378	472	434–521	<0.0001
Free testosterone (pg ml <sup>-1</sup> )	9.0	9.2–10.8	13.0	12.9–15.6	<0.0001
Estradiol (pg ml <sup>-1</sup> )	22.6	20.7–26.0	22.0	18.5–29.3	<0.64
LH (mIU ml <sup>-1</sup> )	4.8	4.7–5.7	5.6	5.7–7.4	<0.04
FSH (mIU ml <sup>-1</sup> )	6.0	6.7–8.8	8.4	8.8–11.8	<0.17
SHBG (mmole l <sup>-1</sup> )	23.8	23.5–28.6	23.4	21.9–27.5	<0.86
<b>Testis Doppler</b>					
Right testicle volume (ml)	19.1	17.2–19.5	21.5	20.1–23.1	<0.0006
Left testicle volume (ml)	17.9	16.5–18.5	21.9	20.4–23.2	<0.0001
Right testis PSV (m s <sup>-1</sup> )	0.06	0.05–0.08	0.0	0.02–0.05	<0.04
Left testis PSV (m s <sup>-1</sup> )	0.11	0.12–0.18	0.0	0.02–0.06	<0.0002
<b>Semen analysis</b>					
Semen volume (ml)	3.0	2.5–3.1	2.8	2.3–2.9	<0.32
Semen concentration (×10 <sup>6</sup> ml <sup>-1</sup> )	7.5	12.5–21.2	10.5	15.8–47.3	<0.03
Sperm motility (%)	30.0	26.7–35.5	23.1	24.4–36.6	<0.89
Sperm morphology, standard of WHO (%)	12.0	14.1–20.7	15	14.1–24.5	<0.52
Sperm morphology, standard of Krueger	1.0	1.0–1.9	0	0.6–1.7	<0.35

CI: confidence interval; FSH: follicle-stimulating hormone; LH: luteinizing hormone; PSV: peak systolic velocity; SHBG: sex hormone binding globulin; Krueger: Krueger strict morphology; WHO: World Health Organization





**Table 3: Comparison of robotic-assisted microsurgical varicocelectomy with subinguinal traditional microscopic varicocelectomy**

	RAMV (our series)	Subinguinal TMV (large cohort or meta-analysis)
Clinical outcomes		
Increase in mean testosterone (ng dl <sup>-1</sup> )	127	97, <sup>14</sup> 131, <sup>12</sup> 122 <sup>13</sup>
Increase in mean sperm concentration (×10 <sup>6</sup> ml <sup>-1</sup> )	14.8	14.1, <sup>15</sup> 7.4, <sup>26</sup> 12.3 <sup>18</sup>
Increase in mean adult left testis volume in adults (ml)	4.3	1.5 <sup>17</sup>
Patients requiring pain medicines (%)	37.3	37.5 <sup>16</sup>
Complications (%)		
Injury to testicular artery	0	0.9 <sup>12</sup>
Hydrocele	0.8	0.4 <sup>22</sup>
Failure/persistence	9.7	1.0–2.5 <sup>22,27</sup>
Hematoma	2.7	-

RAMV: robotic-assisted microscopic varicocelectomy; TMV: traditional microscopic varicocelectomy

is rare with no occurrences in our population. In a large series of over 2100 patients, injury occurred in only 0.9% of cases.<sup>12</sup> This slightly higher incidence is likely due to a larger study size compared to our series. In contrast to a smaller series of only 42 patients, one testicular artery injury occurred with immediate repair.<sup>38</sup> Only 37.3% of patients needed pain medication for more than 24 h postoperatively. This result is similar to another study evaluating postoperative pain requirements. Pan *et al.*<sup>16</sup> only had 37.5% of patients requiring pain medications in their series of subinguinal TMV.

The high capital cost of the DR is used as an argument against its use in the repair of varicoceles. Without a doubt the purchase costs for DR are more than an operating microscope (OM). From a practical viewpoint, unlike the OM, the DR is shared by all services. Frequently service-specific OMs differ in quality and features and are reluctantly shared. The urologic microsurgeon and operating room staff frequently have to familiarize themselves with a different microscope on the day of the procedure, decreasing OR efficiency. Admittedly the use of the robot precludes performing the procedure in outpatient surgery units, where the availability of the robot is unlikely. Although robot access for the urologic microsurgeon might be difficult, the relatively short length of the case makes it administratively attractive. The procedure-specific expenses for the RAMV are the 2 multiple use black diamond and monopolar scissors amounting to below US dollar \$1000 per procedure. The drapes are comparable to those used for the standard microsurgical or laparoscopic approach. This study is not intended to condone the purchase and use of the DR where one is not available or it is a demonstration of the feasibility of the technique, if one is available. A cost analysis was not performed in this study, but the surgeon encountered no administrative resistance in scheduling cases. In terms of surgical training, a typical urology resident is unlikely to use microsurgical skills achieved during residency after training. Few urology residents enter into the area of male infertility. On the other hand, robotic skills learned in residency will continued to be used in performing robotic prostatectomies, nephrectomies, or urogynecologic procedures. As resident staff is already familiar with the DR equipment, their learning curve for the procedure is likely less than standard microsurgery. It seems instinctive that the micro-robotic skills developed handling 8-0 and 9-0 sutures and isolating 1 mm gonadal arteries will only improve macro-robotic skills. Improvement in robotic skills was not evaluated in this study. Additional training may be required for a traditional microsurgeon to master the technique

with the DR, a problem faced by traditional open prostatectomists decades ago. Familiarity with microsurgical techniques and currently available training software were found to be of tremendous benefit to the surgeon (Andrew McCullough) in mastering the technique and minimizing the learning curve. Ergonomically there is no question that operating from a console is superior to the awkward position during a typical OM varicocelectomy. Surgeon fatigue for attending and resident is minimized.

Weaknesses of this study include the retrospective nature of the study and comparison to historical controls rather than a simultaneous comparison. As the hormone values were done at different reference laboratories, the reference ranges may be different from one patient to the next. Patients had follow-up hormonal studies done at the same laboratory that was used for the preoperative laboratories. Though pre- and post-operative semen analyses were always done at the same IVF Andrology laboratory, no attempt was made to standardize the analyses between the two centers. Laboratories were done as the specifications and standards of the American Society for Reproductive Medicine.

Strengths were the rigorous clinical follow-up and use of also used Doppler ultrasound pre- and post-operatively to evaluate outcomes.

## CONCLUSION

This study demonstrates that RAMV is comparable to subinguinal TMV. RAMV can be used as an alternative to TMV where a robot is available without compromise of patient care. More prospective studies are needed to evaluate cost differentials and the benefits to resident training.

## AUTHOR CONTRIBUTIONS

AM came up with study concept, worked as principal surgeon, collected data, performed statistical analysis, and prepared manuscript. LE performed testicular ultrasounds. JE worked as surgical assistant, collected data, and reviewed manuscript. CM collected data, performed statistical analysis, and reviewed manuscript. All authors read and approved the final manuscript.

## COMPETING INTERESTS

All authors declare no competing interests.

## ACKNOWLEDGMENTS

We would like to thank Barry Kogan and Sijo Parekattil for their support, encouragement, and guidance.

## REFERENCES

- Clarke BG. Incidence of varicocele in normal men and among men of different ages. *JAMA* 1966; 198: 1121–2.
- Greenberg SH, Lipshultz LI, Wein AJ. Experience with 425 subfertile male patients. *J Urol* 1978; 119: 507–10.
- WHO. The influence of varicocele on parameters of fertility in a large group of men presenting to infertility clinics. World Health Organization. *Fertil Steril* 1992; 57: 1289–93.
- Comhaire F, Vermeulen A. Varicocele sterility: cortisol and catecholamines. *Fertil Steril* 1974; 25: 88–95.
- Reyes JG, Farias JG, Henriquez-Olavarrieta S, Madrid E, Parraga M, *et al*. The hypoxic testicle: physiology and pathophysiology. *Oxid Med Cell Longev* 2012; 2012: 929285.
- Hadziselimovic F, Leibundgut B, Da Rugna D, Buser MW. The value of testicular biopsy in patients with varicocele. *J Urol* 1986; 135: 707–10.
- Goldstein M, Eid JF. Elevation of intratesticular and scrotal skin surface temperature in men with varicocele. *J Urol* 1989; 142: 743–5.
- Aitken RJ, Clarkson JS, Hargreave TB, Irvine DS, Wu FC. Analysis of the relationship between defective sperm function and the generation of reactive oxygen species in cases of oligozoospermia. *J Androl* 1989; 10: 214–20.



- 9 Alvarez JG, Touchstone JC, Blasco L, Storey BT. Spontaneous lipid peroxidation and production of hydrogen peroxide and superoxide in human spermatozoa. Superoxide dismutase as major enzyme protectant against oxygen toxicity. *J Androl* 1987; 8: 338–48.
- 10 Lopes S, Jurisicova A, Sun JG, Casper RF. Reactive oxygen species: potential cause for DNA fragmentation in human spermatozoa. *Hum Reprod* 1998; 13: 896–900.
- 11 Twigg J, Fulton N, Gomez E, Irvine DS, Aitken RJ. Analysis of the impact of intracellular reactive oxygen species generation on the structural and functional integrity of human spermatozoa: lipid peroxidation, DNA fragmentation and effectiveness of antioxidants. *Hum Reprod* 1998; 13: 1429–36.
- 12 Chan PT, Wright EJ, Goldstein M. Incidence and postoperative outcomes of accidental ligation of the testicular artery during microsurgical varicocelectomy. *J Urol* 2005; 173: 482–4.
- 13 Hsiao W, Rosoff JS, Pale JR, Greenwood EA, Goldstein M. Older age is associated with similar improvements in semen parameters and testosterone after subinguinal microsurgical varicocelectomy. *J Urol* 2011; 185: 620–5.
- 14 Li F, Yue H, Yamaguchi K, Okada K, Matsushita K, *et al*. Effect of surgical repair on testosterone production in infertile men with varicocele: a meta-analysis. *Int J Urol* 2012; 19: 149–54.
- 15 Abdel-Meguid TA, Al-Sayyad A, Tayib A, Farsi HM. Does varicocele repair improve male infertility? An evidence-based perspective from a randomized, controlled trial. *Eur Urol* 2011; 59: 455–61.
- 16 Pan F, Pan L, Zhang A, Liu Y, Zhang F, Dai Y. Comparison of two approaches in microsurgical varicocelectomy in Chinese infertile males. *Urol Int* 2013; 90: 443–8.
- 17 Sakamoto H, Saito K, Ogawa Y, Yoshida H. Effects of varicocele repair in adults on ultrasonographically determined testicular volume and on semen profile. *Urology* 2008; 71: 485–9.
- 18 Baazeem A, Belzile E, Ciampi A, Dohle G, Jarvi K, *et al*. Varicocele and male factor infertility treatment: a new meta-analysis and review of the role of varicocele repair. *Eur Urol* 2011; 60: 796–808.
- 19 Zhou T, Zhang W, Chen Q, Li L, Cao H, *et al*. Effect of varicocelectomy on testis volume and semen parameters in adolescents: a meta-analysis. *Asian J Androl* 2015; 7: 1012–6.
- 20 Zucchi A, Mearini L, Mearini E, Fioretti F, Bini V, *et al*. Varicocele and fertility: relationship between testicular volume and seminal parameters before and after treatment. *J Androl* 2006; 27: 548–51.
- 21 Shridharani A, Lockwood G, Sandlow J. Varicocelectomy in the treatment of testicular pain: a review. *Curr Opin Urol* 2012; 22: 499–506.
- 22 Cayan S, Shavakhabov S, Kadioglu A. Treatment of palpable varicocele in infertile men: a meta-analysis to define the best technique. *J Androl* 2009; 30: 33–40.
- 23 Shu T, Taghechian S, Wang R. Initial experience with robot-assisted varicocelectomy. *Asian J Androl* 2008; 10: 146–8.
- 24 Parekattil SJ, Gudeloglu A. Robotic assisted andrological surgery. *Asian J Androl* 2013; 15: 67–74.
- 25 Lambert B. The frequency of mumps and of mumps orchitis and the consequences for sexuality and fertility. *Acta Genet Stat Med* 1951; 2: 1–166.
- 26 Abdel-Maguid AF, Othman I. Microsurgical and nonmagnified subinguinal varicocelectomy for infertile men: a comparative study. *Fertil Steril* 2010; 94: 2600–3.
- 27 Rotker K, Sigman M. Recurrent varicocele. *Asian J Androl* 2016; 18: 229–33.
- 28 Gat Y, Bachar GN, Everaert K, Levinger U, Gornish M. Induction of spermatogenesis in azoospermic men after internal spermatic vein embolization for the treatment of varicocele. *Hum Reprod* 2005; 20: 1013–7.
- 29 Belay RE, Huang GO, Shen JK, Ko EY. Diagnosis of clinical and subclinical varicocele: how has it evolved? *Asian J Androl* 2016; 18: 182–5.
- 30 Jungwirth A, Giwercman A, Tournaye H, Diemer T, Kopa Z, *et al*. European association of urology guidelines on male infertility: the 2012 update. *Eur Urol* 2012; 62: 324–32.
- 31 Dubin L, Amelar RD. Varicocele size and results of varicocelectomy in selected subfertile men with varicocele. *Fertil Steril* 1970; 21: 606–9.
- 32 Jungwirth A, Gogus C, Hauser G, Gomahr A, Schmeller N, *et al*. Clinical outcome of microsurgical subinguinal varicocelectomy in infertile men. *Andrologia* 2001; 33: 71–4.
- 33 Orhan I, Onur R, Semercioz A, Firdolas F, Ardicoglu A, *et al*. Comparison of two different microsurgical methods in the treatment of varicocele. *Arch Androl* 2005; 51: 213–20.
- 34 Kumar R, Gupta NP. Subinguinal microsurgical varicocelectomy: evaluation of the results. *Urol Int* 2003; 71: 368–72.
- 35 Marmar JL, Kim Y. Subinguinal microsurgical varicocelectomy: a technical critique and statistical analysis of semen and pregnancy data. *J Urol* 1994; 152: 1127–32.
- 36 Lund L, Roebuck DJ, Lee KH, Sorensen HT, Yeung CK. Clinical assessment after varicocelectomy. *Scand J Urol Nephrol* 2000; 34: 119–22.
- 37 Ghanem H, Anis T, El-Nashar A, Shamloul R. Subinguinal microvaricocelectomy versus retroperitoneal varicocelectomy: comparative study of complications and surgical outcome. *Urology* 2004; 64: 1005–9.
- 38 Leung L, Ho KL, Tam PC, Yiu MK. Subinguinal microsurgical varicocelectomy for male factor subfertility: ten-year experience. *Hong Kong Med J* 2013; 19: 334–40.

This is an open access article distributed under the terms of the Creative Commons Attribution-NonCommercial-ShareAlike 3.0 License, which allows others to remix, tweak, and build upon the work non-commercially, as long as the author is credited and the new creations are licensed under the identical terms.

©The Author(s)(2017)

