

***Clostridium paraputrificum* septicemia and liver abscess**

Yong K Kwon, Faiqa A Cheema, Bejon T Maneckshana, Caroline Rochon, Patricia A Sheiner

Yong K Kwon, Faiqa A Cheema, Bejon T Maneckshana, Caroline Rochon, Patricia A Sheiner, Department of Transplant, Hartford Hospital, Hartford, CT 06106, United States

ORCID number: Yong K Kwon (0000-0002-6026-5532); Faiqa A Cheema (0000-0002-8837-0916); Bejon T Maneckshana (0000-0002-5583-557X); Caroline Rochon (0000-0002-8338-3216); Patricia A Sheiner (0000-0002-5562-6698).

Author contributions: Kwon YK and Cheema FA wrote the initial manuscript; Maneckshana BT, Rochon C and Sheiner PA performed a literature search and analyzed the data; all authors contributed equally to editing and revising the final manuscript.

Informed consent statement: Written informed consent and permission to write this manuscript was obtained from the patient of this case report.

Conflict-of-interest statement: The authors certify that we have no conflict of interest to disclose and did not receive any financial support for this study.

Open-Access: This article is an open-access article which was selected by an in-house editor and fully peer-reviewed by external reviewers. It is distributed in accordance with the Creative Commons Attribution Non Commercial (CC BY-NC 4.0) license, which permits others to distribute, remix, adapt, build upon this work non-commercially, and license their derivative works on different terms, provided the original work is properly cited and the use is non-commercial. See: <http://creativecommons.org/licenses/by-nc/4.0/>

Manuscript source: Unsolicited manuscript

Correspondence to: Yong K Kwon, MD, Assistant Professor of Surgery, Department of Transplant, Hartford Hospital, 85 Seymour Street, Suite 320, Hartford, CT 06106, United States. yong.kwon@hhchealth.org
Telephone: +1-860-6962030
Fax: +1-860-5491476

Received: December 19, 2017
Peer-review started: December 20, 2017
First decision: January 23, 2018
Revised: January 30, 2018
Accepted: March 1, 2018
Article in press: March 1, 2018

Published online: March 27, 2018

Abstract

We report the first case of a healthy 23-year-old female who underwent an interventional radiology-guided embolization of a hepatic adenoma, which resulted in a gas forming hepatic liver abscess and septicemia by *Clostridium paraputrificum*. A retrospective review of Clostridial liver abscesses was performed using a PubMed literature search, and we found 57 clostridial hepatic abscess cases. The two most commonly reported clostridial species are *C. perfringens* and *C. septicum* (64.9% and 17.5% respectively). *C. perfringens* cases carried a mortality of 67.6% with median survival of 11 h, and 70.2% of the *C. perfringens* cases experienced hemolysis. All *C. septicum* cases were found to have underlying liver malignancy at the time of the presentation with a mortality of only 30%. The remaining cases were caused by various *Clostridium* species, and this cohort's clinical course was significantly milder when compared to the above *C. perfringens* and *C. septicum* cohorts.

Key words: *Clostridium*; Hemolysis; Liver cell adenoma; Morbidity; Mortality; Pyogenic liver abscess

© **The Author(s) 2018.** Published by Baishideng Publishing Group Inc. All rights reserved.

Core tip: To our best knowledge, this is the first case where a liver abscess grew *C. paraputrificum*. Although pyogenic liver abscesses caused by *Clostridium* species are extremely rare, early and accurate diagnosis of clostridial hepatic abscess and timely interventions are paramount, as it carries an extremely high morbidity and mortality. However, depending on the exact causative *Clostridium* species, the clinical course can vary unexpectedly.

Kwon YK, Cheema FA, Maneckshana BT, Rochon C, Sheiner

PA. *Clostridium paraputrificum* septicemia and liver abscess. *World J Hepatol* 2018; 10(3): 388-395 Available from: URL: <http://www.wjgnet.com/1948-5182/full/v10/i3/388.htm> DOI: <http://dx.doi.org/10.4254/wjgh.v10.i3.388>

INTRODUCTION

Pyogenic liver abscesses caused by *Clostridium* species are extremely rare^[1], and only 57 cases have been reported in the English medical literature (Table 1). *C. perfringens* was responsible for more than a half of these reported cases. This species carries an extremely high mortality rate, especially when associated with hemolysis^[2-4]. The previously reported 20 *C. perfringens* cases showed a median age of 65 years at the time of presentation^[5]. Advanced age, underlying malignancy, liver cirrhosis, and immunocompromised conditions including dialysis, transplant and diabetes mellitus were identified as risk factors^[2,5-8]. Here we present a very unusual case of a healthy 23-year-old female who underwent interventional radiology (IR) embolization for a hepatic adenoma and presented within 24 h with a gas forming hepatic liver abscess and septicemia. Due to the extremely rapid clinical presentation where the embolized tumor was completely replaced by a gas forming abscess within a day, *C. perfringens* was suspected as the causative organism. Unlike many other fatal *C. perfringens* hepatic abscess cases, our patient did not have any signs of hemolysis nor experienced any end-organ failure. Future speciation work-up revealed *C. paraputrificum*. There have been five case reports of septicemia caused by *C. paraputrificum*^[9-13]. However, this is the first case of a gas forming hepatic abscess.

CASE REPORT

A 23-year-old healthy female with obesity (body mass index of 37 kg/m²) and Polycystic Ovarian Syndrome on oral contraceptive pills was evaluated for intermittent, right upper quadrant abdominal pain. She was found to have a hepatic adenoma measuring 5.2 cm × 3.3 cm × 6.6 cm abutting the liver capsule in segment 7 (Figure 1) on imaging. The patient's oral contraceptive pill was discontinued for the more than three months, since the adenoma was diagnosed. A repeat computerized tomography (CT) scan did not show regression of the mass (Figure 2). Due to ongoing intractable abdominal right upper quadrant pain and risk of potential rupture, a surgical resection was presented as an option vs IR-guided embolization as an alternative option given her body habitus and fatty liver on magnetic resonance imaging study. The patient elected to proceed with IR embolization.

Angiogram showed conventional hepatic artery anatomy, and the adenoma was exclusively fed by a

single branch coming off of the posterior right hepatic artery (Figure 3). The tumor was completely embolized with 100-300 μm trisacryl gelatin microspheres (Embosphere®, Merit Medical Systems, Inc., South Jordan, United States). The patient was discharged home the same day.

The next day, the patient began to experience a rapid onset of right upper abdominal pain, nausea, vomiting and fever of 101.5 °F. In the emergency room, the patient was tachycardic with a heart rate in the 120 s. She experienced right upper abdominal tenderness on physical exam. Blood tests showed a white blood cell (WBC) count of 16.4 Thou/μL, a lactic acid of 2.4 nmol/L, a serum aspartate transaminase (AST) of 671 U/L, a serum alanine transaminase (ALT) of 310 U/L, and a total bilirubin (T. bili) of 1.4 mg/dL. A CT scan showed the embolized tumor in segment 7 completely replaced with multiple gas pockets (Figure 4). A set of blood cultures was sent, and the patient was started on vancomycin, levofloxacin and metronidazole (patient has a penicillin allergy). The next day, the set of blood cultures grew gram positive rods. The patient's serum WBC was elevated to 25 Thou/μL. Later that day, the preliminary blood culture revealed *clostridium* species. With ongoing fever and the newly diagnosed *clostridium* species infection, a repeat CT scan was performed to rule out potential life threatening gas gangrene. The repeat CT scan showed no changes.

The patient remained persistently febrile, despite antibiotic therapy and subsequent blood cultures showing no growth. The culture speciation showed *Clostridium paraputrificum* and no other organisms were isolated. Despite improving leukocytosis, an IR-guided drain was placed on hospital day 10 due to the persistent fevers. One hundred and twenty cc of dark turbid sterile fluid was aspirated, and the gram stain showed many neutrophils. No bacteria were isolated. Aspirin was started because the patient's platelet count rose above 500 Thou/μL. Over the next a few days since the drain placement, the fluid character became less turbid. However, the color became frankly bilious. The daily drain output persistently remained less than 200 cc, indicating a low output bile leak. Thus an ERCP was not performed. On Hospital day 16, the patient was afebrile for the first time. The patient was discharged home on hospital day 17 since the patient was afebrile for 48 hours. At the time of discharge, the drain output was less than 100 cc per day and the patient was discharged on oral metronidazole only.

The patient presented two weeks after discharge with a follow-up CT, which revealed a significantly reduced gas filled abscess cavity (Figure 5). The IR drain was taken out as the daily output remained minimum, less than 5 cc per day. Oral metronidazole was continued for two more weeks post drain removal. Upon completion of the antibiotic course, blood tests showed a WBC of 9.5 Thou/μL, a platelet count of 379 Thou/μL, an AST of 27 U/L, an ALT of 30 U/L, and a T. bili of 0.6 mg/dL.

Table 1 Fifty-seven reported clostridial hepatic abscess cases in the English medical literature

Case	Author	Year	Age	Sex	Species	Underlying disease	HML	SSE	TTD	PLM	PMI
1	Fiese ^[35]	1950	67	M	<i>C. perfringens</i>	Cholecystitis	No	Yes	-	No	Yes
2	Kivel et al ^[36]	1958	68	F	<i>C. perfringens</i>	DM	Yes	No	5 d	No	No
3	Kahn et al ^[37]	1972	44	F	<i>C. septicum</i>	Colon cancer	No	Yes	-	Yes	Yes
4	D'Orsi et al ^[38]	1979	52	F	<i>C. septicum</i>	Colon cancer	No	Yes	-	Yes	No
5	D'Orsi et al ^[38]	1979	51	F	<i>C. ramosum</i>	Melanoma	Yes	No	2 d	Yes	No
6	D'Orsi et al ^[38]	1979	29	M	<i>C. ramosum</i> , <i>C. sporogenes</i>	Peri-ampullaryCa	No	Yes	-	Yes	Yes
7	Mera et al ^[39]	1984	6	F	<i>C. perfringens</i>	Fanconi's anemia	Yes	No	14 h	No	No
8	Nachman et al ^[40]	1989	6	M	<i>C. bifermentans</i>	Blunt trauma	No	Yes	-	No	No
9	Yood et al ^[41]	1989	64	F	<i>C. perfringens</i>	Systemic vasculitis	No	Yes	-	No	No
10	Batge et al ^[42]	1992	61	M	<i>C. perfringens</i>	Pancreatic cancer, DM	Yes	Yes	-	No	No
11	Rogstad et al ^[43]	1993	61	M	<i>C. perfringens</i>	None	Yes	No	3 h	No	No
12	Thel et al ^[32]	1994	39	F	<i>C. septicum</i>	Breast Ca, Bone M. txp	No	Yes	-	Yes	No
13	Gutierrez et al ^[44]	1995	74	M	<i>C. perfringens</i>	None	Yes	No	6 h	No	No
14	Jones et al ^[45]	1996	66	F	<i>C. perfringens</i>	OLT, DM	Yes	No	10 h	No	No
15	Lee et al ^[34]	1999	33	F	<i>C. septicum</i>	Uterine cancer	No	Yes	-	Yes	No
16	Eckel et al ^[46]	2000	65	F	<i>C. perfringens</i>	Cholangiocarcinoma	Yes	Yes	-	Yes	Yes
17	Urban et al ^[47]	2000	68	M	<i>C. septicum</i>	Colon cancer	No	Yes	-	Yes	No
18	Sakurai et al ^[48]	2001	75	F	<i>C. difficile</i>	Hepatic cyst	No	Yes	-	Yes	No
19	Kreidl et al ^[8]	2002	80	M	<i>C. perfringens</i>	DM, dialysis	Yes	No	11 h	No	No
20	Sarmiento et al ^[49]	2002	57	M	<i>C. septicum</i>	Colon cancer	No	Yes	-	Yes	No
21	Hsieh et al ^[50]	2003	23	M	Unusual <i>C. spp.</i>	Blunt trauma	No	Yes	-	No	No
22	Quigley et al ^[51]	2003	73	M	<i>C. perfringens</i>	Hepatic cyst	-	No	0 h	Yes	Yes
23	Elsayed et al ^[52]	2004	27	M	<i>C. hathewayi</i>	Cholecystitis	No	Yes	-	No	No
24	Fondran et al ^[53]	2005	63	M	<i>C. perfringens</i>	Pancreatic cancer	No	Yes	-	Yes	Yes
25	Au et al ^[7]	2005	65	M	<i>C. perfringens</i>	DM, dialysis	Yes	No	3 h	No	No
26	Kurtz et al ^[54]	2005	50	F	<i>C. septicum</i>	Colon cancer	No	Yes	-	Yes	No
27	Ohtani et al ^[55]	2006	78	M	<i>C. perfringens</i>	DM	Yes	No	3 h	No	No
28	Daly et al ^[56]	2006	80	M	<i>C. perfringens</i>	DM	Yes	No	3 h	No	No
29	Loran et al ^[57]	2006	69	F	<i>C. perfringens</i>	None	Yes	No	6 h	No	No
30	Chiang et al ^[58]	2007	46	F	<i>C. perfringens</i>	Cholecystitis	No	No	7 d	No	No
31	Abdel-Haq et al ^[59]	2007	11	M	<i>C. novyi type B</i>	Blunt trauma	No	Yes	-	No	No
32	Umgelter et al ^[60]	2007	87	F	<i>C. perfringens</i>	Colon cancer	No	Yes	-	Yes	No
33	Tabarelli et al ^[61]	2009	65	F	<i>C. perfringens</i>	Pancr. Ca s/p whipple	No	No	27 d	No	Yes
34	Merino et al ^[62]	2009	83	F	<i>C. perfringens</i>	None	Yes	No	3 d	No	No
35	Saleh et al ^[63]	2009	53	M	<i>C. septicum</i>	Colon cancer	No	Yes	-	Yes	No
36	Meyns et al ^[64]	2009	64	M	<i>C. perfringens</i>	DM	Yes	No	2 d	No	No
37	Ng et al ^[4]	2010	61	F	<i>C. perfringens</i>	DM	Yes	Yes	-	No	Yes
38	Rajendran et al ^[65]	2010	58	M	<i>C. perfringens</i>	None	Yes	Yes	-	No	No
39	Bradly et al ^[66]	2010	52	M	<i>C. perfringens</i>	OLT	Yes	No	6 h	No	No
40	Ogah et al ^[67]	2012	6	F	<i>C. clostridioforme</i>	None	No	Yes	-	No	No
41	Qandeel et al ^[68]	2012	59	M	<i>C. perfringens</i>	DM, s/p elective chole	Yes	Yes	-	No	No
42	Kim et al ^[69]	2012	80	F	<i>C. perfringens</i>	Hilar cholangiocarcinoma	No	No	3 d	No	Yes
43	Huang et al ^[70]	2012	54	M	<i>C. baratii</i>	Cholecystitis	No	Yes	-	No	No
44	Sucandy et al ^[71]	2012	65	M	<i>C. septicum</i>	Colon cancer	No	No	2 d	Yes	No
45	Law et al ^[5]	2012	50	F	<i>C. perfringens</i>	Rectal cancer	Yes	No	7 d	Yes	No
46	Raghavendra et al ^[72]	2013	63	M	<i>C. septicum</i>	Colon cancer	No	Yes	-	Yes	No
47	Kitterer et al ^[73]	2014	71	M	<i>C. perfringens</i>	OLT, Gastroenteritis	Yes	No	13 h	No	No
48	Imai et al ^[74]	2014	76	M	<i>C. perfringens</i>	None	Yes	No	6.5 h	No	No
49	Kurasawa et al ^[2]	2014	65	M	<i>C. perfringens</i>	DM	Yes	No	6 h	No	No
50	Eltawansy et al ^[75]	2015	81	F	<i>C. perfringens</i>	DM, Gastroenteritis	No	No	N/A ¹	No	Yes
51	Li et al ^[76]	2015	71	M	<i>C. perfringens</i>	HCC, Hepatitis B	Yes	Yes	-	Yes	No
52	Rives et al ^[77]	2015	63	M	<i>C. perfringens</i>	Colon cancer	No	Yes	-	Yes	No
53	Lim et al ^[6]	2016	58	M	<i>C. perfringens</i>	None	Yes	No	7.5 h	No	No
54	Hashiba et al ^[78]	2016	82	M	<i>C. perfringens</i>	DM	Yes	No	2 h	No	No
55	Kyang et al ^[79]	2016	84	M	<i>C. perfringens</i>	Gastric adenoCA	No	Yes	-	Yes	Yes
56	Ulger et al ^[80]	2016	80	F	<i>C. difficile</i>	DM	No	No	18 d	No	No
57	García et al ^[81]	2016	65	M	<i>C. perfringens</i>	DM	Yes	Yes	-	No	Yes

¹Exact time of TTD was not discussed, but terminal vent weaning was initiated and subsequently expired. HML: Hemolysis; SSE: Survival of septic episode; TTD: Time to death; PLM: Presence of liver mass; PMI: Polymicrobial infection.

DISCUSSION

Pyogenic liver abscess (PLA) is an uncommon disease. Various incidences have been reported throughout the

world: 1.1 in Denmark^[14], 2.3 in Canada^[15] and 17.6 per 100000 population in Taiwan^[16]. In the United States, the incidence is 3.6 per 100000 population with a reported in-hospital mortality rate of 5.6%^[17].

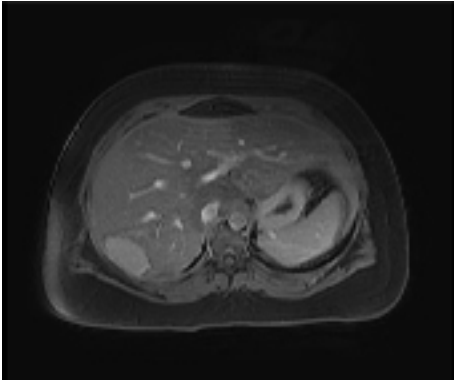


Figure 1 Magnetic resonance imaging of the segment 7 hepatic adenoma measuring 5.2 cm x 3.3 cm x 6.6 cm.

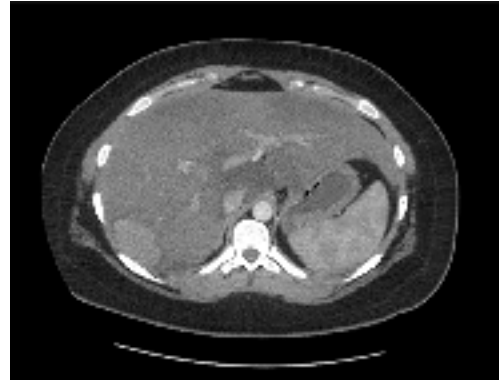


Figure 2 Computed tomography after stopping oral contraceptive pills for 3 mo. No change in size.

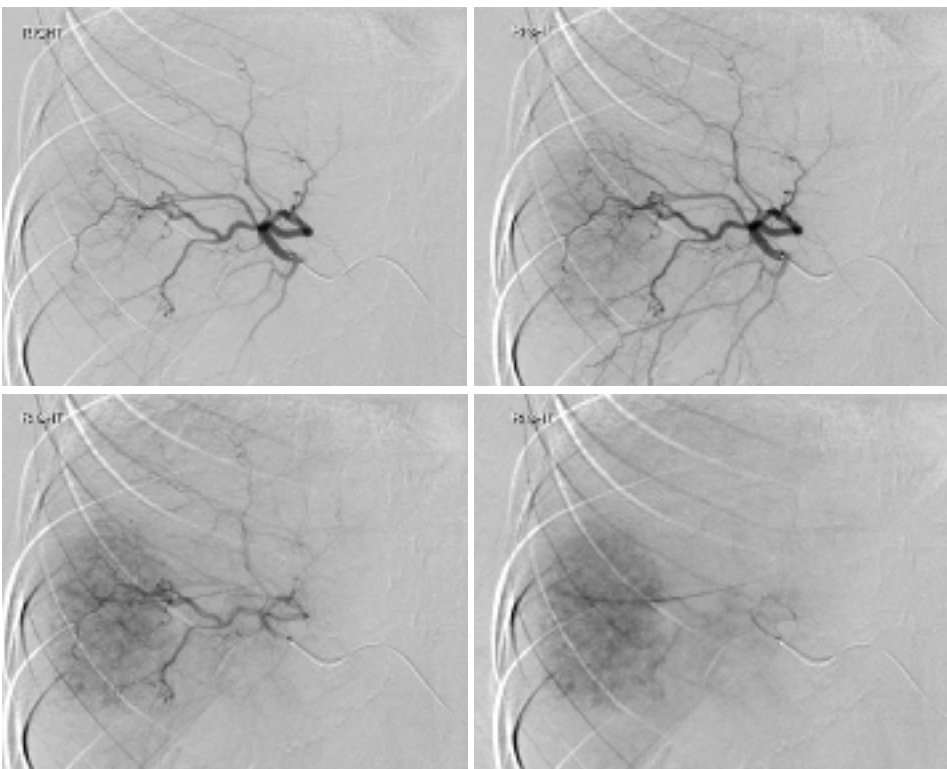


Figure 3 Interventional radiology angiogram of the hepatic adenoma.

The incidences of gas forming pyogenic liver abscess (GFPLA), also known as emphysematous liver abscess, are even rarer, contributing 6.6% to 32% of PLA^[16,18-21]. It carries a significantly higher mortality rate, 27.7% to 37.1%^[22-25]. For those who presented with GFPLA, their incidence of septic shock was higher (32.5% vs 11.7%) and they presented with a shorter duration of symptoms (5.2 d vs 7.6 d) when compared to those who presented with non-gas forming pyogenic liver abscess (NGFPLA)^[22].

The single strongest risk factor for GFPLA appears to be the presence of diabetes and poorly controlled blood glucose^[15,18,22]. According to a case report series done in Taiwan which compared 83 patients with GFPLA against 341 NGFPLA patients, 85.5% of

those with GFPLA had diabetes mellitus with an initial glucose level of 383.0 ± 167.7 (mg/dL) vs 33.1% with an initial glucose level of 262.6 ± 158.0 (mg/dL)^[22]. Similar findings were reported from another single center series from South Korea, where 76% (19 out of 25) were found to have diabetes when comparing 25 patients with GFPLA against 354 NGFPLA patients^[18]. The most common causative organism for GFPLA was *Klebsiella pneumoniae* contributing 77% to 88%^[18,22,25]. *Escherichia*, *Streptococcus*, *Enterococcus*, *Pseudomonas*, *Morganella*, *Enterobacter*, *Serratia*, *Bacteroides* and *Clostridium* species were responsible for the remaining^[22].

An extremely small portion of GFPLA is caused by clostridial species. The two most commonly reported

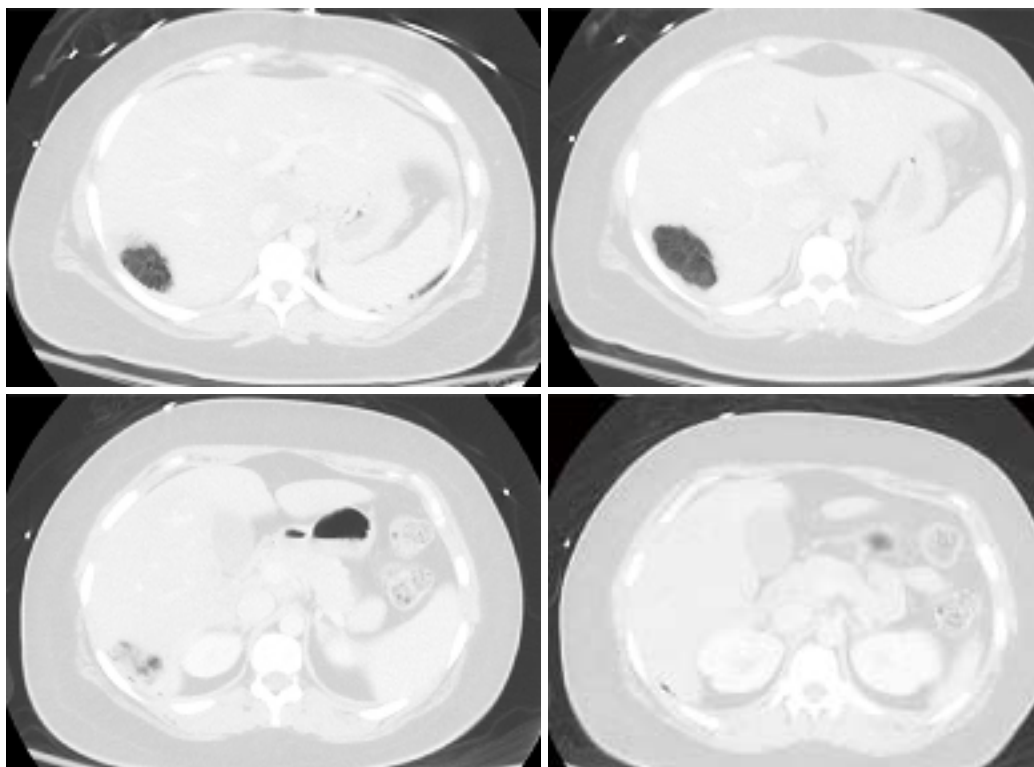


Figure 4 The tumor completely replaced by gas pockets.

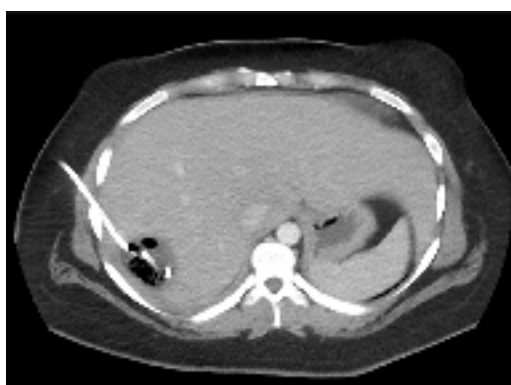

Figure 5 Follow-up computed tomography. The gas pocket reduced.

clostridium species are *C. perfringens* and *C. septicum*. We performed a PubMed literature search and identified 57 *clostridium* hepatic abscess cases reported in the English medical literature (Table 1). Our search showed that *C. perfringens* was responsible for 37 cases (64.9%) and *C. septicum* was responsible for 10 cases (17.5%). Nine cases were caused by *C. difficile*, *C. ramosum*, *C. sporogenes*, *C. baratii*, *C. bifermentans*, *C. clostridioforme*, *C. hathewayi*, and *C. novyi* type B. In one case, the exact speciation was not provided due to the institution's microbiology limitation for identifying rare clostridial species.

C. perfringens septicemia has been reported to carry a mortality rate ranging from 70%-100%^[4]. Massive intravascular hemolysis is a well-known complication, occurring in 7%-15% of *C. perfringens* bacteremia

cases^[26-28]. *C. perfringens*'s alpha-toxin has been shown to be the key virulent factor for this clinical course, by inducing gas gangrene and causing massive hemolysis by destroying red cell membrane integrity^[3]. In our 37 cases of *C. perfringens* hepatic abscess, the mortality rate was 67.6% (25/37). 70.2% (26/37) experienced hemolysis (Table 1). Among the 25 patients who died, one patient died prior to arriving to the hospital. The mean time of survival for these 24 patients was 11 h. Among the 25 patients who died, only 4 patients (16%) were found to have poly-microbial infection, whereas among those who survived, 6 patients (50%) were found to have poly-microbial infection. The most common underlying disease was diabetes (11/37) followed by underlying malignancy (10/37). Interestingly, 7 patients were found to have no clear underlying medical disease.

Among the 10 cases of *C. septicum* species (Table 1), the patient survival was greater, 70% (7/10). Furthermore, no hemolysis was reported in contrast to the *C. perfringens* cases. Of note, *C. septicum* also produces alpha toxin, but it was shown to be unrelated to the alpha toxin of *C. perfringens*^[29]. *C. septicum* infection has been well known to be associated with underlying occult malignancy^[30-33]. It has been hypothesized that a rapidly growing tumor with anaerobic glycolysis provides a relatively hypoxic and acidic environment for germination of the clostridial spores^[34]. In fact, all of the ten patients had infected liver tumors at the time of the presentation, and only one patient (10%) was found to have a poly-microbial infection.

The remaining 10 cases where the infection was

caused by various clostridial species, including the one with no provided speciation, appeared to have a milder clinical course when compared to the above *C. perfringens* and *C. septicum* cohorts (Table 1). The mortality rate was lower, only 20%, and median age at the time of presentation was significantly younger, 27 years. Interestingly, trauma was the underlying disease for the three cases.

Here, we report a young, healthy 23-year-old female who was diagnosed with a hepatic abscess caused by *Clostridium paraputrificum*. Due to the extremely rapid clinical presentation and from the initial imaging study where the mass was completely replaced with multiple gas pockets, a *C. perfringens* infection was highly suspected. Unlike many typical *C. perfringens* hepatic abscess cases, our patient did not experience hemolysis nor had any end organ failure requiring ICU care. In addition, our patient did not have the typical risk factors for *C. perfringens* nor *C. septicum* infections, except for having a tumor in the liver. At the end, the causative organism was identified as *Clostridium paraputrificum*, which has not been reported before in the literature. A *Clostridium* hepatic abscess is an extremely rare case and *C. perfringens* is the most common causative organism. Early accurate diagnosis and timely interventions are paramount, as it carries an extremely high mortality. However, depending on the exact causative clostridial species, the clinical course can vary significantly.

ARTICLE HIGHLIGHTS

Case characteristics

A healthy 23-year-old female developed a *Clostridium paraputrificum* gas forming liver abscess within 24 h after interventional radiology hepatic adenoma embolization.

Clinical diagnosis

The patient's source of sepsis was unequivocally identified once an imaging study showed a gas forming liver abscess.

Differential diagnosis

Klebsiella pneumoniae was suspected to be the causative organism initially as it is known to contributing 77% to 88% of all gas forming pyogenic liver abscesses.

Laboratory diagnosis

In addition to severe leukocytosis and lactic acidosis, elevated lactate dehydrogenase, decreased haptoglobin and elevated bilirubin, signs of massive hemolysis, can be also seen in certain patients.

Imaging diagnosis

A gas forming liver abscess can be diagnosed with an abdominal X-ray or ultrasound, but typically a computed tomography scan is commonly used for the diagnosis.

Pathological diagnosis

A needle aspiration of the hepatic abscess and/or blood culture often will yield the causative organism.

Treatment

An early recognition and treatment with antibiotics is paramount as *Clostridium*

hepatic abscess infections are often extremely aggressive and lethal.

Related reports

There have been five case reports of septicemia caused by *C. paraputrificum*, however, none of them caused hepatic abscess.

Term explanation

Pyogenic liver abscess (PLA) is an uncommon disease. The incidences of gas forming pyogenic liver abscess (GFPLA) also known as emphysematous liver abscess, are even rarer, contributing 6.6% to 32% of PLA.

Experiences and lessons

A *Clostridium* hepatic abscess requires early accurate diagnosis and timely interventions, as it carries an extremely high mortality. However, depending on the exact causative clostridial species, the clinical course can vary significantly.

REFERENCES

- 1 **Khan MS**, Ishaq MK, Jones KR. Gas-Forming Pyogenic Liver Abscess with Septic Shock. *Case Rep Crit Care* 2015; **2015**: 632873 [PMID: 26090240 DOI: 10.1155/2015/632873]
- 2 **Kurasawa M**, Nishikido T, Koike J, Tominaga S, Tamemoto H. Gas-forming liver abscess associated with rapid hemolysis in a diabetic patient. *World J Diabetes* 2014; **5**: 224-229 [PMID: 24748935 DOI: 10.4239/wjd.v5.i2.224]
- 3 **van Bunderen CC**, Bomers MK, Wesdorp E, Peerbooms P, Veenstra J. Clostridium perfringens septicaemia with massive intravascular haemolysis: a case report and review of the literature. *Neth J Med* 2010; **68**: 343-346 [PMID: 20876913]
- 4 **Ng H**, Lam SM, Shum HP, Yan WW. Clostridium perfringens liver abscess with massive haemolysis. *Hong Kong Med J* 2010; **16**: 310-312 [PMID: 20683077]
- 5 **Law ST**, Lee MK. A middle-aged lady with a pyogenic liver abscess caused by Clostridium perfringens. *World J Hepatol* 2012; **4**: 252-255 [PMID: 22993668 DOI: 10.4254/wjh.v4.i8.252]
- 6 **Lim AG**, Rudd KE, Halliday M, Hess JR. Hepatic abscess-associated Clostridial bacteraemia presenting with intravascular haemolysis and severe hypertension. *BMJ Case Rep* 2016; **2016**: pii: bcr2015213253 [PMID: 26823354 DOI: 10.1136/bcr-2015-213253]
- 7 **Au WY**, Lau LS. Massive haemolysis because of Clostridium perfringens [corrected] liver abscess in a patient on peritoneal dialysis. *Br J Haematol* 2005; **131**: 2 [PMID: 16173955 DOI: 10.1111/j.1365-2141.2005.05634.x]
- 8 **Kreidl KO**, Green GR, Wren SM. Intravascular hemolysis from a Clostridium perfringens liver abscess. *J Am Coll Surg* 2002; **194**: 387 [PMID: 11893140 DOI: S1072-7515(01)01169-3]
- 9 **Nerad JL**, Pulvirenti JJ. Clostridium paraputrificum bacteremia in a patient with AIDS and Duodenal Kaposi's sarcoma. *Clin Infect Dis* 1996; **23**: 1183-1184 [PMID: 8922829]
- 10 **Brook I**. Clostridial Infections in Children: Spectrum and Management. *Curr Infect Dis Rep* 2015; **17**: 47 [PMID: 26431956 DOI: 10.1099/00222615-42-2-78]
- 11 **Shandera WX**, Humphrey RL, Stratton LB. Necrotizing enterocolitis associated with Clostridium paraputrificum septicemia. *South Med J* 1988; **81**: 283-284 [PMID: 3340884]
- 12 **Nachamkin I**, DeBlois GE, Dalton HP. Clostridium paraputrificum bacteremia associated with aspiration pneumonia. *South Med J* 1982; **75**: 1023-1024 [PMID: 7112187]
- 13 **Babenco GO**, Joffe N, Tischler AS, Kasdon E. Gas-forming clostridial mycotic aneurysm of the abdominal aorta. A case report. *Angiology* 1976; **27**: 602-609 [PMID: 1053471 DOI: 10.1177/00031977602701007]
- 14 **Hansen PS**, Schönheyder HC. Pyogenic hepatic abscess. A 10-year population-based retrospective study. *APMIS* 1998; **106**: 396-402 [PMID: 9548429]
- 15 **Kaplan GG**, Gregson DB, Laupland KB. Population-based study of the epidemiology of and the risk factors for pyogenic liver abscess. *Clin Gastroenterol Hepatol* 2004; **2**: 1032-1038 [PMID:

- 15551257 DOI: S1542356504004598]
- 16 **Tsai FC**, Huang YT, Chang LY, Wang JT. Pyogenic liver abscess as endemic disease, Taiwan. *Emerg Infect Dis* 2008; **14**: 1592-1600 [PMID: 18826824 DOI: 10.3201/eid1410.071254]
 - 17 **Meddings L**, Myers RP, Hubbard J, Shaheen AA, Laupland KB, Dixon E, Coffin C, Kaplan GG. A population-based study of pyogenic liver abscesses in the United States: incidence, mortality, and temporal trends. *Am J Gastroenterol* 2010; **105**: 117-124 [PMID: 19888200 DOI: 10.1038/ajg.2009.614]
 - 18 **Lee CJ**, Han SY, Lee SW, Baek YH, Choi SR, Roh MH, Lee JH, Jang JS, Han J, Cho SH, Choi SW. Clinical features of gas-forming liver abscesses: comparison between diabetic and nondiabetic patients. *Korean J Hepatol* 2010; **16**: 131-138 [PMID: 20606497 DOI: 10.3350/kjhep.2010.16.2.131]
 - 19 **Pitt HA**. Surgical management of hepatic abscesses. *World J Surg* 1990; **14**: 498-504 [PMID: 2200212]
 - 20 **Halvorsen RA Jr**, Foster WL Jr, Wilkinson RH Jr, Silverman PM, Thompson WM. Hepatic abscess: sensitivity of imaging tests and clinical findings. *Gastrointest Radiol* 1988; **13**: 135-141 [PMID: 3282964]
 - 21 **Rubinson HA**, Isikoff MB, Hill MC. Diagnostic imaging of hepatic abscesses: a retrospective analysis. *AJR Am J Roentgenol* 1980; **135**: 735-745 [PMID: 6778107 DOI: 10.2214/ajr.135.4.735]
 - 22 **Chou FF**, Sheen-Chen SM, Chen YS, Lee TY. The comparison of clinical course and results of treatment between gas-forming and non-gas-forming pyogenic liver abscess. *Arch Surg* 1995; **130**: 401-405; discussion 406 [PMID: 7710340]
 - 23 **Lee TY**, Wan YL, Tsai CC. Gas-containing liver abscess: radiological findings and clinical significance. *Abdom Imaging* 1994; **19**: 47-52 [PMID: 8161903]
 - 24 **Yang CC**, Chen CY, Lin XZ, Chang TT, Shin JS, Lin CY. Pyogenic liver abscess in Taiwan: emphasis on gas-forming liver abscess in diabetics. *Am J Gastroenterol* 1993; **88**: 1911-1915 [PMID: 8237941]
 - 25 **Lee HL**, Lee HC, Guo HR, Ko WC, Chen KW. Clinical significance and mechanism of gas formation of pyogenic liver abscess due to *Klebsiella pneumoniae*. *J Clin Microbiol* 2004; **42**: 2783-2785 [PMID: 15184470 DOI: 10.1128/JCM.42.6.2783-2785.2004]
 - 26 **Caya JG**, Truant AL. Clostridial bacteremia in the non-infant pediatric population: a report of two cases and review of the literature. *Pediatr Infect Dis J* 1999; **18**: 291-298 [PMID: 10093957]
 - 27 **Rechner PM**, Agger WA, Mruz K, Cogbill TH. Clinical features of clostridial bacteremia: a review from a rural area. *Clin Infect Dis* 2001; **33**: 349-353 [PMID: 11438901 DOI: 10.1086/321883]
 - 28 **Bodey GP**, Rodriguez S, Fainstein V, Elting LS. Clostridial bacteremia in cancer patients. A 12-year experience. *Cancer* 1991; **67**: 1928-1942 [PMID: 2004306]
 - 29 **Ballard J**, Bryant A, Stevens D, Tweten RK. Purification and characterization of the lethal toxin (alpha-toxin) of *Clostridium septicum*. *Infect Immun* 1992; **60**: 784-790 [PMID: 1541552]
 - 30 **Kornbluth AA**, Danzig JB, Bernstein LH. Clostridium septicum infection and associated malignancy. Report of 2 cases and review of the literature. *Medicine (Baltimore)* 1989; **68**: 30-37 [PMID: 2642585]
 - 31 **Kolbeinson ME**, Holder WD Jr, Aziz S. Recognition, management, and prevention of *Clostridium septicum* abscess in immunosuppressed patients. *Arch Surg* 1991; **126**: 642-645 [PMID: 2021349]
 - 32 **Thel MC**, Ciaccia D, Vredenburg JJ, Peters W, Corey GR. Clostridium septicum abscess in hepatic metastases: successful medical management. *Bone Marrow Transplant* 1994; **13**: 495-496 [PMID: 7517261]
 - 33 **Kirchner JT**. Clostridium septicum infection. Beware of associated cancer. *Postgrad Med* 1991; **90**: 157-160 [PMID: 1924004]
 - 34 **Lee CH**, Hsieh SY. Case report: Clostridium septicum infection presenting as liver abscess in a case of choriocarcinoma with liver metastasis. *J Gastroenterol Hepatol* 1999; **14**: 1227-1229 [PMID: 10634163]
 - 35 **Fiese MJ**. Tympany over the liver in hepatic abscess caused by *Clostridium welchii*. Report of a case. *Calif Med* 1950; **73**: 505-506 [PMID: 14792343]
 - 36 **Kivel RM**, Kessler A, Cameron DJ. Liver abscess due to *Clostridium perfringens*. *Ann Intern Med* 1958; **49**: 672-679 [PMID: 13571851]
 - 37 **Kahn SP**, Lindenauer SM, Wojtalik RS, Hildreth D. Clostridia hepatic abscess. An unusual manifestation of metastatic colon carcinoma. *Arch Surg* 1972; **104**: 209-212 [PMID: 5008917]
 - 38 **D'Orsi CJ**, Ensminger W, Smith EH, Lew M. Gas-forming intrahepatic abscess: a possible complication of arterial infusion chemotherapy. *Gastrointest Radiol* 1979; **4**: 157-161 [PMID: 456830]
 - 39 **Mera CL**, Freedman MH. Clostridium liver abscess and massive hemolysis. Unique demise in Fanconi's aplastic anemia. *Clin Pediatr (Phila)* 1984; **23**: 126-127 [PMID: 6319064 DOI: 10.1177/000992288402300215]
 - 40 **Nachman S**, Kaul A, Li KI, Slim MS, San Filippo JA, Van Horn K. Liver abscess caused by *Clostridium bifermentans* following blunt abdominal trauma. *J Clin Microbiol* 1989; **27**: 1137-1138 [PMID: 2745689]
 - 41 Case records of the Massachusetts General Hospital. Weekly clinicopathological exercises. Case 42-1989. A 64-year-old woman with a liver abscess, Clostridium perfringens sepsis, progressive sensorimotor neuropathy, and abnormal serum proteins. *N Engl J Med* 1989; **321**: 1103-1118 [PMID: 2571930 DOI: 10.1056/NEJM198910193211608]
 - 42 **Bätge B**, Filejski W, Kurowski V, Klüter H, Djonlagic H. Clostridial sepsis with massive intravascular hemolysis: rapid diagnosis and successful treatment. *Intensive Care Med* 1992; **18**: 488-490 [PMID: 1289375]
 - 43 **Rogstad B**, Ritland S, Lunde S, Hagen AG. Clostridium perfringens septicemia with massive hemolysis. *Infection* 1993; **21**: 54-56 [PMID: 8449584]
 - 44 **Gutiérrez A**, Florencio R, Ezpeleta C, Cisterna R, Martínez M. Fatal intravascular hemolysis in a patient with Clostridium perfringens septicemia. *Clin Infect Dis* 1995; **20**: 1064-1065 [PMID: 7795054]
 - 45 **Jones TK**, O'Sullivan DA, Smilack JD. 66-year-old woman with fever and hemolysis. *Mayo Clin Proc* 1996; **71**: 1007-1010 [PMID: 8820778]
 - 46 **Eckel F**, Lersch C, Huber W, Weiss W, Berger H, Schulte-Frohlinde E. Multimicrobial sepsis including Clostridium perfringens after chemoembolization of a single liver metastasis from common bile duct cancer. *Digestion* 2000; **62**: 208-212 [PMID: 11025370 DOI: 10.1159/000007815]
 - 47 **Urban BA**, McCormick R, Fishman EK, Lillemoie KD, Petty BG. Fulminant Clostridium septicum infection of hepatic metastases presenting as pneumoperitoneum. *AJR Am J Roentgenol* 2000; **174**: 962-964 [PMID: 10749230 DOI: 10.2214/ajr.174.4.1740962]
 - 48 **Sakurai T**, Hajiro K, Takakuwa H, Nishi A, Aihara M, Chiba T. Liver abscess caused by *Clostridium difficile*. *Scand J Infect Dis* 2001; **33**: 69-70 [PMID: 11234983]
 - 49 **Sarmiento JM**, Sarr MG. Necrotic infected liver metastasis from colon cancer. *Surgery* 2002; **132**: 110-111 [PMID: 12110807]
 - 50 **Hsieh CH**, Hsu YP. Early-onset liver abscess after blunt liver trauma: report of a case. *Surg Today* 2003; **33**: 392-394 [PMID: 12734739 DOI: 10.1007/s005950300089]
 - 51 **Quigley M**, Joglekar VM, Keating J, Jagath S. Fatal Clostridium perfringens infection of a liver cyst. *J Infect* 2003; **47**: 248-250 [PMID: 12963388]
 - 52 **Elsayed S**, Zhang K. Human infection caused by Clostridium hathewayi. *Emerg Infect Dis* 2004; **10**: 1950-1952 [PMID: 15550205 DOI: 10.3201/eid1011.040006]
 - 53 **Fondran J**, Williams GB. Liver metastasis presenting as pneumoperitoneum. *South Med J* 2005; **98**: 248-249 [PMID: 15759962 DOI: 10.1097/01.SMJ.0000153196.84534.9A]
 - 54 **Kurtz JE**, Claudel L, Collard O, Limacher JM, Bergerat JP, Dufour P. Liver abscess due to clostridium septicum. A case report and review of the literature. *Hepatogastroenterology* 2005; **52**:

- 1557-1558 [PMID: 16201118]
- 55 **Ohtani S**, Watanabe N, Kawata M, Harada K, Hime M, Murakami K. Massive intravascular hemolysis in a patient infected by a *Clostridium perfringens*. *Acta Med Okayama* 2006; **60**: 357-360 [PMID: 17189980 DOI: 10.18926/AMO/30725]
- 56 **Daly JJ**, Haeusler MN, Hogan CJ, Wood EM. Massive intravascular haemolysis with T-activation and disseminated intravascular coagulation due to clostridial sepsis. *Br J Haematol* 2006; **134**: 553 [PMID: 16822287 DOI: 10.1111/j.1365-2141.2006.06177.x]
- 57 **Loran MJ**, McErlean M, Wilner G. Massive hemolysis associated with *Clostridium perfringens* sepsis. *Am J Emerg Med* 2006; **24**: 881-883 [PMID: 17098117 DOI: 10.1016/j.ajem.2006.03.002]
- 58 **Chiang KH**, Chou AS, Chang PY, Huang HW. Gas-containing liver abscess after transhepatic percutaneous cholecystostomy. *J Vasc Interv Radiol* 2007; **18**: 940-941 [PMID: 17609462 DOI: 10.1016/j.jvir.2007.04.021]
- 59 **Abdel-Haq NM**, Chearskul P, Salimnia H, Asmar BI. Clostridial liver abscess following blunt abdominal trauma: case report and review of the literature. *Scand J Infect Dis* 2007; **39**: 734-737 [PMID: 17654354 DOI: 10.1080/00365540701199865]
- 60 **Umgelter A**, Wagner K, Gaa J, Stock K, Huber W, Reindl W. Pneumobilia caused by a clostridial liver abscess: rapid diagnosis by bedside sonography in the intensive care unit. *J Ultrasound Med* 2007; **26**: 1267-1269 [PMID: 17715325]
- 61 **Tabarelli W**, Bonatti H, Cejna M, Hartmann G, Stelzmueller I, Wenzl E. Clostridium perfringens liver abscess after pancreatic resection. *Surg Infect (Larchmt)* 2009; **10**: 159-162 [PMID: 19388837 DOI: 10.1089/sur.2008.014]
- 62 **Merino A**, Pereira A, Castro P. Massive intravascular haemolysis during *Clostridium perfringens* sepsis of hepatic origin. *Eur J Haematol* 2010; **84**: 278-279 [PMID: 19682059 DOI: 10.1111/j.1600-0609.2009.01337.x]
- 63 **Saleh N**, Sohail MR, Hashmey RH, Al Kaabi M. Clostridium septicum infection of hepatic metastases following alcohol injection: a case report. *Cases J* 2009; **2**: 9408 [PMID: 20072687 DOI: 10.1186/1757-1626-2-9408]
- 64 **Meyns E**, Vermeersch N, Ilsen B, Hoste W, Delooy H, Hubloue I. Spontaneous intrahepatic gas gangrene and fatal septic shock. *Acta Chir Belg* 2009; **109**: 400-404 [PMID: 19943601]
- 65 **Rajendran G**, Bothma P, Brodbeck A. Intravascular haemolysis and septicaemia due to *Clostridium perfringens* liver abscess. *Anaesth Intensive Care* 2010; **38**: 942-945 [PMID: 20865884]
- 66 **Bradly DP**, Collier M, Frankel J, Jakate S. Acute Necrotizing Cholangiohepatitis With *Clostridium perfringens*: A Rare Cause of Post-Transplantation Mortality. *Gastroenterol Hepatol (N Y)* 2010; **6**: 241-243 [PMID: 20567577]
- 67 **Ogah K**, Sethi K, Karthik V. Clostridium clostridioforme liver abscess complicated by portal vein thrombosis in childhood. *J Med Microbiol* 2012; **61**: 297-299 [PMID: 21940652 DOI: 10.1099/jmm.0.031765-0]
- 68 **Qandeel H**, Abudeeb H, Hammad A, Ray C, Sajid M, Mahmud S. Clostridium perfringens sepsis and liver abscess following laparoscopic cholecystectomy. *J Surg Case Rep* 2012; **2012**: 5 [PMID: 24960720 DOI: 10.1093/jscr/2012.1.5]
- 69 **Kim JH**, Jung ES, Jeong SH, Kim JS, Ku YS, Hahm KB, Kim JH, Kim YS. A case of emphysematous hepatitis with spontaneous pneumoperitoneum in a patient with hilar cholangiocarcinoma. *Korean J Hepatol* 2012; **18**: 94-97 [PMID: 22511909 DOI: 10.3350/kjhep.2012.18.1.94]
- 70 **Huang WC**, Lee WS, Chang T, Ou TY, Lam C. Emphysematous cholecystitis complicating liver abscess due to *Clostridium baratii* infection. *J Microbiol Immunol Infect* 2012; **45**: 390-392 [PMID: 22561510 DOI: 10.1016/j.jmii.2011.12.007]
- 71 **Sucandy I**, Gallagher S, Josloff RK, Nussbaum ML. Severe clostridium infection of liver metastases presenting as pneumoperitoneum. *Am Surg* 2012; **78**: E338-E339 [PMID: 22748522]
- 72 **Raghavendra GK**, Carr M, Dharmadhikari R. Colorectal cancer liver metastasis presenting as pneumoperitoneum: case report and literature review. *Indian J Surg* 2013; **75**: 266-268 [PMID: 24426586 DOI: 10.1007/s12262-012-0666-6]
- 73 **Kitterer D**, Braun N, Jehs MC, Schulte B, Alscher MD, Latus J. Gas gangrene caused by clostridium perfringens involving the liver, spleen, and heart in a man 20 years after an orthotopic liver transplant: a case report. *Exp Clin Transplant* 2014; **12**: 165-168 [PMID: 23962047 DOI: 10.6002/ect.2013.0034]
- 74 **Imai J**, Ichikawa H, Tobita K, Watanabe N. Liver abscess caused by *Clostridium perfringens*. *Intern Med* 2014; **53**: 917-918 [PMID: 24739619]
- 75 **Eltawansy SA**, Merchant C, Atluri P, Dwivedi S. Multi-organ failure secondary to a *Clostridium perfringens* gaseous liver abscess following a self-limited episode of acute gastroenteritis. *Am J Case Rep* 2015; **16**: 182-186 [PMID: 25807198 DOI: 10.12659/AJCR.893046]
- 76 **Li JH**, Yao RR, Shen HJ, Zhang L, Xie XY, Chen RX, Wang YH, Ren ZG. Clostridium perfringens infection after transarterial chemoembolization for large hepatocellular carcinoma. *World J Gastroenterol* 2015; **21**: 4397-4401 [PMID: 25892893 DOI: 10.3748/wjg.v21.i14.4397]
- 77 **Rives C**, Chaudhari D, Swenson J, Reddy C, Young M. Clostridium perfringens liver abscess complicated by bacteremia. *Endoscopy* 2015; **47** Suppl 1 UCTN: E457 [PMID: 26465182 DOI: 10.1055/s-0034-1392867]
- 78 **Hashiba M**, Tomino A, Takenaka N, Hattori T, Kano H, Tsuda M, Takeyama N. Clostridium Perfringens Infection in a Febrile Patient with Severe Hemolytic Anemia. *Am J Case Rep* 2016; **17**: 219-223 [PMID: 27049736]
- 79 **Kyang LS**, Bin Traiki TA, Alzahrani NA, Morris DL. Microwave ablation of liver metastasis complicated by Clostridium perfringens gas-forming pyogenic liver abscess (GPLA) in a patient with past gastrectomy. *Int J Surg Case Rep* 2016; **27**: 32-35 [PMID: 27529833 DOI: 10.1016/j.ijscr.2016.08.009]
- 80 **Ulger Toprak N**, Balkose G, Durak D, Dulundu E, Demirbaş T, Yegen C, Soyletir G. Clostridium difficile: A rare cause of pyogenic liver abscess. *Anaerobe* 2016; **42**: 108-110 [PMID: 27693543 DOI: 10.1016/j.anaerobe.2016.09.007]
- 81 **García Carretero R**, Romero Brugera M, Vazquez-Gomez O, Rebollo-Aparicio N. Massive haemolysis, gas-forming liver abscess and sepsis due to Clostridium perfringens bacteraemia. *BMJ Case Rep* 2016; **2016**: pii: bcr2016218014 [PMID: 27888224 DOI: 10.1136/bcr-2016-218014]

P- Reviewer: Cerwenka H, Stanciu C S- Editor: Cui LJ

L- Editor: A E- Editor: Li D





Published by **Baishideng Publishing Group Inc**
7901 Stoneridge Drive, Suite 501, Pleasanton, CA 94588, USA
Telephone: +1-925-223-8242
Fax: +1-925-223-8243
E-mail: bpgoffice@wjgnet.com
Help Desk: <http://www.f6publishing.com/helpdesk>
<http://www.wjgnet.com>

