



ORIGINAL ARTICLE

Calcification of the stylohyoid complex in Libyans



Galal Omami *

American Board of Oral and Maxillofacial Radiology, United States
University of Kentucky College of Dentistry, Department of Oral Health Practice, Division of Oral Medicine, Diagnosis and Radiology, 800 Rose Street, Room MN-320, Lexington, KY 40536-0297, United States

Received 21 May 2016; revised 27 November 2017; accepted 16 December 2017
Available online 24 December 2017

KEYWORDS

Calcification;
Radiography;
Panoramic;
Stylohyoid

Abstract Objective: To investigate the prevalence and pattern of calcification of the stylohyoid complex in Libyan population.

Material and methods: Archived digital panoramic radiographs of 3343 patients were collected; 181 images were excluded for underage or poor image quality. Thus, the images of 3162 patients (1081 men, 2081 women; women-to-men ratio, 2:1; age range, 16–68 years; mean age, 36.7 years) retrieved and assigned to one of four morphological patterns of the stylohyoid complex: regular, elongated, calcified, and undetected. Data were analyzed with the X^2 test using SPSS (Chicago, IL, USA); P values lower than 0.05 were considered statistically significant.

Results: Out of 3162 images studied, the styloid process was demonstrated to be regular in 1935 (61.2%), elongated in 541 (17.2%), calcified in 565 (17.8%), and undetected in 121 (3.8%). Symmetric patterns were demonstrated on 2580 (81.6%) images. An elongated stylohyoid complex was significantly more common in women than in men ($P = .0404$).

Conclusion: The anatomical patterns of the stylohyoid complex in Libyans were highly variable. Dental clinicians should recognize the various morphological patterns of the stylohyoid complex on panoramic radiographs. Computed tomography studies are recommended for further morphometric analysis of the stylohyoid complex.

© 2017 The Author. Production and hosting by Elsevier B.V. on behalf of King Saud University. This is an open access article under the CC BY-NC-ND license (<http://creativecommons.org/licenses/by-nc-nd/4.0/>).

* Address: University of Kentucky College of Dentistry, Department of Oral Health Practice, Division of Oral Medicine, Diagnosis and Radiology, 800 Rose Street, Room MN-320, Lexington, KY 40536-0297, United States.

E-mail address: galal.omami@uky.edu.

Peer review under responsibility of King Saud University.



Production and hosting by Elsevier

1. Introduction

The stylohyoid complex (chain) consists of the styloid process, stylohyoid ligament and the lesser cornu (horn) of the hyoid bone. It is derived from the second pharyngeal arch (Reichert's cartilage). The stylohyoid process projects downward, forward, and slightly medially so that its tip is positioned between the internal carotid artery, internal jugular vein, and cranial nerves V, IX, and X. Langlais et al. reported that the styloid process varies in length between patients and often between the two sides of the same individual (Langlais et al., 1995). They

suggested that an elongated styloid process results from ossification in the stylohyoid ligament.

Calcification of the stylohyoid complex is usually detected as an incidental finding on panoramic radiographs (Monsour et al., 1986). However, this finding may also be associated with a group of clinical symptoms that require surgical intervention (Eagle, 1948). O'Carroll reported that 8 of 103 (8%) patients with an elongated styloid process presented with related symptoms of deep neck pain, foreign body sensation in the throat, pain on turning the head, and odynophagia (O'Carroll, 1984).

Langlais et al. proposed a radiographic classification for the calcified stylohyoid complex, including three patterns of radiographic presentation (elongated, pseudoarticulated, segmented) and four patterns of calcification (calcified outline, partially calcified, nodular complex, completely calcified) (Langlais et al., 1986). However, only a few studies have presented the calcification of the stylohyoid complex in a manner that would be useful for clinicians. Therefore, the aim of this study was to investigate the prevalence and pattern of calcification of the stylohyoid complex in a Libyan population.

2. Material and methods

Records of digital panoramic radiographs treated at the University of Benghazi College of Dentistry between January 2010 and December 2013, were retrieved and evaluated for the prevalence and pattern of calcification of the stylohyoid complex. Patients younger than 16 years of age were excluded from the analysis as these patients would not have reached skeletal maturity. Radiographs with positioning or exposure errors were also excluded from the study. The panoramic images were generally obtained as part of routine radiographic screening for oral diagnosis. Therefore, no specific history related to the stylohyoid complex, e.g., tonsillectomy or cervical trauma, was obtained, so that it was not possible to diagnose Eagle syndrome or stylohyoid syndrome. The images were taken using paX-i (Vatech, Seoul, Korea) set at 60–80 kVp, 8–10 mA, and 10.1 s.

The native population of Libya is mainly a mixture of Arab-Imazighen ethnicities, with large minorities descending from African and Turkish origin. However, it was not possible to determine the ethnic background of each patient.

The classification of the stylohyoid complex used in this study was modified from MacDonald-Jankowski's study (MacDonald-Jankowski, 2001). He classified the stylohyoid complex according to the center of calcification as following: Region 1, tympanohyal; Region 2, stylohyal; Region 3, ceratohyal; Region 4, hypohyal.

The classification used in this study is as following: the styloid process was considered "regular" when it did not extend below the mandibular foramen (Patterns A to D); "elongated" when it extended below the mandibular foramen and appeared to be continuous with skull base (Pattern E); "calcified" when it extended below the mandibular foramen and did not appear to be continuous with the cranial base (Patterns F to K); "undetected" when it could not be seen on the panoramic image (Figs. 1 and 2). All radiographs were de-identified and reviewed by a board-certified oral and maxillofacial radiologist under ambient room lighting using the standardized Apple

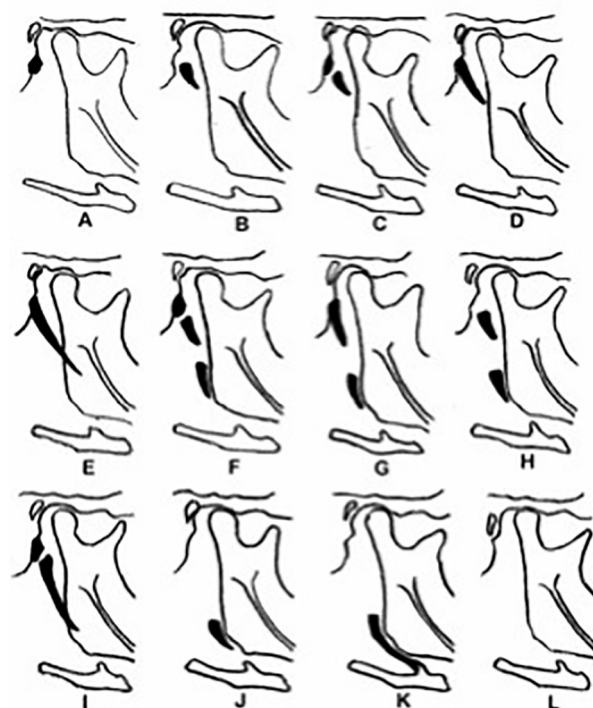


Fig. 1 O'Carroll's classification of the stylohyoid complex: Patterns A through D, regular; Pattern E, elongated; Patterns F through K, calcified; and Pattern L, absent.

software—iPhoto (Apple, Cupertino, CA, USA) on a 27-in. monitor (iMac, Apple) with a screen resolution of 2560 × 1440 pixels.

3. Results

The digital panoramic radiographs of 3343 patients were collected; 181 images were excluded because the patient was younger than 16 or because the image quality was poor as the result of errors in positioning or exposure. Thus, the images of 3162 patients (1081 men, 2081 women; women-to-men ratio, 2:1; age range, 16–68 years; mean age, 36.7 years) were included in the study.

The detailed distribution of the 12 patterns of O'Carroll's classification⁴ is shown in Table 1. The styloid process was classified as regular (Patterns A, B, C, and D) in 1935 images (61.2%), elongated (Pattern E) in 541 (17.2%), calcified (Patterns F, G, H, I, J, K) in 565 (17.8%), and undetected (Pattern L) in 121 (3.8%). However, 2580 (81.6%) of the regular, elongated, calcified, or undetected patterns were symmetrical on both sides. According to O'Carroll's classification, Pattern D was the most common symmetrical pattern (964, 30.5%), whereas Pattern D-C was the most common asymmetrical pattern (180, 5.7%). The elongated stylohyoid complex pattern occurred significantly more frequently among women ($P = .0404$). However, there was no significant difference between men and women in the occurrence of the calcified stylohyoid complex ($P = .0669$).

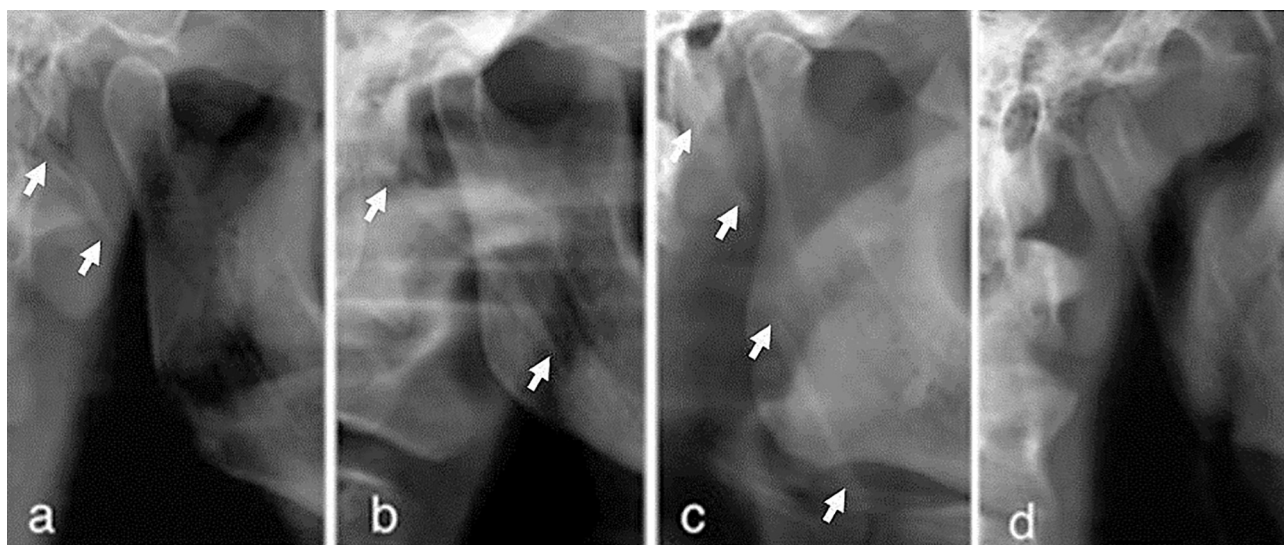


Fig. 2 Classification of the stylohyoid complex used in this study: a, regular; b, elongated; c, calcified; d, undetected.

Table 1 Patterns of calcification of the stylohyoid complex in Libyans.

Pattern	A		B		C		D		E		F		G		H		I		J		K		L	
	Rt	Lt	Rt	Lt	Rt	Lt	Rt	Lt	Rt	Lt	Rt	Lt	Rt	Lt	Rt	Lt	Rt	Lt	Rt	Lt	Rt	Lt	Rt	Lt
Number	99	93	263	246	309	403	1297	1160	528	554	54	57	122	121	21	15	203	251	64	69	76	77	126	116
Total	192		509		712		2457		1082		111		243		36		454		133		153		242	
Percentage	3		8		11		39		17		2		4		0.5		7		2		2.5		4	

RT, right; LT, left.

4. Discussion

This study evaluated the calcification pattern of the stylohyoid complex on panoramic radiographs as this imaging modality is widely used by dental clinicians. To the best of the author's knowledge, the size of the sample in this study is the largest ever included in studies of the stylohyoid complex. The frequency of a calcified stylohyoid complex in this analysis was relatively higher than that found in previous studies (MacDonald-Jankowski, 2001; Jung et al., 2004; Oztas et al., 2012). A relatively recent study reported that only 6% of subjects with a calcified stylohyoid complex had related symptoms (Ilguy et al., 2005). Therefore, the calcification of the stylohyoid complex on panoramic radiographs should be based on clinical findings.

Various classification techniques have been used to evaluate the stylohyoid complex (MacDonald-Jankowski, 2001; Oztas et al., 2012; Okabe et al., 2006; Kursuoglu et al., 2005). In the present study, the stylohyoid complex was simply classified according to 4 patterns (regular, elongated, calcified, and undetected). This classification system is of more clinical value than sorting the stylohyoid complex into one of 12 anatomic patterns, as in O'Carroll's classification (Fig. 1). For instance, in the context of related symptoms, the clinician will essentially need to ascertain the pattern of the stylohyoid complex in terms of elongation and calcification. The current study used the term *regular* rather than *normal*, because it is unclear

whether other patterns of the stylohyoid complex are in essence pathologic conditions; instead, they seem to be normal variants commonly observed on panoramic radiographs. However, the criteria of definitions used in this study corresponded to those used in MacDonald-Jankowski's study (MacDonald-Jankowski, 2001). The elongated and calcified patterns of the stylohyoid complex occurred at quite similar rates in this study (elongated, 17.2%; calcified, 17.8%). The frequency of the calcified pattern was similar to that reported among the Hong Kong Chinese (MacDonald-Jankowski, 2001). However, the frequencies at which other patterns occurred were generally different from those reported in studies investigated subjects of different ethnic backgrounds including Hong Kong Chinese, Londoners, and Turkish populations (MacDonald-Jankowski, 2001; Alpoz et al., 2014). However, O'Carroll reported no particular ethnic predilection in his study involving subjects from the United States (O'Carroll, 1984). Interestingly, the frequency of Pattern L (absent stylohyoid complex) was similar among Libyans, Hong Kong Chinese, Londoners, and Turkish populations (2.5–3.8%) (Monsour, 1986; MacDonald-Jankowski, 2001). However, it is unclear whether this type of stylohyoid complex was actually absent or was simply unseen because of technical reasons; hence, the current study used the term *undetected* rather than *absent*. However, a cadaveric study did not find a single case in which the styloid process was completely absent, although a vestigial process was identified (Frommer, 1974).

The elongated stylohyoid complex was significantly more common among females than among males. However, there was no significant difference between males and females in the frequency of the calcified stylohyoid complex. In agreement with other reports (Monsour, 1986; Omnell, 1998), MacDonald-Jankowski found no significant difference between males and females in the frequency of the elongated or the calcified stylohyoid complex (MacDonald-Jankowski, 2001). However, other studies reported a slight predilection among elderly females for the elongated styloid process (O'Carroll, 1984; Oztas et al., 2012). However, this study did not include gender- or age-based evaluation of the stylohyoid complex, as this approach appears to have little diagnostic value. A study that reviewed 1162 panoramic radiographs obtained from the population of the Aseer region of Saudi Arabia found that the prevalence of the elongated styloid process was as high as 93% (Shaik et al., 2013). A similar study from Northern India found that the prevalence of the elongated styloid process was (Bagga et al., 2012). However, the authors used a different classification technique from that in the present study. In some studies, when asymmetry was present, the side with the most advanced pattern was used to measure the stylohyoid complex (MacDonald-Jankowski, 2001; Oztas et al., 2012). However, in the current analysis, the right and left sides were classified separately so that bias could be avoided. In accordance with other reports, this study has shown a high degree of symmetry in the patterns of stylohyoid complex (MacDonald-Jankowski, 2001; Okabe et al., 2006; Akar et al., 2016).

A calcified stylohyoid complex that appears as a radiopaque nodule on a panoramic radiograph may simulate a sialolith or a calcified carotid atheroma (Langlais et al., 1995). Therefore, dental professionals should carefully evaluate the location and morphology of soft tissue calcifications in the mandibular angle area. However, additional 3D imaging may be necessary for further evaluation. Clinical symptoms associated with Eagle syndrome are likely related to the elongation as well as the medial inclination of the stylohyoid complex. Buyuk et al. found a significant correlation between the length of the stylohyoid complex and its sagittal angle by using cone beam computed tomographic imaging (Buyuk et al., 2017). However, the length and angulation of the stylohyoid complex were not measured in this study, as linear measurements on panoramic radiographs are not reliable.

In conclusion, this study has shown significant differences in the morphology of the stylohyoid complex between Libyans and other ethnic groups. It is of utmost importance for dental clinicians to cope with the various morphological patterns of the stylohyoid complex as demonstrated on panoramic radiographs. Computed tomography studies are necessary for further morphometric analysis of the stylohyoid complex. To the best of the author's knowledge, this is the first study to investigate the prevalence and pattern of calcification of the stylohyoid complex in a Libyan population. Because of its large sample size and its clinically oriented classification technique, this study presents important information for dental practitioners.

Conflict of interest

The author declared that there is no conflict of interest.

References

- Akar, G.C. et al, 2016. Does the state of dentition affect the type of stylohyoid chain calcification pattern? *Surg. Radiol. Anat.* 38, 817–823.
- Alpoz, E. et al, 2014. Prevalence and pattern of stylohyoid chain complex patterns detected by panoramic radiographs among Turkish population. *Surg. Radiol. Anat.* 36, 39–46.
- Bagga, M.B. et al, 2012. Clinicoradiologic evaluation of styloid process calcification. *Imag. Sci. Dent.* 42, 155–161.
- Buyuk, C. et al, 2017. Morphological assessment of the stylohyoid complex variations with cone beam computed tomography in a Turkish population. *Folia. Morphol. (Warsz)*. <https://doi.org/10.5603/FM.a2017.0061>.
- Eagle, W.W., 1948. Elongated styloid process: further observations and a new syndrome. *Arch. Otolaryngol.* 47, 630–640.
- Frommer, J., 1974. Anatomic variations in the stylohyoid chain and their possible clinical significance. *Oral Surg. Oral Med. Oral Pathol.* 8, 659–667.
- Ilguy, M. et al, 2005. Incidence of the type and calcification patterns in patients with elongated styloid process. *J. Int. Med. Res.* 33, 96–102.
- Jung, T. et al, 2004. Elongated styloid process: when is it really elongated? *Dentomaxillofac. Radiol.* 33, 119–124.
- Kursuoglu, P. et al, 2005. Radiological evaluation of the styloid process in young adults resident in Turkey's Yeditepe University Faculty of Dentistry. *Oral Surg. Oral Med. Oral Pathol. Oral Radiol.* 100 (4), 491–494.
- Langlais, R.P. et al, 1995. Soft Tissue Radiopacities. In: Langlais, R.P. (Ed.), *Diagnostic Imaging of the Jaws*. Williams & Wilkins, Baltimore, pp. 617–648.
- Langlais, R.P. et al, 1986. Elongated and mineralized stylohyoid ligament complex: a proposed classification and report of a case of Eagle's syndrome. *Oral Surg. Oral Med. Oral Pathol.* 61 (5), 527–532.
- MacDonald-Jankowski, D.S., 2001. Calcification of the stylohyoid complex in Londoners and Hong Kong Chinese. *Dentomaxillofac. Radiol.* 30 (1), 35–39.
- Monsour, P.A. et al, 1986. Variability of the styloid process and stylohyoid ligament in panoramic radiographs. *Oral Surg. Oral Med. Oral Pathol.* 61, 522–526.
- O'Carroll, M.K., 1984. Calcification in the stylohyoid ligament. *Oral Surg. Oral Med. Oral Pathol.* 58, 617–621.
- Okabe, S. et al, 2006. Clinical significance and variation of the advanced calcified stylohyoid complex detected by panoramic radiographs among 80-year-old subjects. *Dentomaxillofac. Radiol.* 5, 191–199.
- Omnell, K.A. et al, 1998. Ossification of the human stylohyoid ligament. A longitudinal study. *Oral Surg. Oral Med. Oral Pathol. Oral Radiol. Endod.* 85, 226–232.
- Oztas, B., Orhan, K., 2012. Investigation of the incidence of stylohyoid ligament calcifications with panoramic radiographs. *J. Investig. Clin. Dent.* 3 (1), 30–35.
- Shaik, M.A. et al, 2013. Prevalence of elongated styloid process in Saudi population of Aseer region. *Eur. J. Dent.* 7, 449–454.