


Contents lists available at [ScienceDirect](http://www.sciencedirect.com)

Trauma Case Reports

journal homepage: www.elsevier.com/locate/tcr

Case report

Blunt innominate artery trauma requiring repair and carotid ligation

Kathryn L. Howe^{a,*}, Mina Guirgis^a, Grant Woodman^a, F. Victor Chu^b, M.J. Cooper^c, Theodore Rapanos^a, David Szalay^a

^a Division of Vascular Surgery, McMaster University, Hamilton, Ontario, Canada

^b Division of Cardiac Surgery, McMaster University, Hamilton, Ontario, Canada

^c Division of Plastic Surgery, McMaster University, Hamilton, Ontario, Canada

ARTICLE INFO

Keywords:

Innominate artery
Dissection
Limb ischemia
Multi-disciplinary
Forearm compartment release

ABSTRACT

Traumatic dissection of the innominate artery is a rare clinical entity. Management of a patient with motorsensory compromise and dissection extending to the subclavian and right common carotid arteries is quite rare and can be quite involved. Here we present such a case and discuss the unique peri-operative decision-making in the context of what is reported in the literature. Restoration of motorsensory function is critical and in this case, requiring a multi-disciplinary team.

Case report

A 50 year-old man working at heights in heavy industry fell 15 ft and was pinned between a crane and rail car. Initial transfer to a peripheral center diagnosed a small left pneumothorax and multiple rib fractures. After approximately one hour, the right hand became painful, the limb dusky, and pulses were absent. Upon arrival at our trauma center, the patient was insensate to the level of the antecubital fossa with minimal motor function and no demonstrable pulses in the right upper extremity, by palpation or handheld Doppler, from the brachial artery to the palmar arch. Aside from an initial transient loss of consciousness reported by EMS, we received the patient with no central neurological deficit.

CT angiogram demonstrated occlusion of the distal innominate artery, right common carotid and right subclavian arteries (Fig. 1). Flow reconstituted within the distal brachial artery with weak ulnar artery filling. Importantly, the right carotid bifurcation was patent with retrograde filling of the internal carotid artery by the external carotid artery.

The patient was reassessed in the trauma bay. Plastic surgery ruled out secondary brachial plexus injury and cardiac surgery assessed for possible joint operative intervention. Within one hour, the patient had complete restoration of motor and neurologic function. Consequently, a discussion was undertaken regarding treatment of a traumatic dissection for a patient that was now minimally symptomatic and continuing to improve. Aware the clinical picture might represent a dynamic dissection flap, we decided to place the patient on intravenous heparin in our intensive care unit, with the plan that any deterioration would necessitate emergent operation. Our surgical options considered at that time were (extra-anatomic) extrathoracic bypass or median sternotomy with inline revascularization, the latter being preferred given our patient's age and relative fitness for surgery.

By early morning the patient was experiencing significant right arm pain, new onset paraesthesias, and no longer had demonstrable pulses. He remained centrally neurologically intact. Urgent repeat CTA included the complete Circle of Willis and demonstrated the additional findings of absent flow within the entire brachial and internal carotid arteries (Fig. 2). It was suspected the

* Corresponding author at: Hamilton General Hospital, 237 Barton St. E, 8N01, Hamilton, Ontario L8L 2X2, Canada.
E-mail address: kathryn.howe@medportal.ca (K.L. Howe).

<http://dx.doi.org/10.1016/j.tcr.2017.10.011>

Accepted 25 October 2017

Available online 29 October 2017

2352-6440/ © 2017 The Authors. Published by Elsevier Ltd. This is an open access article under the CC BY-NC-ND license (<http://creativecommons.org/licenses/by-nc-nd/4.0/>).

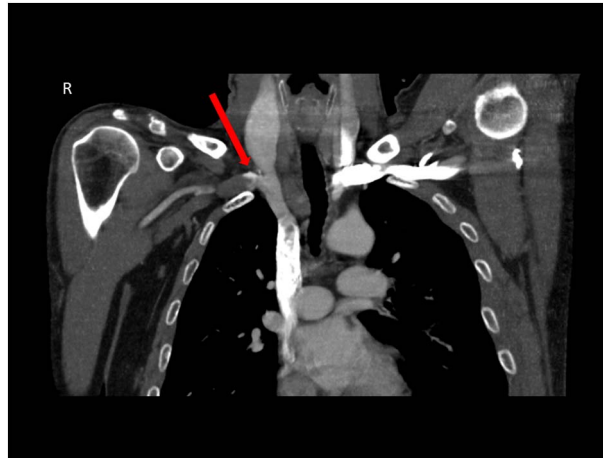


Fig. 1. CTA showing distal innominate artery occlusion.

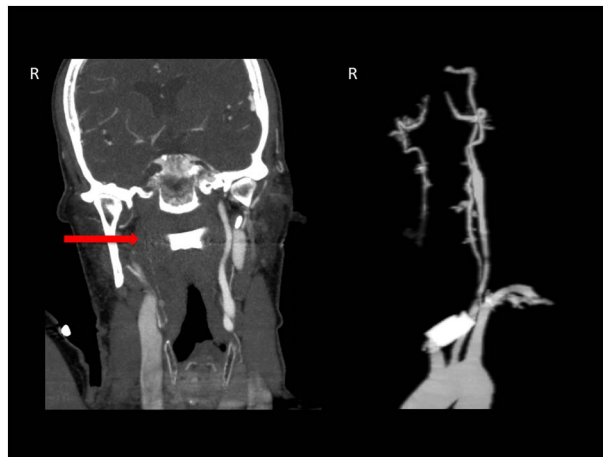

Fig. 2. CTA showing right common and internal carotid artery occlusion (arrow, left panel; 3D right panel).

patient had thromboembolized overnight, and importantly, the clinical exam clearly demonstrated development of a forearm compartment syndrome.

Urgently operative management involved a multidisciplinary team consisting of plastic, cardiac, and vascular surgery. Plastic surgery performed release of the volar and dorsal forearm, carpal tunnel, thenar and first dorsal interosseous compartments. One vascular team worked with cardiac surgery performing the sternotomy and axillary access, while another performed brachial, radial, and ulnar thrombectomies in an attempt to restore flow (Fig. 3). At the level of the innominate artery, there was clearly an intramural thrombus and visible dissection flap, which was tacked down proximally. For security, however, an innominate-axillary artery bypass was performed with 8 mm externally supported polytetrafluoroethylene graft. Finally, to prevent possible embolic stroke, the decision was made to ligate the right common carotid artery since repair of the dissection flap and restoration of vigorous inflow might cause a stroke by propelling thrombus intracranially through a patent Circle of Willis.

Post-operatively the patient did well, awaking neurologically intact with complete right arm motorsensory function. He did suffer a small watershed lacunar infarct in the intensive care unit on post-operative day (POD) 3, with facial droop and upper extremity paresis that had resolved by discharge home on POD 11. He has been seen in clinic with excellent results (Fig. 4).

Discussion

Innominate artery lesions are rare. In the trauma literature, civilian series have determined innominate artery injuries account for 0–3% of recognized arterial trauma [1]. This is, however, the second most commonly affected great vessel after the isthmus of the aorta and injury can present with a range of symptoms. Innominate injuries have a high morbidity and mortality, in part due to their inaccessibility, associated injuries, potential for cerebrovascular hypoperfusion and stroke, and relative inexperience of most surgeons dealing with these injuries. In-hospital mortality rate varies between 5 and 43% [2].

In 1985, Brewster et al. evaluated a 20 year operative series of 71 cases, determining direct repair via median sternotomy with

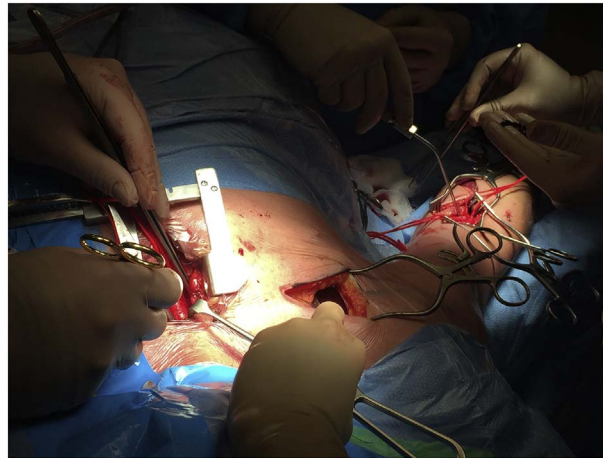


Fig. 3. Intra-operative image depicting multiple teams.

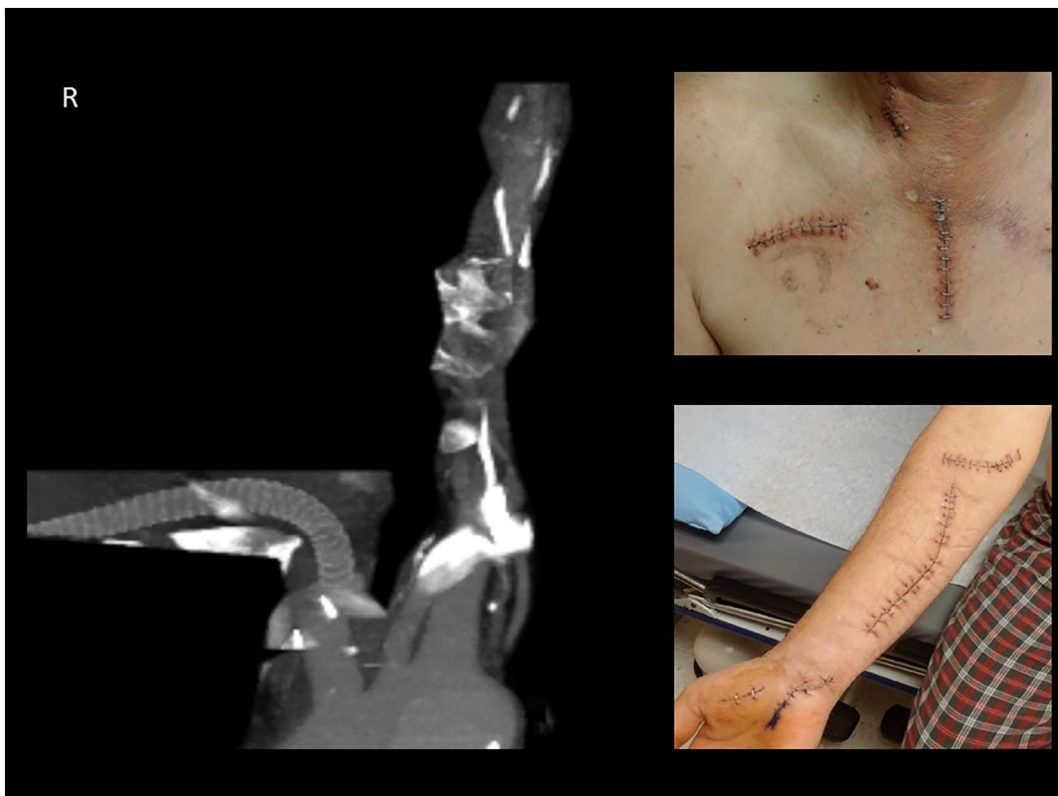

Fig. 4. Post-operative CTA reconstruction showing patent graft (left panel) and incision sites (right: top and bottom panels).

endarterectomy, prosthetic graft insertion, or open thromboembolectomy provides the best long-term results for an occlusive lesion, either due to atherosclerosis or traumatic dissection [3]. Hirose and Gill updated their review of blunt injury of the innominate artery in 2004 [4]. Data from 132 case reports determined the majority of patients were male (86%), mean age 30, and 89% had suffered from a motor vehicle accident. Crush injury and fall represented 9% and 2%, respectively. Similar to our case, associated injuries were common including pneumothorax and rib fractures. Although reported less consistently, abnormal pulse exams were documented in 59% of cases. Location of innominate artery injury was predominantly proximal (82%) with surgical repair performed in 98.5% of cases. Fifty-seven cases employed cerebral precautions in the form of cardiopulmonary bypass, carotid shunting, EEG monitoring, or measurement of the innominate artery or right carotid stump pressure vs. twenty-eight cases that did not. For our case, there was no need to employ cerebral precautions, as the right carotid artery was occluded with a patent Circle of Willis and neurologically intact patient at the time of surgery. It was critical, however, to ensure control of the right common carotid to prevent

thrombus from being released intracranially. This was central to our decision to ligate the right common carotid: with repair of the dissection flap, we introduced the possibility of forward inflow to the right carotid and hence, possible thromboembolism. While unclear to what extent this risk posed, we determined right carotid ligation was imperative to protect the patient from this risk. Finally, Hirose and Gill report innominate artery reconstruction took place in several cases, with grafts placed in 60. Of those outlined, none were innominate-axillary artery bypass. Morbidity and mortality was separated into pre- and post-1985, with the latter substantially improved to 1.5 and 3.1%, respectively. Post-operative stroke was observed in six cases over the entire period (4.5%).

While a different clinical entity, a South African trauma center provided an institutional review of 39 penetrating innominate artery trauma cases over a period of 18 years where interposition graft was used in 38% of the patients (total 87% underwent open surgical repair) [5]. Of the surviving patients, there was a 6% stroke rate, assumed to have suffered a stroke intra-operatively. This is comparable to that reported for blunt trauma (see above). Our patient was extubated neurologically intact on post-operative day 1. Rather, it is suspected he suffered a left-sided stroke secondary to a hypotensive event, from which he recovered completely while in hospital.

Here we report a case of traumatic innominate artery dissection with right arm ischemia with occlusion of the right common carotid and subclavian arteries. While our patient remained neurologically intact, at the time of surgery he had developed compartment syndrome, ultimately requiring a mini-sternotomy, innominate-axillary bypass, thrombectomy, and compartment release. To prevent possible embolic stroke, the right common carotid artery was also ligated. Within the body of literature available, it is clear this is a complex surgical entity. This clinical case report highlights the importance of multidisciplinary teams, deliberation, and a durable surgical repair. Although early, we report a patient who is minimally affected and healing well.

Conflict of interest statement

There are no identified conflicts of interest identified by any authors involved in this research.

Statement of funding

There was no financial or grant support of this case report.

References

- [1] K.L. Mattox, D.V. Feliciano, J. Burch, A.C. Beall, G.L. Jordan, M.E. DeBakey, Five-thousand seven hundred sixty cardiovascular injuries in 4459 patients, *Ann. Surg.* 209 (1989) 698–705.
- [2] R.H. Johnston, M.J. Wall, K.L. Mattox, Innominate artery trauma: a thirty-year experience, *J. Vasc. Surg.* 17 (1993) 134–140.
- [3] D.C. Brewster, A.C. Moncure, R.C. Darling, J.J. Ambrosino, W.M. Abbott, Innominate artery lesions: problems encountered and lessons learned, *J. Vasc. Surg.* 2 (1985) 99–112.
- [4] H. Hirose, I.S. Gill, Blunt injury of the innominate artery: a case report and review of the literature, *Ann. Thorac. Cardiovasc. Surg.* 10 (4) (2004) 218–223.
- [5] D.F. du Toit, W. Odendaal, A. Lambrechts, B.L. Warren, Surgical and endovascular management of penetrating innominate artery injuries, *Eur. J. Vasc. Endovasc. Surg.* 36 (2008) 56–62.