

## Case Report

# Metastasis to Paranasal Sinuses from Carcinoma of Prostate: Report of a Case and Review of the Literature

**Elio Bittar Barbosa** <sup>1</sup>, **Evaldo César Macau Furtado Ferreira**,<sup>1</sup>  
**Fernanda Viviane Mariano**,<sup>2</sup> **Albina Messias de Almeida Milani Altemani**,<sup>2</sup>  
**Emerson Taro Inoue Sakuma**,<sup>3</sup> and **Eulalia Sakano** <sup>1</sup>

<sup>1</sup>Department of Ophthalmology and Otorhinolaryngology, Faculty of Medical Sciences, University of Campinas, Campinas, SP, Brazil

<sup>2</sup>Department of Pathology, Faculty of Medical Sciences, University of Campinas, Campinas, SP, Brazil

<sup>3</sup>Department of Radiology, Faculty of Medical Sciences, University of Campinas, Campinas, SP, Brazil

Correspondence should be addressed to Elio Bittar Barbosa; [eliobb2006@gmail.com](mailto:eliobb2006@gmail.com)

Received 21 December 2017; Accepted 8 March 2018; Published 25 March 2018

Academic Editor: Richard T. Miyamoto

Copyright © 2018 Elio Bittar Barbosa et al. This is an open access article distributed under the Creative Commons Attribution License, which permits unrestricted use, distribution, and reproduction in any medium, provided the original work is properly cited.

Metastasis from distant primary tumors is extremely rare in the paranasal sinuses with few hundred cases in the literature. Metastatic carcinoma of the prostate is even rarer, despite being one of the most common tumors, with only 24 cases published. In this article, we report a case of a 58-year-old male presenting with epistaxis and nasal obstruction as initial symptoms of a metastatic prostate carcinoma in the ethmoid cells and maxillary sinus.

## 1. Introduction

Paranasal sinus cancer represents a small portion of the head and neck cancer, approximately 5% of all head and neck tumors [1]. These tumors may arise from multiple tissues present in the nose and paranasal sinuses [2] or more rarely be a metastasis from a distant primary cancer.

Prostate adenocarcinoma is the most prevalent malignant cancer in the male population. In Europe, the incidence rate is 214 cases per 1000 men [3]. Metastases from prostate tumors are a major determinant of survival rates, and prostate-specific antigen tests decrease the incidence of metastatic disease at diagnosis [4].

In this article, we presented the rare case of a patient with a distant metastasis in the right ethmoid cells from a prostate adenocarcinoma.

## 2. Case Report

A 58-year-old male patient was referred to the Otolaryngology Emergency Service because of important unilateral

epistaxis, the third episode in the previous month. He also presented with ipsilateral nasal obstruction and diplopia with a three-month evolution. In his medical report, there was a record of penile squamous cell carcinoma treated with surgery and radiotherapy in 2014 and stage IV prostate adenocarcinoma (iliac, lumbar, and encephalic metastasis) refractory to hormone therapy and chemotherapy, submitted to palliative radiotherapy one month earlier.

During endoscopy, a polypoid, papilloma-like mass originated from the middle meatus was visible, occupying the entire right nasal fossa. No other abnormality was seen in the left nasal fossa. The epistaxis was controlled; the patient was stabilized and referred to biopsy.

The computed tomography (CT) and magnetic resonance imaging (MRI) showed soft tissue density lesion in the right nasal fossa, ethmoid cells, and maxillary sinus with extension into the inferior portion of the orbit through the lamina papyracea and posteriorly to the pterygomaxillary fissure (Figures 1 and 2).

The biopsy resulted in adenocarcinoma (Figures 3(a) and 3(b)). Since the patient had a medical report of prostate

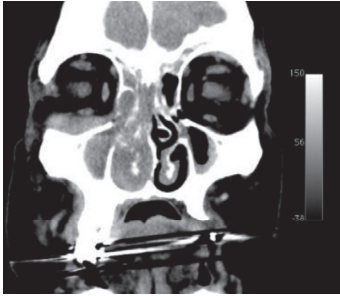


FIGURE 1: CT demonstrates lesion occupying ethmoid cells, nasal cavity, and maxillary sinus and extending through the lamina papyracea.

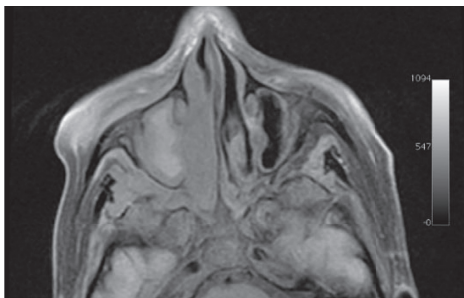


FIGURE 2: T1-weighted MRI with fat suppression demonstrates the lesion extending to the pterigomaxillary fissure.

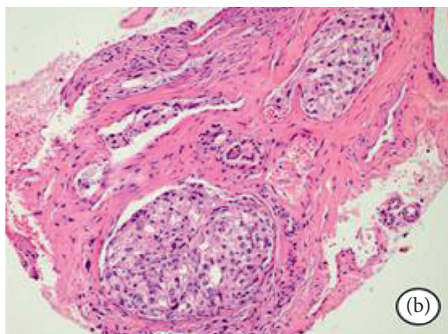
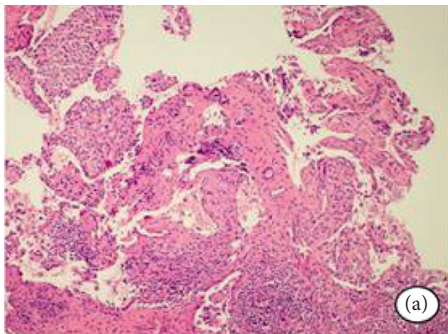


FIGURE 3: (a) Neoplasia infiltrating surrounding tissue with irregular margins (H&E stain). (b) Atypical epithelial islands with ductal characteristics resembling adenocarcinoma (H&E stain).

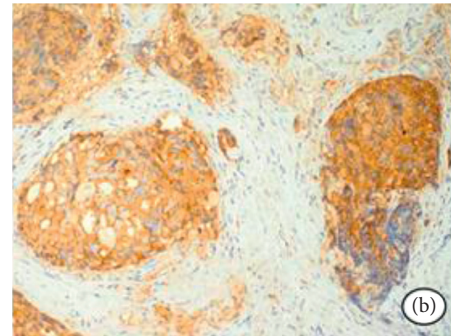
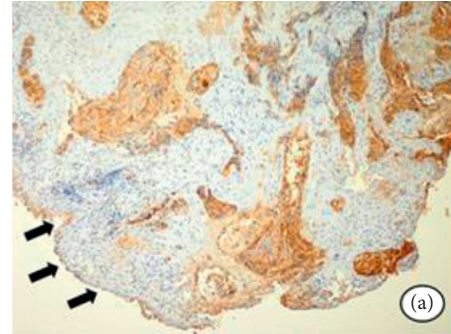


FIGURE 4: (a) Positive reaction to the PSA antigen in the epithelial islands, and there is no reaction in the superficial epithelium. (b) Strong expression of the PSA antigen in the ductal cells.

adenocarcinoma, the sample was submitted to an immunohistochemical panel. The prostate-specific antigen (PSA) was highly positive, and the diagnosis was confirmed as metastatic prostate adenocarcinoma (Figures 4(a) and 4(b)).

Because of the clinical status of the patient, a few symptoms presented, and the fact that he was already submitted to radiotherapy at the same field, it was opted for a clinical follow-up. After two months of the diagnosis, the patient deceased.

### 3. Discussion

Paranasal sinuses are a complex anatomic area, surrounding important structures such as the orbit and skull base. The most incident tumors are the squamous cell carcinoma, followed by adenocarcinoma and adenoid cystic carcinoma [5].

In a review, Prescher and Brors reported 169 cases of metastatic tumor to the paranasal sinuses [6]. Most cases originated from the kidney, followed by the lung, breast, thyroid, and prostate. Prescher and Brors also reported that the maxillary sinus was the most affected, followed by the sphenoid, ethmoid, and frontal sinuses [6]. These data are similar to those published by Bernstein [7]. In 77% of the cases, just one paranasal sinus was affected [6].

The nonspecific symptoms are similar to those of primary tumors. The nasal symptoms are usually nasal mass, nasal obstruction, facial deformity, and epistaxis. Orbital

TABLE 1: Prostate metastasis to the paranasal sinuses.

Author	Age	Sinus	Symptoms	Treatment	Survival
Barrs et al. [15]	61	Sphenoid	Diplopia	Unknown	Died 2 years after presentation
Barrs et al. [15]	57	Sphenoid	Diplopia, decreased visual acuity, ptosis, and numbness of the left face	Unknown	Died 2 years after presentation
McClatchey et al. [16]	54	Sphenoid	Frontal headache and blurring of the right eye	Radiotherapy	Alive 1 year after presentation
Leduc et al. [17]	75	Sphenoid	Diplopia and ptosis of the right eye	Pulpectomy	Alive 19 months after presentation
Matsumoto et al. [18]	79	Sphenoid	Headache and diplopia	Orchiectomy	Unknown
Har-el et al. [19]	77	Maxillary	Exophthalmos of the right eye	Orchiectomy and hormonal block	Unknown
Mickel and Zimmerman [20]	67	Sphenoid	Diplopia and numbness on the right side of the nose	Radiotherapy	Died 2 and a half months after presentation
Saleh et al. [21]	71	Sphenoid	Bilateral exophthalmos and hemoptysis	None	Died 1 month after biopsy
Fortson et al. [22]	50	Ethmoid	Nasal obstruction, diplopia, proptosis, and blurred vision	Chemotherapy and radiotherapy	Died 7 months after presentation
Telera et al. [23]	61	Sphenoid	Ptosis and diplopia of the right eye	Radiotherapy	Died 13 months after presentation
Oliver et al. [8]	72	Maxillary, frontal, and ethmoid	Frontal headache and retro-orbital pain	Hormonal block	Alive three months after presentation
Hunt et al. [11]	76	Sphenoid	Unknown	Radiotherapy and hormonal block	Alive 14 months after presentation
Lavasani et al. [24]	67	Sphenoid	Decreased visual acuity	Radiotherapy	Alive 6 months after presentation
Başeskioglu et al. [25]	69	Maxillary	Sinus fullness	Radiotherapy	Died 32 months after diagnosis
Ibarguren et al. [26]	64	Maxillary and frontal	Ptosis, proptosis, and facial numbness	Hormonal block and chemotherapy	Alive 8 months after presentation
El Khatib et al. [27]	57	Maxillary	Facial swelling	Pulpectomy and hormonal block	Died 9 months after presentation
Viswanatha [28]	68	Ethmoid and frontal	Facial swelling and epistaxis	Radiotherapy	Lost to follow-up after 3 months of presentation
Tunio et al. [29]	65	Ethmoid	Nasal obstruction, diplopia, and proptosis	Radiotherapy and hormonal block	Alive until article publication
Azarpira et al. [30]	74	Maxillary	Nasal obstruction	Chemotherapy and radiotherapy	Died 11 months after presentation
Petersson et al. [31]	55	Sphenoid	Headache, diplopia, and blurred vision	Hormonal block	Unknown
Puche-Sanz et al. [32]	56	Sphenoid	Decreased visual acuity and facial numbness	Radiotherapy and hormonal block	Alive 5 years after presentation
Akdemir et al. [33]	73	Frontal and ethmoid	Headache and exophthalmos	Hormonal block	Unknown
Evarts et al. [34]	59	Maxillary and ethmoid	Cheek numbness, headache, decreased visual acuity, nasal obstruction, and drainage	Chemotherapy	Died 2 months after biopsy
Lechien et al. [35]	67	Frontal	Diplopia, facial pain, and headache	Hormonal block	Died a few months after presentation
Present case	58	Ethmoid and maxillary	Epistaxis, nasal obstruction, and diplopia	None	Died 2 months after diagnosis

symptoms may also occur, such as proptosis, ptosis, decreased vision, and diplopia. Occasionally, these symptoms may be the first presentation of an occult primary tumor [8, 9].

The most frequent sites involved in prostate metastasis are the bone (90%), lung (46%), and liver (25%) [10]. The head and neck are rare locations for metastasis, and it occurs more frequently in the brain, dura, and lymph nodes [11].

The treatment may be hormone therapy, chemotherapy, radioisotopes, and radiotherapy [12].

Metastasis may reach the paranasal sinuses by hematogenous, lymphogenous, or vertebral venous plexus pathways. First postulated by Batson [13], this low-pressure valveless system is a connection between deep pelvic veins, intercostal veins, vena cava, and the azygos system. A rise in the abdominal pressure might redirect the blood flux from the vena

cava system to the vertebral venous plexus. This flux alteration can allow the tumor to reach the paranasal sinuses [14].

This is the twenty-fifth reported case of metastatic prostate adenocarcinoma in the paranasal sinuses. The majority of cases involved patients with known prostate cancer, with a mean age of 63.15 years, and the most affected sinus was the sphenoid (44.5%). Radiotherapy was the preferred treatment option (40.7%). In Table 1, we describe the cases reported in full text, available online so far.

Imaging is not able to differentiate a local tumor from a metastasis; however, it is essential to determine location and extension and for surgical planning. CT may show enhancement, bone erosion, remodeling, and invasion. Magnetic resonance imaging (MRI) has an important role to help, defining leptomeningeal and orbital invasion [13]. Positron emission tomography (PET-CT) might be useful in the primary occult tumor.

Histopathology has an essential role in the diagnosis. When metastasizing to the paranasal sinuses, normally prostate carcinoma is not well differentiated. Immunohistochemical panel is also important, with positivity of prostate-specific antigen, prostate acid phosphatase, EpCam, NKX3.1, and prostein [36].

Usually, the diagnosis of a metastasis to the paranasal sinuses means a poor prognosis. An important factor that can be crucial is whether the metastasis is isolated or part of a widespread disease.

Normally, the treatment involving the metastasis to the paranasal sinuses is palliative, with the exception of an isolated metastasis, for which the radical surgery may be a viable option. The patient's quality of life should be a priority. The main goal is pain relief and bleeding prevention. Management has not changed greatly over the years, and therapy options include radiotherapy, chemotherapy, immunotherapy, and, more recently, endoscopic surgery [37].

Endoscopic surgery may provide symptom relief faster, with lower systemic and local side effects [37]. Tabae et al. suggested three criteria to help in the decision of the surgery: reasonable expectation of improvement, possible prolongation of life, and survivability after anesthesia [38].

#### 4. Conclusion

Despite being a rare entity, metastatic prostatic tumor in the paranasal sinuses should always be part of the differential diagnosis in patients with known prostatic tumor and recently developed nasal or orbital symptoms.

#### Conflicts of Interest

The authors declare that they have no conflicts of interest.

#### References

- [1] P. Bossi, D. Farina, G. Gatta, D. Lombardi, P. Nicolai, and E. Orlandi, "Paranasal sinus cancer," *Critical Reviews in Oncology/Hematology*, vol. 98, pp. 45–61, 2016.
- [2] L. Barnes, J. W. Eveson, P. Reichart, and D. Sidransky, *World Health Organization Classification of Tumours, Pathology and Genetics, Head and Neck Tumours*, IARC Press, Lyon, France, 2005.
- [3] A. Jemal, R. Siegel, and E. Ward, "Cancer statistics, 2008," *CA: A Cancer Journal for Clinicians*, vol. 58, no. 2, pp. 71–96, 2008.
- [4] B. Carlotta, A. Auvinen, M. J. Roobol et al., "Metastatic prostate cancer incidence and prostate-specific antigen testing: new insights from the European randomized study of screening for prostate cancer," *European Urology*, vol. 68, no. 5, pp. 885–890, 2015.
- [5] V. J. Lund, H. Stammberger, P. Nicolai et al., "European position paper on endoscopic management of tumours of the nose, paranasal sinuses and skull base," *Rhinology Supplement*, vol. 22, no. 1, pp. 1–143, 2010.
- [6] A. Prescher and D. Brors, "Metastases to the paranasal sinuses: case report and review of the literature," *Laryngorhinootologie*, vol. 80, no. 10, pp. 583–594, 2001, in German.
- [7] J. M. Bernstein, W. W. Montgomery, and K. Balogh Jr., "Metastatic tumors to the maxilla, nose, and paranasal sinuses," *Laryngoscope*, vol. 76, no. 4, pp. 621–650, 1966.
- [8] V. J. Oliver, A. L. Valdés, A. D. Morillo et al., "Frontal ethmoid metastases of prostatic carcinoma. Report of one case and review of the literature," *Acta Otorrinolaringológica Española*, vol. 52, no. 2, pp. 151–154, 2001.
- [9] S. M. Lee, Y. M. Kim, and B. M. Kim, "Epistaxis as the first manifestation of silent renal cell carcinoma: a case report with relevant literature review," *Iran Journal of Radiology*, vol. 13, no. 1, p. e31208, 2016.
- [10] L. Bubendorf, A. Schopfer, U. Wagner et al., "Metastatic patterns of prostate cancer: an autopsy study of 1,589 patients," *Human Pathology*, vol. 31, no. 5, pp. 568–583, 2000.
- [11] J. L. Hunt, J. E. Tomaszewski, and K. T. Montone, "Prostatic adenocarcinoma metastatic to the head and neck and the workup of an unknown epithelioid neoplasm," *Head and Neck*, vol. 26, no. 2, pp. 171–178, 2004.
- [12] C. Gilson, T. Manickavasagar, and S. Chowdhury, "Treatment of metastatic prostate cancer," *Trends Urology & Men Health*, vol. 6, no. 4, pp. 7–12, 2015.
- [13] O. V. Batson, "The function of the vertebral veins and their role in the spread of metastases," *Annals of Surgery*, vol. 112, no. 1, pp. 138–149, 1940.
- [14] F. López, K. O. Devaney, E. Y. Hanna, A. Rinaldo, and A. Ferlito, "Metastases to nasal cavity and paranasal sinuses," *Head and Neck*, vol. 38, no. 12, pp. 1847–1854, 2016.
- [15] D. M. Barrs, T. J. McDonald, and J. P. Whisnant, "Metastatic tumors to the sphenoid sinus," *Laryngoscope*, vol. 89, no. 8, pp. 1229–1243, 1979.
- [16] K. D. McClatchey, R. V. Lloyd, and J. D. Schaldenbrand, "Metastatic carcinoma to the sphenoid sinus. Case report and review of the literature," *Archives Otorhinolaryngology*, vol. 241, no. 3, pp. 219–224, 1985.
- [17] D. Leduc, C. Massot, G. Crouzet et al., "Metastase sphenocaverneuse d'un cancer prostatique," *La Revue de Médecine Interne*, vol. 7, no. 1, pp. 70–73, 1986, in French.
- [18] I. Matsumoto, M. Furusato, L. Inomaia, T. Wada, and S. Aizawa, "Prostatic cancer presenting as metastatic adenocarcinoma of sphenoid sinus," *Acta Pathologica Japonica*, vol. 36, no. 11, pp. 1753–1756, 1986.
- [19] G. Har-el, I. Avidor, A. Weisbord, and J. Sidi, "Carcinoma of the prostate metastatic to the maxillary antrum," *Head and Neck*, vol. 10, no. 1, pp. 55–58, 1987.
- [20] R. A. Mickel and M. C. Zimmerman, "The sphenoid sinus—a site for metastasis," *Otolaryngology-Head and Neck Surgery*, vol. 102, no. 6, pp. 709–716, 1990.

- [21] H. A. Saleh, P. O'Flynn, and N. S. Jones, "Prostatic metastases in the nose and paranasal sinuses," *Journal of Laryngology Otolaryngology*, vol. 107, no. 7, pp. 629–632, 1993.
- [22] J. K. Fortson, Z. L. Bezmalinovic, and D. L. Moseley, "Bilateral ethmoid sinusitis with unilateral proptosis as an initial manifestation of metastatic prostate carcinoma," *Journal of the National Medical Association*, vol. 86, no. 12, pp. 945–948, 1994.
- [23] S. Telera, S. Carloia, D. Cavallotti, S. Bosco, M. Manni, and L. Cecconi, "Sphenoidal metastasis from prostate carcinoma. Case report and review of literature," *Neurochirurgie*, vol. 47, no. 1, pp. 61–65, 2001.
- [24] L. Lavasani, P. E. Zapanta, N. Tanna, and N. Sadeghi, "Metastasis of prostatic adenocarcinoma to the sphenoid sinus," *Annals of Otolaryngology, Rhinology & Laryngology*, vol. 115, no. 9, pp. 690–693, 2006.
- [25] B. Başeskioglu, S. Eşklçorapçı, S. Ekici, D. E. Baydar, S. Kendi, and H. Özen, "Maxillary sinus metastasis of prostate cancer: a case report," *Turkish Journal of Cancer*, vol. 36, no. 2, pp. 79–81, 2006.
- [26] R. L. Ibarguren, J. G. Rodríguez, A. V. Mateos, I. A. Arin, I. O. Grasa, and C. P. Peña, "Metástasis en senos paranasales secundaria a adenocarcinoma prostático," *Archivos Españoles de Urología*, vol. 60, no. 9, pp. 1137–1140, 2007, in Spanish.
- [27] K. El Khatib, K. Moufid, A. Abouchadi, M. Nassih, and A. Rzin, "Maxillary metastasis revealing a prostate cancer," *Revue Stomatologie Chirurgie Maxillo-Faciale*, vol. 108, no. 5, pp. 468–469, 2007, in French.
- [28] B. Viswanatha, "Prostatic carcinoma metastatic to the paranasal sinuses: a case report," *Ear Nose Throat Journal*, vol. 87, no. 9, pp. 519–520, 2008.
- [29] M. A. Tunio, M. Rafi, R. Mohsin, A. Hashmi, S. Raza, and M. Mubarak, "Ipsilateral ethmoid sinuses metastasis and proptosis: rare presentation of metastatic prostate cancer," *Pakistan Journal of Medical Sciences*, vol. 27, no. 1, pp. 212–213, 2011.
- [30] N. Azarpira, M. J. Ashraf, B. Khademi, and N. Asadi, "Distant metastases to nasal cavities and paranasal sinuses case series," *Indian Journal of Otolaryngology Head Neck Surgery*, vol. 64, no. 4, pp. 349–352, 2011.
- [31] F. Petersson, T. S. Hui, D. Loke, and T. C. Putti, "Metastasis of occult prostatic carcinoma to the sphenoid sinus: report of a rare case and a review of the literature," *Head and Neck Pathology*, vol. 6, no. 2, pp. 258–263, 2012.
- [32] I. Puche-Sanz, F. Vázquez-Alonso, J. F. Flores-Martín, H. Almonte-Fernández, and J. M. Cózar-Olmo, "Sphenoid sinus metastasis as the presenting manifestation of a prostatic adenocarcinoma: case report and overview of the literature," *Case Reports in Oncological Medicine*, vol. 2012, Article ID 819809, 4 pages, 2012.
- [33] F. Akdemir, M. Aldemir, H. Çakar, and G. Güler, "Metastasis of prostate adenocarcinoma to the frontal and ethmoid sinus," *Turkish Journal of Urology*, vol. 42, no. 4, pp. 299–302, 2016.
- [34] M. Evarts, R. A. Schuster, M. Steehler, and K. Steehler, "Metastasis of prostate carcinoma to the paranasal sinuses: a case study," *Journal of Case Reports in Medicine*, vol. 5, pp. 1–3, 2016.
- [35] J. R. Lechien, J. Doyen, M. Khalife, and S. Saussez, "Prostatic carcinoma metastatic to frontal and cavernous sinuses: a case report," *Brazilian Journal of Otorhinolaryngology*, 2016. In press.
- [36] M. B. Amin, J. I. Epstein, T. M. Ulbright et al., "Best practices recommendations in the application of immunohistochemistry in the prostate: report from the International Society of Urologic Pathology consensus conference," *American Journal of Surgical Pathology*, vol. 38, no. 8, pp. 1017–1022, 2014.
- [37] J. M. Roberts, C. Brook, and S. Parnes, "Palliative endoscopic surgery for sinonasal metastases: a case report and literature review," *Ear Nose Throat Journal*, vol. 94, no. 2, pp. 24–26, 2015.
- [38] A. Tabae, G. Nyquist, V. K. Anand, A. Singh, A. Kacker, and T. H. Schwartz, "Palliative endoscopic surgery in advanced sinonasal and anterior skull base neoplasms," *Otolaryngology-Head and Neck Surgery*, vol. 142, no. 1, pp. 126–128, 2010.