

# Intrathyroidal ectopic thymus in children

## A benign lesion

Myung Hoon Bang, MD<sup>a</sup>, JinShik Shin, MD<sup>a</sup>, Kwan Seop Lee, MD, PhD<sup>b</sup>, Min Jae Kang, MD, PhD<sup>a,\*</sup>

### Abstract

As ultrasound is commonly used these days, more and more lesions are found incidentally, including simple cysts, isoechoic nodules, and hypoechoic nodules, such as ectopic thymus. We here report the prevalence of ectopic thymus and its natural course.

We retrospectively reviewed the charts of 690 subjects (342 males, 348 females) who were under 18 years old and had undergone neck or thyroid ultrasound at Hallym University Sacred Heart Hospital from January 2014 to June 2017. Ectopic thymus was defined when the incidental lesion was hypo- to iso-echoic compared to adjacent muscles with vascularity and did not have a connection to the thymus in the mediastinum.

Of the 690 children, 16 (9 males, 7 females; median and ranges of age at diagnosis, 13 months and 18 days to 10 years) were diagnosed as having ectopic thymus. The most common location of ectopic thymus was in the inferior aspect of the left thyroid lobe. The median and ranges of the longest diameter at the time of initial diagnosis was 22.5 mm and 8 mm to 38 mm, respectively. Four cases underwent follow-up ultrasound, of which 3 cases showed no change in size and 1 case showed decreased size.

Ectopic thymus should be kept in mind when a lesion is found in the neck and thyroid incidentally, and physicians should reassure parents about its benign course.

**Abbreviations:** AP = anterior posterior, CT = computed tomography.

**Keywords:** child, ectopic thymus, thyroid, ultrasonography

### 1. Introduction

Ultrasound is a noninvasive and radiation-free examination method compared to computed tomography (CT), so it is used as a first-time diagnostic tool for the evaluation of neck or thyroid lesions.<sup>[1]</sup> As its usage has been increasing, more and more lesions are found incidentally, including simple cysts, isoechoic nodules, and hypoechoic nodules, such as ectopic thymus.<sup>[2]</sup>

The thymus is a primary lymphoid organ that plays an important role in the differentiation of T-cell. The thymus is formed by a fusion of the right and left thymic rudiment, formed from the ectoderm of the third branchial cleft and the endoderm of the third branchial pouch, and moves caudally and medially from the pharyngeal region to the superior anterior mediastinum.<sup>[3]</sup>

Ectopic thymus is due to aberrant thymic migration during embryogenesis and is usually asymptomatic, so the majority of cases are found incidentally. However, when ectopic thymus is

mistaken for a malignant cervical mass or a thyroid nodule, this may lead to unnecessary surgeries or invasive diagnostic procedures.<sup>[4]</sup> Since the majority of ectopic thymus is located in the thyroid gland, patients visit an endocrinology clinic for further evaluations and management, but many pediatricians are not familiar with ectopic thymus. Therefore, we here report the prevalence of ectopic thymus and its natural course based on the experiences in a single center.

### 2. Materials and methods

We retrospectively reviewed the data of 690 subjects (342 males, 348 females) who were under 18 years old and had undergone neck or thyroid ultrasound at Hallym University Sacred Heart Hospital from January 2014 to June 2017. They were referred for a sonographic examination due to neck mass, goiter, or torticollis. Ultrasonographic examinations were performed using Philips IU 22 and EPIQ (Philips, US) with 5 to 12-MHz linear-array transducers and GE LOGIQ E9 (General Electric, US) with a 4 to 15-MHz linear-array transducer.

Ectopic thymus was defined when the incidental lesion had hypo- to iso-echogenicity compared to adjacent muscles with vascularity and did not have a connection to the thymus in mediastinum (Fig. 1). The location (the right-left/superior-inferior aspect of thyroid or another specific region), and size of the ectopic thymus were recorded. If there were follow-up images, they were also reviewed.

This study was approved by the Institutional Review Board of Hallym University Sacred Heart Hospital (IRB#2018-02-003).

### 3. Results

Ectopic thymus was incidentally found in 16 (9 males, 7 females) of 690 (2.3%) children who underwent neck or thyroid ultrasonography (Table 1). The age of the subject was a median

Editor: Neeraj Lalwani.

The authors report no conflicts of interest.

<sup>a</sup> Department of Pediatrics, <sup>b</sup> Department of Radiology, Hallym University Sacred Heart Hospital, Hallym University College of Medicine, Anyang, Korea.

\* Correspondence: Min Jae Kang, Department of Pediatrics, Hallym University Sacred Heart Hospital, Anyang-si, Gyeonggi-do, Korea (e-mail: mjkkang@hallym.or.kr).

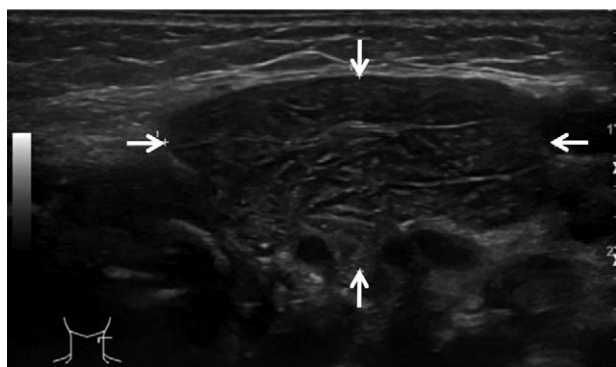
Copyright © 2018 the Author(s). Published by Wolters Kluwer Health, Inc. This is an open access article distributed under the terms of the Creative Commons Attribution-NonCommercial-ShareAlike 4.0 License, which allows others to remix, tweak, and build upon the work non-commercially, as long as the author is credited and the new creations are licensed under the identical terms.

Medicine (2018) 97:14(e0282)

Received: 24 November 2017 / Received in final form: 8 March 2018 /

Accepted: 12 March 2018

<http://dx.doi.org/10.1097/MD.00000000000010282>



**Figure 1.** The ultrasonographic finding of ectopic thymus is indicated with white arrows. The lesion was low-echoic compared to adjacent muscles with vascularity and without any connection to thymus in the mediastinum.

of 13 months with a range of 18 days to 10 years. The chief complaints that led to ultrasonography and the medians and ranges of their ages were as follows: torticollis (n=7), 2 months (18 days to 3 months); palpable swelling in the lateral neck (n=5), 5 years (11 months to 7 years); goiter (n=2), 5 years and 7 years old; congenital hypothyroidism (n=1), 28 months; follow-up imaging after thyroid cancer treatment (n=1), 10 years.

All lesions had low echogenicity with or without multiple echogenic dots inside, and the margins were well-defined. Four patients had lesions on both sides, and 12 patients had a unilateral lesion (8 on the left, 2 on the right, and 2 in the middle). The lesions were located at the inferior aspect of the thyroid lobe in all cases except for 1 subject who had ectopic thymus at both supraclavicular areas. The longest diameter of the ectopic thymus was measured in 14 patients, and the median and ranges were 22.5 mm and 8 to 38 mm, respectively.

A follow-up ultrasound was performed in 4 subjects and no changes of echogenicity were found in any of them. There were no size changes except for in 1 subject (case #16, Table 1). Case #16 underwent a Sistrunk operation at 9 years of age due to a thyroglossal duct cyst and was further diagnosed with papillary carcinoma. No ectopic thymus was found at the time of cancer diagnosis, but 1 year after the cancer treatment, ectopic thymus

was found incidentally on follow-up ultrasonography. At the 4-year follow up after cancer treatment, the left ectopic thymus had totally involuted and the size of the right ectopic thymus had decreased.

#### 4. Discussion

The prevalence of ectopic thymus was 2.3% (16/690) in this study. This is lower than previous studies, which reported 2.5% (9/350),<sup>[5]</sup> 3.9% (7/180),<sup>[3]</sup> and 17.3% (9/52).<sup>[2]</sup> A wide range of prevalence of ectopic thymus may majorly due to the different number of patients. Kim et al included 3195 patients and found the prevalence as 0.4% (12/3195).<sup>[6]</sup> The chief complaints that led to sonographic examination were various as our study: swelling or a palpable neck mass (n=4, 33.3%), an incidentally found thyroid abnormality on chest CT (n=3, 25%), a clinically suspected thyroid mass (n=2, 16.6%), hoarseness (n=1, 8.3%), incidentally found uptakes on positron-emission tomography scan (n=1, 8.3%), and during follow-up after resection of a thyroglossal duct cyst (n=1, 8.3%).<sup>[6]</sup>

The majority of ectopic thymus was located in the inferior aspect; none were found in the superior aspect of thyroid gland, which was similar to the findings of other studies.<sup>[3,7]</sup> Only 1 case had ectopic thymus at the supraclavicular area. The size of ectopic thymus was reported as average at 4×5 mm (APxtransverse) in the other study, which is smaller than in our study.<sup>[3]</sup> This difference may be due to the different ages of the patients since ectopic thymus is thought to follow the same growth trend as normal thymic tissue.<sup>[3]</sup>

No patients had symptoms related to ectopic thymus. The etiologies of neck masses in children are various, and many differential diagnoses are included, such as thyroglossal duct cyst, cystic hygroma, cervical lymphadenopathies, and tumors.<sup>[8]</sup> Nearly, all of the children's cervical masses, including ectopic thymus, were resected to confirm their pathologies. However, the diagnostic algorithm has been changed from performing an operation to conducting radiological imagings, particularly ultrasounds, due to technical developments such as the improvement of transducers and increased resolution.<sup>[9,10]</sup> In addition, since ectopic thymus has a unique appearance on ultrasound, it is recommended as a diagnostic modality of choice.<sup>[10]</sup>

**Table 1**

#### Characteristics of 16 subjects with ectopic thymus.

Case	Age	Gender	Chief complaint	Location	Initial size
1	18d	F	Torticollis	Inferior aspect of left thyroid lobe	31mm × 7mm
2	1mo	F	Torticollis	Inferior aspect of both thyroid	27mm × 38mm
3	1mo	M	Torticollis	Inferior aspect of left thyroid lobe	32mm × 16mm × 33mm
4	2mo	F	Torticollis	Inferior aspect of both thyroid lobe	
5	2mo	F	Torticollis	Inferior aspect of left thyroid lobe	26mm × 8mm
6	3mo	M	Torticollis	Both supraclavicular areas	Rt.: Transverse - 6mm Lt.: Transverse - 8mm
7	3mo	M	Torticollis	Inferior aspect of left thyroid lobe	Transverse - 8.4mm
8	11mo	F	Posterior neck mass	Inferior aspect of both thyroid lobe	Transverse - 24mm
9	15mo	M	Left neck mass	Inferior aspect of left thyroid lobe	Transverse - 34mm
10	4yr	F	Left neck mass	Inferior aspect of left thyroid lobe	9mm × 6mm × 20mm
11	5yr	M	Left neck mass	Inferior aspect of both thyroid lobe	
12	7yr	M	Right neck mass	Inferior aspect of right thyroid lobe	Transverse - 33mm
13	28mo	M	Congenital hypothyroidism	Inferior aspect of right thyroid lobe	12mm × 9mm × 15mm
14	5yr	F	Goiter	Inferior aspect of left thyroid lobe	Transverse - 21mm
15	7yr	M	Goiter	Inferior aspect of left thyroid lobe	6mm × 4mm × 10mm
16	10yr	M	Post-thyroid cancer treatment	Inferior aspect of both thyroid lobe	Rt.: 7mm × 8mm × 18mm Lt.: Transverse - 5.4mm

d=day, F=female, Lt.=left, M=male, mm=millimeter, mo=month, Rt.=right, yr=year.

There were 3 cases without size change and 1 case with involution in our study. In a study by Segni et al, 2 patients' lesions showed a reduction in size and 1 patient's lesion had increased in size and then become stable.<sup>[4]</sup> Kabaalioglu et al reported that of 12 followed-up patients, 1 patient's lesion had disappeared, 4 patients' lesions had decreased sizes, and 1 patient's lesion has grown in size, but become stable.<sup>[3]</sup> Therefore, all cases were shown as benign.

Since ectopic thymus may have multiple dots inside, it resembles calcification of the thyroid malignancies. However, ectopic thymus has well-defined margins, and most have no size changes. So goitrous patients should have regular follow-ups to detect size changes and perform additional diagnostic tools.

In conclusion, although ectopic thymus has low prevalence, it can be found incidentally in children. Therefore, clinicians should be aware of the benign course of ectopic thymus and reassure their parents.

### Author contributions

**Data curation:** J.S. Shin.

**Investigation:** K.S. Lee.

**Writing – original draft:** M.H. Bang.

**Writing – review & editing:** M.J. Kang.

### References

- [1] Brown RE, Harave S. Diagnostic imaging of benign and malignant neck masses in children-a pictorial review. *Quant Imaging Med Surg* 2016; 6:591–604.
- [2] Avula S, Daneman A, Navarro OM, et al. Incidental thyroid abnormalities identified on neck US for non-thyroid disorders. *Pediatr Radiol* 2010;40:1774–80.
- [3] Kabaalioglu A, Oztek MA, Kesimal U, et al. Intrathyroidal ectopic thymus in children: a sonographic survey. *Med Ultrason* 2017;19: 179–84.
- [4] Segni M, di Nardo R, Pucarelli I, et al. Ectopic intrathyroidal thymus in children: a long-term follow-up study. *Horm Res Paediatr* 2011; 75:258–63.
- [5] Carpenter GR, Emery JL. Inclusions in the human thyroid. *J Anat* 1976;122(Part 1):77–89.
- [6] Kim HG, Kim MJ, Lee MJ. Sonographic appearance of intrathyroid ectopic thymus in children. *J Clin Ultrasound* 2012;40:266–71.
- [7] Megremis S, Stiakaki E, Tritou I, et al. Ectopic intrathyroidal thymus misdiagnosed as a thyroid nodule: sonographic appearance. *J Clin Ultrasound* 2008;36:443–7.
- [8] Millman B, Pransky S, Castillo J3rd, et al. Cervical thymic anomalies. *Int J Pediatr Otorhinolaryngol* 1999;47:29–39.
- [9] Schloegel LJ, Gottschall JA. Ectopic cervical thymus: is empiric surgical excision necessary? *Int J Pediatr Otorhinolaryngol* 2009;73: 475–9.
- [10] Han BK, Yoon HK, Suh YL. Thymic ultrasound. II. Diagnosis of aberrant cervical thymus. *Pediatr Radiol* 2001;31:480–7.