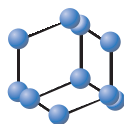


REVIEW ARTICLE

BENTHAM
SCIENCE

The Progress of Gene Therapy for Leber's Optic Hereditary Neuropathy

Yong Zhang¹, Zhen Tian¹, Jiajia Yuan², Chang Liu², Hong li Liu², Si Qi Ma² and Bin Li^{1,2,*}¹Department of Ophthalmology Shiyuan, Hubei University of Medicine - Taihe Hospital, Hubei, China; ²Department of Ophthalmology, Tongji Medical College, Huazhong University of Science and Technology - Tongji Hospital, Wuhan Shi, China

ARTICLE HISTORY

Received: June 23, 2017
Revised: November 16, 2017
Accepted: November 20, 2017DOI:
10.2174/1566523218666171129204926**Abstract: Introduction:** Leber's Optic Hereditary Neuropathy (LHON) is a common cause of teen-aged blindness in both eyes for which there is currently no effective treatment. In 1871, the German ophthalmologist Theodor Leber was the first to describe the clinical characteristics of his namesake disease, and through unremitting efforts over the past 100 years, researchers have continued to increase their understanding of LHON. In recent years, using gene therapy, several groups have obtained breakthroughs in the treatment of the disease.**Conclusion:** In this article, we will review the challenging journey that researchers faced towards our current understanding of LHON, and describe the transition of gene therapy research for LHON from the bench to bedside.**Keywords:** Leber's optic hereditary neuropathy, Gene therapy, Translational medicine, Mitochondrial disease, MT-ND4, Allo-topic expression technology.

1. LEBER'S HEREDITARY OPTIC NEUROPATHY

1.1. Overview

Leber's Hereditary Optic Neuropathy (LHON) is a hereditary disease causing blindness in both the eyes in teenagers [1, 2]. It was first reported in 1858, and in 1871, the German ophthalmologist T. Leber was the first to describe the clinical characteristics of this disease, which is named after him [3]. In 1972, Erickson proposed that LHON was a classical maternally inherited disease [4] because most patients are male [5]. The clinical presentation of LHON is the simultaneous or sequential painless loss of vision with either an acute or subacute onset, which is accompanied with a deficiency in the central visual field and defects in color vision [6-8]. There are no effective treatments for LHON and once the disease manifests, only a minority of affected individuals will self-recover, whereas most patients will eventually be completely blind. Because of the severity of the condition and its early onset in life, LHON has been the focus of researchers, clinicians, and healthcare professionals who have been searching since its discovery for an understanding of its etiology and underlying mechanism as well as efforts towards developing an effective treatment of the disease.

The completion of the Human Genome Project was a major advancement in medicine enabling researchers to identify and characterize the causes of many diseases. In fact, some

researchers have used bioengineering techniques to study the etiology and mechanisms of LHON at the molecular level. In 1988, Wallace *et al.* [9] found a mutation in *MT-ND4* (m.11778G>A) in mitochondrial DNA (mtDNA) that was associated with LHON. This discovery was a major breakthrough as it determined the main etiopathology of LHON, as a mitochondrial disorder. The identification of this mutation was followed by the discovery of other mtDNA mutations, such as m.3460G>A [10] and m.14484T>C [11]. Subsequently, researchers have found over 50 mtDNA mutations that are associated with LHON, and our understanding of the pathogenic mechanisms of LHON continues to improve.

The aim of medical research is to benefit patients conferring improved quality of life both for themselves as well as for their family members. Human eyes are confined spheres and this unique structural feature is a major reason that eyes are a favorable site for gene therapy. Because our understanding of the pathogenic causes and mechanisms of LHON has been continuously increasing, we believe that the time has arrived towards using gene therapy for the treatment of LHON. However, despite an improved understanding of the disease, there is still a distance required for a breakthrough in gene therapy taking it from the bench and translating it to the bedside as an effective clinical treatment approach. In 2007, three groups in the United States and the United Kingdom successfully carried out clinical trials on gene therapy for Leber congenital amaurosis (LCA) [12, 13] providing satisfactory results [14, 15]. These studies opened a new chapter and provided references in the use of gene therapy demonstrating its potential as a valid treatment option of eye diseases. Globally, there are many groups including ourselves

*Address correspondence to this author at the Department of Ophthalmology Shiyuan, Hubei University of Medicine - Taihe Hospital, Hubei, China; E-mail: libin-12@163.com

who are pursuing translational medicinal research in LHON to bridge this distance from the bench to the bedside [16-26] and bring hope to the many patients with LHON and their families in the next 10 years.

1.2. Epidemiology

LHON can occur at any age group, but occurs mostly in teenagers [27], with a modal age of onset between 15-20 years [28]. The disease has two major characteristics consisting of incomplete penetrance and occurring mainly in males. Epidemiological studies in Europe found that the incidence of LHON varies between countries [29, 30]. The highest incidence for LHON was reported in Northeastern England with an incidence of approximately 1 in 25 000 and a gene mutation rate of 1.18/10 000, whereas the Netherlands and Finland reported lower incidences of 1 in 39 000 and 1 in 50 000, respectively [31-34]. To date, there are no data from large-sample epidemiological studies in Asia.

1.3. Mutation Sites

Since Wallace *et al.* [35] found the first mutation for LHON in *MT-ND4* (m.11778G>A) in 1998, 50 mtDNA mutations have been associated with the disease. These mutations can be classified as primary or multi-site mutations.

1.3.1. Primary Mutations

Primary mutations specifically occur in families with LHON and any one of which can cause the disease. Common primary mutations include m.11778G>A, m.3460G>A, and m.14484T>C, and some reports have shown that 90% of patients with LHON were because of mutations in one of these three sites [1, 2, 36]. Therefore, the detection of these three mutations has become the gold standard in LHON diagnosis. The frequency of these mutations in patients with LHON varies by ethnicity. In Asia, the frequency of m.11778G>A, m.3460G>A, and m.14484T>C in LHON are 87%-92.9%, 1.4%-4%, and 5.7%-9%, respectively. In the mainland China, m.11778G>A is the most common mutation found in approximately 90% of patients, of which 80% were male [37, 38]. The frequency of m.11778G>A in the Middle East is similar to that found in Asia [39], whereas in Europe, the frequency of m.11778G>A, m.3460G>A, and m.14484T>C is 50%-70%, 15%-25%, and 15%, respectively. In addition to these three common primary mutations, other lower-frequency primary mutations such as m.3635G>A have been reported [40].

1.3.2. Multi-site Mutations

Multi-site LHON mutations are found in families and can also occur in the normal population. However, the frequency of LHON in family members with an affected individual is higher than that found in the general population. Multi-site mutations such as m.3394T>C cannot cause LHON alone, but may confer a phenotypic effect through cooperation with a primary causative LHON mutation [41]. The other multi-site mutations may result in phenotypic variability in affected patients. We have been interested in multi-site mutations and have performed related research.

1.4. Clinical Presentation

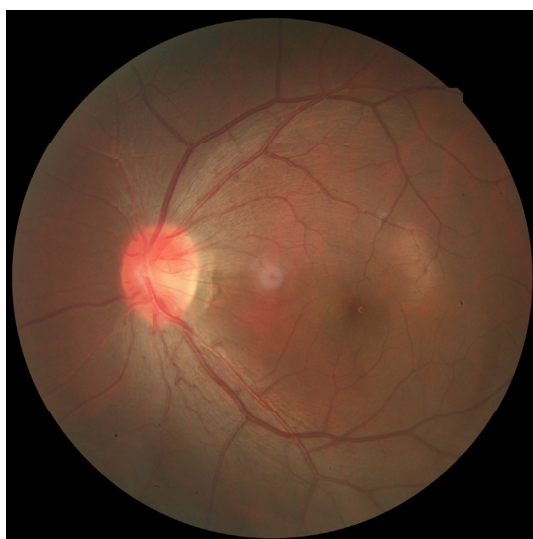The clinical presentation of LHON is the simultaneous or sequential onset of acute or subacute painless vision loss in both the eyes. The course of the disease is classified according to disease progression into presymptomatic, acute, and atrophic stages. Patients are normally diagnosed in the presymptomatic stage during family screening without obvious clinical presentations. In the acute stage, the vision of patients rapidly decreases [42] and vision acuity reaches a nadir at 4-6 weeks based on common indices or hand motion. Simultaneous or sequential onset of vision loss in both eyes occurs in 25% and 75% of patients, respectively [43]. During this stage, most patients present with a classical triad consisting of a swelling of the nerve fiber layer around the optic disc, circumpapillary telangiectatic microangiopathy (Fig. 1), and the absence of fluorescent leakage in fluorescein angiography. Visual field and color vision testing can show deficiency in the central visual field (Fig. 2) and color vision defects, respectively. During the atrophic stage, the main pathological processes are optic nerve atrophy and thinning of the retinal nerve fiber layer with no other specific clinical manifestations. It has been reported that some patients with LHON experience vision recovery including recovery of the visual field and color vision [44]. This stage may be considered a recovery stage; however, such patients are in minority. Several studies have found that vision recovery is associated with specific mtDNA mutations. Those patients with LHON caused by m.14484T>C were the most likely to experience vision recovery followed by patients harboring m.3460G>A. In contrast, patients with m.11778G>A had the least vision recovery [2, 11, 28, 45]. This variable recovery response in patients with different mutations may be because of differences in the condition of the eye and of the body itself during disease onset.

2. BASIC RESEARCH ON LHON

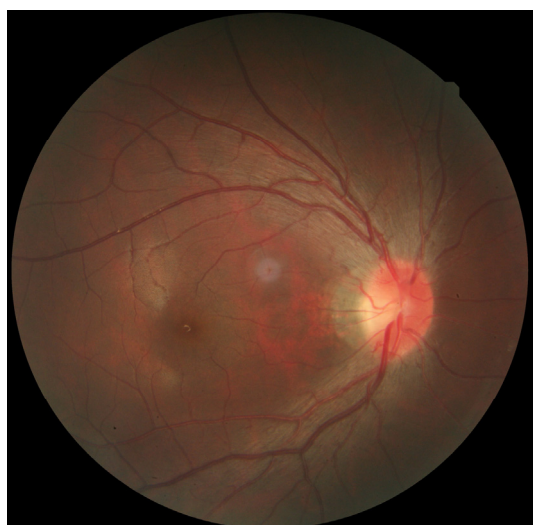Mitochondria are organelles in eukaryotic cells with independent genetic systems. The complete mtDNA genome consists of 16 569 base pairs in a double-stranded, close-loop structure and 37 genes that encode polypeptides associated with oxidative phosphorylation as well as 2 rRNA, 22 tRNA, and 13 RNA encoding for polypeptides associated with oxidative phosphorylation [46]. Although the mitochondrial genome can operate independently, it is largely regulated by nuclear genes. Therefore, mutations in either mitochondrial and/or nuclear-related genes involved in mitochondrial function can lead to defects and cause mitochondrial-related diseases [47].

Mitochondria are the location where oxidative phosphorylation occurs inside eukaryotic cells, providing 95% of the energy needed for an organism's metabolism. Mitochondria can also participate in cellular apoptosis. It is a major source of intracellular reactive oxygen species (ROS) and plays an indispensable function in maintaining optic nerve function. Because of its important biological functions, mutations in mtDNA can impair mitochondrial function that leads to an increased energy demand and damage to ROS-sensitive retinal ganglion cells. The result is vision impairment and is likely the underlying mechanism of LHON [28, 48-50]. Researchers have found that 95% of patients with LHON are associated with one of the three primary mtDNA

mutations, m.11778G>A, m.3460G>A, or m.14484T>C, and therefore, these mutations are considered necessary for LHON pathogenesis [51-53]. In addition, these primary mutations are found in genes that encode complex I of the respiratory chain. Hence, current research on LHON has focused on identifying mutations in complex I-related mitochondrial genes, specifically *ND1* to *ND6* (also known as mitochondrially encoded NADH:ubiquinone oxidoreductase core subunits 1 to 6), with a particular focus on *MT-ND4*, which is the site of the most commonly reported mutation in patients with LHON, m.11778G>A [54]. Studies have found that mutations, at this site, result in decreased activity of respiratory complex I that leads to a slowing of cellular respiration and decrease in production efficiency, which eventually leads to damage of the optic nerve [55-58].



(A)



(B)

Fig. (1). Fundus color images during the acute stage of LHON. (A, B) Swelling of the nerve fiber layer around the optic disc, circum-papillary telangiectatic microangiopathy, and presence of the optic nerve boundary can be observed. (For interpretation of the references to color in this figure legend, the reader is referred to the web version of this paper.)

Because the *MT-ND4* 11778G>A point mutation is the most common causative mutation found in patients with LHON, it has been the focus of previous gene therapy efforts. In 1998, Guy *et al.* [59] attempted gene therapy using allotropic expression technology [60] to transfer normal (wild type) *MT-ND4* into cells, which will then be translated into functional protein. NADH-ubiquinone oxidoreductase chain 4 (ND4) was imported into mitochondria rather than to its typical target, the nucleus, by addition of a mitochondrial targeting sequence (MTS) to the capsid [61] and the imported wild type *MT-ND4* resulted in recovery of production efficiency in some damaged mitochondria, which achieved the aim of restoring cellular function and confirmed that gene therapy is theoretically feasible. To overcome the limitations of *in vitro* cell experiments, some researchers [62] constructed animal models and used allotropic expression technology to transfer both wild type *MT-ND4* and mutated *MT-ND4* containing the 11778G>A point mutation into the eyes of rabbits. They found that mutated *MT-ND4* resulted in damage to retinal ganglion cells, whereas no such effects were observed with wild type *MT-ND4*. In 2009, Guy *et al.* [63] used injection into the vitreous cavities of eyes to successfully transfer copies of *MT-ND4* into mice using constructed AAV-ND4 vectors. They found that injection of wild type *MT-ND4* did not cause damage to mouse optic nerves, a finding that confirmed the intravitreal injection of drugs was a safe approach for gene therapy.

These studies provided the basis in theory for the feasibility, efficacy, and safety of gene therapy for LHON.

3. CLINICAL TREATMENT FOR LHON

Since the discovery of LHON, various methods and techniques including traditional Chinese medicine, western medicine, acupuncture, infrared, stem cells, and biological agents, especially idebenone [64, 65] have been attempted for the treatment of LHON. A multicenter clinical study of idebenone treatment for LHON was conducted in Europe in 2007, but upon its conclusion in 2011, their results showed no significant effect [66, 67].

Stem cells therapy was another approach considered to have good potential [68]. However, key issues remain unresolved in stem cell therapy of LHON, and that there is still some distance before clinical applications may be realized.

4. GENE THERAPY FOR LHON

In gene therapy for LHON, normal (wild type) unmutated *MT-ND4* is transferred into the cells of a patient that contain mutated *MT-ND4*. This wild type gene will then be encoded into properly functioning ND4 that will be imported into mitochondria to replace the mutated ND4. This replacement rescues the physiological function of the protein in its role in cellular respiration, thereby achieving the aim of treating LHON. ND4, ND1, and ND2 form complex I in mitochondria (Fig. 3) and repairing ND4 enables resumption of normal physiological functions inside mitochondria.

In 2011, we performed the first LHON gene therapy study in the world by injecting 0.05 mL of AAV2-ND4 in the vitreous cavity of a single eye, and completed the treatment of another eight patients in 2 years [22]. In the




Fig. (2). Visual field presentation during the acute stage of LHON. Note deficiency of the central visual field.

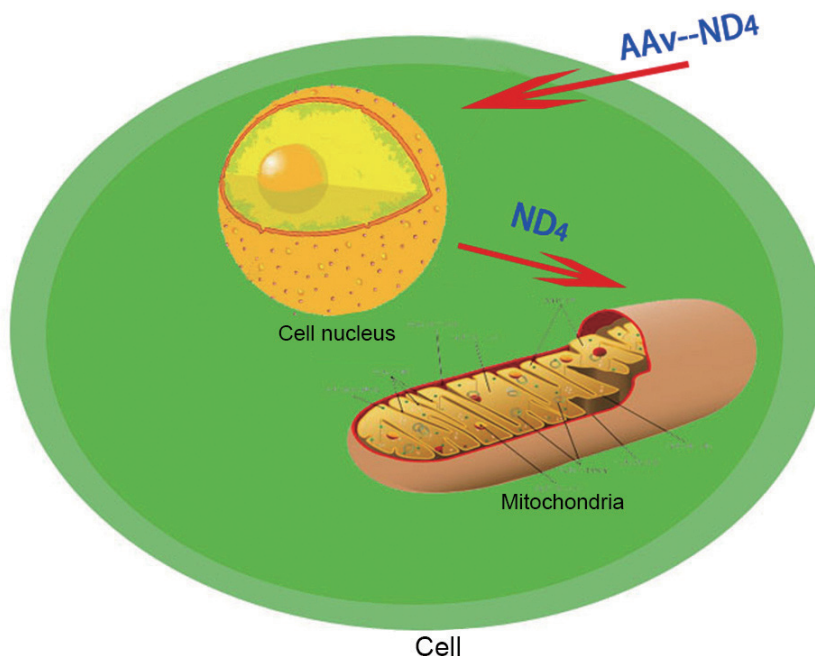


Fig. (3). Allotropic expression of AAV2-ND4 effector mechanism. AAV2 transports normal (wild type) *MT-ND4* into nodular cells, which is translated into ND4 in the cytoplasm. Under the guidance of a MTS, ND4 is imported into mitochondria to carry out its biological functions.

subsequent 36-month follow-up period, none of the nine patients experienced serious adverse events either in their eye or in their entire body. Using measures of best-corrected visual acuity (BCVA) compared to baseline, six of the nine patients exhibited improvement. Based on visual field tests compared to baseline measurements, we found that seven patients exhibited progress. From results of other observational markers, such as retinal nerve fiber layer thickness and visual evoked potential (VEP), all patients showed improvements compared to baseline measures before therapy.

In 2014, Guy *et al.* [69] performed a prospective, open-label clinical trial where his team designed, constructed, and

injected AAV2-P1ND4-v2 into the vitreous cavity of a single eye. The five patients recruited in their study were divided into groups and given low, medium, or high therapeutic doses. After a 6-month follow-up, no serious adverse events because of treatment were observed in any of the patients. In addition, two patients exhibited significant improvements in visual acuity, whereas no significant changes were found in the other three patients.

In 2015, GenSight Biologics carried out a clinical trial on LHON gene therapy by injecting GS0101 into the vitreous cavity of a single eye in 15 patients. In the 48-week follow-up period, they found improved visual acuity in patients with

a disease course less than 2 years, whereas patients with a disease course greater than 2 years did not exhibit any significant change.

Those studies showed that gene therapy for LHON may be achievable and effective based on current scientific progress.

CONCLUSION AND PROSPECTS

After decades of exploration and development, gene therapy is gradually maturing for clinical use. Over the past decade, clinical research of gene therapy for eye disease has flourished and some studies have achieved initial success [70-74]. Ophthalmology has entered an era of gene therapy.

Reviewing the research progress of gene therapy for LHON, the progression from concept to clinical testing has been gradual from the discovery of LHON gene mutation sites to the feasibility of gene therapy, from building the AAV2-ND4 construct to determine the effectiveness of cell and animal experiments, and finally, from clinical treatment studies to determine clinical observation indicators to gene therapy implementation. In the future, large-sample, multi-center, randomized controlled trials are needed to validate the safety and efficacy of gene therapy for LHON in every stage.

During our investigation, the findings from three independent research teams showed improvement in visual acuity in both eyes after injecting AAV2-ND4 in the vitreous cavity of a single eye in patients, a finding that astonished everyone. To answer this question, researchers returned to the laboratory. The results of animal experiments in one study [19] showed that injection of AAV2-ND4 in a single eye with resulting improvements in visual acuity in both eyes may be because there is a degree of axonal connectivity between the two optic nerves, which results in both eyes receiving the injected construct.

This process illustrates the need in the present day where specialization is increasing, and it is only through close cooperation and collaboration between molecular biologists, clinicians, and healthcare professionals that we can make the transition from bench to bedside for gene therapy for LHON. Laboratory and clinical research should be integrated using clinical problems as a guide for laboratory research, and furthermore, using clinical research and testing to validate research findings from the laboratory. Only through this concerted effort, we can make the successful transition from bench to bedside for the eventual benefit for all patients.

CONSENT FOR PUBLICATION

Not applicable.

CONFLICT OF INTEREST

This research was supported by the National Nature Science Foundation of China (Grant #81271015 , #81770969) and the 2016 Huazhong University of Science and Technology Independent Innovation Fund Major Project (2016 YXZD022). The authors report no conflict of interest.

ACKNOWLEDGEMENTS

We would like to express our appreciation to everyone who was involved in the drafting and preparation of the manuscript.

REFERENCES

- [1] Man PYW, Turnbull DM, Chinnery PF. Leber hereditary optic neuropathy. *J Med Genet* 2002; 39(3): 162-9.
- [2] Man PYW, Griffiths PG, Brown DT, *et al.* The epidemiology of Leber hereditary optic neuropathy in the North East of England. *Am J Hum Genet* 2003; 72(2): 333-9.
- [3] Leber TH. Über hereditäre und congenital-angelegte Sehnervenleiden. *Graefes Arch Clin Exp Ophthalmol* 1871; 17(2): 249-91.
- [4] Erickson RP. Leber's optic atrophy, a possible example of maternal inheritance. *Am J Hum Genet* 1972; 24: 348-9.
- [5] Puomila A, Hamalainen P, Kivioja S, *et al.* Epidemiology and penetrance of Leber hereditary optic neuropathy in Finland. *Eur J Hum Genet* 2007; 15: 1079-89.
- [6] Newman NJ, Wallace DC. Mitochondria and Leber's hereditary optic neuropathy. *Am J Ophthalmol* 1990; 109(6): 726-30.
- [7] Carelli V, La Morgia C, Valentino ML, *et al.* Retinal ganglion cell neurodegeneration in mitochondrial inherited disorders. *Biochimica et Biophysica Acta* 2009; 1787(5): 518-28.
- [8] Brown MD, Wallace DC. Spectrum of mitochondrial-DNA mutations in Lebers hereditary optic neuropathy. *Clin Neurosci* 1994; 2(2): 138-45.
- [9] Wallace DC, Singh G, Lott MT, *et al.* Mitochondrial DNA mutation associated with Leber's hereditary optic neuropathy. *Science* 1988; 242(4884): 1427-30.
- [10] Huoponen K, Vilkkii J, Aula P, *et al.* A new mtDNA mutation associated with Leber hereditary optic neuroretinopathy. *Am J Hum Genet* 1991; 48: 1147-53.
- [11] Mackey D. A variant of Leber hereditary optic neuropathy characterized by recovery of vision and by an unusual mitochondrial genetic etiology. *Am J Hum Genet* 1992; 51: 1218-28.
- [12] Maguire AM, Simonelli F, Pierce EA, *et al.* Safety and efficacy of gene transfer for Leber's congenital amaurosis. *N Engl J Med* 2008; 358: 2240-8.
- [13] Bainbridge JW, Smith AJ, Barker SS, *et al.* Effect of gene therapy on visual function in Leber's congenital amaurosis. *N Engl J Med* 2008; 358: 2231-9.
- [14] Hauswirth WW, Aleman TS, Kaushal S, *et al.* Treatment of leber congenital amaurosis due to RPE65 mutations by ocular subretinal injection of adeno-associated virus gene vector: Short-term results of a phase I trial. *Hum Gene Ther* 2008; 19(10): 979-90.
- [15] Hufnagel RB, Ahmed ZM, Correa ZM, *et al.* Gene therapy for Leber congenital amaurosis: Advances and future directions. *Graefes Arch Clin Exp Ophthalmol* 2012; 250: 1117-1128.
- [16] Shi H, Gao J, Pei H, *et al.* Adeno-associated virus-mediated gene delivery of the human ND4 complex I subunit in rabbit eyes. *Clin Exp Ophthalmol* 2012; 40(9): 888-94.
- [17] Cui G, Ding H, Xu Y, *et al.* Applications of the method of high resolution melting analysis for diagnosis of Leber's disease and the three primary mutation spectrum of LHON in the Han Chinese population. *Gene* 2013; 512(1): 108-12.
- [18] Pei H, Wan X, Hu W, *et al.* Construction and detection of a novel type of recombinant human rAAV2/2-ND4. *Eye Sci* 2013; 28(2): 55-9.
- [19] Shuo Y, Heng H, Zhu Y, *et al.* Chemical and material communication between the optic nerves in rats[J]. *Clin Exp ophthalmol* 2015, 43(8): 742-8.
- [20] Wan X, Pei H, Zhao M, *et al.* Efficacy and safety of rAAV2-ND4 treatment for Leber's hereditary optic neuropathy. *Sci Rep* 2016; 6: 21587.
- [21] Ruijin Ran, Shuo Yang, Heng He, *et al.* A retrospective analysis of characteristics of visual field damage in patients with Leber's hereditary optic neuropathy. *Springer Plus* 2016; 5(1): 1-6.
- [22] Shuo Y, Ma S, X Wan, *et al.* Long-term outcomes of gene therapy for the treatment of Leber's hereditary optic neuropathy. *Ebiomedicine* 2016, 10: 258-68.
- [23] Shuo Y, Hong Y, Ma S, *et al.* Evaluation of Leber's hereditary optic neuropathy patients prior to a gene therapy clinical trial. *Medicine* 2016; 95(40): e5110.

- [24] Feuer WJ, Schiffman JC, Davis JL, *et al.* Gene therapy for leber hereditary optic neuropathy: Initial results. *Ophthalmology* 2016; 123(3): 558-570.
- [25] Jing G, Hui S, Han P. Comparison of immunosuppressive effects and ND4 expression among different immunosuppressive strategies following AAV2-ND4 gene treatment for Leber hereditary optic neuropathy. *Acta Medicinæ Universitatis Scientiæ et Technologiæ Huazhong* 2013; 2: 14.
- [26] Guy J, Feuer WJ, Davis JL, *et al.* Gene therapy for leber hereditary optic neuropathy: Low- and medium-dose visual results. *Ophthalmology* 2017.05.016.
- [27] Testa F, Maguire AM, Rossi S, *et al.* Three-year follow-up after unilateral subretinal delivery of adeno-associated virus in patients with Leber congenital Amaurosis type 2. *Ophthalmology* 2013; 120(6): 1283-1291.
- [28] Fulda S, Kufer MU, Meyer E, *et al.* Sensitization for death receptor- or drug-induced apoptosis by re-expression of caspase-8 through demethylation or gene transfer. *Oncogene* 2001; 20(41): 5865
- [29] Yu-Wai-Man P, Griffiths PG. Mitochondrial optic neuropathies - disease mechanisms and therapeutic strategies. *Prog Retin Eye Res* 2011; 30: 81-114.
- [30] Yu-Wai-Man P, Griffiths P G, Hudson G, *et al.* Inherited mitochondrial optic neuropathies. *J Med Genet* 2009; 46(3):145-58.
- [31] Chinnery P F, Johnson M A, Wardell T M, *et al.* The epidemiology of pathogenic mitochondrial DNA mutations. *Ann Neurol* 2000; 48(2): 188-193.
- [32] Man PYW, Griffiths PG, Brown DT, *et al.* The epidemiology of Leber hereditary optic neuropathy in the North East of England. *Am J Hum Genet* 2003; 72(2):333-339.
- [33] Spruijt L, Kolbach DN, de Coo RF, *et al.* Influence of mutation type on clinical expression of Leber hereditary optic neuropathy. *Am J Ophthalmol* 2006; 141(4):676-682.
- [34] Puomila A, Hamalainen P, Kivioja S, *et al.* Epidemiology and penetrance of Leber hereditary optic neuropathy in Finland. *Eur J Hum Genet* 2007; 15(10):1079-89.
- [35] Bu-Amoro KK, Bosley TM, Bohlega S, *et al.* Complex I respiratory defect in LHON plus dystonia with no mitochondrial DNA mutation. *Br J ophthalmol* 2005; 89(10):1380-1.
- [36] Ryan SE, Ryan F, Barton D, *et al.* Development and validation of a novel PCR-RFLP based method for the detection of 3 primary mitochondrial mutations in Leber's hereditary optic neuropathy patients. *Eye and Vision* 2015; 2(1): 18.
- [37] Huoponen K, Vilkki J, Aula P, *et al.* A new mtDNA mutation associated with Leber hereditary optic neuroretinopathy. *Am J Hum Genet* 1991; 48(6): 1147-53.
- [38] Howell N, Bindoff LA, McCullough DA, *et al.* Leber hereditary optic neuropathy: Identification of the same mitochondrial ND1 mutation in six pedigrees. *Am J Hum Genet* 1991; 49(5):939-50.
- [39] Mashima Y, Yamada K, Wakakura M, *et al.* Spectrum of pathogenic mitochondrial DNA mutations and clinical features in Japanese families with Leber's hereditary optic neuropathy. *Curr Eye Res* 1998; 17(4): 403-8.
- [40] Zhang AM, Jia X, Guo X, *et al.* Mitochondrial DNA mutation m.3635G>A may be associated with Leber hereditary optic neuropathy in Chinese. *Biochem Biophys Res Commun* 2009; 386(2): 392-5.
- [41] Zhang M, Zhou x, Li c, *et al.* Mitochondrial haplogroup M9a specific variant NDI T3394C may have a modifying role in the phenotypic expression of the LHON-associated ND4 G11778A mutation. *Mol Genet Metab* 2010; 101(2-3):192-9.
- [42] Man PYW, Turnbull DM, Chinnery PF. Leber hereditary optic neuropathy. *J Med Genet* 2002. 39(3): 162-9.
- [43] Meunier I, Lenaers G, Hamel C, *et al.* Hereditary optic neuropathies:from clinical signs to diagnosis.*Journal francais d'ophtalmologie*2013; 36(10):886-900.
- [44] Nikoskelainen EK, Huoponen K, Juvonen V, *et al.* Ophthalmologic findings in Leber hereditary optic neuropathy, with special reference to mtDNA mutations. *Ophthalmol* 1996; 103(3): 504-14.
- [45] Klopstock T, Yu-Wai-Man P, Dimitriadis K, *et al.* A randomized placebo-controlled trial of idebenone in Leber's hereditary optic neuropathy. *Brain* 2011; 134(9): 2677-86.
- [46] DiMauro S, Schon EA. Mitochondrial respiratory-chain diseases. *N Engl J Med* 2003; 348(26): 2656-68.
- [47] DiMauro S, Davidzon G. Mitochondrial DNA and disease. *Ann Med* 2005; 37(3): 222-32.
- [48] Koilkonda RD, Guy J. Leber's hereditary optic neuropathy-gene therapy: From benchtop to bedside. *J Ophthalmol* 2010; 2011(2011): 16.
- [49] Brady ST, Lasek RJ, Allen RD. Video microscopy of fast axonal transport in extruded axoplasm:a new model for study of molecular mechanisms. *Cytoskeleton* 1985; 5(2): 81-101.
- [50] Chinnery PF, Andrews RM, Turnbull DM, *et al.* Leber hereditary optic neuropathy: Does heteroplasmy influence the inheritance and expression of the G11778A mitochondrial DNA mutation? *Am J Med Genet Part A* 2001; 98(3): 235-43.
- [51] Qu J, Li R, Zhou X, *et al.* The novel A4435G mutation in the mitochondrial tRNAMet may modulate the phenotypic expression of the LHON-associated ND4 G11778A mutation. *Invest Ophthalmol Vis Sci* 2006; 47(2): 475-83.
- [52] Qu J, Li R, Zhou X, *et al.* Cosegregation of the ND4 G11696A mutation with the LHON-associated ND4 G11778A mutation in a four generation Chinese family. *Mitochondrion* 2007; 7(1): 140-6.
- [53] Liang M, Guan M, Zhao F, *et al.* Leber's hereditary optic neuropathy is associated with mitochondrial ND1 T3394C mutation. *Biochem Biophys Res Commun* 2009; 383(3): 286-92.
- [54] Zhou X, Zhang H, Zhao F, *et al.* Very high penetrance and occurrence of Leber's hereditary optic neuropathy in a large Han Chinese pedigree carrying the ND4 G11778A mutation. *Mol Genet Metabol* 2010; 100(4): 379-84.
- [55] Johns DR, Neufeld MJ, Park RD, *et al.* An ND-6 mitochondrial DNA mutation associated with leber hereditary optic neuropathy. *Biochem Biophys Res Commun* 1992; 187(3): 1551-7.
- [56] Man PY, Turnbull DM, Chinnery PF, *et al.* Leber hereditary optic neuropathy. *J Med Genet* 2002; 39(3): 162-9
- [57] Brown MD, Trounce IA, Jun, AS, *et al.* Functional analysis of lymphoblast and cybrid mitochondria containing the 3460, 11778, or 14484 leber's hereditary optic neuropathy mitochondrial DNA mutation. *J Biol Chem* 2000; 275(51): 39831-6.
- [58] Brown MD. The enigmatic relationship between mitochondrial dysfunction and Leber's hereditary optic neuropathy. *J Neurol Sci* 1999; 165: 1-5.
- [59] Guy J, Qi X, Pallotti F, *et al.* Rescue of a mitochondrial deficiency causing Leber Hereditary Optic Neuropathy. *Ann Neurol* 2002; 52(5): 534-42.
- [60] De Grey ADNJ. Mitochondrial gene therapy: An arena for the biomedical use of inteins. *Trends Biotechnol* 2000; 18(9): 394-9.
- [61] Yu H, Mehta A, Wang G, *et al.* Next-generation sequencing of mitochondrial targeted AAV transfer of human ND4 in mice. *Mol Vis* 2013; 19: 1482-91.
- [62] Bonnet C, Kaltimbacher V, Ellouze S, *et al.* Allotopic mRNA localization to the mitochondrial surface rescues respiratory chain defects in fibroblasts harboring mitochondrial DNA mutations affecting complex I or v subunits. *Rejuvenation Res* 2007; 10(2): 127-44.
- [63] Koilkonda RD, Chou TH, Porciatti V, *et al.* Induction of rapid and highly efficient expression of the human ND4 complex I subunit in the mouse visual system by self-complementary adeno-associated virus. *Arch Ophthalmol* 2010; 128: 876-83.
- [64] Mashima Y, Hiida Y. Remission of Leber's hereditary optic neuropathy with idebenone. *Lancet* 1992; 340: 368-9.
- [65] Meyerson C, Van Stavern G, McClelland C. Leber hereditary optic neuropathy: Current perspectives. *Clin Ophthalmol* 2015; 9: 1165.
- [66] Klopstock T, Yu-Wai-Man P, Dimitriadis K, *et al.* A randomized placebo-controlled trial of idebenone in Leber's hereditary optic neuropathy. *Brain* 2011; 134(9): 2677-86.
- [67] Newman NJ. Treatment of Leber hereditary optic neuropathy. *Brain* 2011; 134(9): 2447-50.
- [68] Vugler A, Carr AJ, Lawrence J, *et al.* Elucidating the phenomenon of HESC-derived RPE: Anatomy of cell genesis, expansion and retinal transplantation. *Exp Neurol* 2008; 214(2): 347-61.
- [69] Feuer WJ, Schiffman JC, Davis JL, *et al.* Gene therapy for Leber hereditary optic neuropathy: Initial results. *Ophthalmology* 2016; 123(3): 558-70.
- [70] MacLaren RE, Groppe M, Barnard AR, *et al.* Retinal gene therapy in patients with choroideremia: Initial findings from a phase 1/2 clinical trial. *Lancet* 2014; 383(9923):1129-37.
- [71] Boye SE, Boye SL, Lewin AS. A comprehensive review of retinal gene therapy. *Mol Ther* 2013; 21: 509-19.
- [72] Rakoczy EP, Lai CM, Magno AL, *et al.* Gene therapy with recombinant adeno-associated vectors for neovascular age-related macu-

- lar degeneration: 1 year follow-up of a phase 1 randomised clinical trial. *Lancet* 2015; 386(10011): 2395-403.
- [73] Nguyen QD, Schachar RA, Nduaka CI, *et al.* Phase 1 dose-escalation study of a siRNA targeting the RTP801 gene in age-related macular degeneration patients. *Eye* 2012; 26: 1099-105.
- [74] Moreno-Montañés J, Sádaba B, Ruz V, *et al.* Phase I clinical trial of SYL040012, a small interfering RNA targeting β -adrenergic receptor 2, for lowering intraocular pressure. *Mol Ther* 2014; 22: 226-32.