

# Transaxillary uniportal video assisted thoracoscopic surgery for right upper lobectomy

Yaxing Shen<sup>1\*</sup>, Yong Zhang<sup>2\*</sup>, Jianchao Sun<sup>3</sup>, Jianying Gu<sup>2</sup>, Yunfeng Yuan<sup>1</sup>, Qun Wang<sup>1</sup>

<sup>1</sup>Department of Thoracic Surgery, <sup>2</sup>Department of Plastic Surgery, Zhongshan Hospital of Fudan University, Shanghai 200032, China; <sup>3</sup>Department of Cardio-thoracic Surgery, Laiyang Central Hospital, Yantai 265200, China

\*These authors contributed equally to the work.

*Correspondence to:* Yunfeng Yuan, MD. Department of Thoracic Surgery, Zhongshan Hospital, Fudan University, 180 Fenglin Road, Shanghai 200032, China. Email: yuan.yunfeng@zs-hospital.sh.cn; Jianying Gu, MD. Department of Plastic Surgery, Zhongshan Hospital, Fudan University, 180 Fenglin Road, Shanghai 200032, China. Email: Gu.jianying@zs-hospital.sh.cn.

**Abstract:** Uniportal video-assisted thoracic surgery (VATS) was growing popular since its first introduction. Based on the conventional uniportal VATS, we modified the technique and introduced transaxillary uniportal VATS lobectomy in this case report. In March 2017, transaxillary uniportal VATS was firstly attempted on a patient suffering from right upper lobe lesion at the Department of Thoracic Surgery, Zhongshan Hospital, Fudan University. A 4-cm single incision was made at the fossa axillaris paralleled to the skin folds, to which a soft wound protector was applied to reach the third intercostal space along the anterior axillary line. The right upper lobectomy was performed through the transaxillary incision. The surgery was accomplished without conversion to thoracotomy or application of extra incision. The truncus anterior artery, the upper lobe bronchus and upper pulmonary vein was mobilized and dissected in order. The target lobe was removed through the fossa axillaris incision. The operation duration was 110 minutes with limited blood loss. The patient was discharged 3 days post-operatively. Transaxillary uniportal VATS lobectomy is safe and feasible, and the procedure showed cosmetic advantages. Further studies based on larger population are required to determine these findings.

**Keywords:** Uniportal surgery; transaxillary incision; video-assisted thoracic surgery (VATS); lobectomy; minimally invasive surgery

Submitted Jun 15, 2017. Accepted for publication Jul 26, 2017.

doi: 10.21037/jtd.2018.02.86

**View this article at:** <http://dx.doi.org/10.21037/jtd.2018.02.86>

## Introduction

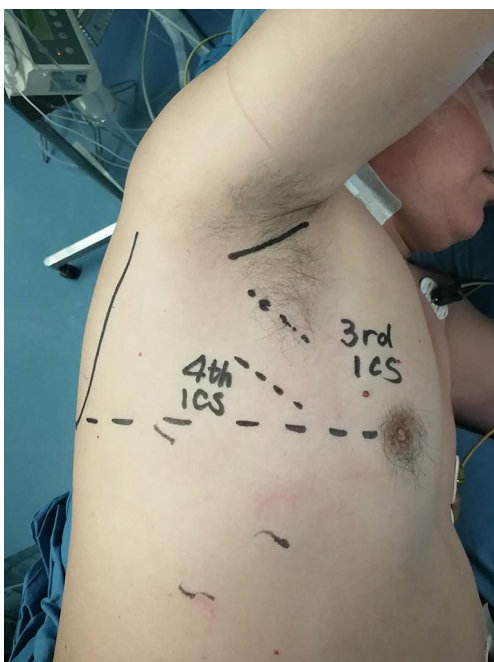
Uniportal video-assisted thoracic surgery (VATS) surgery was widely practiced since its first practice by Rocco. The single incision applied for thoracic surgery was made for less pain and cosmetic consideration. Meanwhile, continuous attempts were made to further modify this procedure and introduce our technique for uniportal VATS lobectomy through transaxillary incision.

## Case presentation

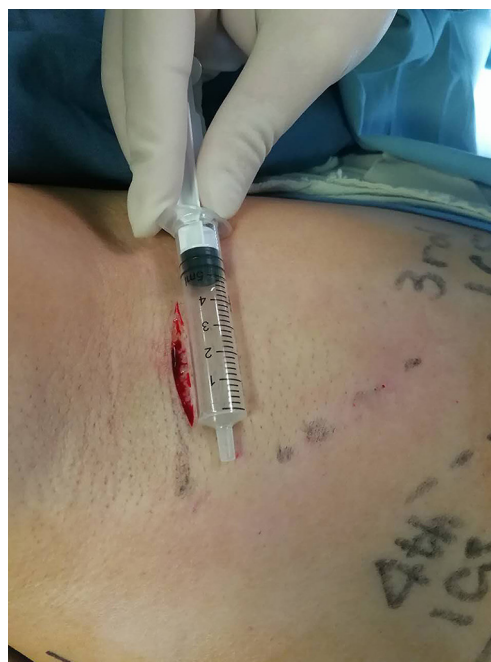### *Surgical technique of transaxillary uniportal VATS lobectomy*

### **Anesthesia and analgesia**

The patient received a combination of epidural and general anesthesia. After intravenous induction, he was intubated with a double-lumen endotracheal tube to accomplish single lung ventilation during the operation. Patient's vital signs were followed and recorded every five minutes throughout



**Figure 1** The patient's position of transaxillary uniportal VATS.



**Figure 2** The incision of transaxillary uniportal VATS.

the operation. After the surgery, the patient was extubated at the end of surgery and transferred to the ward with patient-controlled analgesia (PCA) equipped.

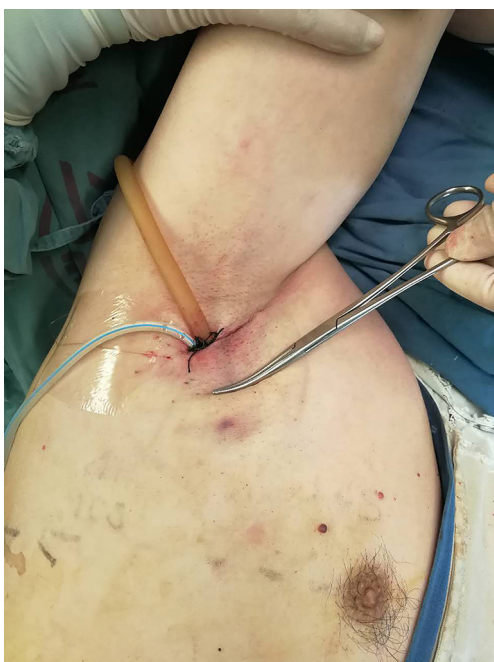#### Position and incision

The patient was kept in a folding knife gesture (with the cranial side slightly raised up and caudal side pushed down) in lateral decubitus position (*Figure 1*). The right arm was sanitized and draped to be mobilizable, facilitating the exposure of the incision during the surgery. Intraoperatively, the surgeons stood on the abdominal side of the patient. The entire procedure was performed under the screen observation and the surgical video was recorded (Karl Storz, GmbH & Co. Tuttlingen, Germany).

A 4-cm incision was made at the fossa axillaris area paralleled to the skin folds (*Figure 2*). The incision tunnels to the 3<sup>rd</sup> intercostal space at the anterior axillary line. A soft plastic wound protector was then applied to the incision without rib-spreading procedure. A 10-mm 30 degree thoracoscope (Karl Storz, GmbH & Co. Tuttlingen, Germany) was positioned in the superior side of the incision during the lobectomy. The curved surgical instruments, in together with the harmonic shear (Ethicon Endo-Surgery Inc., Cincinnati, OH, USA) or hook electrocautery were applied during the procedure.

After the introduction of thoracoscope, the exposure of the hilum was shown, which was similar to conventional uniportal VATS. The surgery started from the mobilization of truncus anterior branch along the right pulmonary artery. The Marshall space between the right pulmonary vein (V1a+b) and apical branch of the right pulmonary artery (A1) was exposed. The first branch (V1a) was ligated and dissected to facilitate the exposure of the apical branch (A1), which was cut by using endoscopic stapler. The mobilization and dissection of A3 and then A2 was accomplished after the apical branch. After the dissection of all branches of pulmonary arteries to the upper lobe, the mobilization of right upper bronchus was easy through the transaxillary incision. The horizontal fissure was cut open by using endoscopic staplers, which facilitated the mobilization of right upper pulmonary vein (central vein included). After the dissection of the vein, the right upper lung specimen was taken out by using the endoscopic specimen bag (Ethicon Endo-Surgery Inc., Cincinnati, OH, USA).

The specimen was then sent to the pathology for frozen section, and centralized 3.5 cm inflammatory pseudotumor was verified. The procedure was disclosed after lung re-expansion and careful check for the potential bleeding sites. A 20-Fr chest tube, in together with a negative-pressure bulb were inserted at the end of the operation (*Figure 3*).



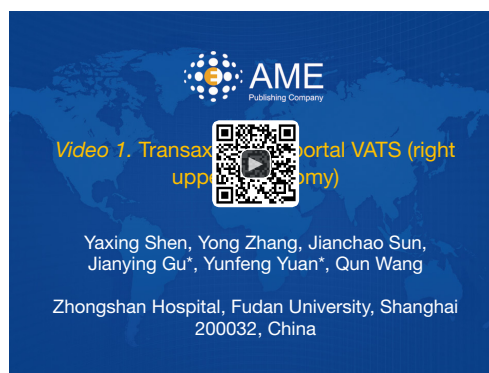**Figure 3** The incision of transaxillary uniportal VATS.

The drainage tube was removed 2 days post-operatively. The estimated volume of blood loss was 120 mL without blood transfusion. The surgical video of the procedure was recorded (*Figure 4*).

## Discussion

In this case report, transaxillary uniportal VATS was pioneered on surgical candidates for lobectomy. The right upper lobe lobectomy was achieved through a single 2.5 cm incision that was located at fossa axillaris. Post-operative recovery was uneventful and the patient was discharged 3 days after the surgery. The results suggested that transaxillary uniportal VATS is safe and feasible with potential cosmetic advantages.

Since 2011, growing number of uniportal lobectomies were performed throughout the world (2,3). Meanwhile, continuous modifications to the single-port procedure were made for the sake of improved clinical outcomes (4,5). Among the many efforts, different incision locations of uniportal VATS were most practiced: Liu and associates introduced subxiphoid uniportal VATS, to which the incision was switched from intercostal space to subxiphoid area (6). The procedure facilitated bilateral manipulation with fewer disturbances to the intercostal nerves, and



**Figure 4** Transaxillary uniportal VATS (right upper lobectomy) (1). Available online: <http://www.asvide.com/article/view/23856>

resulted in less pain post-operatively (7). On the other side, Dr. Marcin Zielinski from Poland practiced transcervical uniportal VATS lobectomy (8). The procedure was performed through a cervical incision, sacrificing internal mammary artery for the exposure of the surgical field. As different attempts bear different advantage or disadvantages, none has practiced uniportal VATS through fossa axillaris.

Transaxillary incision was most practiced by thoracic surgeons for first rib resection due to the thoracic outlet syndrome (TOS) (9). For uniportal VATS, the fourth or fifth intercostal space would be optimal for lobectomy. Technically, the subcutaneous tissue under the incision could be well mobilized to create a tunnel between the incision and the third intercostal space along the anterior axillary line. When the port was introduced to the incision, the surgical field was nearly identical to the one created to conventional uniportal lobectomy (10). The procedure went uneventfully according the order of pulmonary artery, right upper bronchus and superior pulmonary vein.

Recently, growing evidence showed that ground glass opacity (GGO) was increasing and female patients were more likely to suffer from GGOs than male patients (11). Another tendency for GGO lesion was that their age was relatively younger at the time GGO was found (12). The combination of the two factors encouraged the introduction of transaxillary uniportal VATS, as the incision was hidden in the axillary area, and the scar made was close both in shape and color in compared to the skin folding in the fossa axillaris. This procedure promises in the cosmetic issue without compromising in surgical or oncological effects.

The case report limited only in the upper lobectomy. In lower lobe resection, the procedure would be relatively difficult since the incision was through the fourth intercostal

space and the exposure of the target vessels was not as easy as the upper lobe. Further studies based on larger case volume would be required to validate its further application.

### Acknowledgements

*Funding:* This work was supported by the American Association for Thoracic Surgery's Evarts A. Graham Memorial Traveling Fellowship and the National Natural Science Foundation of China (Grant No. 81400681).

### Footnote

*Conflicts of Interest:* The authors have no conflicts of interest to declare.

*Informed Consent:* All participants sent their informed consents.

### References

1. Shen Y, Zhang Y, Sun J, et al. Transaxillary uniportal VATS (right upper lobectomy). *Asvide* 2018;5:381. Available online: <http://www.asvide.com/article/view/23856>
2. Gonzalez-Rivas D, Parabela M, Fernandez R, et al. Uniportal video-assisted thoracoscopic lobectomy: two years of experience. *Ann Thorac Surg* 2013;95:426-32.
3. Rocco G, Martucci N, La Manna C, et al. Ten-year experience on 644 patients undergoing single-port (uniportal) video-assisted thoracoscopic surgery. *Ann Thorac Surg* 2013;96:434-8.
4. Ng CS, Rocco G, Wong RH, et al. Uniportal and single-incision video-assisted thoracic surgery: the state of the art. *Interact Cardiovasc Thorac Surg* 2014;19:661-6.
5. Xie D, Wang H, Fei K, et al. Single-port video-assisted thoracic surgery in 1063 cases: a single-institution experience. *Eur J Cardiothorac Surg* 2016;49 Suppl 1:i31-6.
6. Liu CC, Wang BY, Shih CS, et al. Subxiphoid single-incision thoracoscopic left upper lobectomy. *J Thorac Cardiovasc Surg* 2014;148:3250-1.
7. Aresu G, Weaver H, Wu L, et al. Uniportal subxiphoid video-assisted thoracoscopic bilateral segmentectomy for synchronous bilateral lung adenocarcinomas. *J Vis Surg* 2016;2:170.
8. Zieliński M, Pankowski J, Hauer Ł, et al. The right upper lobe pulmonary resection performed through the transcervical approach. *Eur J Cardiothorac Surg* 2007;32:766-9.
9. Peek J, Vos CG, Ünlü Ç, et al. Outcome of Surgical Treatment for Thoracic Outlet Syndrome: Systematic Review and Meta-Analysis. *Ann Vasc Surg* 2017;40:303-26.
10. Shen Y, Wang H, Feng M, et al. Single- versus multiple-port thoracoscopic lobectomy for lung cancer: a propensity-matched study. *Eur J Cardiothorac Surg* 2016;49 Suppl 1:i48-53.
11. Zhang J, Chen SF, Zhen Y, et al. Multicenter analysis of lung cancer patients younger than 45 years in Shanghai. *Cancer* 2010;116:3656-62.
12. Corrales-Rodríguez L, Arrieta O, Mas L, et al. An international epidemiological analysis of young patients with non-small cell lung cancer (AduJov-CLICaP). *Lung Cancer* 2017;113:30-6.

**Cite this article as:** Shen Y, Zhang Y, Sun J, Gu J, Yuan Y, Wang Q. Transaxillary uniportal video assisted thoracoscopic surgery for right upper lobectomy. *J Thorac Dis* 2018;10(3):E214-E217. doi: 10.21037/jtd.2018.02.86