



Contents lists available at ScienceDirect

International Journal of Surgery Case Reports

journal homepage: www.casereports.com

Intraorbital hemorrhage following a secondary intervention at integrated zygomatic implants: A case report

Philippe Van Camp^{a,*}, Luc Vrielinck^a, Bert Gemels^b, Constantinus Politis^b

^a Department of OMFS St-John's Hospital, Genk, Belgium

^b Department of OMFS University Hospitals, Leuven, Belgium

ARTICLE INFO

Article history:

Received 1 December 2017

Received in revised form 5 January 2018

Accepted 16 January 2018

Available online 4 February 2018

Keywords:

Complication

Zygomatic implant

Intraorbital hemorrhage

ABSTRACT

INTRODUCTION: Zygomatic implant placement can be the best option for restoring masticatory function of an extremely atrophic upper jaw, but the procedure is more invasive than conventional implant placement and can be associated with complications.

PRESENTATION OF CASE: We report a complication that occurred during a secondary corrective surgical procedure four years after zygomatic implant placement. The patient was a 54-year-old female who had been edentulous for 25 years. Four zygomatic implants were placed. Subsequent prosthetic rehabilitation was successful. Four years later, the patient complained of discomfort. It was found that the tips of the implants on the right side were subcutaneously palpable and surrounded by granulomatous tissue. Intraoral surgery was performed to remove the protruding tips of the two implants. Post-operatively, the patient developed severe orbital pain on the right side with proptosis and diffuse swelling of the eyelids. Emergency surgery was performed to drain the intraorbital hemorrhage. The patient healed uneventfully without loss of visual acuity.

DISCUSSION: Scarce prior reports describe trauma to the orbit during zygomatic implant surgery, mostly involving orbital penetration during zygoma implant placement. To our knowledge, the present case report is the first to describe an intraorbital hemorrhage that led to an orbital compression syndrome necessitating emergency surgery.

CONCLUSION: In our case, corrective surgery in a patient with zygomatic implants resulted in an intraorbital hemorrhage, followed by an orbital compression syndrome. Emergency surgery was immediately performed, allowing hematoma drainage and eliminating compression of the intraorbital content. Symptoms quickly resolved and eyesight was not compromised.

© 2018 The Author(s). Published by Elsevier Ltd on behalf of IJS Publishing Group Ltd. This is an open access article under the CC BY-NC-ND license (<http://creativecommons.org/licenses/by-nc-nd/4.0/>).

1. Introduction

Zygomatic implants offer an additional treatment option for restoring masticatory function of an extremely atrophic upper jaw, and can potentially also improve facial appearance. The use of zygomatic implants may serve as a valid alternative to sinus augmentations or onlay bone grafts, followed by dental implant placement. Compared to the placement of conventional dental implants, the installation of zygomatic implants is a more invasive procedure, but it may be the best or only option in cases where bone reconstructive options are contra-indicated or unwanted by the patient [1,2].

Zygomatic implants have a high success rate, with reported cumulative survival rates of 96.3–100% [1–5]. The literature

includes reports of zygomatic implants being associated with several types of complications, including persistent infection of the maxillary sinus in up to 21.4% of procedures [2–5], buccosinus fistula, infection around the implants, chronic gingivitis, and infraorbital nerve damage [2,5,6,11]. Implant penetration into the nasal cavity or even intracerebral penetration have also been described [1,3,7].

Here we report a case in which intraorbital hemorrhage occurred following surgery to correct protruding tips of zygomatic implants, four years after initial implant placement. This case report is in line with the SCARE criteria [8].

2. Presentation of case

A 54-year-old Caucasian female presented at the Department of Oral and Maxillofacial Surgery at our institute. The patient was healthy, and did not smoke or consume large amounts of alcohol. She only suffered from hypothyroidism, treated with levothyroxine 125 µg once daily.

* Corresponding author at: Nieuwelaan 52, 2520 Oelegem, Belgium.

E-mail addresses: philippe.vancamp@zol.be (P. Van Camp), luc.vrielinck@zol.be (L. Vrielinck), bert.gemels@uzleuven.be (B. Gemels), constantinus.politis@uzleuven.be (C. Politis).

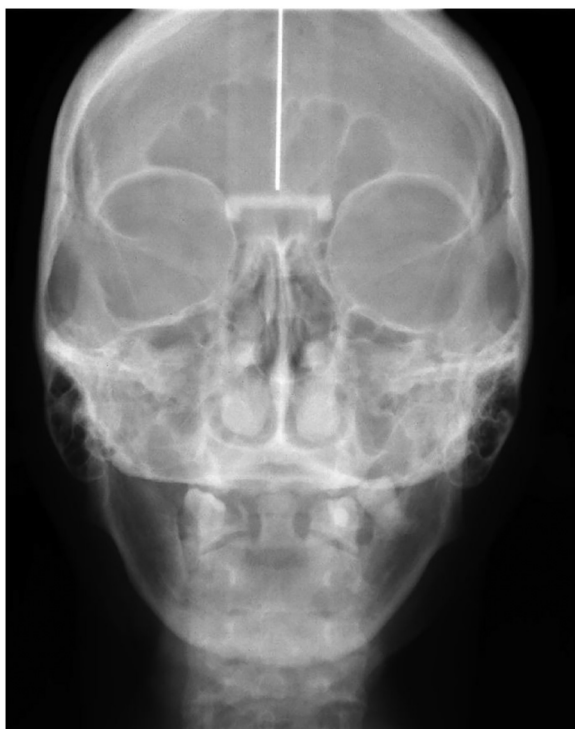

Fig. 1. PA radiograph pre-treatment. Note that there are no abnormalities of the orbits.

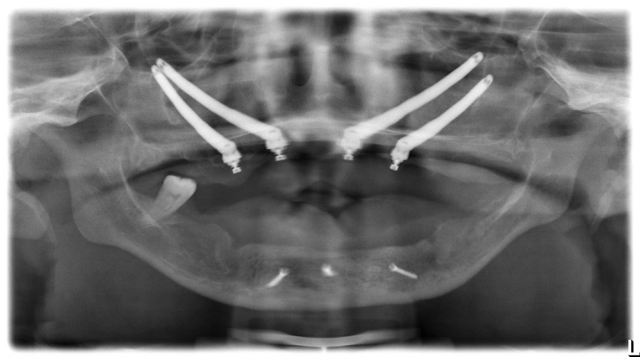


Fig. 2. Panoramic radiograph showing the placement of four zygomatic implants and onlay graft.

The patient had been edentulous in the upper jaw for more than 25 years. Several removable prostheses had been fabricated for her over this time, but there was a lack of retention due to severe atrophy of the jaw. PA radiograph showed no other abnormalities (Fig. 1). It was decided to place four zygomatic implants to improve stability and function, while simultaneously removing teeth in the lower jaw due to advanced periodontitis, and performing a bone graft procedure in the mandible using corticospongy bone graft from the anterior iliac crest (Fig. 2).

Surgery was uneventful. Four zygomatic fixtures were placed into the zygomatic bone, and the patient was discharged from the hospital the following day. Healing went well, and prosthetic rehabilitation of the upper jaw was conducted using a removable overdenture. A temporary removable prosthesis was made for the lower jaw. Treatment resulted in improved masticatory function and esthetics.

Four years later, the patient returned to our department complaining of a protrusion in the region of the zygomatic bone on the right side. This protrusion caused chronic irritation and pain

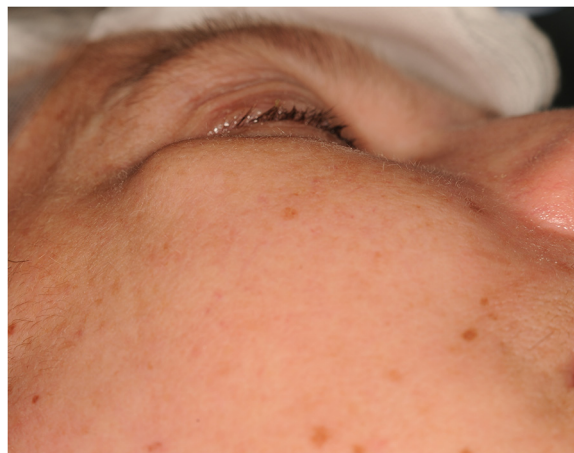


Fig. 3. Clinical photograph showing the protrusion at the zygoma on the right side.

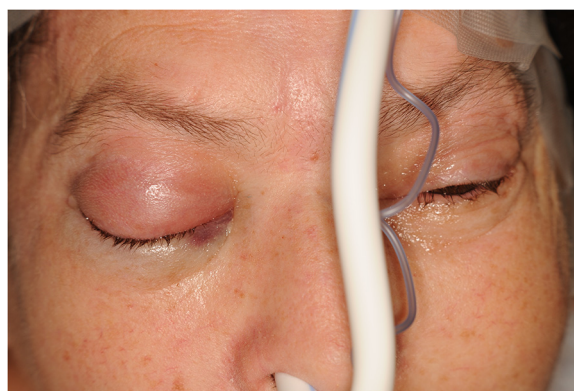

Fig. 4. Extensive swelling of the eyelid and proptosis, frontal view.

in the overlying skin. Examination revealed that these symptoms were caused by protruding tips of the apical part of the two zygomatic implants on the right side, which were surrounded by chronic granulomatous tissue (Fig. 3).

It was decided to perform exploratory surgery of the area, and to shorten these zygomatic implants under general anesthesia on an outpatient basis. Although the top of the zygoma is a difficult region to visualize from an intra-oral approach, surgery went as expected. We observed that at this time (four years after implantation), the implants protruded 3–5 mm past the outer border of the zygoma. Most likely, a low-grade infection at the tips caused resorption of the zygomatic bone. A 3-mm-diameter round drill was used to mechanically remove the overhang of both implants until no more irregularities were observed. The operating field was copiously rinsed, and then the wound was closed using resorbable sutures. The patient recovered uneventfully from the anesthesia, and was transported to the recovery room.

About half an hour later, the patient developed severe pain at the right eye, along with diffuse swelling of the upper and lower eyelid (Fig. 4). The severity of swelling precluded clinical inspection of the eye or extensive evaluation of eyesight. A proptosis of the eyeball was observed, and the patient was still able to differentiate between light and dark. The most likely clinical explanation was a bleed in the orbit, although the precise cause was unknown. No ophthalmologist was readily available for an emergency consult. The patient was prepped for emergency surgery to decompress the orbital content. No CT scan was performed at that time.

The patient was put under general anesthesia. A lower eyelid incision was made to gain entry to the right orbit. The lower orbital rim was identified, and the orbital floor was explored. During this

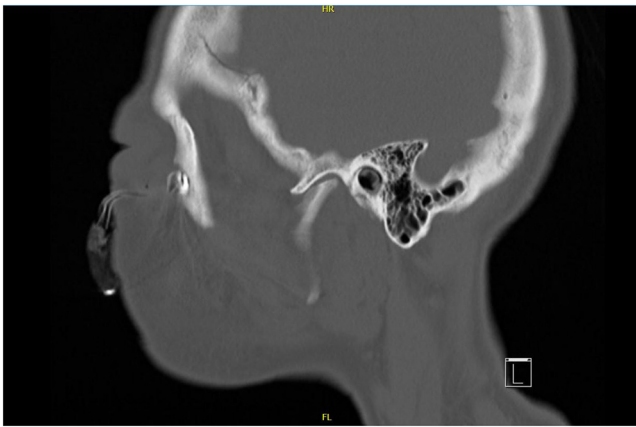

Fig. 5. CT image from one day after surgery showing the very close proximity of the zygomatic implant tip to the lateral orbit, sagittal view.

procedure, active drainage of blood from within the orbit was observed. When spontaneous draining was completed, two Penrose drains were inserted and left in place: one on the orbital floor and one on the lateral side of the zygoma. Methylprednisolone 40 mg (four times a day) was administered, and acetazolamide 500 mg was added after an ophthalmological consult several hours later.

Subsequently, the patient was admitted to the ward and her eyesight was closely monitored. The next day, the swelling had diminished and the patient could spontaneously open her eyes and see colors. She complained of blurry vision and mild diplopia. A CT scan was performed. Image examination by protocol revealed no obvious bony defects. However, close examination of the CT images revealed a small bony defect, precisely in the region where the implants tips were removed (Fig. 5).

Two days post-operatively, the patient showed no sign of bleeding. The Penrose drains were removed, and the patient was discharged from the hospital. At follow-up consultation, the patient had no complaints of diminished eyesight, and skin healing was uneventful.

3. Discussion

Here we report the case of a very unusual complication following corrective surgery to already integrated zygomatic implants. Four years following routine zygomatic implant placement, the patient complained of discomfort. Examination revealed that the zygomatic bone on the right side had developed resorption around the implant tips, leading to subcutaneous protrusion. Corrective surgery to shorten the implants caused minimal trauma to the orbit, which led to an intraorbital hemorrhage and subsequent development of acute orbital compartment syndrome. Shortly after the procedure, the patient reported excruciating pain, and exhibited extensive swelling and protrusion of the eyeball. Emergency surgery was immediately performed. Entry to the orbit was gained through an infra-orbital incision, allowing hematoma drainage and eliminating the compression of the intraorbital content. Symptoms quickly resolved and eyesight was not compromised.

Although scarce, the literature includes some reports of trauma to the orbit during zygomatic implant surgery, mostly involving orbital penetration during zygoma implant placement [4,9]. To our knowledge, the present case report is the first to describe an intraorbital hemorrhage that led to an orbital compression syndrome necessitating emergency surgery.

Upon discovery of the complication, the course of action taken was in accordance with that described by Brucoli et al. [10]. Notably, no radiographic evaluation was made between diagnosis of the

complication and the performance of emergency surgery. This was due to the clear link between the original surgery and the complication. CT imaging would have delayed emergency surgery, and would not have changed the steps taken to resolve the issue.

In this particular case, the surgeon chose to use an infra-orbital approach rather than a lateral canthotomy. This was because he wanted to explore the entire anterior region of the orbital floor and lateral orbit since the exact source of the bleed was unknown.

4. Conclusion

To our knowledge, this is the first report to describe an intra-orbital hemorrhage leading to an orbital compression syndrome, hours after corrective zygomatic implant surgery. Emergency surgery was performed to relieve intraorbital pressure, leading to full recovery of the patient's eyesight.

Conflicts of interest

None.

Funding

None.

Ethical approval

This case report was exempt from ethical approval. The study was written with consent of the patient involved. Patient data were anonymised to protect the privacy of the patient.

Consent

Written informed consent was obtained.

Author contribution

Van Camp Philippe: data collection, preparation of paper, review of manuscript.

Vrielinck Luc: review of manuscript.

Gemels Bert: data collection, preparation of paper, review of manuscript.

Politis Constantinus: review of manuscript.

Registration of research studies

Not applicable, case report.

Guarantor

Van Camp Philippe.

Vrielinck Luc.

Acknowledgement

None.

References

- [1] B. Chrcanovic, M. Abreu, Survival and complications of zygomatic implants: a systematic review, *Oral Maxillofac. Surg.* 17 (2013) 81–93.
- [2] E. Candel-Marti, C. Carrillo-Garcia, D. Penarrocha-Oltra, M. Penarrocha-Diago, Rehabilitation of atrophic posterior maxilla with zygomatic implants: review, *J. Oral Implantol.* 5 (2012) 653–657.
- [3] R. Araujo, A. Sverzut, A. Tivellato, C. Sverzut, Retrospective analysis of 129 consecutive zygomatic implants used to rehabilitate severely resorbed

- maxillae in a two-stage protocol, *Int. J. Oral Maxillofac. Implants* 32 (2017) 377–384.
- [4] R. Davo, O. Pons, J. Rojas, E. Carpio, Immediate function of four zygomatic implants: a 1-year report of a prospective study, *Eur. J. Oral Implantol.* 3 (2010) 323–334.
- [5] K.E. Kahnberg, P. Henry, J.M. Hirsch, L.O. Öhrnell, L. Andreasson, P.I. Branemark, et al., Clinical evaluation of the zygoma implant: 3-year follow-up at 16 clinics, *J. Oral Maxillofac. Surg.* 65 (2007) 2033–2038.
- [6] H. Fernandez, A. Gomez-Delgado, S. Trujillo-Saldarriaga, D. Varon-Cardona, J. Castro-Nunez, Zygomatic implants for the management of the severely atrophied maxilla: a retrospective analysis of 244 implants, *J. Oral Maxillofac. Surg.* 72 (2014) 887–891.
- [7] H. Reyhler, R. Olszewski, Intracerebral penetration of a zygomatic dental implant and consequent therapeutic dilemmas: case report, *Int. J. Oral Maxillofac. Implants* 25 (2010) 416–418.
- [8] R. Agha, A. Fowler, A. Saetta, I. Barai, S. Rajmohan, D. Orgill, The SCARE statement: consensus-based surgical case report guidelines, *Int. J. Surg.* 34 (2016) 180–186.
- [9] L. Duarte, H. Filho, C. Francischone, L. Peredo, P.I. Branemark, The establishment of a protocol for the total rehabilitation of atrophic maxillae employing four zygomatic fixtures in an immediate loading system – a 30-month clinical and radiographical follow-up, *Clin. Implant Dent. Relat. Res.* 9 (2007) 186–196.
- [10] M. Brucoli, F. Arcur, M. Giarda, R. Benech, A. Benech, Surgical management of posttraumatic intraorbital hematoma, *J. Craniofac. Surg.* 23 (2012) e58–e61.
- [11] J. Rodriguez-Chessa, H. Netto, J. Shibli, M. de Moraes, R. Mazzonetto, Treatment of atrophic maxilla with zygomatic implants in 29 consecutive patients, *Int. J. Clin. Exp. Med.* 7 (2014) 426–430.

Open Access

This article is published Open Access at [sciencedirect.com](https://www.sciencedirect.com). It is distributed under the [IJSCR Supplemental terms and conditions](#), which permits unrestricted non commercial use, distribution, and reproduction in any medium, provided the original authors and source are credited.