

# Anti-inflammatory Effects of *Brassica oleracea* Var. capitata L. (Cabbage) Methanol Extract in Mice with Contact Dermatitis

Youjung Lee<sup>†</sup>, Seoyoung Kim<sup>†</sup>, Beodeul Yang, Chiyeon Lim<sup>1</sup>, Jung-Hoon Kim, Hyungwoo Kim, Suin Cho

Division of Pharmacology, School of Korean Medicine, Pusan National University, Yangsan, <sup>1</sup>Department of Medicine, College of Medicine, Dongguk University, Seoul, South Korea

<sup>†</sup>Both authors contributed equally to this work.

Submitted: 20-04-2017

Revised: 17-05-2017

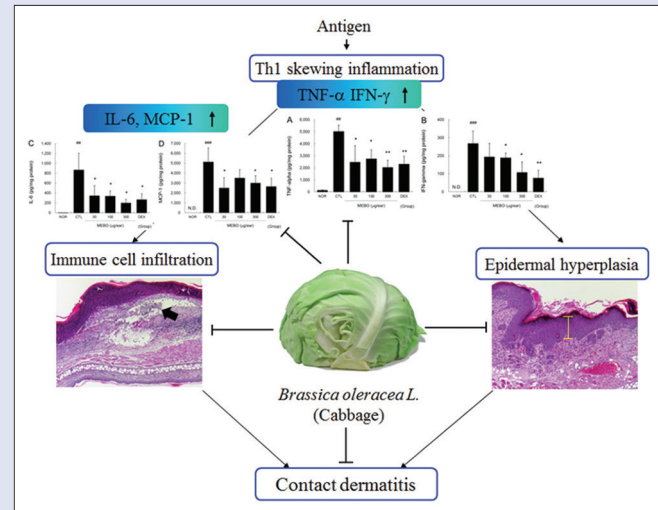
Published: 10-04-2018

## ABSTRACT

**Background:** Cabbage, *Brassica oleracea* var. capitata L., is one of the most common vegetables in the world. Because of its high levels of flavonoids and anthocyanins, cabbage has long been used as a herbal medicine. The antioxidant and anti-inflammatory properties of cabbage were also recently been reported. **Objective:** This study was designed to investigate the anti-inflammatory effects of cabbage in mice with contact dermatitis (CD). **Materials and Methods:** We investigated the effects of methanol extract of *B. oleracea* var. capitata L. (MEBO) on ear swelling, erythema, and histopathological changes in CD mice. Moreover, the effects on cytokine production and the spleen/body weight ratio were investigated. **Results:** Topical treatment with MEBO inhibited ear swelling and erythema significantly. MEBO also significantly inhibited epidermal hyperplasia and infiltration of immune cells. Furthermore, the levels of tumor necrosis factor- $\alpha$ , interferon- $\gamma$ , interleukin-6, and monocyte chemoattractant protein-1 in inflamed tissues were effectively lowered by MEBO. Finally, MEBO did not affect body weight gain or spleen body weight ratio. **Conclusions:** These results indicate that cabbage can be used for the treatment of skin inflammation and that its anti-inflammatory activity is closely related to the inhibition of Th1 skewing reactions. **Key words:** *Brassica oleracea*, cabbage, contact dermatitis, herbal medicine, inflammation

## SUMMARY

- MEBO inhibited ear thickness, weight, and erythema in inflamed skin
- MEBO also prevented epidermal hyperplasia and infiltration of immune cells
- The levels of tumor necrosis factor- $\alpha$ , interferon- $\gamma$ , interleukin-6, and monocyte chemoattractant protein-1 in inflamed tissues were lowered by MEBO.



**Abbreviations used:** AOO: Acetone and olive oil (4:1), CBA: Cytometric bead array, CD: Contact dermatitis, DEX: Dexamethasone, DNFB: 1-fluoro-2,4-dinitrofluorobenzene, GM-CSF: Granulocyte-macrophage colony-stimulating factor, ICAM-1: Intercellular Adhesion Molecule-1, LPS: Lipopolysaccharide, MEBO: Methanol extract of *Brassica oleracea*, MCP-1: Monocyte chemoattractant protein-1, NO: Nitric oxide.

## Correspondence:

Prof. Hyungwoo Kim,  
School of Korean Medicine,  
Pusan National University, Yangsan,  
Gyeongnam 50612, South Korea.  
E-mail: kronos7@pusan.ac.kr  
DOI: 10.4103/pm.pm\_152\_17

Access this article online

Website: www.phcog.com

Quick Response Code:



## INTRODUCTION

Cabbage (*Brassica oleracea* var. capitata L.), which belongs to the family Brassicaceae, is one of the most common vegetables grown worldwide. Cabbage is often referred to as green cabbage to distinguish it from red cabbage, which has the same scientific name. Due to its antioxidant and anti-inflammatory properties,<sup>[1,2]</sup> cabbage has been widely used as an herbal medicine to treat gastrointestinal disorders such as gastritis, peptic and duodenal ulcers, and irritable bowel syndrome, as well as wounds and mastitis.<sup>[1,3,4]</sup>

Many people have believed cabbage can ameliorate various skin ailments such as xeroderma, skin troubles, and acne. In the theory of traditional medicine, malfunction of gastrointestinal tract is closely related in skin problems.<sup>[5]</sup> In addition, cabbage is recognized as good supplement for

both gastrointestinal disorders and skin problems in Korea. For this reason, Korean people have used cabbage to improve skin ailments through amelioration of gastrointestinal malfunctions. Furthermore, grated cabbage is used as ingredient of face mask and its usages are easily found on websites.<sup>[6]</sup>

This is an open access journal, and articles are distributed under the terms of the Creative Commons Attribution-NonCommercial-ShareAlike 4.0 License, which allows others to remix, tweak, and build upon the work non-commercially, as long as appropriate credit is given and the new creations are licensed under the identical terms.

For reprints contact: reprints@medknow.com

**Cite this article as:** Lee Y, Kim S, Yang B, Lim C, Kim JH, Kim H, et al. Anti-inflammatory effects of *Brassica oleracea* Var. capitata L. (Cabbage) methanol extract in mice with contact dermatitis. Phcog Mag 2018;14:174-9.

Occupational contact dermatitis (CD) is characterized by dry and flaking skin, as well as by pruritus, macular erythema, hyperkeratosis, and vesiculation. Although this condition is not life-threatening, it leads to severe impairment of workplace efficiency and the quality of life of workers. In addition, it has a very high-financial burden. For example, almost 13 million workers in the United States have the potential to CD each year, resulting in costs exceeding US\$ 1 billion annually.<sup>[7]</sup>

CD is an inflammatory response to dermal exposure to a harmful agent, which is known as a sensitizer. This condition tends to be chronic, repetitive, and consistent because workers have no choice but to be exposed to the sensitizer. For this reason, patients with occupational CD tend to use corticosteroids frequently and continuously, even if they have had adverse reactions to such treatments.<sup>[8]</sup>

We have recently been investigating the anti-inflammatory effects of plant materials, which have relatively low toxicity, to identify candidates for complementary or alternative medicine to corticosteroids. As part of these efforts, we investigated the anti-inflammatory effects of *B. oleracea* var. capitata L., in mice with CD induced by 1-fluoro-2,4-dinitrofluorobenzene (DNFB).

## MATERIALS AND METHODS

### Preparation of samples

Cabbage, *B. oleracea* var. capitata L., cultivated in Jeju Island, Korea, in 2014, was purchased from a public market (Top Mart, Yansan, Korea). The extracting processes were conducted according to our standard procedure.<sup>[9]</sup> A total of 50 g minced cabbage was immersed in 500 ml methanol, then sonicated for 15 min, after which the sample was extracted for 24 h. Next, the supernatant was transferred and the sample was extracted in 500 ml of methanol for an additional 24 h. The extract was subsequently filtered through Whatman filter paper No. 20 and evaporated under reduced pressure using a vacuum evaporator (Eyela, Tokyo, Japan). The condensed extract was then lyophilized using a freeze dryer (Labconco, Kansas City, MO, USA). Finally, 4.1 g of lyophilized powder (methanol extract of *B. oleracea* var. capitata L., [MEBO]) was obtained (yield, 8.2%). An aliquot of the extract was deposited at the Division of Pharmacology, School of Korean Medicine, Pusan National University (MEBO, Voucher No. MH 2014-033).

### Animals

Male 6-week-old Balb/c mice were purchased from Samtaco (Incheon, Korea). Mice were housed under specific pathogen-free conditions with a 12 h light/dark cycle and free access to standard rodent food and water. All animal experiments were approved by our Animal Care and Use Committee and conducted according to institutional guidelines (PNU-2012-0140).

### Induction of contact dermatitis and experimental design

Experimental CD was induced using DNFB and all procedures were described in our previous reports.<sup>[9]</sup> Mice were sensitized by painting 50  $\mu$ L of DNFB (0.2%, v/v) in acetone: olive oil (AOO, 4:1) onto the shaved back of each animal for 3 consecutive days. Four days after sensitization, each mouse was challenged by painting 20  $\mu$ L of DNFB (0.2%, v/v) in AOO onto the dorsum of both ears every 2 days (4 times). MEBO solution (30, 100, or 300  $\mu$ g/ear) was then applied onto the dorsum of both ears for 6 consecutive days. Naïve animals were treated with vehicle (AOO) and then painted with vehicle ( $n = 4$ ). Control animals (CTL) were sensitized and challenged with DNFB, after which they were painted with vehicle ( $n = 8$ ). MEBO-treated animals were sensitized and challenged

with DNFB, then painted with 30  $\mu$ g/ear (0.1%, w/v), 100  $\mu$ g/ear (0.33%, w/v), and 300  $\mu$ g/ear (1%, w/v) of MEBO ( $n = 8$ ). DEX-treated animals were sensitized and challenged with DNFB, then painted with 75  $\mu$ g/ear dexamethasone (DEX) as a positive control ( $n = 6$ ). The experimental schedule is summarized in Figure 1.

### Measurement of ear thicknesses and weights

Mice were sacrificed with CO<sub>2</sub>, after which the thicknesses of both ears were measured using vernier calipers (Mitutoyo, Kanagawa, Japan). The weights of earpieces obtained through dermal punch (5 mm in diameter) were also determined using a microbalance (Sartorius AG, Göttingen, Germany).

### Evaluation of erythema index

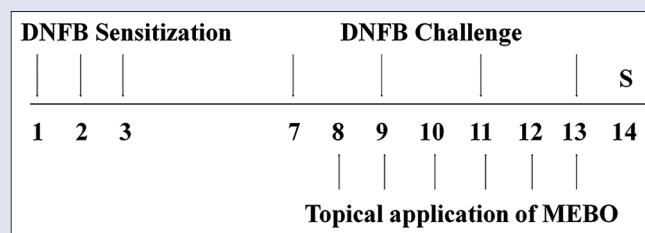
At the end of the experiment, resected ears were photographed using a digital camera (Olympus, Tokyo, Japan). To measure the effects on erythema, the levels of flushing and vasodilatation in the ear skin were evaluated using arbitrary units as follows: Grade 0, no flushing and normal range of blood vessels in the center; Grade 1, no flushing and slight vasodilatation in the center; Grade 2, slight flushing and vasodilatation in the center; Grade 3, flushing and vasodilatation in the edge and in the center; and Grade 4, severe flushing, petechia, and vasodilatation in the edge and in the center. Erythema index values are presented as the mean  $\pm$  standard deviation (SD).

### Histopathological examination

Following measurement of ear thicknesses and weights, ear tissues were resected and embedded in paraffin. Sections were then stained with hematoxylin and eosin for histopathological changes such as epidermal hyperplasia, hyperkeratosis, and immune cell infiltration. Stained tissues were observed at  $\times 50$  and  $\times 100$  using a light microscope.

### Evaluation of epidermal hyperplasia and immune cell infiltration

For evaluation of epidermal hyperplasia and immune cell infiltration, five nonoverlapping fields per slide were randomly selected and images were captured with a light microscope. To measure the thickness of the epithelium, the vertical length between the basal lamina and the top of the outermost stratum granulosum was quantified. For each slide, five lengths were measured at random, after which the average values of epithelial thickness in all experimental groups were used for analysis. To evaluate immune cell infiltration, infiltrated immune cells were counted using a cell counting grid.



**Figure 1:** Experimental schedule – the experimental groups, except for the naïve group, were sensitized by painting with 1-fluoro-2,4-dinitrofluorobenzene on days 1, 2, and 3. Mice were challenged by 1-fluoro-2,4-dinitrofluorobenzene on days 7, 9, 11, and 13. The naïve group was treated with vehicle (acetone: olive oil) in the same way. Methanol extract of *Brassica oleracea* var. capitata L. and DEX groups were topically treated with methanol extract of *Brassica oleracea* var. capitata L. (30, 100, or 300  $\mu$ g/ear in ethanol and acetone: olive oil) or DEX (75  $\mu$ g/ear in ethanol and acetone: olive oil) for 6 days from day 8–13. All animals were sacrificed on day 14

## Measurement of cytokine production

Cytokine levels in ear tissues were measured using the cytometric bead array (CBA) method. Briefly, resected ear tissues were lysed and homogenized with protein extraction solution (Intron Bio, Daejeon, Korea) using a bullet blender (Next Advance, New York, NY, USA) to obtain tissue lysates. Next, 50  $\mu\text{g}$  of each lysate was used to measure the levels of tumor necrosis factor- $\alpha$  (TNF- $\alpha$ ), interferon- $\gamma$  (IFN- $\gamma$ ), interleukin-6 (IL-6), and monocyte chemoattractant protein-1 (MCP-1). Cytokine levels were measured using a CBA kit (BD Bioscience, CA, USA). All experimental procedures were conducted according to the manufacturer's guidelines.

## Statistical analysis

Mann-Whitney test was used for all statistical comparisons, and Prism 5 for Windows Version 5.01 (GraphPad Software, CA, USA) was used for all analyses. All data are presented as the mean  $\pm$  SD. The  $P < 0.05$  was considered statistically significant.

## RESULTS

### Methanol extract of *Brassica oleracea* var. capitata L. effectively inhibited ear swelling in inflamed tissues.

Repeated painting of DNFB enlarged ear thickness and weight significantly compared to nontreated normal mice. Treatment with more than 100  $\mu\text{g}/\text{ear}$  of MEBO effectively prevented enlargement of ear thickness. In addition, MEBO lowered ear weights significantly [Figure 2].

### Methanol extract of *Brassica oleracea* var. capitata L. effectively lowered the erythema index in the skin

Severe flushing and vasodilatation were observed in the edge and center of the ear in the CTL group. However, treatment with more than 100  $\mu\text{g}/\text{ear}$  of MEBO effectively prevented the flushing and vasodilatation induced by DNFB in a dose-dependent manner [Figure 3].

### Methanol extract of *Brassica oleracea* var. capitata L. effectively inhibited epidermal hyperplasia, hyperkeratosis, and immune cell infiltration in inflamed tissues

Multiple applications of DNFB induced epidermal hyperplasia (yellow bars) and hyperkeratosis, as well as immune cell infiltration [Figure 4a].

Topical application of MEBO inhibited epidermal hyperplasia, hyperkeratosis, and immune cell infiltration [Figure 4]. As shown in Figure 4b, 300  $\mu\text{g}/\text{ear}$  of MEBO significantly prevented epithelial hyperplasia. In addition, MEBO prevented immune cell infiltration induced by DNFB in a dose-dependent manner [Figure 4b].

### Methanol extract of *Brassica oleracea* var. capitata L. reduced the levels of tumor necrosis factor- $\alpha$ , interferon- $\gamma$ , interleukin-6, and monocyte chemoattractant protein-1 in inflamed tissues of contact dermatitis mice

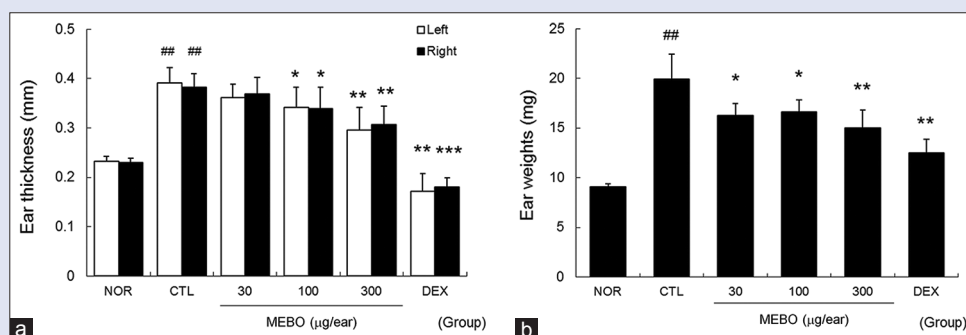
Marked increases in TNF- $\alpha$ , IFN- $\gamma$ , IL-6, and MCP-1 production were observed in the CTL group. MEBO effectively inhibited the TNF- $\alpha$ , IFN- $\gamma$ , IL-6, and MCP-1 production induced by repeated application of DNFB [Figure 5].

### Methanol extract of *Brassica oleracea* var. capitata L. did not affect spleen body weight ratio of contact dermatitis mice

Slight inhibition of body weight gain was observed in the CTL group, while MEBO had no effect on body weight gain. Conversely, topical application of dexamethasone inhibited body weight gain significantly [Figure 6a]. In addition, multiple applications of DNFB elevated the spleen body weight ratio compared to nontreated normal mice, while MEBO had no effect on spleen body weight ratio in CD mice. On the other hand, dexamethasone significantly reduced the spleen body weight ratio compared to nontreated normal and control mice [Figure 6b].

## DISCUSSION

CD induced by superantigens such as 2,4-Dinitrochlorobenzene (DNFB) and DNFB is characterized by severe skin lesions such as marked scaling, crust, and erythematous eruptions in the skin surface, Th1 skewing reactions such as elevated levels of TNF- $\alpha$  and IFN- $\gamma$ , and immune cell infiltration into the inflamed tissues.<sup>[10]</sup> In addition, it is well known that topical application of DNFB can enlarge skin thickness and weight in experimental animals.<sup>[9]</sup> In our model, repeated application of DNFB induced ear swelling and erythema in ear skin, as well as epithelial hyperplasia, hyperkeratosis and immune cell infiltration in ear tissues. Marked increases in inflammatory cytokines such as TNF- $\alpha$ , IFN- $\gamma$ , IL-6, and chemokine (MCP-1) were



**Figure 2:** Effects of methanol extract of *Brassica oleracea* var. capitata L. on ear swelling in inflamed tissues. The ear thickness and weight were measured on day 14. NOR, nontreated normal mice; CTL, nontreated contact dermatitis mice; 30, 100 or 300, 30, 100, or 300  $\mu\text{g}/\text{ear}$  of methanol extract of *Brassica oleracea* var. capitata L.-treated contact dermatitis mice; DEX, 75  $\mu\text{g}/\text{ear}$  of dexamethasone-treated contact dermatitis mice. (a) Ear thickness; (b) ear weight. All values are presented as the mean  $\pm$  standard deviation.  $^{**}P < 0.01$  and  $^{###}P < 0.001$  vs. nontreated normal mice (NOR),  $^{*}P < 0.05$ ,  $^{**}P < 0.01$  and  $^{***}P < 0.001$  versus nontreated contact dermatitis mice (CTL)



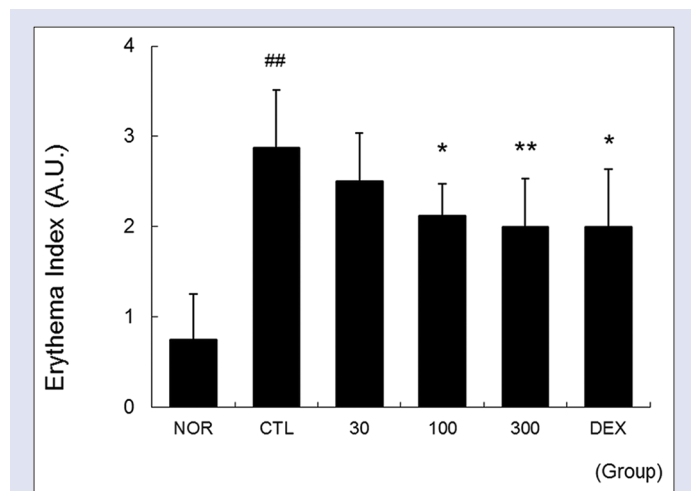
also observed. These results were in accordance with those of previous studies conducted using an animal model of CD and indicate that our model mimics human CD well.

Cabbage has high levels of flavonoids<sup>[11]</sup> and anthocyanins,<sup>[12]</sup> which possess antioxidant properties and can increase the levels of antioxidant

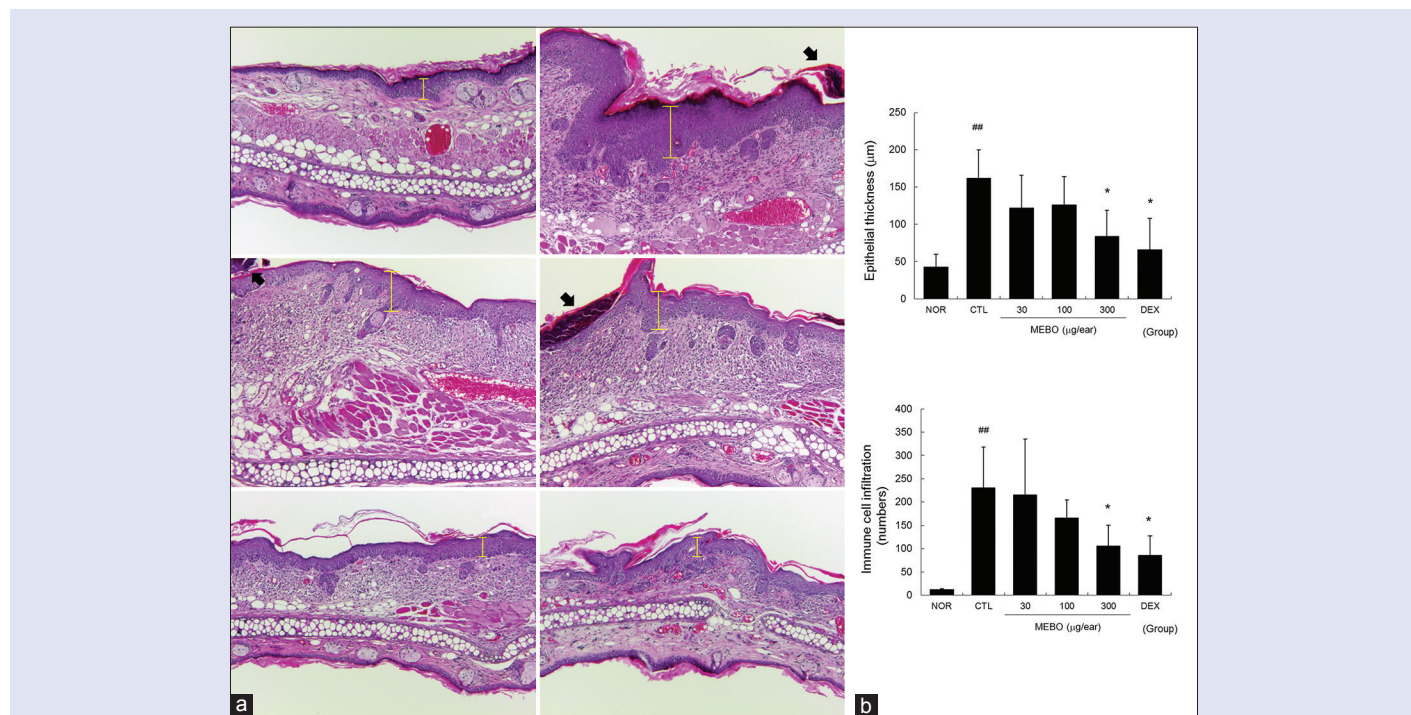
enzymes, leading to protection of the free-radical action and high nutritional value.<sup>[13]</sup> The antioxidant and anti-inflammatory mechanisms of cabbage are reportedly linked to stimulation of the Nrf2 pathway.<sup>[14,15]</sup> In addition, Sarandy *et al.* recently reported that cabbage ointment matured the extracellular matrix in skin wounds of Wistar rats.<sup>[14]</sup> Taken together, these findings suggest that cabbage can ameliorate skin lesions and pathophysiological changes in CD.

Th 1 skewing inflammatory reactions such as elevated production levels of TNF- $\alpha$  and IFN- $\gamma$  and immune cell infiltration play an important role in the pathophysiology of CD and are considered hallmarks and therapeutic targets of CD. In this study, treatment with MEBO effectively reduced the production levels of TNF- $\alpha$  and IFN- $\gamma$  in ear tissues [Figure 5], indicating that MEBO is an anti-inflammatory agent against the Th 1 skewing reaction of T cells.

IL-1 $\beta$ , TNF- $\alpha$ , and granulocyte-macrophage colony-stimulating factor (GM-CSF) contribute to the activation and migration of epidermal Langerhans cells during induction of CD, and strongly upregulate chemokines, resulting in recruitment of leukocytes.<sup>[16]</sup> In addition, IFN- $\gamma$  accelerates the release of mediators such as chemokine (C-X-C motif) receptor (CXCR) 3 agonist and MCP-1.<sup>[17]</sup> TNF- $\alpha$  released by activated immune cells and keratinocytes can induce surface expression of intercellular adhesion molecule-1 and various chemokines such as IL-8, MCP-1, and chemokine (C-C motif) ligand 27 (CCL27) in both an autocrine and paracrine manner.<sup>[18]</sup> MCP-1, which is also known as chemokine (C-C motif) ligand 2 (CCL2), can recruit T cells, monocytes, and dendritic cells to inflammatory sites.<sup>[19,20]</sup> In our study, MEBO effectively lowered production levels of two representative Th1 cytokines, TNF- $\alpha$  and IFN- $\gamma$ , and the chemokine, MCP-1 [Figure 5a and d]. In addition, MEBO prevented immune cell infiltration induced by DNFB in



**Figure 3:** Effects of methanol extract of *Brassica oleracea* var. capitata L. on erythema index of the skin. Ear skins were observed using a digital camera on day 14. The effects of methanol extract of *Brassica oleracea* var. capitata L. on the erythema index were evaluated using arbitrary units as shown in the materials and methods. Abbreviations are the same as in Figure 2; A.U., arbitrary unit. All values are presented as the mean  $\pm$  standard deviation. ## $P$  < 0.01 versus nontreated NOR mice, \* $P$  < 0.05 and \*\* $P$  < 0.01 versus nontreated contact dermatitis mice



**Figure 4:** Effects of methanol extract of *Brassica oleracea* var. capitata L. on histopathological changes in contact dermatitis mice. Ear tissues were stained with hematoxylin and eosin and observed using a light microscope. Abbreviations are the same as in Upper left, NOR; upper right, CTL; middle left, 30  $\mu$ g/ear of MEBO-treated; middle right, 100  $\mu$ g/ear of MEBO-treated; bottom left, 300  $\mu$ g/ear of MEBO-treated; bottom right, DEX (X50). Yellow bars indicate epidermal thicknesses, filled arrows mean hyperkeratotic areas (a). The epithelial thickness and immune cell infiltration were evaluated in a quantitative manner. Abbreviations are the same as in Figure 2. All values are presented as the mean  $\pm$  standard deviation. ## $P$  < 0.01 versus nontreated NOR mice, \* $P$  < 0.05 versus nontreated contact dermatitis mice (b)

inflamed tissue [Figure 4b and c]. These results imply that MEBO can prevent immune cell infiltration through inhibition of MCP-1 production and that inhibition of MCP-1 by MEBO may be closely related to regulation of Th1 skewing cytokine production.

Keratinocytes play a pivotal role in the initiation and progression of CD as an effector cell with other immune cells. During initiation of CD, sensitizers, especially haptens, induce activation of keratinocytes, resulting in the release of inflammatory mediators such as TNF- $\alpha$ , IL-1, IL-6, and GM-CSF.<sup>[21]</sup> Among them, IL-6, which is mainly secreted from skin tissues after injury, can accelerate the proliferation and migration of keratinocytes.<sup>[22]</sup> Moreover, inflammatory cytokines such as TNF- $\alpha$  and IFN- $\gamma$  can activate keratinocytes in both an autocrine and paracrine manner, leading to epidermal hyperplasia in the case of inflammatory skin diseases such as psoriasis and eczema.<sup>[23]</sup> In our experiment, MEBO significantly lowered production levels of TNF- $\alpha$ , IFN- $\gamma$ , and IL-6 [Figure 5] and prevented hyperplasia in the epidermis [Figure 4a and b]. These results will help elucidate the action mechanism by which MEBO inhibits enlargement of ear thickness and weight [Figure 2].

Both erythema and swelling are major hallmarks of inflammation that are closely related to vasodilatation.<sup>[24]</sup> In the present study, MEBO effectively lowered the erythema index [Figure 3] and prevented ear swelling [Figure 2]. These results imply that the anti-inflammatory effects of MEBO in the skin tissues of CD and the mechanisms that lead to these effects are closely related to inhibition against vasodilatation through regulation of Th1 skewing immune responses.

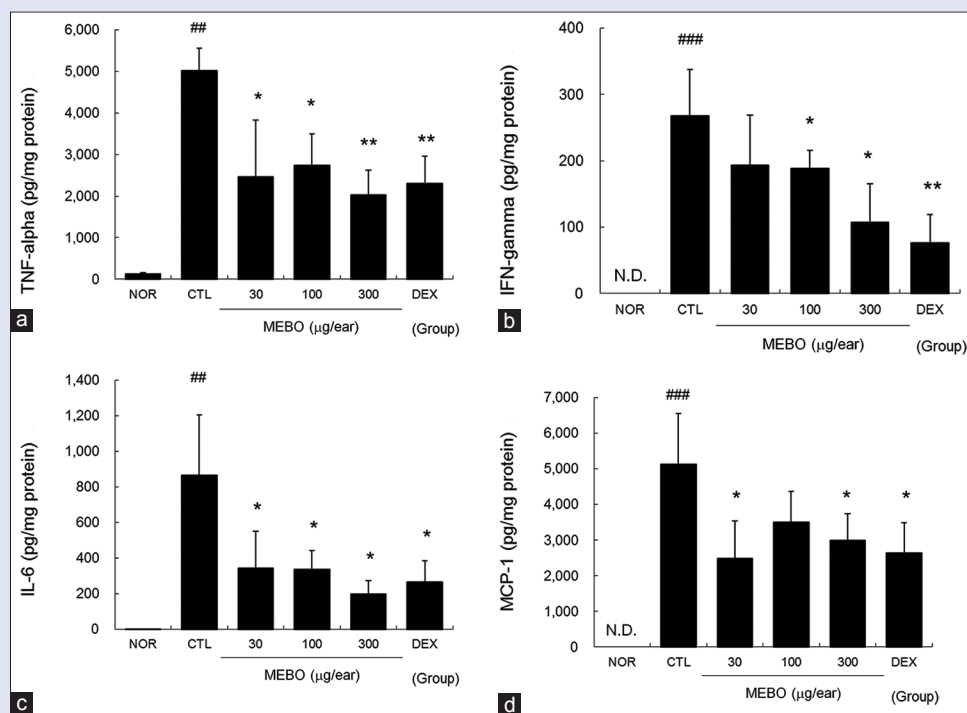
Rokayya *et al.* reported that cabbage can effectively scavenge free radicals and slightly inhibit nitric oxide (NO) production in Raw 264.7 cells.<sup>[1]</sup> We also investigated the effects of MEBO on cytotoxicity and NO production. We found that treatment with up to 100  $\mu\text{g/ml}$  MEBO did not affect cell

viability or NO production induced by 1  $\mu\text{g/ml}$  of lipopolysaccharide (LPS) for 20 h (data not shown). These discrepancies may be due to use of different experimental systems and extraction methods. We treated MEBO for 4 h and discarded MEBO containing media, after which cells were stimulated using LPS for 20 h. Conversely, Rokayya *et al.* treated samples for 24 h and did not describe the stimulation method. We also extracted minced cabbage using absolute methanol, while Rokayya *et al.* used ground cabbage and 80% methanol. Considering these differences, the yield of extraction by Rokayya *et al.* may be higher than that obtained by us; however, they did not report their yield.

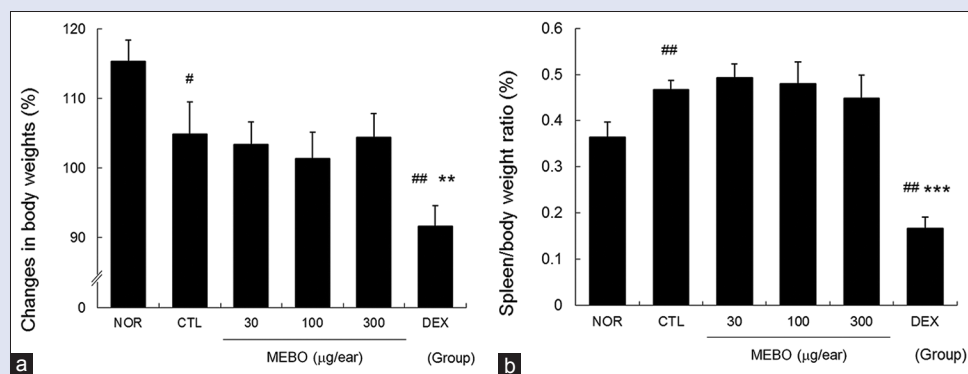
We also investigated the inhibitory effects of MEBO on degranulation of mast cells. We found that MEBO did not inhibit degranulation of mast cells induced by phorbol 12-myristate 13-acetate plus A23187 (data not shown). At present, we are considering whether MEBO can inhibit activation of keratinocytes or not. We already found that treatment with up to 200  $\mu\text{g/ml}$  MEBO did not affect cell viability of HaCaT keratinocytes (data not shown).

Both dexamethasone and MEBO showed similar anti-inflammatory efficacies in CD mice. However, dexamethasone significantly lowered the spleen/body weight ratio, which can be used as a hallmark of immune reaction,<sup>[25-27]</sup> compared to the normal group and the CTL group [Figure 6b]. In addition, average body weight gain was significantly lowered by treatment with dexamethasone [Figure 6a]. These results mean that MEBO did not act as dexamethasone which suppresses general immune reaction.

Taken together, these findings demonstrate that MEBO can be used for the treatment of inflammatory skin diseases. These findings indicate that the therapeutic mechanisms of MEBO are involved in the inhibition of Th1 immune reactions.



**Figure 5:** Effects of methanol extract of *Brassica oleracea* var. capitata L. on levels of tumor necrosis factor- $\alpha$ , interferon- $\gamma$ , interleukin-6, and monocyte chemoattractant protein-1 in contact dermatitis mice. The production levels of tumor necrosis factor- $\alpha$ , interferon- $\gamma$ , interleukin-6, and monocyte chemoattractant protein-1 in inflamed tissues were measured using the cytometric bead array method. A total of 50  $\mu\text{g}$  of tissue lysates were used to measure the cytokine levels. Abbreviations are the same as in Figure 2. (a) Tumor necrosis factor- $\alpha$ ; (b) interferon- $\gamma$ ; (c) interleukin-6; (d) monocyte chemoattractant protein-1. All values are presented as the mean  $\pm$  standard deviation.  $^{##}P < 0.01$  and  $^{###}P < 0.001$  versus nontreated NOR mice,  $^{*}P < 0.05$  and  $^{**}P < 0.01$  versus nontreated contact dermatitis mice (CTL)



**Figure 6:** Effects of methanol extract of *Brassica oleracea* var. capitata L. on spleen body weight ratio in contact dermatitis mice. The spleen body weight ratio was calculated using body and spleen weights measured on day 14. Abbreviations are the same as in Figure 2. (a) Changes in body weights; (b) spleen body weight ratio. All values are presented as the mean  $\pm$  standard deviation. <sup>#</sup> $P < 0.05$  and <sup>##</sup> $P < 0.01$  versus nontreated NOR mice, <sup>\*\*</sup> $P < 0.01$  and <sup>\*\*\*</sup> $P < 0.001$  versus nontreated contact dermatitis mice (CTL)

## CONCLUSIONS

In the present study, we showed that MEBO reduced Th1 skewing reactions such as production of TNF- $\alpha$ , IFN- $\gamma$ , and MCP-1, resulting in reduced epidermal hyperplasia and immune cell infiltrations. These consecutive anti-inflammatory reactions of MEBO ultimately led to the inhibition of ear swelling and erythema. The effects of MEBO were similar or slightly weaker than those of dexamethasone, and there was no general immune suppression observed in the dexamethasone-treated group. Taken together, these findings indicate that MEBO can be used as a relatively safe alternative to corticosteroids.

## Financial support and sponsorship

The National Research Foundation of Korea grant funded by the Korean Government (MSIP; grant no. 2015R1A2A2A04005619 and 2014R1A5A2009936).

## Conflicts of interest

There are no conflicts of interest.

## REFERENCES

- Rokayya S, Li CJ, Zhao Y, Li Y, Sun CH. Cabbage (*Brassica oleracea* L. Var. capitata) phytochemicals with antioxidant and anti-inflammatory potential. *Asian Pac J Cancer Prev* 2014;14:6657-62.
- Lin JY, Li CY, Hwang IF. Characterisation of the pigment components in red cabbage (*Brassica oleracea* L. Var.) juice and their anti-inflammatory effects on LPS-stimulated murine splenocytes. *Food Chem* 2008;109:771-81.
- Noess K. Ulcer-fiber-cabbage and Vitamin U. *Tidsskr Nor Laegeforen* 1986;106:693-4.
- Doll R, Pygott F. Clinical trial of robaden and of cabbage juice in the treatment of gastric ulcer. *Lancet* 1954;267:1200-4.
- Gabrielle H. Encyclopedia of Folk Medicine: Old World and New World Traditions. Santa Barbara, CA: ABC-CLIO; 2004. p. 59-60.
- Wordpress.org. Word Press Foundation; c2000-01. Available from: <http://www.cabbage-vi17.tk/some-tips-cures-folk-cabbage/>. [Last updated on 2016 May 28].
- Lurati AR. Occupational risk assessment and irritant contact dermatitis. *Workplace Health Saf* 2015;63:81-7.
- Peate WE. Occupational skin disease. *Am Fam Physician* 2002;66:1025-32.
- Han HY, Ryu MH, Lee G, Cheon WJ, Lee C, An WG, *et al.* Effects of *Dictamnus dasycarpus* turcz. root bark on ICAM-1 expression and chemokine productions *in vivo* and *in vitro* study. *J Ethnopharmacol* 2015;159:245-52.
- Christensen AD, Haase C. Immunological mechanisms of contact hypersensitivity in mice. *APMIS* 2012;120:1-27.
- Hassimotto NM, Genovese MI, Lajolo FM. Antioxidant activity of dietary fruits, vegetables,

and commercial frozen fruit pulps. *J Agric Food Chem* 2005;53:2928-35.

- Xu F, Zheng Y, Yang Z, Cao S, Shao X, Wang H, *et al.* Domestic cooking methods affect the nutritional quality of red cabbage. *Food Chem* 2014;161:162-7.
- Kim SJ, Kim JM, Shim SH, Chang HI. Anthocyanins accelerate the healing of naproxen-induced gastric ulcer in rats by activating antioxidant enzymes via modulation of Nrf2. *J Funct Foods* 2014;7:569-79.
- Sarandy MM, Novaes RD, da Matta SL, Mezencio JM, da Silva MB, Zanuncio JC, *et al.* Ointment of *Brassica oleracea* var. capitata matures the extracellular matrix in skin wounds of wistar rats. *Evid Based Complement Alternat Med* 2015;2015:919342.
- Hirota A, Kawachi Y, Yamamoto M, Koga T, Hamada K, Otsuka F, *et al.* Acceleration of UVB-induced photoaging in Nrf2 gene-deficient mice. *Exp Dermatol* 2011;20:664-8.
- Grabbe S, Schwarz T. Immunoregulatory mechanisms involved in elicitation of allergic contact hypersensitivity. *Immunol Today* 1998;19:37-44.
- Albanesi C, Cavani A, Girolomoni G. IL-17 is produced by nickel-specific T lymphocytes and regulates ICAM-1 expression and chemokine production in human keratinocytes: Synergistic or antagonist effects with IFN-gamma and TNF-alpha. *J Immunol* 1999;162:494-502.
- Goebeler M, Trautmann A, Voss A, Br, Vos EV, Toksoy A, Gillitzer R, *et al.* Differential and sequential expression of multiple chemokines during elicitation of allergic contact hypersensitivity. *Am J Pathol* 2001;158:431-40.
- Carr MW, Roth SJ, Luther E, Rose SS, Springer TA. Monocyte chemoattractant protein 1 acts as a T-lymphocyte chemoattractant. *Proc Natl Acad Sci U S A* 1994;91:3652-6.
- Xu LL, Warren MK, Rose WL, Gong W, Wang JM. Human recombinant monocyte chemoattractant protein and other C-C chemokines bind and induce directional migration of dendritic cells *in vitro*. *J Leukoc Biol* 1996;60:365-71.
- Bonneville M, Chavagnac C, Vocanson M, Rozieres A, Benetiere J, Pernet I, *et al.* Skin contact irritation conditions the development and severity of allergic contact dermatitis. *J Invest Dermatol* 2007;127:1430-5.
- Kawakami M, Kaneko N, Anada H, Terai C, Okada Y. Measurement of interleukin-6, interleukin-10, and tumor necrosis factor-alpha levels in tissues and plasma after thermal injury in mice. *Surgery* 1997;121:440-8.
- Corsini E, Galli CL. Epidermal cytokines in experimental contact dermatitis. *Toxicology* 2000;142:203-11.
- Crawford GH, Pelle MT, James WD. Rosacea: I. Etiology, pathogenesis, and subtype classification. *J Am Acad Dermatol* 2004;51:327-41.
- Lee HJ, Jo S, Ryu J, Jeong HS, Lee G, Ryu MH, *et al.* Effects of *Schisandra chinensis* turcz. fruit on contact dermatitis induced by dinitrofluorobenzene in mice. *Mol Med Rep* 2015;12:2135-9.
- Jeklova E, Leva L, Jaglic Z, Faldyna M. Dexamethasone-induced immunosuppression: A rabbit model. *Vet Immunol Immunopathol* 2008;122:231-40.
- Ahmed SA, Sriranganathan N. Differential effects of dexamethasone on the thymus and spleen: Alterations in programmed cell death, lymphocyte subsets and activation of T cells. *Immunopharmacology* 1994;28:55-66.