

Detection of Apoptotic Cells in Human Colorectal Cancer by Two Different *in situ* Methods: Antibody against Single-stranded DNA and Terminal Deoxynucleotidyl Transferase-mediated dUTP-biotin Nick End-labeling (TUNEL) Methods

Ichizo Watanabe,¹ Masao Toyoda,¹ Junji Okuda,¹ Toshiyuki Tenjo,¹ Keitaro Tanaka,¹ Tetsuhisa Yamamoto,¹ Hiroshi Kawasaki,¹ Toshihiro Sugiyama,² Yoshihiko Kawarada² and Nobuhiko Tanigawa¹

¹Department of General and Gastroenterological Surgery, Osaka Medical College, 2-7 Daigakumachi, Takatsuki, 569-8686 and ²First Department of Biochemistry, Akita University School of Medicine, 1-1-1 Hondo, Akita, 010-0000

We comparatively investigated the extent of apoptotic cell loss in human colorectal cancers evaluated by two methods, namely the conventional terminal deoxynucleotidyl transferase (TdT)-mediated deoxyuridine triphosphate (dUTP)-biotin nick end-labeling (TUNEL) method and immunohistochemistry for single-stranded (ss) DNA. The apoptotic index (AI) obtained with the TUNEL method was higher than that shown by the immunohistochemistry for ssDNA. However, a significant correlation in AIs evaluated by these methods was found. The AIs obtained by both methods were significantly higher in the advanced cancers than in the early cancers. Cellular proliferation activity was assessed in terms of positivity rate (PR) for expression of proliferating cell nuclear antigen (PCNA). The PR of advanced cancers was significantly higher than that of early cancers. The present results indicate that immunohistochemistry for ssDNA is useful (as is the TUNEL method) for evaluation of apoptotic tumor cells in colorectal carcinomas. In addition, it was confirmed that there is a remarkable increase of not only proliferation activity, but also tumor cell apoptosis in the process of progression of colon cancer from early to advanced stages of the disease.

Key words: Apoptosis — TUNEL — Immunohistochemistry — Single-stranded DNA — Colorectal cancer

Apoptosis is characterized morphologically by large chromatin fragments,¹⁾ by extensive margination and fragmentation of the chromatin viewed electromicroscopically,²⁾ and by a characteristic “ladder formation” of DNA fragments of about 180–200 base pairs by endonuclease activation in gel electrophoresis.³⁾

The terminal deoxynucleotidyl transferase (TdT)-mediated deoxyuridine triphosphate (dUTP)-biotin nick end-labeling (TUNEL) method, which detects apoptosis and programmed cell death has been utilized to identify apoptotic cells at the single-cell level.⁴⁾ In contrast, Tomei has speculated that apoptosis involves the modification of chromatin, which results in a break-down of the supercoiling organization and the formation of individual super breaks. He has further proposed that single-stranded (ss) DNA modification in the nucleosomal linker region might constitute a critical early step in apoptosis.⁵⁾ Naruse *et al.* showed that the antibody against ssDNA is a good marker of both drug-induced apoptosis and programmed cell death during embryogenesis. A polyclonal antibody

against ssDNA has been used to immunohistochemically detect apoptotic cell death in epithelial cells.⁶⁾

There is, to our knowledge, no report on the relationship between apoptosis detected by immunohistochemistry for ssDNA and cellular proliferation activity assessed in terms of the positivity rate (PR) of proliferating cell nuclear antigen (PCNA) in colorectal carcinoma. In the present study, we investigated the extent of apoptotic cell loss in human colorectal cancers by the conventional TUNEL method and by immunohistochemistry for ssDNA. In addition, we compared the apoptotic indices (AIs) obtained by these two methods to determine whether the immunohistochemistry for ssDNA can reliably and accurately demonstrate the apoptosis of colorectal cancer.

MATERIALS AND METHODS

Materials We analyzed the tumor specimens of 76 patients who had undergone tumor resection for adenocarcinoma of the colon or rectum. The tumor tissues were obtained from the routine surgical procedure performed at

E-mail: sur040@poh.osaka-med.ac.jp

the Department of General and Gastroenterological Surgery, Osaka Medical College, in the period from January 1994 to December 1995. The ages of the patients (40 men and 36 women) ranged from 39 to 80 years (mean age, 61.3 years). The classification of the tumors was performed according to the Japanese Classification of Colorectal Carcinoma.⁷⁾ All tissue samples were fixed routinely in 10% formalin overnight at room temperature (RT), embedded in paraffin, and cut into 4- μ m-thick sections. The sections were deparaffinized in xylene, dehydrated through graded alcohols, and washed in freshly prepared 0.01 M phosphate-buffered saline (PBS).

TUNEL method protocol The nuclei of tissue sections were stripped from proteins by incubation with 160 μ l/ml proteinase K (PA) (Sigma Chemical Co., St. Louis, MO) in 0.01 M PBS, pH 7.2, at RT for 20 min, and the slides were then washed three times in H₂O for 5 min each time. Endogenous peroxidase was inactivated by covering the sections with 2% H₂O₂ for 7 min at RT, followed by rinsing 3 times in distilled water (DW) at RT for 5 min each time. The TUNEL method was performed for visualizing the 3'-OH ends of DNA fragments in apoptotic cells according to the protocol described by Gavrieli *et al.*⁴⁾ The sections were soaked in the TdT buffer (30 mM Tris-HCl, pH 7.2, 140 mM sodium cacodylate, 1 mM CaCl₂) for 10 min and then incubated at 37°C for 90 min in a moist chamber with 50 μ l of the TdT buffer containing 0.3 eu/ μ l terminal deoxynucleotidyl transferase (TdT; Lot. No. FAJ401; GIBCO, Grand Island, NY) and 0.04 nmol/ μ l biotin-16-deoxyuridine triphosphate (dUTP; Boehringer Mannheim, Mannheim, Germany). The reaction was stopped by soaking the sections in TB buffer (300 mM sodium chloride, 30 mM sodium citrate), followed by rinsing 3 times in DW at RT for 5 min and PBS at RT for 5 min. The biotinylated dUTP molecules incorporated into nuclear DNA were visualized by incubation with horseradish peroxidase-conjugated streptavidin (Dako, Glostrup, Denmark) diluted 1:100 at 37°C for 30 min in a moist chamber. After further rinsing of the sections in PBS for 5 min 3 times, the peroxidase coloring reaction was performed by immersing the sections for 5 min in 0.05 M Tris-HCl buffer, pH 7.4, containing 30 mg/dl diaminobenzidine tetrahydrochloride, 65 mg/dl sodium azide, 10 mM imidazole, and 0.005% H₂O₂. The nuclei were counterstained with 5% Mayer's hematoxylin buffered with 0.1 M veronal acetate, pH 4.0 for 10 s. A positive control slide was prepared by nicking DNA with DNase I (0.7 μ g/ml; Stratagene Co., La Jolla, CA) for the first staining procedure. A specimen known to be positive for apoptotic cells was used as the positive control for subsequent staining. For the negative control, TdT was replaced with DW. The sections were counterstained with hematoxylin.

Immunohistochemical staining method The immuno-

histochemical studies were performed on strictly 24-h formalin-fixed, paraffin-embedded tissue using the labeled streptavidin-biotin immunoperoxidase technique. One representative paraffin block from each patient, in which viable tumor tissue was present, was used for this study. Four-micrometer-thick sections, mounted on glass slides were dewaxed in xylene, dehydrated in ethanol, and then incubated with 3% hydrogen peroxide for 20 min. After having been washed with PBS, the sections were incubated in 10% normal bovine serum for 5 min, followed by incubation for 1 h with a rabbit polyclonal antibody (PoAb) against ssDNA at a 1:100 dilution and a mouse monoclonal antibody (MoAb) against PCNA (PC10, Dako Japan, Kyoto) at 1:50 dilution. The immunohistochemical study for PCNA was performed on tissues which were prepared by formalin fixation for precisely 24 h, because the fixation period significantly influences the staining. The rabbit IgG is specific for ssDNA and the mouse IgG is specific for PCNA. Biotinylated goat anti-mouse IgG and anti-rabbit IgG (Dako LSAB kit; Dako Japan) were used at a dilution of 1:500. Finally, 0.02% diaminobenzidine and 1% hydrogen peroxide (Dako Japan) in PBS were used as the substrate. The sections were counterstained with hematoxylin.

Determination of AI The AI was expressed as the number of positively staining tumor cells and bodies among 1,000 tumor cells. At least five representative areas without necrosis in a section were selected by light microscopy using 200-fold magnification. Positively staining tumor cells with the morphological characteristics of apoptosis were identified using standard criteria, including chromatin condensation, nucleolar disintegration, and formation of crescentic caps of condensed chromatin at the nuclear periphery.⁸⁾ Single, relatively large ($\geq 4 \mu$ m diameter) and roundish nuclear residues existing in extra- or intratumoral cells with intensive staining were identified as apoptotic bodies. Positively staining cells or bodies located in the stroma and lumen were excluded, because these apoptotic cells or bodies may have originated from other cell types.

Determination of PR The PR was expressed as the ratio of positive cells for PCNA staining to all tumor cells, as a percentage. At least five representative areas in a section were selected by light-microscopic examination at 200-fold magnification and a minimum of 3,000 cells was counted.

Evaluation and statistical methods The correlation between AIs assessed by the TUNEL method and those assessed by the immunostaining method (antibody against ssDNA) was analyzed using the Spearman rank correlation coefficient. Both the χ^2 and Wilcoxon tests were used to determine the statistical correlation between clinicopathological parameters and AI or PR. For all statistical analyses, the criterion of significance was defined as

$P < 0.05$. The term tendency is used where the P value lies between 0.05 and 0.1.

RESULTS

AI and morphological characteristics of apoptosis By the TUNEL method (Fig. 1), positive staining for apoptosis was observed in 92% (70 of 76) of the slides, with AIs from 0 to 83. The mean AI was 27.4 (SD 20.5). Various stages of apoptosis could be found in the same area, and intensive staining was observed even in some “normal-looking” tumor cells. Non-specific necrotic foci showed a faint and diffuse staining and could be distinguished from apoptotic nuclei by simple morphological examination. The immunohistochemical analysis with rabbit PoAb

against ssDNA revealed strong staining in the nuclei of tumor cells together with weak, non-specific cytoplasmic staining (Fig. 2). Positive staining for apoptosis was observed in 92% (70 of 76) of the slides with AIs from 0 to 28. The mean AI was 7.2 (SD 5.7). The AIs obtained by the TUNEL method were higher than those obtained by the immunohistochemical method using IgG specific for ssDNA.

Correlation between AI values obtained by the two methods Regression analysis with the Spearman rank correlation coefficient, on plots of AI values obtained by the TUNEL method versus those obtained with the immunohistochemical method using IgG specific for ssDNA on a per case basis, showed a highly significant positive correlation between the two sets of AIs (Fig. 3; $r = 0.6613$, $P < 0.0001$). The AI values in advanced cancers were sig-

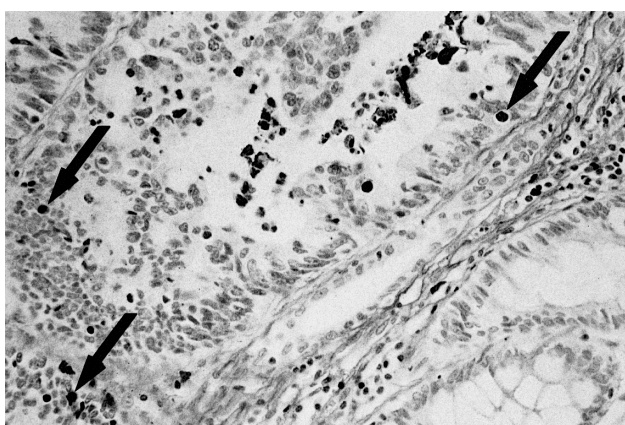


Fig. 1. Apoptotic features visualized by the TUNEL method, with dark brown dots easily recognized ($\times 110$).

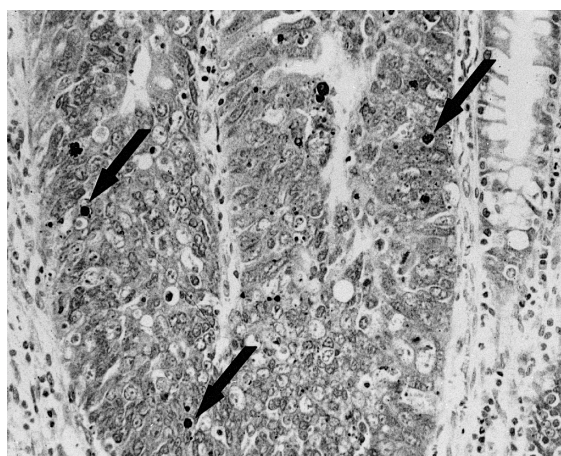


Fig. 2. Photomicrograph of colon cancer stained with ssDNA PoAb. Nuclei of cells were strongly stained brown, with non-specific weak staining in the cytoplasm ($\times 120$).

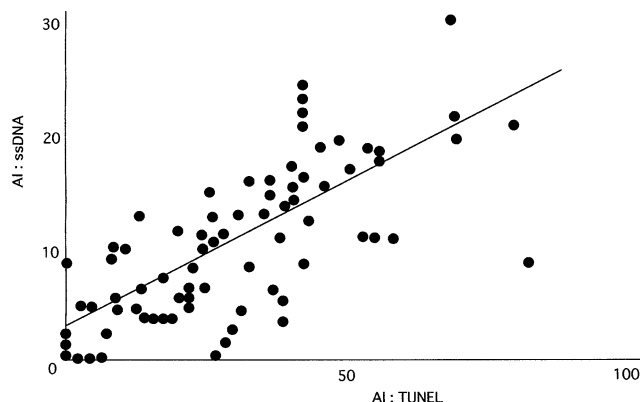


Fig. 3. Correlation between AI values obtained by the TUNEL method and AI values obtained by the immunohistochemical method using IgG specific for ssDNA. $r = 0.6613$, $P < 0.0001$, Spearman.

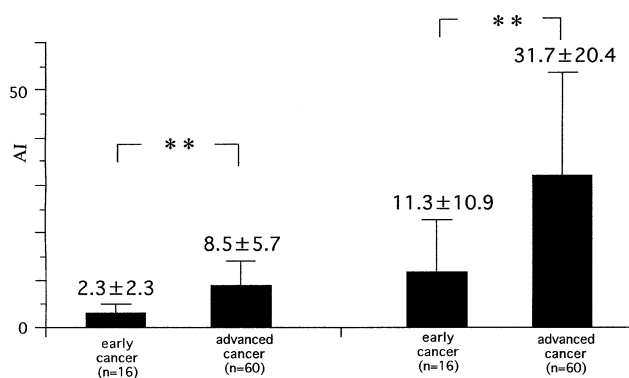


Fig. 4. AI values obtained by the TUNEL method and by the immunohistochemical method using IgG specific for ssDNA in early and advanced colorectal cancers. $** P < 0.01$.

Table I. Relationship between Clinicopathological Features and AI Values Obtained by the Immunohistochemical Method Using IgG Specific for ssDNA or PR Assessed by the Immunohistochemical Method Using a Mouse MoAb against PCNA

Variable	No. of cases	AI ssDNA	<i>P</i> value	PR PCNA	<i>P</i> value
Depth of invasion					
m-sm	16	2.3±2.2] <0.001	19.0±6.7] <0.05
mp-si(ai)	60	8.5±5.7		28.4±15.4	
Lymph node metastasis					
Negative	47	5.8±4.5] <0.05	25.5±13.1] NS
Positive	29	9.5±6.9		27.9±15.8	
Lymphatic invasion					
Negative	22	4.9±4.3] <0.05	25.3±14.9] <0.01
Positive	54	8.2±6.0		26.8±13.9	
Venous invasion					
Negative	30	5.4±5.0] <0.05	22.4±10.5] <0.05
Positive	46	8.4±5.9		29.0±15.6	
Peritoneal metastasis					
Negative	73	7.4±5.8] NS	27.2±20.5] NS
Positive	3	2.7±3.1		31.0±23.8	
Liver metastasis					
Negative	64	7.5±5.9] NS	26.0±19.6] NS
Positive	12	6.0±4.6		34.8±24.5	
Histological typing					
Well-differentiated	43	6.7±6.5] NS	23.1±17.5] NS
Less differentiated	33	7.9±4.5		33.0±22.9	
Tumor size (cm)					
<3	19	5.5±5.6] 0.06	20.4±6.4] NS
≥3	57	7.8±5.7		28.4±15.4	

AI: apoptotic index, PR: positivity rate, NS: not significant.

nificantly higher than those in early cancers obtained not only by the TUNEL method but also by the immunohistochemical method using IgG specific for ssDNA (Fig. 4; $P < 0.01$).

Relationship between AI values and clinicopathological features The correlation between AI and clinicopathological features is shown in Table I. Significant differences in AIs assessed by using an antibody specific to ssDNA were noted according to various tumor pathologies, including depth of tumor invasion, lymph node metastasis, lymphatic invasion and venous invasion. The AIs for invading to mp-si(ai) were significantly higher than those for tumors confined to m-sm. The AI values for positive lymph node metastasis, positive lymphatic invasion and positive venous invasion were significantly higher than those for corresponding negative items, respectively. The AI values for tumors of 3 cm or more in diameter tended to be higher than those of tumors smaller than 3 cm.

Relationship between PCNA labeling indices and clinicopathological features Each colon cancer tissue section was stained with the PCNA MoAb for evaluation of proliferative activity. The nuclei of the PCNA-positive cells were stained brown (Fig. 5). The relationship between the

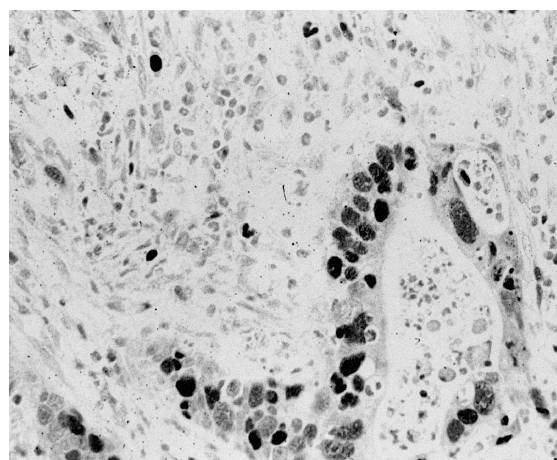


Fig. 5. Photomicrograph of colon cancer stained with PCNA MoAb. Nuclei of cells stained brown are seen ($\times 100$).

PR values and clinicopathological features is summarized in Table I. There was a significant difference in PR according to the depth of tumor invasion; the PR values

of the depth of tumor invasion mp-si(ai) were significantly greater than those of the depth of tumor invasion m-sm. The PR values for tumors with positive lymphatic invasion and positive venous invasion were significantly greater than those for tumors with negative lymphatic invasion or negative venous invasion, respectively. The PR values of tumors 3 cm or more in diameter tended to be higher than those of tumors smaller than 3 cm.

DISCUSSION

DNA fragmentation in apoptotic cells represents an active breakdown of the supercoiled DNA organization by endogenous endonucleases.⁹⁾ The method of *in situ* end-labeling of fragmented DNA (i.e., the TUNEL method) has been utilized to identify apoptotic cells at single-cell level. The feasibility of programmed cell death (PCD) labeling *in situ* by the TUNEL method was first established in the small intestine in humans. The epithelium of this tissue has a high turnover rate. TUNEL findings clearly revealed a distinct pattern of nuclear staining. The TUNEL sequence labels the apoptotic cells in formalin-fixed, paraffin-embedded sections of thymus and lymphoid organs. Epithelial cells at the tip of the villi of the small intestine, surface columnar cells of the colon, desquamating endometrial cells, follicular cells of the ovary, and a few parenchyma cells in the pancreas, liver, and kidney also show positive signals.⁴⁾

The formation of apurinic or apyrimidinic sites, inducing single-strand modification of the DNA chain, is closely associated with the mutagenic activity of a variety of DNA-damaging agents.^{10,11)} Tomei has speculated that apoptosis involves the modification of chromatin, which results in a break-down of the supercoiling organization and the formation of individual super breaks. He has further proposed that ssDNA modification in the nucleosomal linker region might constitute a critical early step in apoptosis.⁵⁾ The experiments presented by Naruse *et al.* showed that the antibody against ssDNA is a good marker of both drug-induced apoptosis and programmed cell death during embryogenesis.⁶⁾ SsDNA stretches 3–4 bases long or longer are detectable by this antibody, with strong reactivity being seen against ssDNA of 5–6 bases long or longer.¹²⁾

In the present study, we comparatively investigated the extent of cell loss in colorectal cancers by the conventional TUNEL method and by immunohistochemistry for ssDNA. The AI values obtained by the TUNEL method were higher than those obtained by the immunohistochemical method. Generally, TUNEL stains not only apoptotic, but also necrotic cells.¹³⁾ Study of apoptosis and necrosis in the liver demonstrated that TUNEL can be severely misleading as a method for evaluation of cell death mechanism.¹⁴⁾ Also, sensitivity of TUNEL is limited

by the detection of only late apoptotic events accompanied by internucleosomal DNA degradation.¹⁵⁾ In contrast, PoAb to ssDNA detected cells at an early stage of apoptosis, which preceded all detachment and DNA fragmentation.^{16,17)} Our data suggested that anti-ssDNA PoAb may be a more specific (no staining of necrotic cells) and sensitive (staining of early apoptosis in the absence of internucleosomal DNA fragmentation) reagent for the detection of apoptotic cells. In the present study, indeed, positive staining for ssDNA was not observed in necrotic cells, especially within the lumen. However, higher AIs by TUNEL compared to those by anti-ssDNA PoAb directly conflict with this. A possible explanation is non-specific nuclear staining, including necrotic cells and disintegrated nucleoli from non-apoptotic cell debris. The AIs obtained by immunohistochemistry for ssDNA as well as those by the TUNEL method were significantly higher in the advanced cancers than in the early-stage cancers, especially with regard to the depth of tumor invasion, lymph node metastasis, lymphatic invasion and venous invasion. A significant positive correlation was found between AI values assessed by the TUNEL method and those by immunohistochemistry. Thus, immunohistochemistry for ssDNA is valuable (as is the TUNEL method) for detecting apoptosis.

PCNA is the auxiliary protein of DNA polymerase- δ . The nuclear protein is known as cyclin, with a relative molecular mass of 36,000 (36 kDa); its synthesis is correlated with the proliferative state of the cell. PCNA is also a cell cycle-related nuclear protein that is maximally elevated in the late G₁ and S phases of proliferating cells. The percentage of PCNA-positive cells of the advanced colorectal cancers (28.4%) was significantly higher than that of the early cancers (19.0%). Our study thus demonstrated that an increase of cellular proliferation activity was found in the progression of colon cancer from the early to the advanced stages of the disease.

The AI values obtained by the immunohistochemistry for ssDNA were significantly higher in the advanced cancers than in the early-stage cancers, while a higher percentage of PCNA-positive tumor cells was also seen in more advanced tumors, indicating that the rates of cellular proliferation and cell loss are increased in the advanced stage compared to the early stage of cancer. More advanced tumors tended to have a relatively greater degree of cell proliferation than less advanced tumors. In addition, apoptosis is not only involved in cell turnover in many normal tissues, but also accounts for extensive spontaneous cell loss in malignant neoplasms.²⁾ It remains controversial whether proliferative indices correlate positively with apoptotic indices¹⁸⁾ and whether a higher occurrence of apoptosis may reflect the slow-growing nature of a carcinoma.¹⁹⁾ The positive correlation between proliferative and apoptotic indices in colorectal cancers,

seen in this study, is consistent with other reports.^{20, 21)} It remains unclear, however, whether and to what extent the type of “programmed” cell death whose hallmark is the endonucleolytic cleavage of genomic DNA at internucleosomal sites²²⁾ is an inherent characteristic of a given carcinoma and whether it is influenced by microenvironmental or other stimuli. The mechanisms responsible for apoptotic cell death in neoplastic tissues remain incompletely understood.

REFERENCES

- 1) Payne, C. M. and Cromey, D. W. An image analysis workstation designed for multiple users: application of quantitative digital imaging techniques to electron microscopy. *Ultrastruct. Pathol.*, **16**, 147–154 (1992).
- 2) Kerr, J. F. R., Wyllie, A. H. and Currie, A. R. Apoptosis: a basic biological phenomenon with wide-ranging implications in tissue kinetics. *Br. J. Cancer*, **26**, 239–257 (1972).
- 3) Compton, M. M. A biochemical hallmark of apoptosis: internucleosomal degradation of the genome. *Cancer Metastasis Rev.*, **11**, 105–119 (1992).
- 4) Gavrieli, Y., Sherman, Y. and Ben-Sasson, S. A. Identification of programmed cell death *in situ* via specific labeling of nuclear DNA fragmentation. *J. Cell Biol.*, **119**, 493–501 (1992).
- 5) Tomei, L. D. Apoptosis: a program death or survival? In “Apoptosis, The Molecular Basis of Cell Death,” ed. L. D. Tomei and F. Cope, pp. 279–316 (1991). Cold Spring Harbor Laboratory Press, New York.
- 6) Naruse, I., Keino, H. and Kawarada, Y. Antibody against single-stranded DNA detects both programmed cell death and drug-induced apoptosis. *Histochemistry*, **101**, 73–78 (1994).
- 7) Japanese Society for Cancer of the Colon and Rectum. Japanese “Classification of Colorectal Carcinoma,” pp. 3–74 (1997). Kanehara Co., Tokyo.
- 8) Thompson, C. B. Apoptosis in the pathogenesis and treatment of disease. *Science*, **267**, 1456–1462 (1995).
- 9) Cohen, J. J. and Duke, R. C. Glucocorticoid activation of a calcium-dependent endonuclease in thymocyte nuclei leads to cell death. *J. Immunol.*, **132**, 38–42 (1984).
- 10) Fortini, P., Bigmami, M. and Dogliotti, E. Evidence for AP site formation related to DNA-oxygen alkylation in CHO cells treated with ethylating agents. *Mutat. Res.*, **236**, 129–137 (1990).
- 11) Laval, J., Boiteux, S. and O’Connor, T. R. Physiological properties and repair of apurinic/aprimidinic sites and imidazole ring-opened guanines in DNA. *Mutat. Res.*, **233**, 73–79 (1990).
- 12) Umemura, S., Yasuda, M., Osamura, Y., Kawarada, Y., Sugiyama, T. and Tsutsumi, Y. Enhancement of TdT-mediated dUTP-biotin nick end labeling (TUNEL) method using mung bean nuclease, a single-strand DNA digestion enzyme. *J. Histochem. Cytochem.*, **44**, 125–132 (1996).
- 13) Ansari, B., Coates, P. J., Greenstein, B. D. and Hall, P. A. *In situ* end-labeling detects DNA strand breaks in apoptosis and other physiological and pathological states. *J. Pathol.*, **170**, 1–8 (1993).
- 14) Grasl-Kraupp, B., Ruttkay-Nedecky, B., Koudelka, H., Bukowska, K., Bursch, W. and Schulte-Hermann, R. *In situ* detection of fragmented DNA (TUNEL assay) fails to discriminate among apoptosis, necrosis, and autolytic cell death: a cautionary note. *Hepatology*, **21**, 1465–1468 (1995).
- 15) Desjardins, L. M. and Macmanus, J. P. An adherent cell model to study different stages of apoptosis. *Exp. Cell Res.*, **216**, 380–387 (1995).
- 16) Frankfurt, O. S., Seckinger, D. and Sugarbaker, E. V. Pleiotropic drug resistance and survival advantage in leukemic cells with diminished apoptotic response. *Int. J. Cancer*, **59**, 217–224 (1994).
- 17) Frankfurt, O. S., Robb, J. A., Sugarbaker, E. V. and Villa, L. Monoclonal antibody to single-stranded DNA is a specific and sensitive cellular marker of apoptosis. *Exp. Cell Res.*, **226**, 387–393 (1996).
- 18) Leoncini, L., Vecchio, M. T. D., Megha, T., Barbini, P., Galieni, P., Pileri, S., Sabattini, E., Gherlinzoni, F., Tosi, P., Kraft, R. and Cottier, H. Correlations between apoptotic and proliferative indices in malignant non-Hodgkin’s lymphomas. *Am. J. Pathol.*, **142**, 755–763 (1993).
- 19) Kasagi, N., Gomyo, Y., Shirai, H., Tsujitani, S. and Ito, H. Apoptotic cell death in human gastric carcinoma: analysis by terminal deoxynucleotidyl transferase-mediated dUTP-biotin nick end labeling. *Jpn. J. Cancer Res.*, **85**, 939–945 (1994).
- 20) Tatebe, S., Ishida, M., Kasagi, N., Tsujitani, S., Kaibara, N. and Ito, H. Apoptosis occurs more frequently in metastatic foci than in primary lesions of human colorectal carcinomas: analysis by terminal-deoxynucleotidyl-transferase-mediated dUTP-biotin nick end labeling. *Int. J. Cancer*, **65**, 173–177 (1996).
- 21) Hawkins, N., Lees, J., Hargrave, R., O’Connor, T., Meagher, A. and Ward, R. Pathological and genetic correlates of apoptosis in the progression of colorectal neoplasia. *Tumour Biol.*, **18**, 146–156 (1997).
- 22) Compton, M. M. Laboratory methods: development of an apoptosis endonuclease assay. *DNA Cell Biol.*, **10**, 133–141 (1991).

(Received October 14, 1998/Revised November 30, 1998/ Accepted December 4, 1998)