

## Mutations of *p53* in Morphologically Non-neoplastic Mucosa of Long-standing Ulcerative Colitis

Hideya Takaku,<sup>1,2,3</sup> Yoichi Ajioka,<sup>1</sup> Hidenobu Watanabe,<sup>1</sup> Hideki Hashidate,<sup>1</sup> Satoshi Yamada,<sup>1</sup> Junji Yokoyama,<sup>1</sup> Shinsuke Kazama,<sup>1</sup> Takeyasu Suda<sup>2</sup> and Katsuyoshi Hatakeyama<sup>2</sup>

<sup>1</sup>First Department of Pathology and <sup>2</sup>First Department of Surgery, Niigata University School of Medicine, 1-757 Asahimachi-dori, Niigata 951-8510

Two cases of ulcerative colitis (UC)-associated carcinoma or dysplasia and morphologically non-neoplastic mucosa with *p53* protein overexpression (MNNM-*p53*OE) were selected. DNA was extracted from the paraffin blocks of these lesions and exons 5–8 of the *p53* gene were analyzed by PCR and direct sequencing. In addition, mutations in *K-ras* codon 12 were analyzed by PCR-RFLP methods. MNNM-*p53*OE was located surrounding and adjoining a coexisting carcinoma and/or dysplasia. A *p53* mutation was detected in 12/22 (54.5%) MNNM-*p53*OE samples, 4/8 (50%) dysplasia samples and 8/8 (100%) carcinoma samples. The *p53* mutations detected in MNNM-*p53*OE were identical to those demonstrated in the adjoining carcinoma and/or dysplasia. No *K-ras* codon 12 mutation was detected in any of the samples. These results indicate that MNNM-*p53*OE may share an identical clonal linkage with a coexisting carcinoma and/or dysplasia, and may be an initial and submorphological form of UC-associated neoplasia. Recognition of MNNM-*p53*OE in biopsy specimens may help to identify patients with UC at risk of developing colorectal carcinoma.

Key words: Ulcerative colitis — Colorectal cancer — Dysplasia — *p53* — *K-ras*

Long-standing and extensive ulcerative colitis (UC) increases one's risk for developing colorectal cancer.<sup>1</sup> Most, if not at all, UC-associated carcinomas (UAC) derive from unequivocal neoplastic change in the mucosa known as dysplasia.<sup>2</sup> Dysplasia is accepted as a histologic marker of increased cancer risk in UC, and its detection is an end point of endoscopic surveillance programs to identify UC patients at risk for developing colorectal cancer.<sup>2</sup> However, the histologic diagnosis of dysplasia is sometimes subjective, and the differentiation of it from epithelia with inflammatory regenerative atypia is not always straightforward. Objective methods to identify patients at risk for developing carcinoma or methods to add an objective criterion to the histologic diagnosis of dysplasia should be established.

The *p53* gene is a member of a family of tumor suppressor genes, and inactivation of this protein plays an crucial role in the emergence and further progression of a multitude of human malignancies<sup>3,4</sup> including carcinoma of the colon and rectum.<sup>5,6</sup> In UAC, mutations of the *p53* gene are regarded as a relatively early event. The frequency of *p53* alterations including mutation and loss of heterozygosity (LOH) in UAC have been reported to be 71 to 100%<sup>7–11</sup> and 34 to 52%<sup>7,9–11</sup> within dysplasia, a pre-malignant condition. Abnormalities in the *p53* gene can be detected immunohistochemically and correlate with

increased expression of its protein. The wild-type *p53* protein has a short half-life, so that it cannot be detected immunohistochemically, whereas many of the mutated forms of the *p53* protein accumulate, leading to increased protein levels.<sup>12</sup> The immunohistochemical detection of such increased mutated *p53* protein can be a useful marker for mutated *p53*.<sup>13</sup> In UAC and dysplasia, the prevalence of *p53* protein overexpression has been reported to be 52 to 85% and 30 to 80%,<sup>8,14–16</sup> respectively. Thus, the immunohistochemical detection of *p53* protein overexpression can be utilized for a more objective differential diagnosis of UAC and/or dysplasia from non-neoplastic conditions.

However, *p53* immunoreactive cells can be detected not only in UC-associated neoplasia, but also in various inflammatory states.<sup>17,18</sup> The difference between these two conditions is the distribution of the *p53* immunoreactive cells.<sup>17</sup> In UC-associated neoplasia, the *p53* immunoreactive cells appear in a diffuse or aggregated pattern,<sup>14</sup> and almost all of the cells constituting the neoplastic tissue are strongly positive. Alternatively, it can appear as an aggregation of uniformly positive cells with a distinct demarcation from the surrounding epithelium. On the other hand, inflammatory mucosa shows a sporadic (or scattered) pattern<sup>17,18</sup> with only several positive cells scattered in the crypts. Thus, although *p53* immunostaining has been regarded as a useful marker for diagnosing UC-associated neoplasia, the staining pattern has to be carefully evaluated, and only a diffuse (or aggregated) staining

<sup>3</sup> To whom correspondence should be addressed.  
E-mail: htkq@qg7.so-net.ne.jp

pattern should be considered as a signal of neoplastic change. In this sense, the term 'p53 protein overexpression,' implying an accumulation of mutant p53 protein, should only be used when p53-positive cells are present in a diffuse or aggregated pattern.

Recently, we have reported a case of UC with p53 protein overexpression in advanced carcinoma invading the adventitia and in a flat lesion composed of mixed low- and high-grade dysplasia.<sup>19)</sup> A notable finding was that the histologically non-neoplastic looking mucosa adjacent to the carcinoma showed p53 immunoreactive cells with a staining pattern similar to that of UC-associated neoplasia. From a genetic standpoint, *p53* gene alterations have been reported within non-neoplastic mucosa of UC.<sup>7, 9, 20)</sup> However, it is not known whether such mucosa with *p53* mutations also show p53 protein overexpression. If histologically non-neoplastic-appearing mucosa with p53 protein overexpression harbors *p53* mutations, this may be an early warning sign for UC patients at risk of developing carcinoma.

In this study, we examined two cases of UC (including the previously reported one) with colorectal carcinoma and/or dysplasia and adjacent non-neoplastic-appearing mucosa with p53 protein overexpression. We assayed for the presence of *p53* gene mutations in each set of tissues. In addition, we investigated mutations in *K-ras* codon 12, which have been reported to be less frequent in UAC and dysplasia than in sporadic colorectal neoplasms.

## MATERIALS AND METHODS

**Samples** Colectomy specimens were obtained from 7 patients with UC complicated with carcinoma and/or dysplasia. Five patients showed advanced carcinoma and/or dysplasia, and 2 showed dysplasia alone. The specimens were fixed in 10% formalin, and each entire specimen was cut into 5 mm step sections and embedded in paraffin. All the paraffin blocks were cut into three serial 3- $\mu$ m-thick slices for hematoxylin and eosin (HE) staining and for p53 and Ki-67 immunostaining (described below). By histologic and immunohistochemical examinations, two resected colorectum specimens were found to have non-neoplastic-appearing mucosa with p53 protein overexpression (MNNM-p53OE: morphologically non-neoplastic mucosa with p53 overexpression). One patient (case 1) was a 29-year-old woman with a 12-year history of extensive mucosal disease involving the entire colorectum, and low-grade dysplasia in the descending colon. The other patient (case 2) was a 53-year-old man with a 22-year history of UC involving the entire colorectum,<sup>19)</sup> with invasive adenocarcinoma and dysplasia (low- and high-grade) in the rectum.

**Histologic examination** In this study, we used the histologic term dysplasia in the sense of the standardized clas-

sification of Riddell *et al.*,<sup>2)</sup> as an unequivocal epithelial proliferation. However, we have suggested that dysplasia can be classified as either adenoma, or intramucosal carcinoma with low-grade atypia or high-grade atypia.<sup>21)</sup> This is because of the different histological criteria between Western and Japanese pathologists.<sup>22)</sup> The dysplasia found in the two cases of UC were diagnosed as intramucosal carcinoma of low and high-grade atypia according the criteria of the latter.

**Immunohistochemistry** Immunostaining for p53 protein was carried out using the monoclonal antibody PAb1801 (Oncogene Science Inc., Manhasset, NY) by a streptavidin-biotin immunoperoxidase (SAB) method. p53 protein overexpression was classified as : (-), negative ; (+), a few scattered positive cells ; (++) , localized aggregation of positive cells ; (+++) , diffusely positive cells. p53 protein overexpression was defined as a staining pattern of (++) or (+++). To detect proliferating cells, Ki-67 immunostaining was done using the monoclonal antibody MIB-1 (Immunotech, Marseilles, France) by a SAB method, as well.

**DNA extraction** DNA was extracted from carcinoma, dysplasia, MNNM-p53OE, and non-neoplastic mucosa without p53 protein overexpression, using ten 10- $\mu$ m-thick sections, by a microdissection method carried out manually with a microscope at a magnification of 10 $\times$ 10, with commercially available sterilized disposable 25 G $\times$ 1 needles ( $\phi$  0.5mm) (Terumo, Tokyo) on a syringe. The DNA was isolated using a DNA Isolater PS Kit (WAKO Pure Chemical Industries Ltd., Osaka) and dissolved in 30  $\mu$ l of distilled water.

**Analysis of p53 mutation** Exons 5, 6, 7 and 8 of the *p53* gene were amplified by a nested polymerase chain reaction (PCR) using two sets of primers for each exon as described previously.<sup>23)</sup> DNA sequencing of the PCR products was done using an AutoLoad Solid Phase Sequencing Kit (Pharmacia, Uppsala, Sweden) with a fluorescent sequencer apparatus (A.L.F. DNA sequencer; Pharmacia) equipped with A.L.F. Manager Version 2.6. Each PCR product was sequenced in both directions (forward and reverse) at least twice to confirm the reproducibility of the products.

**Analysis of K-ras codon 12 mutation** Assaying for *K-ras* codon 12 point mutations was performed using the nested polymerase chain reaction restriction fragment length polymorphism (PCR-RFLP) method described by Ooshima *et al.*<sup>24)</sup> Briefly, PCR products (10  $\mu$ l) were incubated with 1  $\mu$ l of MvaI (TaKaRa, Kyoto) at 37°C for 6 h, electrophoresed in a 3.5% NuSieve agarose gel (FMC Bio-products, Rockland, ME), and stained with ethidium bromide. The wild-type PCR products are cleaved by MvaI, generating bands of 86 bp fragments. Any PCR product not cleaved by MvaI (i.e., 106 bp fragment) was considered to contain a mutation within codon 12.

## RESULTS

**Distribution of carcinoma, dysplasia and MNNM-p53OE** In case 1, low-grade dysplasia were identified in the descending colon, being of papillary and granular type macroscopically. MNNM-p53OE was located adjoining and surrounding the dysplasia (Fig. 1A). In case 2, an expansive ulcerating tumor of mixed histology with well-differentiated tubular adenocarcinoma and solid adenocarcinoma invading the adventitia was present in the rectum.<sup>19</sup> Low- and high-grade dysplasia were found adjacent to the invasive carcinoma, and MNNM-p53OE was observed in the surrounding both carcinoma and dysplasia (Fig. 1B). In both cases, MNNM-p53OE showed a flat appearance which could not be recognized macroscopically.

**Histologic and immunohistochemical features of MNNM-p53OE** p53 immunostaining showed diffuse positivity (+++) within both the carcinoma and dysplasia

of the two cases (Fig. 2). The immunostaining pattern of the MNNM-p53OE was moderate (++) with the cells in the lower half of the crypts showing strong and diffuse positivity, although the number of p53-immunoreactive cells diminished closer to the surface epithelium (Fig. 3). The p53-positive cell distribution exceeded that of the proliferating cells detected by MIB-1 immunostaining (Ki-67 staining). In both cases, the histologic features of the MNNM-p53OE were those of remission phase UC, corresponding to 'negative for dysplasia.'<sup>2)</sup> The crypts were distorted and branched, with focal papillary structure indicating regenerative nature. Cytologically, they showed rather well-preserved goblet cells without dystrophic type, little nuclear stratification, a low nuclear-cytoplasmic ratio (N/C ratio) and surface mucus cell maturation.

**DNA analysis** The results of examination of the p53 mutational status of the two cases are shown in Table I. Considering the known p53 intramucosal mutational heterogeneity of colorectal neoplasms,<sup>25)</sup> several samples from

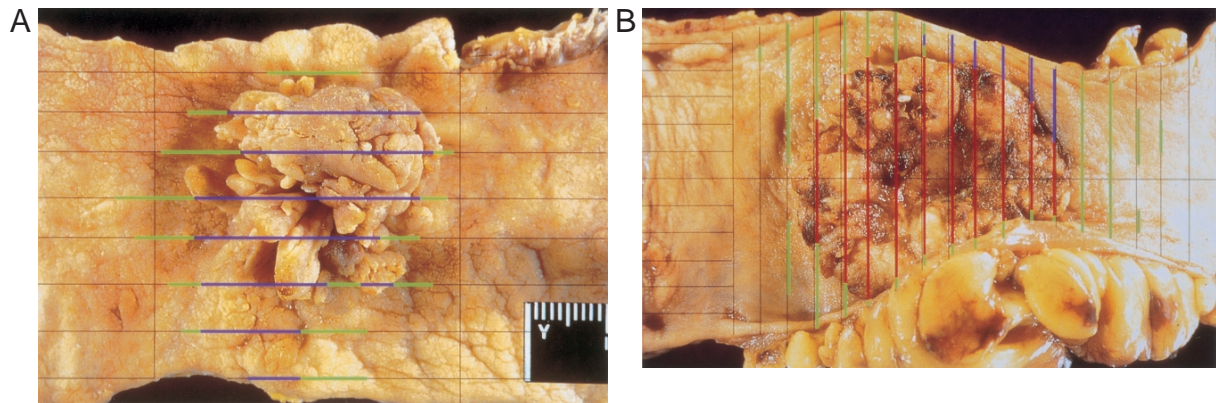


Fig. 1. Mapping of carcinoma and dysplasia (according to the classification of Riddell *et al.*<sup>2)</sup>) and MNNM-p53OE in two cases of ulcerative colitis. Blue line, dysplasia (intramucosal carcinoma); green line, MNNM-p53OE; red line, invasive carcinoma.

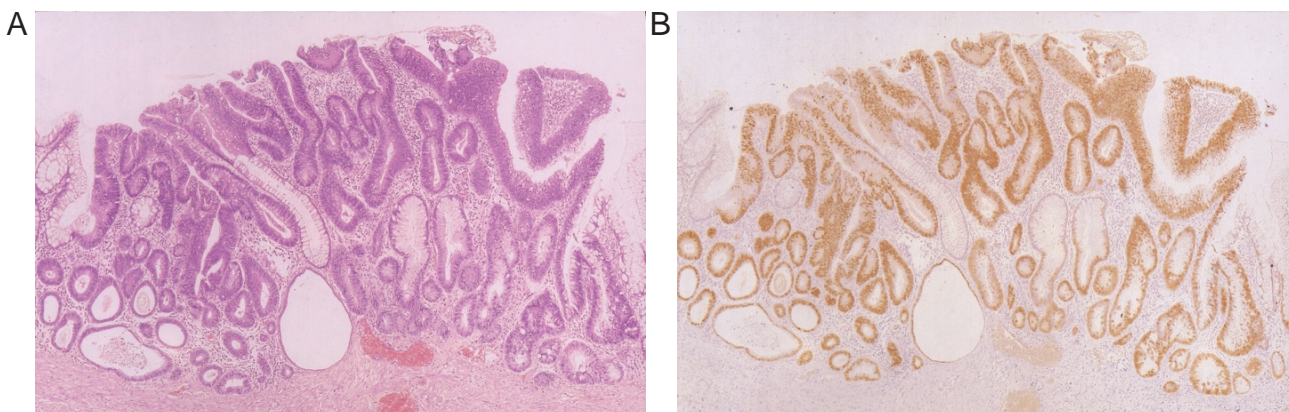


Fig. 2. Dysplasia in case 1 showing diffuse positivity by p53 immunostaining. A, HE staining; B, p53 immunostaining.

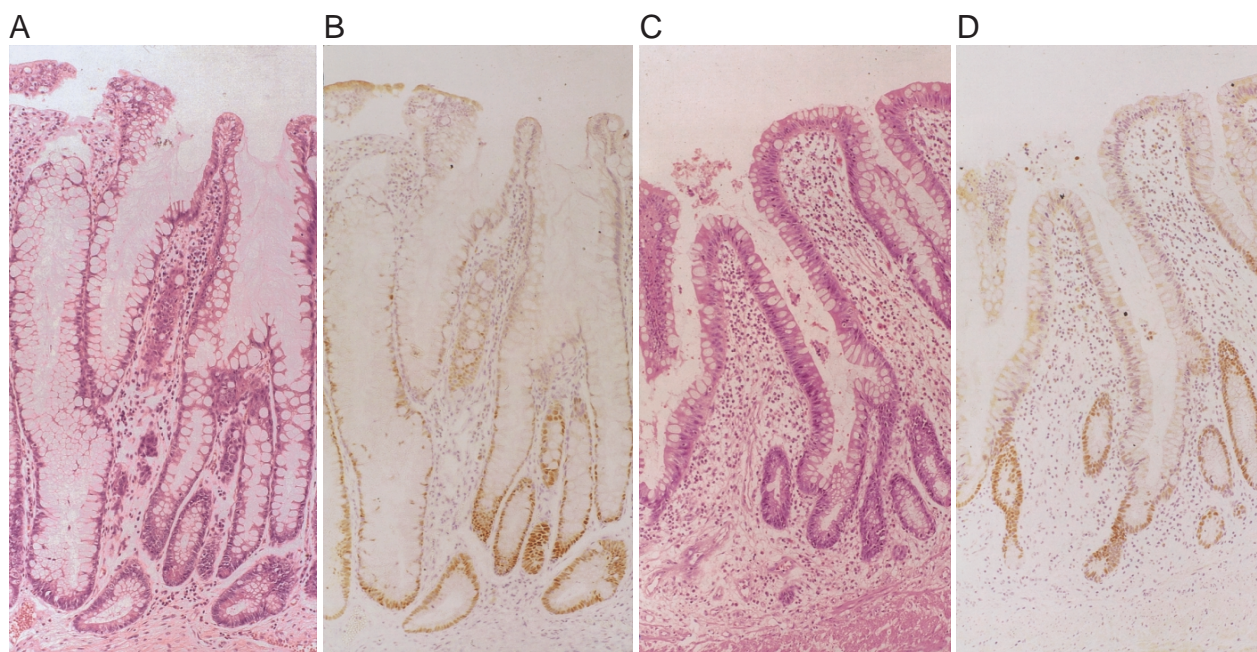


Fig. 3. Mucosa negative for dysplasia, with p53 protein overexpression (MNNM-p53OE: non-neoplastic mucosa with p53 protein overexpression), seen in case 1 (A, B) and case 2 (C, D). Cells of the lower half of the crypts show strong and diffuse positivity by p53 immunostaining (B, D).

Table I. p53 Mutational Status of MNNM-p53OE, Dysplasia and Invasive Carcinoma

Sample	MNNM-p53OE <sup>a)</sup>		Dysplasia		Carcinoma <sup>b)</sup>	
	No. of focus	Codon	No. of focus	Codon	No. of focus	Codon
Case 1	3	wild	1	wild	—	—
	2	273	3	273	—	—
Case 2	7	wild	3	wild		
	8	173	1	173	8	173
	2	272				

a) Morphologically non-neoplastic mucosa with p53 protein overexpression.

b) Invasive carcinoma.

wild: mutation in exons 5 to 8 not detected; codon 273: CGT→TGT, Arg→Cys; codon 272: GTG→GCG, Val→Ala; codon 173: GTG→TTG, Val→Leu.

each specimen (e.g., five samples from MNNM-p53OE of case 1) were selected for DNA analysis. Furthermore, each MNNM-p53OE sample consisted of a set of two separately extracted DNAs, one from the upper half of the crypts showing little or no p53 immunoreactivity, and the other from the lower half of the crypts, which harbored

diffusely p53-positive cells. The results of the DNA analysis (both p53 and K-ras) were identical in the upper half and the lower half of the crypts in each. Four DNA samples from non-neoplastic mucosa without p53 protein overexpression (2 from the proximal side and 2 from the distal side of the carcinoma or dysplasia) were examined for each case.

Overall, p53 mutations were detected in 2/5 (40%) and 10/17 (59%) of the DNA samples from MNNM-p53OE in cases 1 and 2, respectively. Mutation rates in dysplasia were 75% and 25% for cases 1 and 2, respectively, and all samples from invasive carcinoma showed mutations. No mutation was found in non-neoplastic mucosa without p53 protein overexpression (data not shown). In case 1, a single and identical p53 point mutation (mutation at codon 273) status was found both in the MNNM-p53OE and the adjoining dysplasia. In case 2, two different mutations (codons 173 and 272) were detected in MNNM-p53OE, while only a single mutation was found in the dysplasia and invasive carcinoma (mutation at codon 173) (Fig. 4). However, the mutation in the dysplasia and invasive carcinoma (codon 173) was identical to the major one found in the adjoining MNNM-p53OE (Table I).

None of the DNA samples used for the p53 mutational analysis showed a K-ras codon 12 mutation (data not shown).

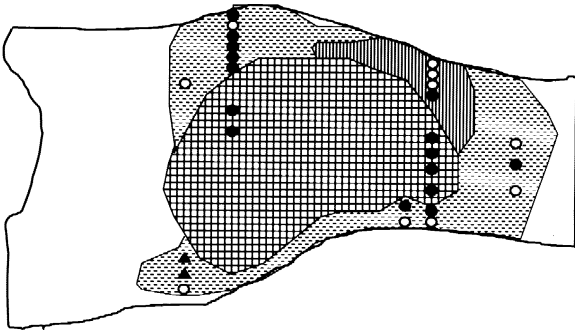


Fig. 4. Correlation of histological diagnosis and p53 mutational status (case 2). An identical p53 mutation (mutation at codon 173) was found in the dysplasia, invasive carcinoma and the adjoining MNNM-p53OE. ■■■, invasive carcinoma; ■■■■, dysplasia (intramucosal carcinoma); ■■■, MNNM-p53OE. p53 mutational status (○, wild; ●, mutation at codon 173; ▲, mutation at codon 272).

## DISCUSSION

p53 immunoreactivity in the colorectum complicating UC is classified into two patterns: sporadic (or scattered) and diffuse (or aggregated). Scattered positive cells are seen in various phases of the inflammatory mucosa of UC,<sup>17, 18)</sup> which may be led by the accumulation of wild-type p53 protein causing a G1 arrest of cells damaged by inflammation, allowing time for necessary cell repair.<sup>18)</sup> Supporting this speculation is the variation in the frequency of p53-positive cells in different inflammatory phase mucosae. Cells positive for p53 most frequently appear in mucosa in the active phase of inflammation, which would have sustained more cell stress or damage than resolving-phase or remission-phase mucosa.<sup>17, 18)</sup> In our previous study, the mean population of p53-positive cells per crypt was 5.4, 2.4 and 1.3 in active, resolving and remission-phase mucosa, respectively.<sup>17)</sup> On the other hand, dysplasia and carcinoma display diffuse (or aggregated) immunoreactivity.<sup>14, 19)</sup> Furthermore, sporadic p53-positive cells in inflamed mucosa only occur within the proliferative zone, while diffuse (or aggregated) positive cells in UC-associated neoplasia are found irrespective of proliferating activity.<sup>17, 19)</sup>

The MNNM-p53OE (morphologically non-neoplastic mucosa with p53 protein overexpression) of the present study showed a discrepancy in the correlation between p53 immunoreactivity and the histology described above. Although histologically it appeared as a remission-phase regenerative epithelium corresponding to 'negative for dysplasia,'<sup>2)</sup> it displayed aggregations of p53-immunoreactive cells in the lower half of the crypts. The number of p53-positive cells gradually diminished closer to the surface with mucus maturation (cellular differentiation). To

date, the demonstration of such mucosa in UC has been reported only in our previous<sup>19)</sup> and the present study. However, a similar p53 staining pattern has been observed in normal squamous epithelium of the skin. Ren *et al.*<sup>26)</sup> demonstrated uniform nuclear p53 staining (compact staining pattern) within the basal cells of an otherwise normal epidermis, and often the staining pattern became weak or absent in the upper layer, which consisted of mature keratinocytes. After microdissection and sequencing of the DNA, the keratinocytes with such a p53 staining pattern harbored mutated p53, and were interpreted as representing clandestine clonal proliferations, which may involve large areas of the epidermis without signaling their presence by any morphologic alterations. Ren *et al.*<sup>26)</sup> speculated that such groups of keratinocytes are submorphologic precursors of dysplasia and skin cancer, but they failed to prove the occurrence of identical p53 mutations in any coexisting areas of dysplasia, carcinoma *in situ* or squamous cell carcinoma.

The present study demonstrated p53 gene mutations in MNNM-p53OE. Our results are consistent with earlier studies detecting p53 genetic alterations in specimens that were histologically indefinite or negative for dysplasia. Twenty-nine percent<sup>7)</sup> and 19%<sup>9)</sup> of mucosa samples negative for dysplasia obtained from UC patients with carcinoma and/or dysplasia were reported to have p53 gene mutations. Kim *et al.*<sup>20)</sup> also reported two cases of UC without dysplasia that had a p53 mutation. The significance of the present study is that the MNNM-p53OE had identical mutations to those in the adjacent carcinoma and/or dysplasia. These data indicate that the MNNM-p53OE may belong to same original clone as the neoplasia. Considering its distribution around carcinoma and/or dysplasia, MNNM-p53OE can be regarded as their direct precursor.

However, the frequencies of p53 mutation in MNNM-p53OE and dysplasia were not 100%, while all of the DNA samples from invasive carcinoma (case 2) demonstrated identical mutation. Beside the possibility that some mutations other than in exons 5 to 8 might be missed by the present investigation, this mutational heterogeneity in MNNM-p53OE and dysplasia could be explained by their oligo-clonal nature. MNNM-p53OE and dysplasia could be composed of various subclones in regard to p53 mutation and one of these subclones would develop to monoclonal invasive carcinoma after clonal selection. We have demonstrated a similar phenomenon in sporadic colorectal carcinomas, i.e., p53 mutational heterogeneity in carcinoma in mucosa and homogeneity in invasive carcinoma.<sup>25)</sup>

MNNM-p53OE may be an initial and submorphologic<sup>26)</sup> form of UC-associated neoplasia, and such mucosa can be detected by means of immunohistochemistry. Recognition of MNNM-p53OE in immunostained biopsy specimens

might be useful for the early detection of patients with UC at risk for developing carcinoma and dysplasia. In this study, only 2 out of 7 cases were found to have MNNM-p53OE. The reason for this low frequency of MNNM-p53OE may be that our materials consisted mostly of advanced-stage UAC. We presume that early-stage UAC (early carcinoma) and dysplasia would more frequently be accompanied with MNNM-p53OE.

In MNNM-p53OE, identical *p53* mutations were demonstrated in both the upper and the lower half of the crypts, although the extents of *p53* immunoreactivity were different. The lower half showed aggregation of positive cells, whereas the upper half displayed few or no positive cells. Similar to normal colonic crypts, the lower half of the MNNM-p53OE crypts involved the cell proliferating zone, and the number of proliferating cells detected by MIB-1 (Ki-67) immunostaining diminished toward the surface, with corresponding mucus cell differentiation. There are at least two possible explanations for the demonstration of identical *p53* mutations in the upper half of the crypts without *p53* immunoreactivity: either growth arrest or cell differentiation may suppress *p53* protein expression. In the former case, *p53* gene expression may be upregulated in the proliferating cells in order to stop the multiplication of damaged cells, and its expression would be down-regulated when cells leave the proliferation cycle and enter the G0 phase. The latter explanation was demonstrated to apply in keratinocytes by Weinberg *et al.*, who showed that *p53* synthesis declined in differentiating but not growth-arrested cells.<sup>27)</sup> Whether the same *p53* regulation mechanism as in keratinocytes occurs in colon cells is not known. However, a previous study examining the *p53* immunoreactivity of neoplastic endocrine and Paneth cells in UC-associated cancer or dysplasia<sup>28)</sup> may favor the latter explanation, since such differentiated cells displayed no *p53* immunoreactivity, even though the coexisting undifferentiated dysplastic or malignant cells showed diffuse *p53* immunoreactivity.

Besides *p53* mutations, several genomic abnormalities have been reported in the early stage of neoplastic changes and morphologically normal-appearing mucosa of UC. Abnormal DNA content (aneuploidy) has been found by flow cytometry in histologically non-dysplastic UC-

involved epithelium from colectomy specimens containing colorectal cancer.<sup>9, 10, 15)</sup> Chromosomal alterations may occur early in UC-related neoplastic progression and seem to precede the histologic development of dysplasia.<sup>29)</sup> Microsatellite instability (MIN) was found in 50% of UC patients whose colonic mucosa was negative for dysplasia.<sup>30)</sup> These genomic abnormalities during an early stage of the neoplastic process, as well as our observations, may occur due to chronic persistent and recurrent inflammation. Recurrent active mucosal inflammation results in epithelial cell damage and regeneration. Long-standing inflammation presumably causes free radical-mediated DNA damage, and increases the population of actively cycling cells in the colonic crypts so that the UC mucosa may be predisposed to a mutational event.<sup>31)</sup> Furthermore, an increase in the number of cell divisions causes telomerase shortening and may contribute to DNA aneuploidy.<sup>32)</sup> In sporadic colorectal neoplasms, such an increase in cell divisions would be caused at least partly by *K-ras* mutation, which is known to upregulate the mitogenic signal transduction pathway.<sup>33)</sup> The reported low occurrence of *K-ras* mutations in UC-associated neoplasms compared to sporadic colorectal neoplasms<sup>9, 34, 35)</sup> as well as our present results would indicate that chronic persistent and recurrent inflammation may substitute for the endogenous role of the *K-ras* mutation.

In summary, non-neoplastic mucosa with *p53* overexpression already shows *p53* genetic mutation, and the change may represent an initial, submorphologic form of UC-associated neoplasia. To detect such mucosa in biopsy specimens may be important for clinical cancer surveillance.

#### ACKNOWLEDGMENTS

The authors thank Kazuko Kojima, Naoyuki Yamaguchi and Ayako Sato for their excellent technical assistance and Makoto Yoshida for the preparation of the figures. This study was partly supported by the Research Committee for Inflammatory Bowel Disease, the Ministry of Health and Welfare of Japan.

(Received August 17, 2000/Revised November 13, 2000/  
Accepted November 18, 2000)

#### REFERENCES

- 1) Ekblom, A., Helmick, C., Zack, M. and Adami, H.-O. Ulcerative colitis and colorectal cancer. A population-based study. *N. Engl. J. Med.*, **323**, 1228–1233 (1990).
- 2) Riddell, R. H., Goldman, H., Ransohoff, D. F., Appleman, H. D., Fenoglio, C. M., Haggitt, R. C., Ahren, C., Correa, P., Hamilton, S. R., Morson, B. C., Sommers, S. C. and Yardley, J. H. Dysplasia in inflammatory bowel disease: standardized classification with provisional clinical applications. *Hum. Pathol.*, **14**, 931–968 (1983).
- 3) Lane, D. P. *p53*, guardian of the genome. *Nature*, **358**, 15–16 (1992).
- 4) Hollstein, M., Sidransky, D., Vogelstein, B. and Harris, C. C. *p53* mutations in human cancers. *Science*, **253**, 49–53 (1991).
- 5) Vogelstein, B., Fearon, E. R., Hamilton, S. R., Kern, S. E., Preisinger, A. C., Leppert, M., Nakamura, Y., White, R.,

- Smits, A. M. M. and Bos, J. L. Genetic alterations during colorectal-tumor development. *N. Engl. J. Med.*, **319**, 525–532 (1988).
- 6) Fearon, E. R. and Vogelstein, B. A genetic model for colorectal tumorigenesis. *Cell*, **61**, 759–767 (1990).
  - 7) Brentall, T. A., Chrispin, D. A., Rabinovitch, P. S., Haggitt, R. C., Rubin, C. E., Stevens, A. C. and Burmer, G. C. Mutations in the p53 gene; an early marker of neoplastic progression in ulcerative colitis. *Gastroenterology*, **107**, 369–378 (1994).
  - 8) Harpaz, N., Peck, A. L., Yin, J., Fiel, I., Hontanosas, M., Tong, T. R., Laurin, J. N., Abraham, J. M., Greenwald, B. D. and Meltzer, S. J. p53 protein expression in ulcerative colitis-associated colorectal dysplasia and carcinoma. *Hum. Pathol.*, **25**, 1069–1074 (1994).
  - 9) Holzmann, K., Klump, B., Borchard, F., Hsieh, C. J., Kuhn, A., Gaco, V., Gregor, M. and Porschen, R. Comparative analysis of histology, DNA content, p53 and Ki-ras mutations in colectomy specimens with long-standing ulcerative colitis. *Int. J. Cancer*, **30**, 1–6 (1998).
  - 10) Burmer, G. C., Rabinovitch, P. S., Haggitt, R. C., Crispin, D. A., Brentnall, T. A., Kolli, V. R., Stevens, A. C. and Rubin, C. E. Neoplastic progression in ulcerative colitis: histology, DNA content, and loss of a p53 allele. *Gastroenterology*, **103**, 1602–1610 (1992).
  - 11) Fogt, F., Vortmeyer, A. O., Goldman, H., Giordano, T. J., Jerino, M. J. and Zhuang, Z. Comparison of genetic alterations in colonic adenoma and ulcerative colitis-associated dysplasia and carcinoma. *Hum. Pathol.*, **29**, 131–136 (1998).
  - 12) Finlay, C. A., Hinds, P. W., Tan, T. H., Eliyahu, D., Oren, M. and Levine, A. J. Activating mutations for transformation by p53 produce a gene product that forms an hsc70-p53 complex with an altered half-life. *Mol. Cell. Biol.*, **8**, 531–539 (1988).
  - 13) Baas, I. O., Mulder, J. W. R., Offerhaus, G. J., Vogelstein, B. and Hamilton, S. R. An evaluation of six antibodies for immunohistochemistry of mutant p53 gene product in archival colorectal neoplasms. *J. Pathol.*, **172**, 5–12 (1994).
  - 14) Ajioka, Y., Watanabe, H. and Matsuda, K. Over-expression of p53 protein in neoplastic changes in ulcerative colitis: immunohistochemical study. *J. Gastroenterol.*, **30**, 33–35 (1995).
  - 15) Klump, B., Holzmann, K., Kuhn, A., Borchard, F., Sarbia, M., Gregor, M. and Porschen, R. Distribution of cell population with DNA aneuploidy and p53 protein expression in ulcerative colitis. *Eur. J. Gastroenterol. Hepatol.*, **9**, 789–794 (1997).
  - 16) Taylor, H. W., Boyle, M., Smith, S. C., Bustin, S. and Williams, N. S. Expression of p53 in colorectal cancer and dysplasia complicating ulcerative colitis. *Br. J. Surg.*, **80**, 442–444 (1993).
  - 17) Matsuda, K., Watanabe, H., Jass, J. R., Ajioka, Y., Kobayashi, M., Saito, H., Sasaki, M., Yasuda, K. and Kuwabara, A. Frequency of p53-positive cells in differing histological phases of ulcerative colitis. *Acta Med. Biol.*, **43**, 197–203 (1995).
  - 18) Krishna, M., Woda, B., Savas, L., Baker, S. and Banner, B. Expression of p53 antigen in inflamed and regenerated mucosa in ulcerative colitis and Crohn's disease. *Mod. Pathol.*, **8**, 654–657 (1995).
  - 19) Matsuda, K., Watanabe, H., Ajioka, Y., Kobayashi, M., Saito, H., Sasaki, M., Yasuda, K., Kuwabara, A., Nishikura, K. and Muto, T. Ulcerative colitis with overexpression of p53 preceding overt histological abnormalities of the epithelium. *J. Gastroenterol.*, **31**, 860–867 (1996).
  - 20) Kim, H. J. and Chang, S. K. p53 mutation in patients with ulcerative colitis in rectal biopsy. *Korean Intern. Med.*, **13**, 110–116 (1998).
  - 21) Watanabe, H., Ajioka, Y., Yamaguchi, M., Noda, Y., Honma, T. and Motoyama, T. New histological criteria of colorectal adenoma and carcinoma. *Stomach Intestine*, **24**, 253–259 (1989) (in Japanese).
  - 22) Schlemper, R. J., Itabashi, M., Kato, Y., Lewin, K. J., Riddell, R. H., Shimoda, T., Sipponen, P., Stolte, M. and Watanabe, H. Differences in the diagnostic criteria used by Japanese and Western pathologists to diagnose colorectal carcinoma. *Cancer*, **82**, 60–69 (1998).
  - 23) Yokoyama, N., Hitomi, J., Watanabe, H., Ajioka, Y., Pruyas, M., Serra, I., Shirai, Y. and Hatakeyama, K. Mutations of p53 in gallbladder carcinomas in high-incidence area of Japan and Chile. *Cancer Epidemiol. Biomarker Prev.*, **7**, 297–310 (1998).
  - 24) Ooshima, S., Shimizu, Y. and Takahama, M. Detection of c-Ki-ras gene mutation in paraffin sections of adenocarcinoma and atypical bronchioalveolar cell hyperplasia of human lung. *Virchows Arch.*, **424**, 129–134 (1994).
  - 25) Kuwabara, A., Watanabe, H., Ajioka, Y., Yasuda, K., Saito, H., Matsuda, K., Kijima, H. and Hatakeyama, K. Alteration of p53 clonality accompanying colorectal cancer progression. *Jpn. J. Cancer Res.*, **89**, 40–46 (1998).
  - 26) Ren, Z. P., Hedrum, A., Ponten, A., Nister, M., Ahmadian, A., Lundeberg, J., Uhlen, M. and Ponten, J. Human epidermal cancer and accompanying precursors have identical p53 mutations different from p53 mutations in adjacent areas of clonally expanded non-neoplastic keratinocytes. *Oncogene*, **12**, 765–773 (1996).
  - 27) Weinberg, W. C., Azzoli, C. G., Chapman, K., Levine, A. J. and Yuspa, S. H. p53-mediated transcriptional activity increases in differentiating epidermal keratinocytes in association with decreased p53 protein. *Oncogene*, **15**, 2271–2279 (1995).
  - 28) Matsuda, K., Watanabe, H., Ohta, T. and Ajioka, Y. Over-expressed p53 protein and cell-proliferative activity disappear or remarkably decrease in neoplastic CGA-positive endocrine and Paneth cells in cancer or dysplasia of ulcerative colitis. *Jpn. J. Gastroenterol.*, **92**, 1922–1928 (1995) (in Japanese with English abstract).
  - 29) Willenbacher, R. F., Zelman, S. J., Ferrell, L. D., Moore, D. H. and Waldman, F. M. Chromosomal alterations in ulcerative colitis-related neoplastic progression. *Gastroenterology*, **113**, 791–801 (1997).

- 30) Brentnall, T. A., Crispin, D. A., Bronner, M. P., Cherian, S. P., Hueffed, M., Rabinovitch, P. S., Rubin, C. E., Haggitt, R. C. and Boland, C. R. Microsatellite instability in non-neoplastic mucosa from patients with chronic ulcerative colitis. *Cancer Res.*, **56**, 1237–1240 (1996).
- 31) Noffsinger, A. E., Miller, M. A., Cusi, M. V. and Fenoglio-Preiser, C. M. The pattern of cell proliferation in neoplastic and nonneoplastic lesions of ulcerative colitis. *Cancer*, **78**, 2307–2312 (1996).
- 32) Kinouchi, Y., Hiwatashi, N., Chida, M., Nagashima, F., Takagi, S., Maekawa, H. and Toyota, T. Telomere shortening in the colonic mucosa of patients with ulcerative colitis. *J. Gastroenterol.*, **33**, 343–348 (1998).
- 33) Bos, J. L. The ras gene family and human carcinogenesis. *Mutat. Res.*, **195**, 255–271 (1988).
- 34) Burner, G. C., Levine, D. S., Kulander, B. G., Haggitt, R. C., Rubin, C. E. and Rabinovitch, P. S. c-Ki-ras mutations in chronic ulcerative colitis and sporadic colon carcinoma. *Gastroenterology*, **99**, 416–420 (1990).
- 35) Chaubert, P., Benhattar, J., Saraga, E. and Costa, J. K-ras mutations and p53 alterations in neoplastic and nonneoplastic lesions associated with longstanding ulcerative colitis. *Am. J. Pathol.*, **144**, 767–775 (1994).