

Clonal evolution in the transition from cutaneous disease to acute leukemia suggested by liquid biopsy in blastic plasmacytoid dendritic cell neoplasm

We have detected novel mutations in *TET2* and *RHOA* genes in a case of blastic plasmacytoid dendritic cell neoplasm (BPDCN). Analysis of peripheral blood mononuclear cell (PBMNC) samples at two timepoints allowed inference of subclonal variation associated with the evolution of acute leukemia from cutaneous disease.

Blastic plasmacytoid dendritic cell neoplasm is a rare disease, which is now regarded as myeloid-related.¹ There is a male preponderance (M:F 3:1), and patients typically present with cutaneous lesions, which might include nodules, patch-plaques or bruise-like areas. Bone marrow (60-90%) and lymph nodes (40-50%) might also be involved, while low-level peripheral blood involvement is a recognized feature of the disease.^{2,3} While some cases remain cutaneous, others develop acute myeloid leukemia, which is often metachronous.³ Prognosis is poor with a median overall survival of 12-14 months, although combination chemotherapy followed by allogeneic stem cell transplantation appears to offer the possibility of cure for some patients.⁴

Malignant cells in BPDCN show surface expression of CD4, CD43, CD56 and CD123.⁵ A Sanger sequencing study (n=13) described *TET2* gene mutations in 53% (7

of 13).⁶ Whole exome sequencing (n=3) revealed multiple protein-coding changes but no common mutation, which underlines the genetic diversity within the condition (Table 1).⁷ Targeted sequencing confirmed this conclusion; one study (n=25), in which 38 genes were sequenced, identified *TET2* as being the most frequently mutated gene (36%), followed by *ASXL1* (32%), *NRAS* (20%), *NPM1* (20%), *IKAROS* family (20%) and *ZEB2* (16%).⁷ A high frequency of *TET2* mutations was also suggested by a small targeted sequencing study (n=5) in which all cases showed changes to this gene.⁸ Others investigating BPDCN using a targeted sequencing panel for 50 genes (n=33) showed mutations in *NRAS* (27%), *ATM* (21%), *MET*, *KRAS*, *IDH2*, *KIT* (9% each), *APC* and *RB1* (6% each), as well as in *VHL*, *BRAF*, *MLH1*, *TP53* and *RET* (3% each).⁹

The patient was a 75-year old man who presented with a lower leg mass. Blood count showed mild lymphopenia ($0.7 \times 10^9/L$) but was otherwise normal, and the peripheral blood film was morphologically normal. Computed tomography (CT) scan showed no nodal or extra-nodal lesions. Initial immunohistochemical investigation of the leg mass biopsy suggested a diagnosis of peripheral T-cell lymphoma. The mass was treated with radiotherapy (8 Gy in a single fraction) and resolved, but the patient developed multiple bruise-like lesions within five weeks and a population of blasts, not previously

Table 1. List of all known *TET2* mutations in blastic plasmacytoid dendritic cell neoplasm derived from the literature⁶⁻⁸ and this report.

Protein_Change	Mutation_Type	Start_Position	End_Position	Reference_Allele	Variant_Allele	Reference
S217fs	Frame_Shift_Del	106155749	106155750	C	-	6
H667fs	Frame_Shift_Ins	106157099	106157100	-	T	6
Q1523*	Nonsense_Mutation	106196234	106196234	C	T	6
Y1618*	Nonsense_Mutation	106196521	106196521	C	G	6
L699M	Missense_Mutation	106157194	106157194	T	A	6
S393fs	Frame_Shift_Ins	106156273	106156274	-	T	6
Q1030fs*3	Frame_Shift_Del	106158187	106158188	C	-	6
A289fs*4	Frame_Shift_Del	106155964	106155965	G	-	6
L446fs*8	Frame_Shift_Del	106156435	106156436	TT	-	6
Q649*	Nonsense_Mutation	106157044	106157044	C	T	7
R1262Sfs*8	Frame_Shift_Ins	106164901	106164902	-	ACGCTCACCAAT	7
H1904R	Missense_Mutation	106197378	106197378	A	G	7
C1289F	Missense_Mutation	106180838	106180838	G	T	7
Y1560*	Frame_Shift_Ins	106196345	106196346	-	TA	7
I490Yfs*14	Frame_Shift_Ins	106156566	106156567	-	CT	7
S1583*	Nonsense_Mutation	106196415	106196415	C	A	7
N1103Rfs*24	Frame_Shift_Del	106158404	106158411	AATAATTTT	-	7
E1234*	Nonsense_Mutation	106164832	106164832	G	T	7
R1452*	Nonsense_Mutation	106193892	106193892	C	T	7
Q1524fs*54	Complex_frame_shift	106196239	106196239	G	CT	8
I1873T	Missense_Mutation	106197285	106197285	T	C	8
W564*	Nonsense_Mutation	106156790	106156790	G	A	8
C1016fs*16	Frame_Shift_Del	106158146	106158149	GTGA	-	8
Q1627*	Nonsense_Mutation	105275389	105275389	C	T	8
D1113fs*1	Frame_Shift_Del	106158436	106158445	GATACCTTA	-	8
Y1255fs*1	Frame_Shift_Ins	106164895	106164896	-	A	This report

detectable, were observed in the peripheral blood and bone marrow (Figure 1A and 1B). Immuno-phenotyping of bone marrow cells showed a CD4⁺CD7^{lo}CD56⁺CD123⁺ blast population, accounting for 90% of all leukocytes, compatible with a diagnosis of BPDCN in leukemic phase (Figure 1D). At this same time point, the CD4⁺CD7^{lo}CD56⁺CD123⁺ population accounted for 25% of all CD45⁺ leukocytes in peripheral blood (or approx.

46% of all mononuclear cells) (Figure 1E). Metaphase cytogenetics demonstrated a normal karyotype (46XY). Retrospective analysis of the leg mass demonstrated CD303 staining consistent with BPDCN, and a reanalysis of the bone marrow obtained at presentation with cutaneous disease showed a CD4⁺CD7^{lo}CD56⁺ population (2% of all CD45⁺ leukocytes) (Figure 1C). The patient was not fit for intensive chemotherapy but steroid treatment

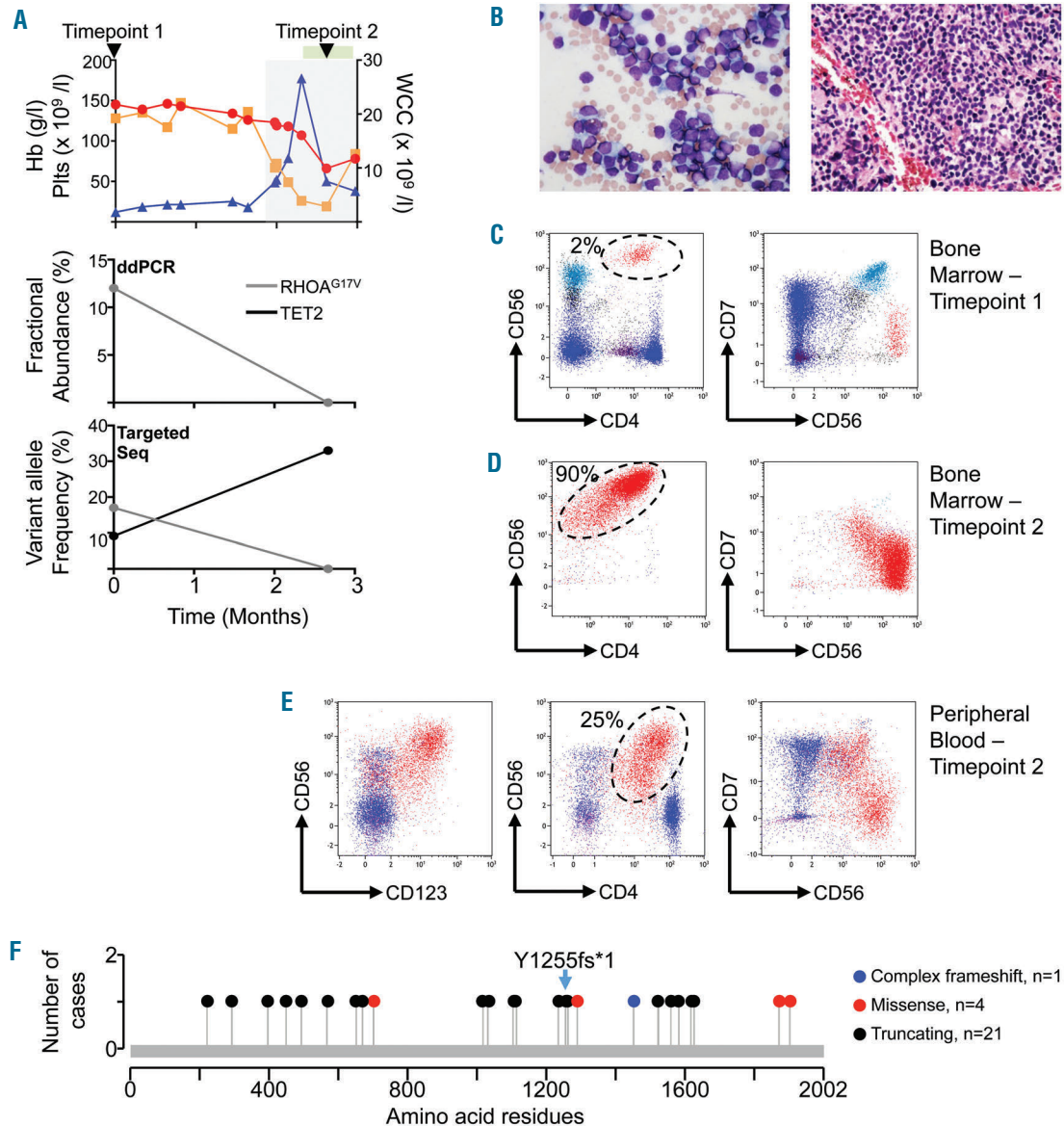


Figure 1. Characterization of hematologic course and burden of *RHOA* and *TET2* mutations. (A) Panels demonstrating levels of *RHOA*^{G17V} and *TET2* mutations. The upper panel shows the patient's hematologic course. Red line represents hemoglobin concentration (g/L), blue line the total white cell count ($\times 10^9/L$), and the orange line the platelet count ($\times 10^9/L$). Black arrowheads indicate the times at which blood samples were taken for the genetic analysis reported here (timepoint 1 when the patient presented with cutaneous disease and timepoint 2 after acute leukemia developed). The gray rectangle represents the leukemic phase, the top green rectangle shows the period in which steroids were administered. The middle panel shows fractional abundance of the *RHOA*^{G17V} mutation [number of mutant droplets/(number of mutant droplets + number of wild-type droplets) from the droplet digital PCR (ddPCR)]. Bottom panel shows the mutational frequency (number of reads showing the mutation/total number of reads) derived from targeted sequencing of 60 amplicons from 12 genes (*ARID1A*, *ATM*, *DNMT3A*, *FYN*, *IDH2*, *JAK2*, *PLCG1*, *RHOA*, *STAT3*, *STAT5B*, *TET2*, *TP53*). (B) Low power (x10) (right hand panel) and high power (x20) (left hand panel) of bone marrow after the development of acute leukemia. (C-E) Flow cytometry. Cells were stained with antibodies directed against CD4, CD7, CD56 or CD123 as indicated. The tumor population (red dots) are circled and the size of this population (as a percentage of all CD45⁺ leukocytes) is indicated. (C) Dot plots of bone marrow obtained at presentation with leg mass. Dot plots of (D) bone marrow and (E) peripheral blood on development of acute leukemia. (F) Position of known mutations in *TET2* protein in BPDCN^{9,10,11} and the insertion reported in this case (labeled Y1255fs*1 in the diagram). No change has been found in more than one case of BPDCN. Overall, 21 truncating mutations, 4 missense and 1 complex frameshift of *TET2* are now known in blastic plasmacytoid dendritic cell neoplasm.

produced minor symptomatic improvement before disease progression over the course of a few weeks and death.

There is current interest in the analysis of peripheral blood (liquid biopsy), either circulating tumor cells or cell-free (cf) DNA, in order to gain comprehensive knowledge of mutational burden and heterogeneity of solid cancers. As part of screening for hematologic malignancy, we carried out targeted sequencing of hot-spot mutations in 12 genes from cf DNA from the patient with BPDCN. At presentation with cutaneous disease, we detected a single base insertion in *TET2* exon 6 (nucleotide position 3764-3765, COSMIC ID: COSM211719_Y1255fs*1) causing a frameshift and truncation of the open reading frame (VAF 15%; 933/6087 reads) and a point mutation in *RHOA* producing a substitution of valine for glycine at residue 17 (COSMIC ID: COSM78415_G17V) (VAF of approx. 21%; 12543/60449 reads). The *TET2* insertion has not previously been reported in BPDCN (Table 1 and Figure 1E) but has been found in myeloid diseases (MDS, AML and CMML).^{10,11} *RHOA*^{G17V} has been found in the T-cell lymphoproliferative diseases, ATLL¹² and AITL,¹³ and also in 20% (3 of 15) of cases of NK/T cell lymphoma,¹⁴ but has also not previously been reported in BPDCN. Targeted sequencing of PBMNC DNA, an alternative source of material from blood, showed the *TET2* insertion with a VAF of 9.1% (620 of 6815 reads) and G17V at 17% (1814 of 10670). We validated the presence of *RHOA*^{G17V} by droplet digital PCR of PBMNC DNA, which showed a fractional abundance of 12%. We specifically sought the mutation responsible for *RHOA*^{G17V} in 5 further cases of BPDCN but none of these possessed the change.

Targeted sequencing of PBMNC DNA at the second time point, following development of acute leukemic disease, demonstrated changes to the VAFs such that while the *RHOA*^{G17V} mutation was undetectable, i.e. within the noise generated by the platform, the VAF for the *TET2* mutation had risen to 33% (1772 of 5403 reads). Droplet digital PCR confirmed the fall in *RHOA*^{G17V} fractional abundance corresponding with the development of acute leukemia (Figure 1A).

The substantial changes in the mutation frequency we detected in *TET2* and *RHOA*, in association with the disease entering a leukemic phase, are surprising (Figure 1A). The data suggest clonal evolution associating with the development of the acute leukemic phase but there are two major possibilities; firstly, the *RHOA*^{G17V} mutation and *TET2* insertion could represent two separate clones with loss of the *RHOA*^{G17V} clone or outgrowth of the *TET2* clone, possibly in association with secondary mutations, as the disease evolves, or secondly, both mutations could be present in the same cell but with loss or reversion of *RHOA*^{G17V} as the acute leukemia developed. Genetic changes leading to complete loss of *TET2* function have been reported in human lymphoma.¹⁵ Amplicons representing the entire *TET2* gene were represented in our targeted panel and no other mutations were detected. With a *TET2* insertion VAF of 33% and a tumor cell population of 46% of mononuclear cells it is likely to be heterozygous in many of the tumor cells, but it is also possible that the aberration is homozygous in a proportion or that there is loss of heterozygosity at the locus. *TET2* mutations associated with clonal hematopoiesis occur in the elderly but *TET2* aberrations are also frequent in BPDCN (Table 1), and the specific *TET2* insertion described here has not previously been described as a somatic mutation associating with clonal hematopoiesis and is, therefore, likely to be tumor associated. A further implication of

this study is that, although *RHOA*^{G17V} is suspected to be a driver mutation in AITL, this might not be the case for BPDCN, because the acute leukemic phase was associated with apparent loss of the *RHOA*^{G17V} mutation.

The acute leukemic phase followed radiotherapy, which could have had a role in the transformation, although there is no evidence to suggest a causal relationship. The patient had started steroid treatment at the time the second sample was obtained for genetic analysis, but we consider it unlikely that this treatment caused clonal selection. As described above, it seems more likely that we have observed subclonal variation with the development of acute leukemia.

In this report, we have extended the spectrum of mutations associating with BPDCN through analysis of cfDNA and PBMNC DNA, suggesting that liquid biopsy may contribute to diagnosis or help to guide future therapy in this rare hematologic malignancy, and secondly, we suggest an association between clonal evolution and development of the leukemic phase of the disease. We have not been able to directly address the question of whether a complex pattern of clonality existed at presentation or whether there was a single clone bearing both *TET2* insertion and *RHOA*^{G17V} mutation and we, therefore, recognize that to answer this question further work (probably involving cell sorting and single cell sequencing) is needed. The results do, however, demonstrate the potential usefulness of serial liquid biopsy allied to targeted sequencing for mutation detection in BPDCN.

Eleni Ladikou,^{1,2} Barbara Ottolini,^{1,2} Nadia Nawaz,^{1,2} Rebecca L. Allchin,^{1,2} Daniel Payne,³ Hebah Ali,⁴ Teresa Marafioti,⁴ Jacqui Shaw,⁴ Matthew J. Ahearne^{1,2} and Simon D. Wagner^{1,2}

¹Leicester Cancer Research Centre and ²Ernest and Helen Scott Haematology Research Institute, University of Leicester; ³Department of Haematology, Leicester Royal Infirmary and ⁴Department of Cellular Pathology, University College London Hospitals, UK

Funding: the work was supported by grants from the Leicester Haematology Research Fund.

Correspondence: sw227@le.ac.uk/mja40@le.ac.uk
doi:10.3324/haematol.2017.171876

Information on authorship, contributions, and financial & other disclosures was provided by the authors and is available with the online version of this article at www.haematologica.org.

References

- Vardiman JW, Thiele J, Arber DA, et al. The 2008 revision of the World Health Organization (WHO) classification of myeloid neoplasms and acute leukemia: rationale and important changes. *Blood*. 2009;114(5):937-951.
- Herling M, Jones D. CD4+/CD56+ hematodermic tumor: the features of an evolving entity and its relationship to dendritic cells. *Am J Clin Pathol*. 2007;127(5):687-700.
- Feuillard J, Jacob MC, Valensi F, et al. Clinical and biologic features of CD4(+)/CD56(+) malignancies. *Blood*. 2002;99(5):1556-1563.
- Reimer P, Rüdiger T, Kraemer D, et al. What is CD4+CD56+ malignancy and how should it be treated? *Bone Marrow Transplant*. 2003;32(7):637-646.
- Marafioti T, Paterson JC, Ballabio E, et al. Novel markers of normal and neoplastic human plasmacytoid dendritic cells. *Blood*. 2008;111(7):3778-3792.
- Jardin F, Ruminy P, Parmentier F, et al. *TET2* and *TP53* mutations are frequently observed in blastic plasmacytoid dendritic cell neoplasm. *Br J Haematol*. 2011;153(3):413-416.
- Menezes J, Acquadro F, Wiseman M, et al. Exome sequencing reveals novel and recurrent mutations with clinical impact in blastic plasmacytoid dendritic cell neoplasm. *Leukemia*. 2014;28(4):823-829.
- Alayed K, Patel KP, Konoplev S, et al. *TET2* mutations, myelodysplastic features, and a distinct immunoprofile characterize blastic

- plasmacytoid dendritic cell neoplasm in the bone marrow. *Am J Hematol.* 2013;88(12):1055-1061.
9. Stenzinger A, Endris V, Pfarr N, et al. Targeted ultra-deep sequencing reveals recurrent and mutually exclusive mutations of cancer genes in blastic plasmacytoid dendritic cell neoplasm. *Oncotarget.* 2014;5(15):6404-6413.
 10. Weissmann S, Alpermann T, Grossmann V, et al. Landscape of TET2 mutations in acute myeloid leukemia. *Leukemia.* 2012;26(5):934-942.
 11. Itzykson R, Kosmider O, Renneville A, et al. Clonal architecture of chronic myelomonocytic leukemias. *Blood.* 2013;121(12):2186-2198.
 12. Nagata Y, Kontani K, Enami T, et al. Variegated RHOA mutations in adult T-cell leukemia/lymphoma. *Blood.* 2016;127(5):596-604.
 13. Palomero T, Couronné L, Khiabani H, et al. Recurrent mutations in epigenetic regulators, RHOA and FYN kinase in peripheral T cell lymphomas. *Nat Genet.* 2014;46(2):166-170.
 14. Yoo HY, Sung MK, Lee SH, et al. A recurrent inactivating mutation in RHOA GTPase in angioimmunoblastic T-cell lymphoma. *Nat Genet.* 2014;46(4):371-375.
 15. Quivoron C, Couronné L, Valle Della V, et al. TET2 inactivation results in pleiotropic hematopoietic abnormalities in mouse and is a recurrent event during human lymphomagenesis. *Cancer Cell.* 2011;20(1):25-38.