

CASE REPORT

Fatal case of amoebic encephalitis masquerading as herpes

Rikesh Baral¹ and Binit Vaidya^{2,*}¹Department of Medicine, National Center for Rheumatic Diseases, Medicine, Kathmandu, Nepal, and²Department of Medicine, National Center for Rheumatic Diseases, Medicine, Pashupati Sadak, Kathmandu-9, Kathmandu, Nepal

*Correspondence address. National Center for Rheumatic Diseases, Medicine, Pashupati Sadak, Kathmandu-9, Kathmandu, Nepal. Tel: +97714464288; E-mail: drbinitvaidya@yahoo.com

Abstract

Primary amoebic meningoencephalitis (PAM) is a rare, fulminating, hemorrhagic infection of the brain caused by *Naegleria fowleri*, a thermophilic, free-living amoeba. A 74-year male presented with sudden severe global headache and fever with features of anomic aphasia. Magnetic resonance imaging (MRI) suggested herpes encephalitis and acyclovir (IV) was started but the patient developed altered sensorium, agitation and progressive weakness of lower limbs with gradual truncal weakness. Repeat MRI showed increase in lesion size and edema with confluent blood areas. Dexamethasone showed significant improvement. Ten days after completion of acyclovir, there was recurrence of altered sensorium with seizures. Repeat MRI showed new lesions appearing. Excisional biopsy of brain confirmed *N. fowleri*. Amphotericin B and miltefosin was started but patient succumbed to his illness after 10 days. This is a first case of PAM in Nepal, involving elderly immune-competent male without environmental exposure to freshwater, mimicking as herpes encephalitis.

INTRODUCTION

Amoebic encephalitis is a rare disease that can be rapidly fatal if not diagnosed early. Around 300 cases are reported world wide [1]. The main organisms responsible are free-living amoeba of three species: *Acanthamoeba*, *Balamuthia* and *Naegleria*. The first two are known to present as fatal granulomatous amoebic encephalitis (GAE) whereas *Naegleria* mainly presents as primary amoebic meningoencephalitis (PAM) [2]. *Naegleria fowleri* is naturally found in warm freshwater environments such as lakes, hot springs, sewage, poorly maintained swimming pools, hydrotherapy and remedial pools and soil [3]. The diagnosis is usually missed because of rarity of disease, low suspicion and lack of diagnostic tests [3]. Many cases reported are diagnosed on autopsy and even when diagnosed ante mortem,

the reported survival is very low [4] with only few survivors worldwide. We report first case of amoebic encephalitis presenting as herpes encephalitis in a 74-year-old immunocompetent individual with no risk factors from Nepal.

CASE REPORT

A 74-year-old gentleman, otherwise healthy, presented with 4 days history of low grade fever followed by 2 days history of severe global headache. He had features of anomic aphasia but there were no symptoms of vomiting, seizure or other neurological deficit at presentation. Additional medical history was positive for hypertension only. He was not on any immunosuppressant; there was no history of swimming in lifetime and no recent history of travel.

Received: December 7, 2017. Revised: December 29, 2017. Accepted: January 23, 2018

© The Author(s) 2018. Published by Oxford University Press.

This is an Open Access article distributed under the terms of the Creative Commons Attribution Non-Commercial License (<http://creativecommons.org/licenses/by-nc/4.0/>), which permits non-commercial re-use, distribution, and reproduction in any medium, provided the original work is properly cited. For commercial re-use, please contact journals.permissions@oup.com

An empirical treatment with intravenous ceftriaxone and dexamethasone was started. A magnetic resonance imaging (MRI) brain was obtained on 4th day of presentation, which showed edema and temporal lobe lesion (T1 hypo and T2 hyper intense) with few areas of micro-hemorrhages suggestive of cerebritis (likely Herpes) (Fig. 1). Intravenous acyclovir was started at 10 mg/kg three times a day on the same day along with phenytoin. Cerebrospinal fluid (CSF) findings are summarized in Table 1. Dexamethasone was stopped with provisional diagnosis of herpes encephalitis and rest continued. Patient developed altered sensorium and agitation on the same day. After 5 days, he started developing gradually progressive weakness of bilateral lower limbs with gradual truncal weakness. A repeat MRI was done which showed increase in size of lesion with confluent blood areas and increase in edema (Fig. 2). Dexamethasone was restarted for weakness and showed rapid improvement (from 1 to 4-power in lower limbs) in weakness and hence was continued. However, his sensorium continued to fluctuate over next 1 week and a repeat CSF was done. In view of non-improvement, anti-tubercular treatment and

meropenem was started empirically. He gradually improved over next 1 week and was discharged after completion of 14 days of meropenem and 21 days of acyclovir (Table 2).

Next 10 days, he was doing well except for episodes of accelerated hypertension and headache which was managed with anti-hypertensive. There was no motor deficit except for anomic aphasia. After 10 days, he developed vomiting with slight hematemesis and was rushed back to hospital. Hematemesis did not recur but he again started to develop agitation and altered sensorium. A repeat MRI again showed an increase in lesion with new lesions appearing in right high-parietal area (Fig. 3). Patient's sensorium deteriorated to E1M5V1 and he was electively intubated and an excisional brain biopsy was done. Histopathology revealed areas of necrosis with some evidence of thrombosed arteries but without any vessel wall involvement or any mitotic pathology. Finally, few slides showed trophozoite from of parasite engulfing red blood cells and it was later confirmed as *N. Fowleri* by three independent pathologists (Figs 4 and 5). A combination of amphotericin B lipid complex, flucytosine, voriconazole, azithromycin,

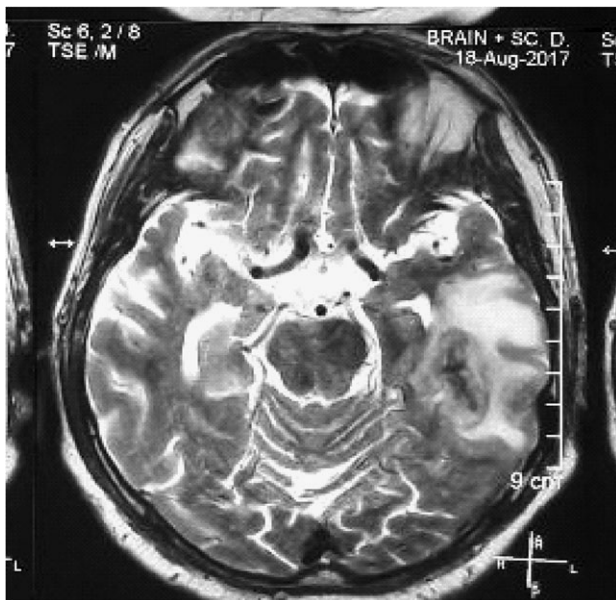


Figure 1: MRI at presentation: T2 hyper intense lesion at left temporal lobe with minimal enhancement and small bleeding areas consistent with hemorrhagic encephalitis.

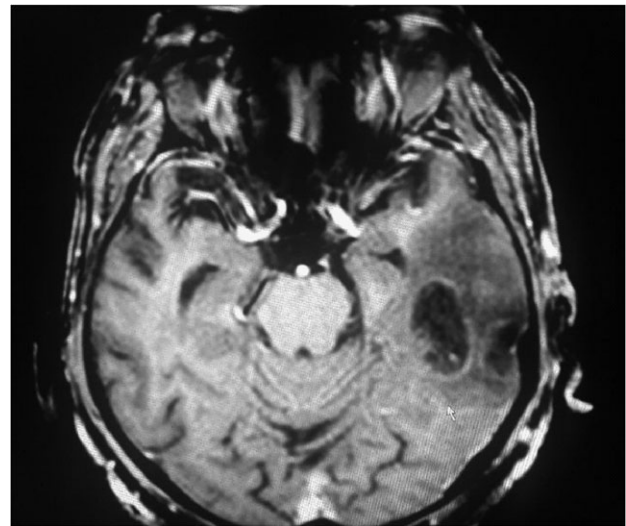


Figure 2: MRI at 5 days: T1 hypointense lesion increased upto the posterior limb of internal capsule with confluence and enlargement of hemorrhagic areas indicating interval increase in lesion.

Table 1: CSF findings.

Parameters	First 14.08.2017	Second 21.08.2017
Total count	4	95
Differential	85% Lymphocytes	86% Lymphocytes
Protein	80 mg/dl	100 mg/dl
Sugar	120 mg/dl	132 mg/dl
Gm stain	Negative	Negative
AFB stain	Negative	Negative
ADA	2	4
TB PCR	Negative	Negative
HSV PCR	Negative	Negative
KOH		Negative
ACE level		Negative

Comparative table of CSF findings at admission and after 1 week of treatment.

Table 2: Other investigations.

Investigation	Reports	Remarks
ANA by (IFA)	Negative	
dsDNA (ELISA)	Negative	
Anti-Smith Antibody (ELISA)	Negative	
Toxoplasma serology	Negative	Both IgG/IgM
HIV serology	Negative	Both I and II (repeated)
CD4 count/ percentage	320/45%	Normal
Brain tissue TB PCR	Negative	
Paragonimia ELISA	Negative	
Brain tissue for toxoplasma antibody stain	Negative	
Amoebic serology (Entamoeba)	Positive	Common in our population
HSV I serology IgG	Positive	Common in our population
HSV I serology IgM	Negative	

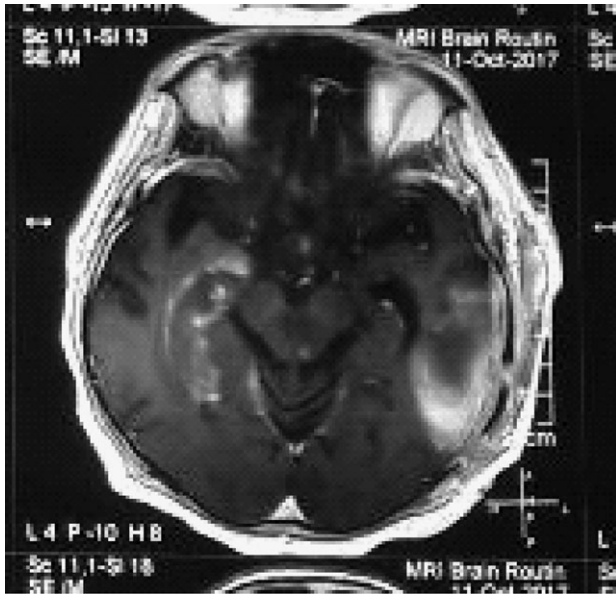


Figure 3: MRI at 6weeks: persistent lesion in left temporal lobe with appearance of new lesion in right hippocampal and mid brain area.

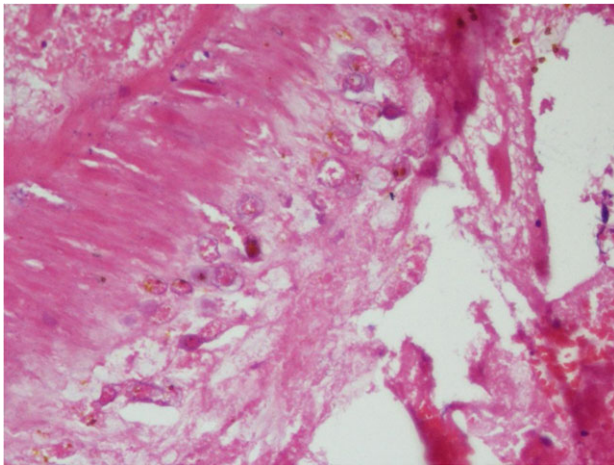


Figure 4: H&E stain of section showing trophozoites of *N.fowleri* with engulfed erythrocytes.

rifampicin and miltefosine were started. However, by the time diagnosis was established (7 weeks from disease onset), the patient had dilated and unresponsive pupils. After 10 days of treatment, he started having raised bilirubin, deranged renal function and oliguria. He developed metabolic acidosis and finally succumbed to his illness.

DISCUSSION

Naegleria is a free water living, thermophilic amoeba that can be pathogenic to immunocompetent individuals. Over 30 species have been isolated from soil and water but only *N. fowleri* has been associated with human disease and the usual port of entry is via olfactory route to the brain through the cribriform plate [2]. PAM is the usual presentation and has been reported to be highly virulent with death within 1 week of onset [4]. Out of 143 PAM infections from 1962 through 2016, there were only four survivors in the USA with 97% mortality [5].

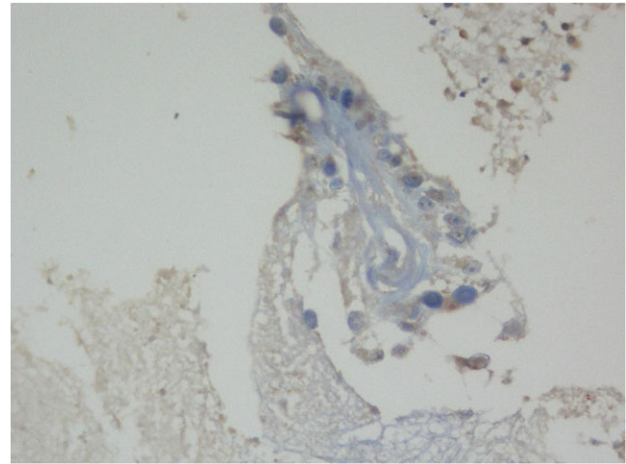


Figure 5: Toulidine blue stain showing trophozoite with multiple nuclei.

There are no early characteristic clinical or radiological findings that can help in diagnosis of amoebic encephalitis and the mortality is very high unless aggressive treatment is started early in the course of disease. Moreover, our case presented with many atypical features: most of the reported cases affected children and young adults [6] but our patient was an elderly male; there was no history of any exposure to free water; the disease followed a relatively indolent and waxing-waning course and the meningeal signs were absent. Detection of amoeba on wet mount preparation of CSF is considered important aid to the diagnosis [4, 7]. However, though the CSF was done twice, amoeba was not detected due to lack of expertise and low index of clinical suspicion. None of the features typically described in cases of PAM were present in our patient in early phase of disease. The presence of low fever, headache, isolated hemorrhagic temporal lobe lesion and lymphocytic pleocytosis all suggested herpes encephalitis. The waxing and waning course also mimicked natural history of herpes encephalitis adding to the diagnostic confusion.

There is no proven effective treatment protocol for amoebic encephalitis. Amphotericin B is the agent with best effectiveness against *Naegleria* sp [8]. Though a combination of treatment including amphotericin B and miltefosine was initiated after confirmation of treatment, it was already 7 weeks after diagnosis and the results were unrewarding.

Making diagnostic tests more accessible and epidemiological screening for the presence of pathogenic organism in the water source are important to estimate the risks for the general population. High index of clinical suspicion is very important, especially if the initial diagnostic tests are negative. The disease can even have an indolent and waxing-waning course without definite signs of meningitis.

CONCLUSION

Amoebic encephalitis is a life-threatening condition with rapid course and poor outcome. It should be suspected in early phases of encephalitis if diagnostic tests for other etiologies are negative.

ACKNOWLEDGEMENTS

We are thankful to the clinicians and nurses who managed this patient. The relative to the deceased is also acknowledged for consenting to have this case published.

CONFLICT OF INTEREST STATEMENT

None declared.

ETHICAL APPROVAL

Ethical approval was given by Ethical Review Committee of National Center for Rheumatic Disease via letter number CR-07/17.

FUNDING

No funding was received to publish this case report.

REFERENCES

1. De Jonckheere JF. What do we know by now about the genus *Naegleria*? *Exp Parasitol* 2014;**145**:S2–9.
2. Marciano-Cabral F, Cabral G. The immune response to *Naegleria fowleri* amoebae and pathogenesis of infection. *FEMS Immunol Med Microbiol* 2007;**51**:243–59.
3. Visvesvara GS. Free-living amoebae as opportunistic agents of human disease. *J Neuroparasitol* 2010;**1**:6–8.
4. Visvesvara GS, Moura H, Schuster FL. Pathogenic and opportunistic free-living amoebae: *Acanthamoeba* spp., *Balamuthia mandrillaris*, *Naegleria fowleri* and *Sappinia diploidea*. *FEMS Immunol Med Microbiol* 2007;**50**:1–26.
5. CDC: Parasites—*Naegleria fowleri*—Primary Amebic Meningoencephalitis (PAM)—Amebic Encephalitis. Available from: <https://www.cdc.gov/parasites/naegleria/index.html> (7 December 2017, date last accessed).
6. Yoder JS, Eddy BA, Visvesvara GS, Capewell L, Beach MJ. The epidemiology of primary amoebic meningoencephalitis in the USA, 1962–2008. *Epidemiol Infect* 2010;**138**:968–75.
7. Martinez AJ *Free-Living Ameba's: Natural History, Prevention, Diagnosis, Pathology and Treatment of Disease*. Boca Raton, FL: CRC Press Inc., 1985.
8. Seidel JS, Harmatz P, Visvesvara GS, Cohen A, Edwards J, Turner J. Successful treatment of primary amoebic meningoencephalitis. *New Engl J Med* 1982;**306**:346–8.