

Cervical lift-up laminoplasty with titanium basket plates after resection of intradural tumor

ABSTRACT

Background: Performing cervical laminoplasty after wide laminectomy may be technically demanding. The unique technique of cervical lift-up laminoplasty using titanium basket plates was applied for the reconstruction of cervical laminae after wide laminectomy for the resection of intradural tumors.

Materials and Methods: This technical study included 14 cases that could be followed periodically for at least 6 months after surgery. Participants were 8 male and 6 female, with a mean age of 41.6 years (range, 13–71 years). Tumors were intramedullary in 11 cases and extramedullary in 3 cases. After resection of intradural tumors, custom-designed titanium baskets were fitted to expand the spinal canal. Combining baskets of different sizes are also possible for each side at one level. A mixture of hydroxyapatite granules and collagen was packed into the basket. The reconstructed posterior laminae were secured using titanium mini plates. The fascia of the paravertebral muscles was sutured to the spino-ligamentous complex to further stabilize the posterior elements of the cervical spine.

Results: No wounds or implant problems requiring revision surgery were recognized. Imaging analysis demonstrated no significant change in C2–C7 angle cervical range of motion between before and after surgery, suggesting sequential spinal stability at the base of the laminae.

Conclusions: This technical note suggests that cervical lift-up laminoplasty with titanium basket plates appears practical and useful as a procedure to reconstruct cervical laminae after wide laminectomy.

Keywords: Cervical spine, laminoplasty, lift-up, spinal intramedullary tumor, titanium basket

INTRODUCTION

Cervical laminoplasty is commonly performed for posterior cervical decompression. A variety of procedures have been developed to obtain a reconstruction of posterior cervical elements.^[1-11] Cervical laminoplasty appears effective on the maintenance of spinal curvature and range of motion (ROM) even long after surgery although the efficacy of this method has remained contentious.^[12-14] However, performing cervical laminoplasty after wide laminectomy for intradural procedures such as resection of intradural tumors may be technically demanding.

We have developed a unique method of cervical laminoplasty using a hydroxyapatite (HA) block, in what we term “lift-up laminoplasty,” and have reported the advantages in the previous publications.^[3,6,15] Here, we modified our technique

of cervical lift-up laminoplasty to use titanium basket plates and created an integrated laminoplasty of the cervical spine. The mixture of HA granules and collagen was packed into the basket to be integrated with the lamina edge. The procedure is not particularly complicated and appears easier. We applied this technique for the reconstruction of

KEISUKE SHIROSAKA, KENTARO NAITO, TORU YAMAGATA¹, MASAKI YOSHIMURA², KENJI OHATA, TOSHIHIRO TAKAMI

Department of Neurosurgery, Osaka City University Graduate School of Medicine, ¹Department of Neurosurgery, Osaka City General Hospital, ²Department of Neurosurgery, Yao Tokushukai General Hospital, Osaka, Japan

Address for correspondence: Dr. Toshihiro Takami, Department of Neurosurgery, Osaka City University Graduate School of Medicine, 1-4-3 Asahi-machi, Abeno-ku, Osaka 545-8585, Japan.
E-mail: ttakami@med.osaka-cu.ac.jp

This is an open access journal, and articles are distributed under the terms of the Creative Commons Attribution-NonCommercial-ShareAlike 4.0 License, which allows others to remix, tweak, and build upon the work non-commercially, as long as appropriate credit is given and the new creations are licensed under the identical terms.

For reprints contact: reprints@medknow.com

How to cite this article: Shirotsuka K, Naito K, Yamagata T, Yoshimura M, Ohata K, Takami T. Cervical lift-up laminoplasty with titanium basket plates after resection of intradural tumor. J Craniovert Jun Spine 2018;9:26-31.

Access this article online	
Website: www.jcvjs.com	Quick Response Code 
DOI: 10.4103/jcvjs.JCVJS_127_17	

cervical laminae after the resection of intradural tumors and examined the postoperative imaging results for cervical curvature and ROM.

MATERIALS AND METHODS

Patient population

Cervical lift-up laminoplasty with titanium basket plates was introduced in our institute in September 2014 and was applied for the reconstruction of cervical laminae after the resection of intradural tumors. This study of cervical lift-up laminoplasty with titanium basket plates included 14 cases that could be followed periodically for at least 6 months after surgery. Participants were 8 male and 6 female, with a mean age of 41.6 years (range, 13–71 years). Tumors were intramedullary in 11 cases and extramedullary in three cases. Recurrent cases were excluded from this study. Patient characteristics are summarized in Table 1.

Surgical technique

The surgical technique for lift-up laminoplasty of the cervical spine has been described previously.^[3,6,15] Briefly, after standard exposure of the posterior cervical spine with preservation of the spino-ligamentous complex, osteotomy of the laminae was carried out by transecting the laminae using a high-speed drill. The yellow ligaments were sharply dissected at the upper and lower level of the laminotomy, and the laminae removed *en bloc*. Additional resection of the lamina edge or posterior foraminotomy was performed in selected cases. After resection of intradural tumors, custom-designed titanium baskets (AMMTEC, Tokyo, Japan) were fitted to expand the spinal canal. The minimum size of a basket is 8 mm long. The width of a basket is 3 mm for the C3–C7 subaxial spine or 4 mm for C2. Combining

baskets of different sizes are also possible for each side at one level. A mixture of HA granules and collagen (Refit; HOYA Technosurgical Corporation, Tokyo, Japan) was packed into the basket. The reconstructed posterior laminae were secured using titanium mini plates [Figure 1]. The fascia of the paravertebral muscles was sutured to the spino-ligamentous complex to further stabilize the posterior elements of the cervical spine. A soft collar was applied several weeks after surgery. No other external orthosis was applied after surgery.

Image analysis

All patients underwent comprehensive evaluations before and after surgery and completed a minimum 6 months of follow-up after surgery. Radiological evaluations included the C2–C7 angle of spinal curvature and ROM of the cervical spine on plain radiography and osseous integrity

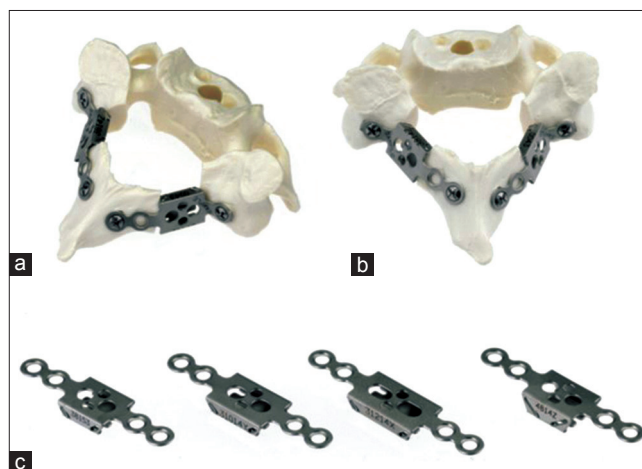


Figure 1: Photograph showing the cervical lift-up laminoplasty with titanium basket plates using a plastic model of the spine (a and b). Basket plates are titanium-6 aluminum-4 vanadium extra-low interstitial alloy consisting of a box-shaped cage available in different sizes (c)

Table 1: Patient characteristics

Patient	Age	Sex	Follow-up (months)	Tumor		
				Spine level	Location	Pathology
1	36	Female	8	C2-C4	Intramedullary	Anaplastic ependymoma
2	70	Male	27	C4-C5	Intramedullary	Hemangioblastoma
3	23	Female	24	C6-C7	Intramedullary	Germ cell tumor
4	30	Male	23	C4-C6	Intramedullary	Ependymoma
5	71	Male	7	C4-C6	Extramedullary	Hemangioblastoma
6	37	Male	22	C2-C4	Intramedullary	Ependymoma
7	52	Male	22	C3-C4	Intramedullary	Cavernoma
8	33	Female	22	C2	Intramedullary	Hemangioblastoma
9	38	Male	21	C4-C5	Extramedullary	Schwannoma
10	44	Male	20	C4-C5	Intramedullary	Hemangioblastoma
11	13	Female	13	C2-C5	Intramedullary	Cavernoma
12	70	Female	12	C2	Extramedullary	Meningioma
13	32	Male	12	C2-C4	Intramedullary	Subependymoma
14	33	Female	8	C4-Th3	Intramedullary	Ependymoma
Average	41.6		17.2			

on computed tomography.^[16,17] All radiological evaluations were performed using a computerized medical records system (EGMAIN-EX).

Statistical analysis

All data are expressed as means \pm standard deviation. JMP version 9.0 Software (SAS Institute, Cary, NC, USA) was used for all statistical analyses in the present study. The paired *t*-test was used to assess differences in C2–C7 angle of spinal curvature and ROM of the cervical spine between before and after surgery.

Statement of ethics

We certify that all applicable institutional and governmental regulations concerning the ethical use of clinical data were followed in the present study. This comprehensive analysis of surgery-related outcomes was approved by the Institutional Ethics Committee. Informed consent for the use of titanium basket plates was obtained from the patient before surgery.

RESULTS

In the 14 patients, a total of 32 cervical laminae were reconstructed after resection of intradural tumors. Mean operation time including resection of the tumor was 473 min (range, 250–637 min). Mean estimated blood loss including the resection of the tumor was 261 ml (range, 40–700 ml). No wound or implant problems requiring revision surgery were encountered.

Cervical spine curvature before surgery was lordotic in 12 patients, straight in 0, S-shaped in 1, and kyphotic in 1. Postoperative image analysis demonstrated that cervical spine curvature after surgery remained lordotic in

12 patients, straight in 0, S-shaped in 0, and became kyphotic in 2. Average C2–C7 angle did not change significantly after surgery. Average neck ROM between flexion and extension was 40.9° before surgery and remained 46.8° after surgery [Figure 2]. The data from image analysis are summarized in Table 2. Image analysis using computed tomography suggested sequential spinal stability at the base of the laminae [Figure 3].

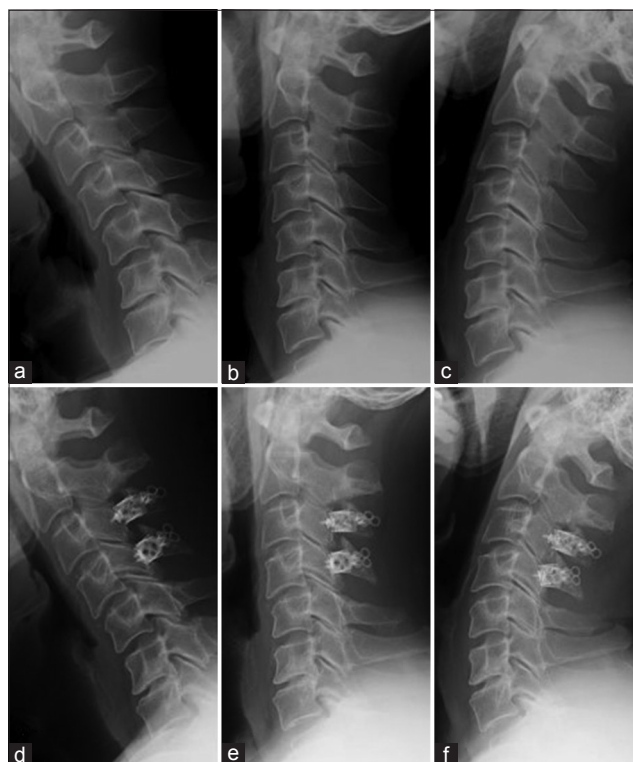


Figure 2: Lateral radiographs of the cervical spine (Patient 7) showing maintenance of C2–C7 angle and range of neck motion from before surgery (a-c) to after surgery (d-f)

Table 2: Summary of image analysis

Patient	Number of laminoplasty	Cervical curvature		C2-C7 angle	
		Preoperative	Postoperative	Preoperative	Postoperative
1	3	Lordotic	Lordotic	8	10
2	2	Lordotic	Lordotic	33	29
3	2	S-shaped	Lordotic	8	21
4	3	Lordotic	Lordotic	14	9
5	3	Lordotic	Lordotic	18	17
6	1	Lordotic	Lordotic	12	5
7	2	Lordotic	Lordotic	22	12
8	1	Lordotic	Lordotic	12	18
9	2	Lordotic	Lordotic	23	8
10	2	Lordotic	Lordotic	8	20
11	4	Lordotic	Kyphotic	6	-4
12	1	Lordotic	Lordotic	40	45
13	3	Lordotic	Lordotic	23	10
14	3	Kyphotic	Kyphotic	-4	0
Average	2.3			15.9	14.3

Illustrative case 1

A 36-year-old woman was admitted with acute deterioration of a left-sided motor-weakness. Functional assessment before surgery suggested Grade 5 in the modified McCormick functional schema.^[18,19] Magnetic resonance imaging (MRI) before surgery demonstrated the existence of intramedullary tumor at the C1–C4 level [Figure 4a]. Surgical verification revealed the anaplastic nature of the tumor, and partial resection was accomplished without trouble. Pathological examination of the tumor led to a diagnosis of intramedullary anaplastic ependymoma. Cervical lift-up laminoplasty with titanium basket plates for C2–C4 was completed [Figure 4b and d]. The patient underwent postoperative treatment with local radiation and chemotherapy [Figure 4c]. The postoperative course was uneventful, and functional assessment early after surgery suggested Grade 4 of the modified McCormick functional schema. During follow-up, image analysis demonstrated the maintenance of cervical curvature.

Illustrative case 2

A 23-year-old woman was admitted with acute deterioration of tetraparesis. Functional assessment before surgery suggested Grade 5 of the modified McCormick functional schema. MRI before surgery demonstrated an intramedullary tumor at the C6–C7 level with extensive intramedullary signal change [Figure 5a]. Surgical verification revealed the anaplastic nature of the tumor, and partial resection of the tumor was accomplished without trouble. Pathological examination led to the diagnosis of intramedullary germ cell tumor. Cervical lift-up laminoplasty with titanium basket plates of C6–C7 was completed [Figure 5b and d]. The patient underwent postoperative radiotherapy of the whole brain and spine and chemotherapy [Figure 5c]. The postoperative

course was uneventful, and functional assessment early after surgery suggested Grade 4 of the modified McCormick functional schema. During follow-up, image analysis demonstrated the improvement of the cervical curvature.

DISCUSSION

Although a variety of technical modifications are available for cervical laminoplasty, such as unilateral open-door, bilateral open-door, HA spacer or titanium plate, and screws,^[1-11] these procedures may not be entirely suitable for the reconstruction of cervical laminae after resection of an intradural tumor. Wide laminectomy is helpful for surgeons to secure a sufficient working space for intradural procedure but may result in spinal deformity, instability, or aggravation of neck ROM.^[20-23] Our previous reports described our lift-up technique of cervical laminoplasty using HA block.^[3,6,15] Resected laminae were completely secured in the original position using HA block and titanium plates after wide laminectomy. The advantages of cervical lift-up laminoplasty are the provision of a wide space for intradural procedures and reconstruction of posterior osseous elements of the cervical spine. The degree of lift-up can be modified by changing the size of the HA block. Furthermore, expansive duraplasty was easily secured with the reconstructed laminae.^[15] On the other hand, the procedure is not necessarily simple or easy, and the structure may be complex.

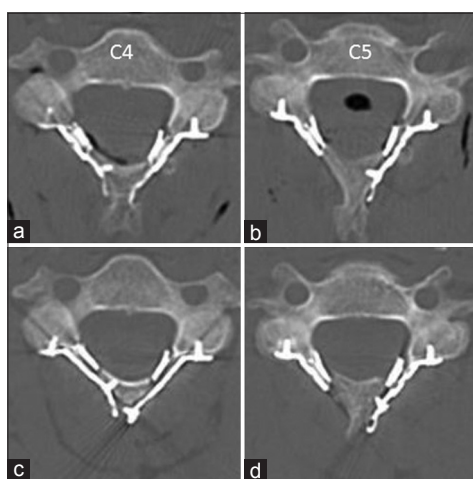


Figure 3: Image analysis using computed tomography (Patient 10) suggesting sequential osseous stability at the base of the laminae. (a and b): Early after surgery; (c and d): 6 months after surgery

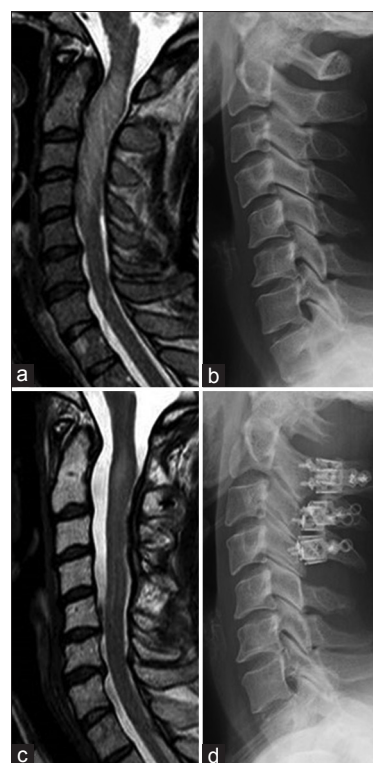


Figure 4: Illustrative case (Patient 1). (a and b): Before surgery; (c and d): After surgery and radiation

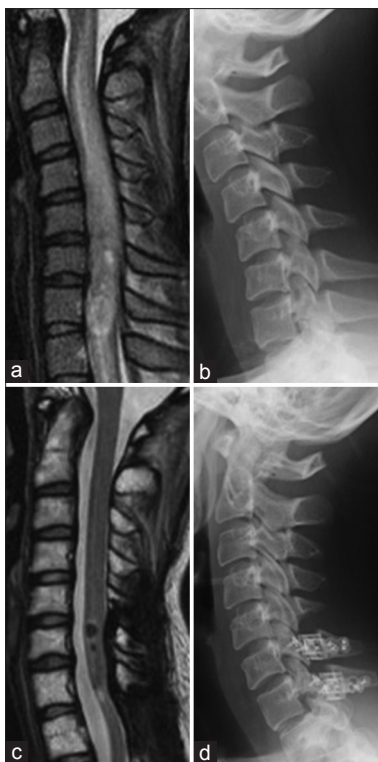

Figure 5: Illustrative case (Patient 3). (a and b): Before surgery; (c and d): After surgery and radiation

This technical note suggested that cervical lift-up laminoplasty with titanium basket plates can be applied easily and safely after resection of intradural tumors. Reconstructed laminae were assumed to be stable during follow-up, even after postoperative local radiation. Cervical alignment and ROM were well maintained after surgery. As Tani *et al.* reported, titanium basket plates offer some advantages.^[10] The titanium basket plates are universally applicable to both uni- and bi-lateral open-door laminoplasty, not only to lift-up laminoplasty. The malleability of the metal allows the basket to be altered to fit with the laminae. Finally, a lower chance of implant failure such as crack formation associated with HA spacers can be noted. Minimal artifacts on postoperative MRI and computed tomography may be another advantage because the basket consists of a thin titanium alloy.

As mentioned above, we started performing this procedure in September 2014, and the number of cases in which we performed the procedure and the follow-up period was quite limited. Longer-term results for bony fusion and deformity in the postoperative period are thus needed. We will, therefore, continue using this procedure and accumulating and evaluating the results. Furthermore, biomechanical stability of the reconstructed laminae also needs to be carefully examined. This preliminary study, although quite short and including only a small number of cases, suggested that cervical lift-up laminoplasty with titanium basket plates

may be clinically practical and represents a valid choice for reconstructing cervical laminae after wide laminectomy.

CONCLUSIONS

The technique of cervical lift-up laminoplasty using titanium basket plates was modified to create an integrated laminoplasty of the cervical spine after resection of intradural tumors. This preliminary analysis suggested that cervical spine curvature and average C2–C7 angle were not markedly changed after surgery. Neck ROM between flexion and extension was maintained from before surgery to after surgery. Image analysis using computed tomography suggested sequential osseous stability at the base of the laminae. Cervical lift-up laminoplasty with titanium basket plates appears practical and useful as a procedure to reconstruct the cervical laminae after wide laminectomy.

Declaration of patient consent

The authors certify that they have obtained all appropriate patient consent forms. In the form the patient(s) has/have given his/her/their consent for his/her/their images and other clinical information to be reported in the journal. The patients understand that their names and initials will not be published and due efforts will be made to conceal their identity, but anonymity cannot be guaranteed.

Financial support and sponsorship

Nil.

Conflicts of interest

There are no conflicts of interest.

REFERENCES

1. Kawai S, Sunago K, Doi K, Saika M, Taguchi T. Cervical laminoplasty (Hattori's method). Procedure and follow-up results. *Spine (Phila Pa 1976)* 1988;13:1245-50.
2. Seichi A, Takeshita K, Ohishi I, Kawaguchi H, Akune T, Anamizu Y, *et al.* Long-term results of double-door laminoplasty for cervical stenotic myelopathy. *Spine (Phila Pa 1976)* 2001;26:479-87.
3. Goto T, Ohata K, Takami T, Nishikawa M, Tsuyuguchi N, Morino M, *et al.* Hydroxyapatite laminar spacers and titanium miniplates in cervical laminoplasty. *J Neurosurg* 2002;97:323-9.
4. Takayasu M, Takagi T, Nishizawa T, Osuka K, Nakajima T, Yoshida J, *et al.* Bilateral open-door cervical expansive laminoplasty with hydroxyapatite spacers and titanium screws. *J Neurosurg* 2002;96 1 Suppl: 22-8.
5. Tani S, Isoshima A, Nagashima Y, Tomohiko Numoto R, Abe T. Laminoplasty with preservation of posterior cervical elements: Surgical technique. *Neurosurgery* 2002;50:97-101.
6. Takami T, Ohata K, Goto T, Nishikawa M, Nishio A, Tsuyuguchi N, *et al.* Lift-up laminoplasty for myelopathy caused by ossification of the posterior longitudinal ligament of the cervical spine. *Neurol India* 2004;52:59-63.
7. Kihara S, Umebayashi T, Hoshimaru M. Technical improvements

- and results of open-door expansive laminoplasty with hydroxyapatite implants for cervical myelopathy. *Neurosurgery* 2005;57 4 Suppl: 348-56.
8. Chiba K, Ogawa Y, Ishii K, Takaishi H, Nakamura M, Maruiwa H, *et al.* Long-term results of expansive open-door laminoplasty for cervical myelopathy – Average 14-year follow-up study. *Spine (Phila Pa 1976)* 2006;31:2998-3005.
 9. Kim P, Murata H, Kurokawa R, Takaishi Y, Asakuno K, Kawamoto T, *et al.* Myoarchitectonic spinolaminoplasty: Efficacy in reconstituting the cervical musculature and preserving biomechanical function. *J Neurosurg Spine* 2007;7:293-304.
 10. Tani S, Suetsua F, Mizuno J, Uchikado H, Nagashima H, Akiyama M, *et al.* New titanium spacer for cervical laminoplasty: Initial clinical experience. Technical note. *Neurol Med Chir (Tokyo)* 2010;50:1132-6.
 11. Kurokawa R, Kim P. Cervical laminoplasty: The history and the future. *Neurol Med Chir (Tokyo)* 2015;55:529-39.
 12. Heller JG, Edwards CC 2nd, Murakami H, Rodts GE. Laminoplasty versus laminectomy and fusion for multilevel cervical myelopathy: An independent matched cohort analysis. *Spine (Phila Pa 1976)* 2001;26:1330-6.
 13. Ratliff JK, Cooper PR. Cervical laminoplasty: A critical review. *J Neurosurg* 2003;98:230-8.
 14. Duetzmann S, Cole T, Ratliff JK. Cervical laminoplasty developments and trends, 2003-2013: A systematic review. *J Neurosurg Spine* 2015;23:24-34.
 15. Goto T, Ohata K, Takami T, Nishikawa M, Nishio A, Morino M, *et al.* Prevention of postoperative posterior tethering of spinal cord after resection of ependymoma. *J Neurosurg* 2003;99:181-7.
 16. Takeshita K, Murakami M, Kobayashi A, Nakamura C. Relationship between cervical curvature index (Ishihara) and cervical spine angle (C2–7). *J Orthop Sci* 2001;6:223-6.
 17. Scheer JK, Tang JA, Smith JS, Acosta FL Jr., Protosaltis TS, Blondel B, *et al.* Cervical spine alignment, sagittal deformity, and clinical implications: A review. *J Neurosurg Spine* 2013;19:141-59.
 18. McCormick PC, Torres R, Post KD, Stein BM. Intramedullary ependymoma of the spinal cord. *J Neurosurg* 1990;72:523-32.
 19. Takami T, Naito K, Yamagata T, Kawahara S, Ohata K. Surgical outcomes of posterolateral sulcus approach for spinal intramedullary tumors: Tumor resection and functional preservation. *World Neurosurg* 2017. pii: S1878-8750(17)31428-6.
 20. Inoue A, Ikata T, Katoh S. Spinal deformity following surgery for spinal cord tumors and tumorous lesions: Analysis based on an assessment of the spinal functional curve. *Spinal Cord* 1996;34:536-42.
 21. Asazuma T, Nakamura M, Matsumoto M, Chibo K, Toyama Y. Postoperative changes of spinal curvature and range of motion in adult patients with cervical spinal cord tumors: Analysis of 51 cases and review of the literature. *J Spinal Disord Tech* 2004;17:178-82.
 22. Fassett DR, Clark R, Brockmeyer DL, Schmidt MH. Cervical spine deformity associated with resection of spinal cord tumors. *Neurosurg Focus* 2006;20:E2.
 23. Joaquim AF, Riew KD. Management of cervical spine deformity after intradural tumor resection. *Neurosurg Focus* 2015;39:E13.