



King Saud University

Saudi Journal of Biological Sciences

www.ksu.edu.sa  
www.sciencedirect.com



ORIGINAL ARTICLE

# Antiulcerogenic activity of the hydroalcoholic extract of leaves of *Annona muricata* Linnaeus in mice



Elizângela Beneval Bento<sup>a</sup>, Francisco Elizauo de Brito Júnior<sup>a</sup>, Dayanne Rakelly de Oliveira<sup>a</sup>, Cícera Norma Fernandes<sup>a</sup>, Gyllyandeson de Araújo Delmondes<sup>a</sup>, Francisco Rafael Alves Santana Cesário<sup>a</sup>, Cristina Kelly de Sousa Rodrigues<sup>a</sup>, Valterlúcio dos Santos Sales<sup>a</sup>, Francisco Rodolpho Sobreira Dantas Nóbrega de Figueiredo<sup>a</sup>, Izabel Cristina Santiago Lemos<sup>a</sup>, Álefe Brito Monteiro<sup>a</sup>, Irwin Rose Alencar de Menezes<sup>a</sup>, José Galberto Martins da Costa<sup>b</sup>, Marta Regina Kerntopf<sup>a,\*</sup>

<sup>a</sup> Laboratory of Molecular Chemistry and Pharmacology, Regional University of Cariri, Rua Cel. Antonio Luis 1161, Pimenta, 63105-000 Crato (CE), Brazil

<sup>b</sup> Laboratory of Research in Natural Products, Regional University of Cariri, Rua Cel. Antonio Luis 1161, Pimenta, 63105-000 Crato (CE), Brazil

Received 28 July 2015; revised 23 November 2015; accepted 13 January 2016

Available online 21 January 2016

## KEYWORDS

Peptic ulcer;  
Medicinal plants;  
Phytotherapy;  
*Annona*

**Abstract** *Annona muricata* Linnaeus, popularly known as “graviola” and also called soursop, is a species typical of countries with a tropical climate, and it is used in folk medicine as an anticancer, analgesic and antispasmodic agent. The aim of the present study was to validate the gastroprotective activity of the hydroalcoholic extract of the leaves of *A. muricata* (HEAM) and to investigate the underlying mechanisms of action for this effect. Gastric lesions were induced in mice by absolute ethanol, acidified ethanol or indomethacin. Before, the animals were pretreated with saline, omeprazole or HEAM orally at doses of 50–400 mg/kg. To determine the mechanism of action of the extract, we investigated, using specific inhibitors, the involvement of nitric oxide (NO), prostaglan-

\* Corresponding author at: Laboratory of Research in Natural Products, Regional University of Cariri – URCA, Rua Cel. Antonio Luis 1161, Pimenta, 63105-000 Crato (CE), Brazil. Tel.: +55 (88)31021212; fax: +55 (88) 31021291.

E-mail address: [martareginakerntopf@outlook.com](mailto:martareginakerntopf@outlook.com) (M.R. Kerntopf).

Peer review under responsibility of King Saud University.



Production and hosting by Elsevier

dins (PGEs), ATP-dependent K<sup>+</sup> channels and  $\alpha$ 2-noradrenergic receptors. HEAM showed significant antiulcer activity against lesions induced by absolute ethanol, acidified ethanol or indomethacin, which was mediated by endogenous gastric prostaglandins.

© 2016 The Authors. Production and hosting by Elsevier B.V. on behalf of King Saud University. This is an open access article under the CC BY-NC-ND license (<http://creativecommons.org/licenses/by-nc-nd/4.0/>).

## 1. Introduction

Peptic ulcer disease is a term used to represent a group of disorders that affect the gastric and duodenal mucosa, characterized by damage to the parietal cells and can occur in any part of the gastrointestinal tract (Hernandes, 2010), each year affecting nearly 4 million people worldwide (Zelickson et al., 2011). Its pathogenesis is associated with an imbalance between protective factors secreted by the gastric mucosa (mucous secretion, nitric oxide, prostaglandins, bicarbonate and other peptides) and aggressive factors (*Helicobacter pylori* infection, pepsin, gastric acid secretion) (Mendonça et al., 2013).

Research using medicinal plants has proven to be a promising source of novel compounds in the search of new compounds with clinical and therapeutic potential that can be used in the treatment of peptic ulcers. Plants of the genus *Annona* studied are particularly reported in the literature as possessing gastroprotective activities. Species of this genus with proven antiulcerogenic effect include *Annona reticulata* (Singh et al., 2012), *Annona squamosa* (Alluri et al., 2011) and *Annona muricata* (Omoja et al., 2014; Moghadamtousi et al., 2014; Hamid et al., 2012).

*A. muricata* L., popularly known as graviola and also called soursop, belongs to the family Annonaceae, which comprises about 130 genera, including about 2300 species. Of these genera, 51 are American, while two occur in Africa (*Annona* and *Xylopia*) and one in Asia (*Anoxagorea*). In Brazil, they are present throughout the country, and the occurrence of 29 genera and about 260 species has been recorded (Alali et al., 1999). In folk medicine, this plant is used for anticancer, analgesic, anti-inflammatory and antispasmodic purposes (Junqueira et al., 1999). In an ethnobotanical survey conducted by Vásquez et al. (2014) in riverine communities, the popular use of tea made with leaves and stem bark of *A. muricata* for the treatment of gastrointestinal problems was mentioned, among them, poor digestion and gastritis.

Studies have shown that graviola contains a large number of compounds, including tannins and flavonoids (Reis, 2011; Lima, 2007; Luna et al., 2006), which have therapeutic uses because of their anti-inflammatory, antifungal, antioxidant, healing properties (Zuanazzi and Montanha, 2004) and gastroprotective effects (Parmar and Parmar, 1998).

Accordingly, the aim of our study was to validate the gastroprotective activity of the hydroalcoholic extract of the leaves of *A. muricata* L. (HEAM) and to investigate the underlying mechanisms of action for this effect.

## 2. Materials and methods

### 2.1. Plant material and extract preparation

The leaves of *A. muricata* L. were collected from the municipality of Crato, Ceara, Brazil. The plant material was identi-

fied at the Herbarium of the Regional University of Cariri – URCA, where a voucher specimen was deposited (#4417). Fresh leaves of *A. muricata* L. (2 kg) were washed under running water, and air dried. The air dried materials were macerated with 8.7 l of 99.9% ethanol and water (1:1, v/v) for seven days. The mixture was filtered using filter paper and the solvent was evaporated and lyophilized to obtain the hydroalcoholic extract of the leaves of *A. muricata* L. (HEAM) (Matos, 1997), where a final yield of 3.61% (72.24 g) was obtained.

### 2.2. Animals

Male and female albino mice, strain Swiss, weighing 20–30 g from our own breeding colony (Animal House-holding, Faculty of Medicine of Juazeiro do Norte – FMJ, Brazil) were kept in cages with free access to food and water, in a room with controlled temperature (22–24 °C) and in a 12 h light/dark cycle. The mice were divided into groups of six animals each, acclimatized and accustomed to the laboratory atmosphere for at least a week before the experiments and were used only once throughout the experiment. The protocol of this study has been approved by the Ethics Committee on Animal Research of the URCA, Brazil, with number 00214/2013. The number of animals and intensity of ulcerogenic agents were the minimum necessary to demonstrate consistent treatment effects.

### 2.3. Experimental procedures

#### 2.3.1. Gastric lesions induced by absolute ethanol

Ethanol-induced gastric lesion was carried out according to Robert et al. (1979). The mice were divided into eight groups of 6 animals per group (3 males and 3 females), fasted for a period of 14 h and treated with HEAM (50, 100, 200 and 400 mg/kg, p.o.), omeprazole (30 mg/kg, p.o.), or vehicle (saline, 0.1 ml/10 g, p.o.) 1 h before administration of absolute ethanol (0.1 ml/10 g, p.o.). After 30 min, the animals were euthanized by cervical dislocation. Their stomach was removed, opened along the greater curvature, rinsed with saline and digitized; the ulcerated area was expressed as a percentage relative to the total area of the gastric body using ImageJ software.

#### 2.3.2. Gastric lesions induced by acidified ethanol

This test was performing according to Mizui et al. (1987). The mice were treated with HEAM (50, 100, 200 and 400 mg/kg, p.o.), omeprazole (30 mg/kg, p.o.), or vehicle (saline, 0.1 ml/10 g, p.o. for the control lesion group). One hour after treatment, the animals received 0.2 ml of 0.3 M hydrochloric acid (HCl) in 60% ethanol and were euthanized 1 h later. The percentage of stomach ulceration was determined as described above.

### 2.3.3. Gastric lesions induced by indomethacin

The induction of gastric lesions by indomethacin was performed as described by Djahanguiri (1969). The mice were pretreated with HEAM (200 and 400 mg/kg, p.o.), omeprazole (30 mg/kg, p.o.), or vehicle (saline, 0.1 ml/10 g, p.o. for the control lesion group). Six hours after administration of the ulcerogenic agent (indomethacin, 10 mg/kg, s.c), the animals were euthanized. The percentage of stomach ulceration was determined as described above.

### 2.3.4. Evaluation of the mechanisms involved in gastroprotective activity of HEAM

In order to investigate the possible mechanisms by which HEAM exerts its gastroprotective effect, we examined the involvement of  $\alpha$ -2 receptors, prostaglandins, nitric oxide, ATP-dependent  $K^+$  channel activation of the capsaicin-sensitive afferent neurons. For this set of experiments, we used 200 mg/kg, of HEAM since it did not present toxicity and was effective in decreasing the induced damage in all the experimental models of gastric ulcer. To evaluate the involvement of different targets, specific antagonists such as yohimbine (2 mg/kg, i.p.) for  $\alpha$ -2 adrenergic receptor, indomethacin (10 mg/kg, p.o.) for prostaglandins, L-NAME (10 mg/kg, i.p.) for NO synthesis, glibenclamide (5 mg/kg, p.o.) for ATP-dependent  $K^+$  channel or specific agonists as L-arginine (600 mg/kg, p.o.) as a positive control for L-NAME and misoprostol (0.016 mg/kg, p.o.) as a control for indomethacin and capsaicin in dose 0.2 mg/kg and 4 mg/kg (p.o.) for capsaicin-sensitive afferent neurons were used. All drugs were dissolved in saline solution. In each case, the animals were pretreated with the specific antagonist or agonist for 30 min before the administration of HEAM. The volume of 0.1 ml/10 g, p.o. of 96% ethanol was orally administered one hour after HEAM. The animals were then euthanized, and their stomach was removed, opened along the greater curvature, washed in saline and compressed between glass slides for better viewing. The slides were scanned at 1200 dpi. The percentage of area with gastric lesions (glandular portion) was determined with ImageJ software. The injured area was expressed as a relative percentage of the total area of the gastric body (Lapa et al., 2008; Rahgozar et al., 2001; Matsuda et al., 1999; Djahanguiri, 1969).

### 2.3.5. Effect of HEAM on intestinal motility

The effect of HEAM on intestinal motility was evaluated as reported by Lapa et al. (2008). Briefly, animals were treated with HEAM (200 mg/kg, p.o.), saline (0.1 ml/10 g, vehicle, p.o.), or atropine (0.01 g/kg, p.o.) a muscarinic antagonist, followed by 10% activated charcoal one hour after (0.1 ml/10 g, p.o.). Thirty minutes after charcoal administration, the animals were euthanized, and their small intestine was removed. The total length of the intestine (the pyloric region to the ileocecal junction) was then measured; the distance traveled by the charcoal was determined based on the distance from the pylorus to the last portion of the intestine that contained at least 1 cm of continuous charcoal.

### 2.4. Statistical analysis

Results were expressed as mean  $\pm$  standard error mean (S.E. M.) and analyzed by a one-way ANOVA followed by Newman-Keuls test, unless otherwise stated  $p < 0.05$  was consid-

ered significant. Graphs were drawn by using GraphPad Prism 5 software.

## 3. Results

### 3.1. Effect of HEAM on acute gastric lesions induced in mice by absolute ethanol

The effect of HEAM on gastric lesions induced by absolute ethanol (0.2 mL/animal) is shown in Fig. 1. Animals that received only the vehicle combined with oral administration of absolute ethanol showed an extensive area of gastric lesions ( $18.57 \pm 2.12\%$ ). Oral HEAM pretreatment at doses of 50, 100, 200 and 400 mg/kg before the administration of absolute ethanol produced a significant reduction in lesion area of 92.89%, 94.13%, 97.79% and 96.55%, respectively, showing that HEAM at a dose of 200 and 400 mg/kg was more effective than the standard drug used in the positive control group (omeprazole) (Fig. 1). Animals that received omeprazole (30 mg/kg p.o.) showed a significant reduction in gastric lesion areas of 95.79%, compared to the control ( $p < 0.001$ ).

### 3.2. Effect of HEAM on acute gastric lesions induced in mice by acidified ethanol

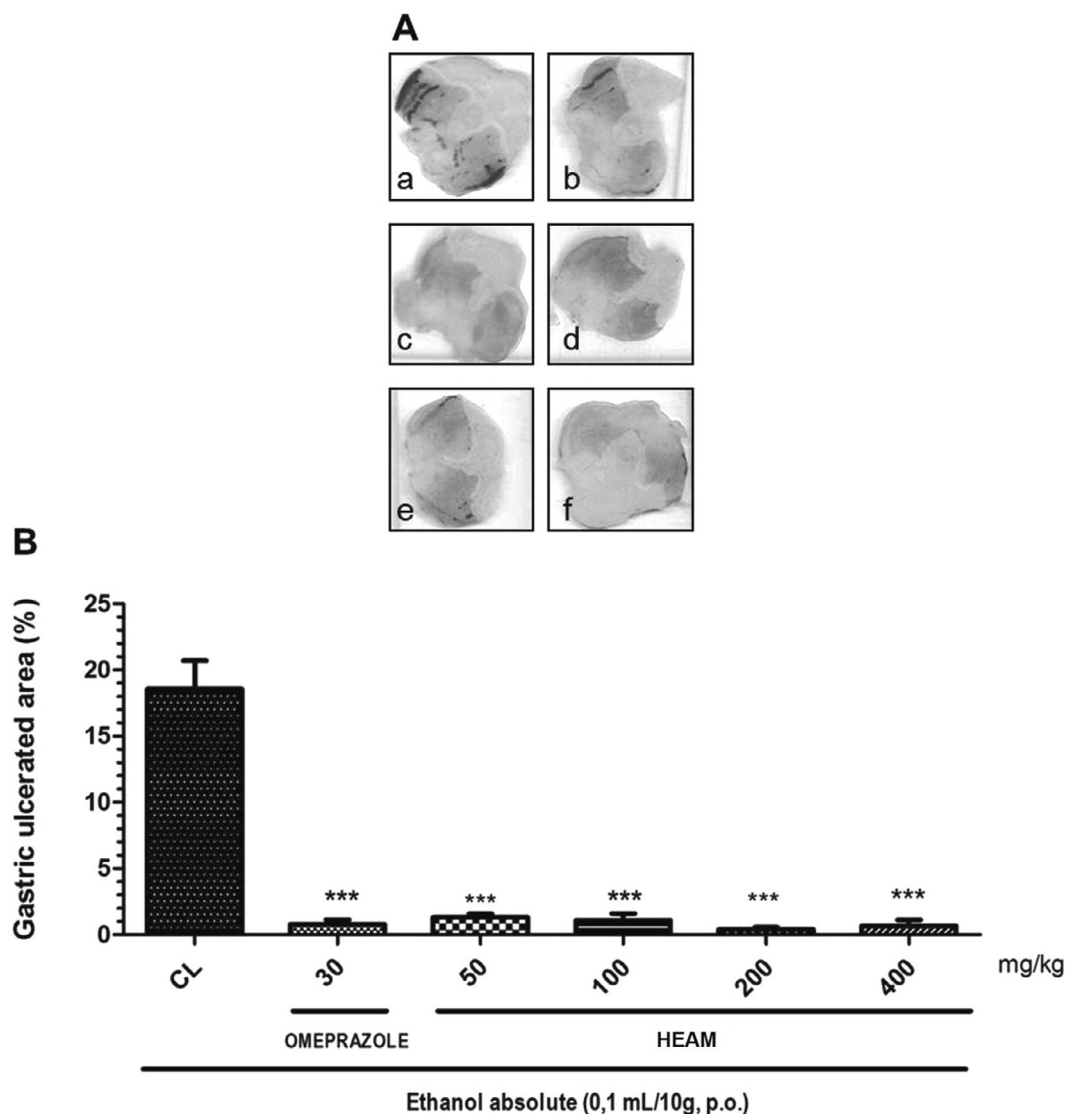
The administration of 0.3 M HCl in 70% ethanol solution induced lesions in the gastric mucosa to an extent of  $23.19 \pm 3.09\%$ . In the groups pretreated with HEAM at doses of 50, 100, 200 and 400 mg/kg, we observed a reduction in lesions of 47.69%, 76.23%, 80.20% and 93.22%, respectively (Fig. 2). At a dose of 400 mg/kg, HEAM was as effective as the standard drug (omeprazole), which reduced the ulcer area by 93.22%. Animals that received omeprazole (30 mg/kg) showed a significant reduction in gastric lesion areas of 84.56% ( $p < 0.001$ ) compared to the control (Fig. 2).

### 3.3. Effect of HEAM on acute gastric lesions induced by in mice non-steroidal anti-inflammatory drug – NSAIDs (indomethacin)

Indomethacin (10 mg/kg) produced gastric lesions of  $12.61 \pm 3.27\%$ , as shown in Fig. 3. Pretreatment of animals with 200 and 400 mg/kg HEAM before indomethacin administration showed changes in lesion areas. HEAM at 200 mg/kg proved to be the most effective dose, reducing the incidence of ulcers by 94.13% (Fig. 3). HEAM at 400 mg/kg also decreased the incidence of ulcers significantly by 91.67%. Omeprazole (30 mg/kg) reduced lesion rates by 96.82% compared with the control group (Fig. 3).

### 3.4. Gastroprotective effect of HEAM in mice model of gastric lesions induced by absolute ethanol and role of nitric oxide (NO)

The administration of the vehicle in combination with absolute ethanol (0.2 ml/animal) produced gastric lesions of  $20.52 \pm 2.29\%$ . Animals that received L-NAME (10 mg/kg), an inhibitor of nitric oxide synthase (NOS), showed a percentage of  $28.73 \pm 3.83\%$  lesions associated with absolute ethanol. The animals that received L-arginine (600 mg/kg), the precursor for nitric oxide synthesis, in combination with absolute ethanol showed a percentage of gastric lesions of  $1.47 \pm 0.38\%$



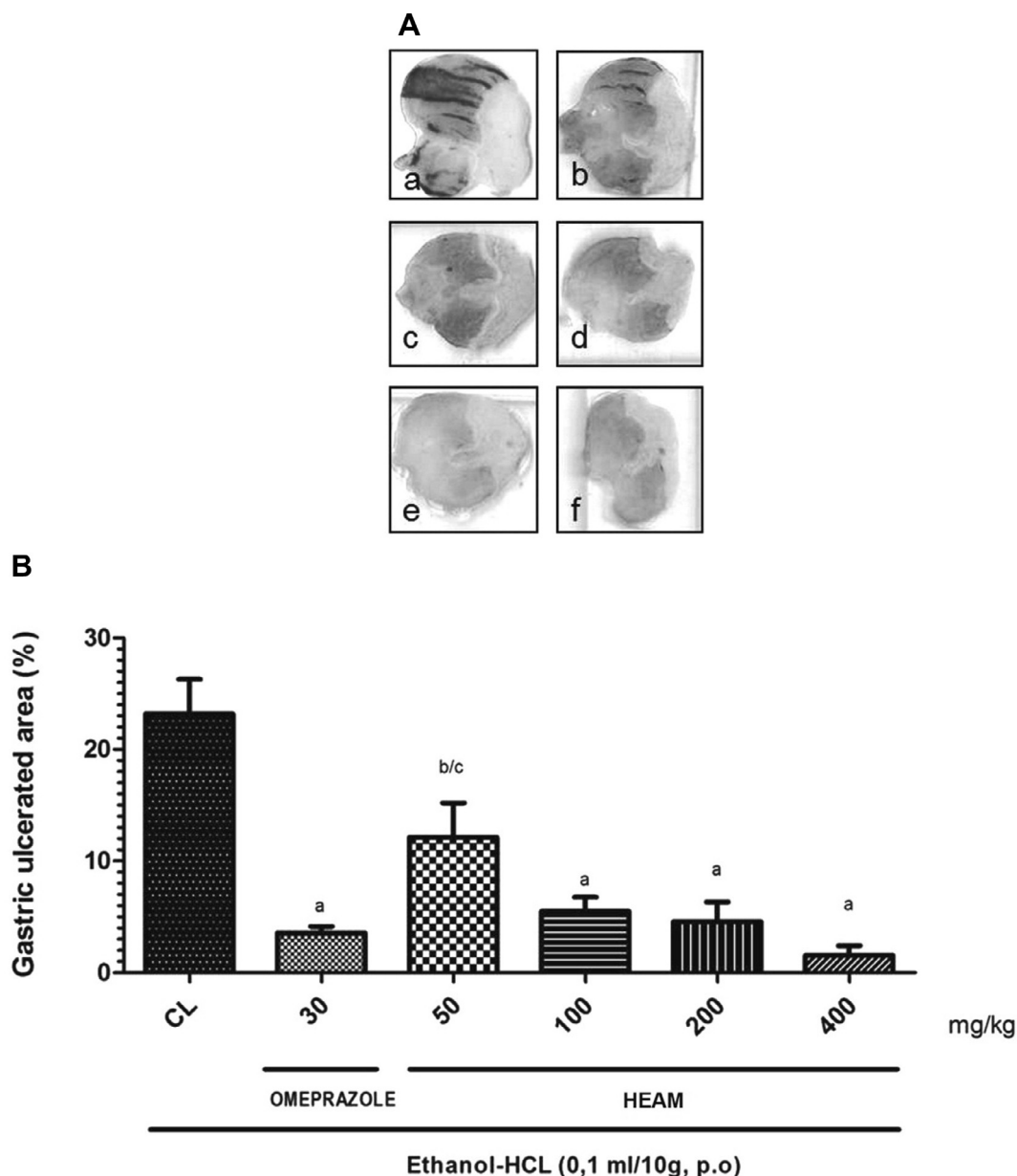
**Figure 1** Effect of oral administration of HEAM on gastric lesions induced by absolute ethanol in mice. (A) Macroscopic appearance of the stomach mucosa: control group (a); groups treated with omeprazole (b), 50 mg/kg HEAM (c), 100 mg/kg HEAM (d), 200 mg/kg HEAM (e) and 400 mg/kg HEAM (f). (B) Quantification of ulcerated area expressed in%. \*\*\*  $p < 0.001$ , compared with lesion control (CL).

(Fig. 4). In animals pre-treated with 200 mg/kg HEAM, there was a 98.57% decrease in ulcer area when compared to the group that received L-NAME + absolute ethanol (Fig. 4). In the groups pretreated with HEAM (200 mg/kg) + L-NAME (10 mg/kg) and HEAM (200 mg/kg) + L-arginine (600 mg/kg) had a reduction in lesion area of 85.58% and 88.54%, respectively, when compared to the group that received L-NAME + absolute ethanol.

### 3.5. Gastroprotective effect of HEAM in mice model of gastric lesions induced by absolute ethanol and role of prostaglandins

The ulcerations of the gastric mucosa induced by vehicle in combination with absolute ethanol (0.2 ml/animal) were  $18.57 \pm 2.12\%$  (Fig. 5). The animals that received indomethacin (10 mg/kg), an inhibitor of prostaglandin synthesis, com-

bined with absolute ethanol (0.2 ml/animal) exhibited a lesion area of  $13.09 \pm 1.92\%$ . The animals pretreated with misoprostol (0.016 mg/kg), a synthetic prostaglandin analog, along with absolute ethanol showed a reduction in lesion area of 95.64%, when compared to the group that received indomethacin combined with absolute ethanol. In the group pretreated with 200 mg/kg HEAM, there was a reduction in lesion area of 96.86%, when compared to the group that received indomethacin combined with absolute ethanol (Fig. 5). In the group pretreated with HEAM (200 mg/kg) + indomethacin (10 mg/kg), we observed a reduction in lesion area of 26.81%, when compared to the group that received indomethacin combined with absolute ethanol (Fig. 5). In the group pretreated with HEAM (200 mg/kg) + misoprostol (0.016 mg/kg), an analog of prostaglandin E1 type (PGE 1), there was a reduction in lesion area of 91.21%, when



**Figure 2** Effect of oral administration of HEAM on gastric lesions induced by acidified ethanol in mice. (A) Macroscopic appearance of the stomach mucosa: control group (a); groups treated with omeprazole (b), 50 mg/kg HEAM (c), 100 mg/kg HEAM (d), 200 mg/kg HEAM (e) and 400 mg/kg HEAM (f). (B) Quantification of ulcerated area expressed in%. <sup>a</sup> $p < 0.001$  vs lesion control (CL). <sup>b</sup> $p < 0.01$  vs CL and <sup>c</sup> $p < 0.05$  vs omeprazole group.

compared to the group that received indomethacin combined with absolute ethanol (Fig. 5).

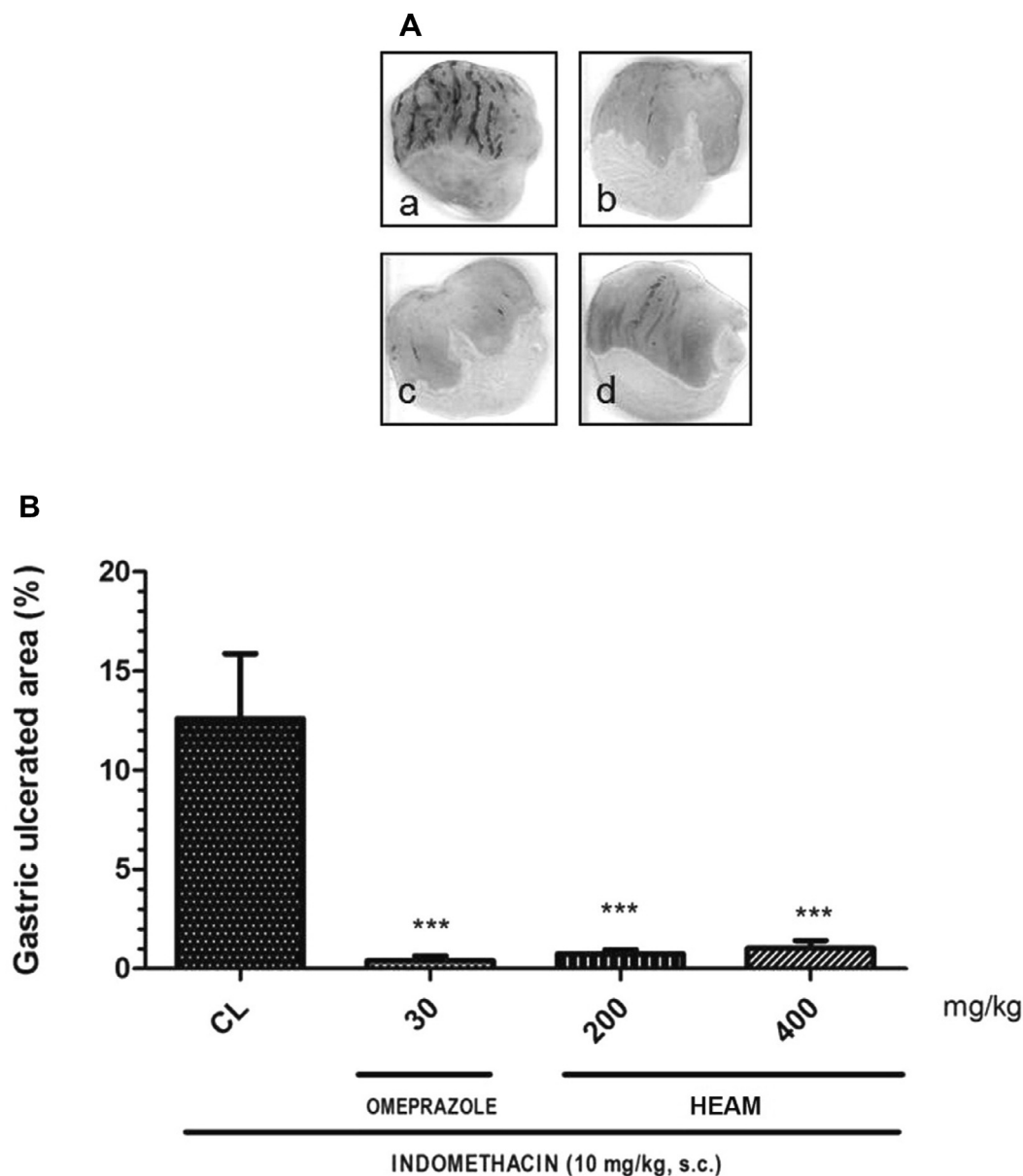
### 3.6. Gastroprotective effect of HEAM in mice model of gastric lesions induced by absolute ethanol and role of $\alpha 2$ -noradrenergic receptors

The administration of absolute ethanol induced lesions in the gastric mucosa, followed by loss of folds and occurrence of edema and hemorrhage with ulcerative lesions of  $23.22 \pm 2.08\%$ , as shown in Fig. 6. Animals that received yohimbine (2 mg/kg), an antagonist of  $\alpha 2$ -noradrenergic receptors, combined with absolute ethanol (0.2 ml/animal) showed an extensive ulcerated area ( $30.34 \pm 4.96\%$ ). Lesions induced by

absolute ethanol decreased in the group pretreated with 200 mg/kg HEAM ( $p < 0.001$ ), where the lesion area was reduced by 98.64% when compared to the group that received yohimbine combined with absolute ethanol (Fig. 6).

### 3.7. Gastroprotective effect of HEAM in mice model of gastric lesions induced by absolute ethanol and role of ATP-dependent $K^+$ channels

The administration of absolute ethanol caused ulceration of the gastric mucosa showing an area of  $17.17 \pm 2.44\%$ . Animals that received glibenclamide (5 mg/kg), a blocker of ATP-dependent  $K^+$  channels, combined with absolute ethanol (0.2 ml/animal) exhibited a large ulcerated area (13.30



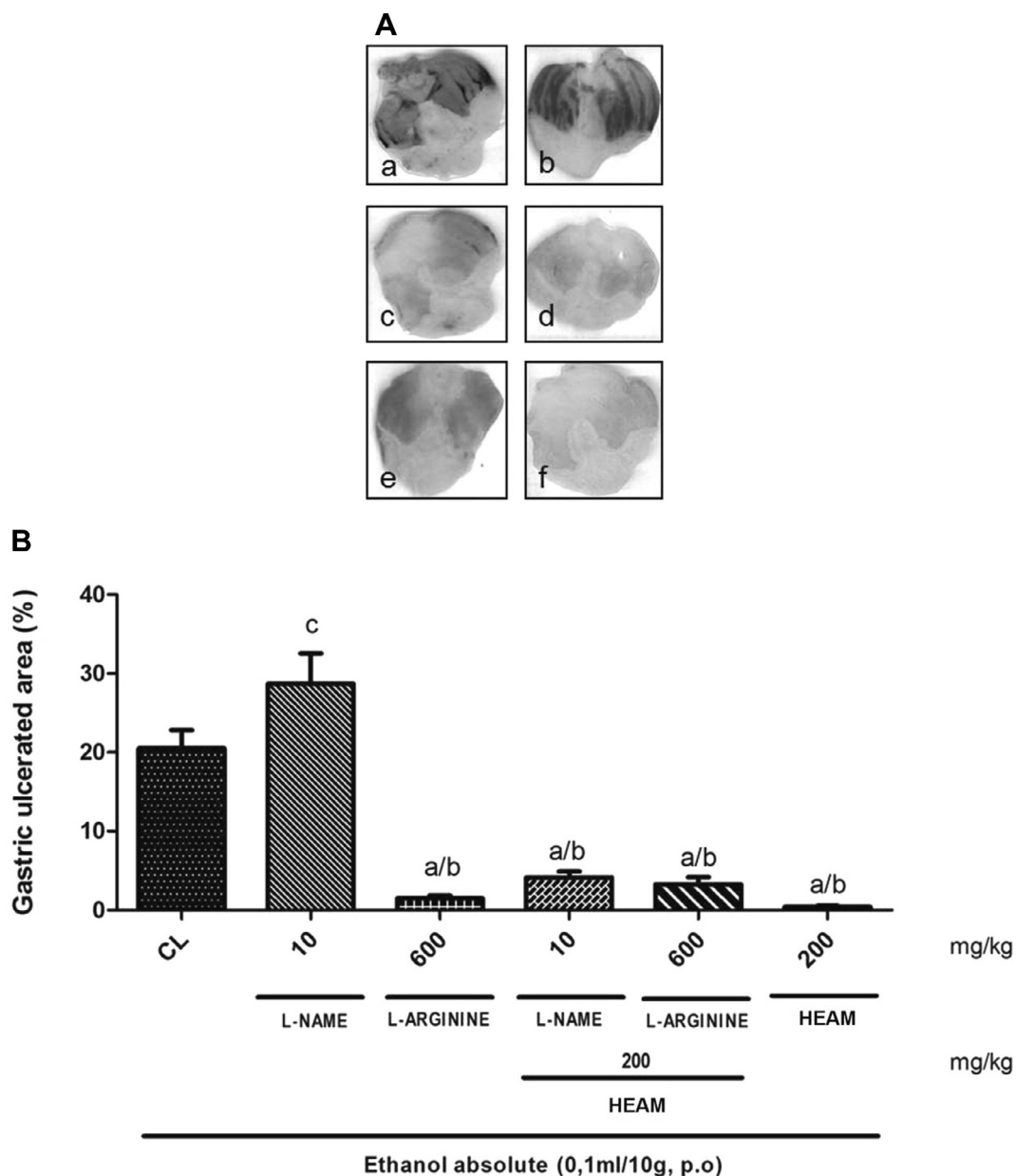
**Figure 3** Effect of oral administration of HEAM on indomethacin-induced gastric lesions in mice. (A) Macroscopic appearance of the stomach mucosa: control group (a); groups treated with omeprazole (b), 50 mg/kg HEAM (c), 100 mg/kg HEAM (d), 200 mg/kg HEAM (e) and 400 mg/kg HEAM (f). (B) Quantification of ulcerated area expressed in%. \*\*\*  $p < 0.001$  compared with lesion control (CL).

$\pm 2.25\%$ ). Already the group that received the glibenclamide (5 mg/kg) associated with HEAM (200 mg/kg) exhibited an ulcerated area percentage of  $1.45 \pm 0.57\%$ . The ulceration of the gastric mucosa induced by absolute ethanol was reduced by 96.91% in the group pretreated with 200 mg/kg HEAM, when compared to the group that received glibenclamide combined with absolute ethanol (Fig. 7).

### 3.8. Gastroprotective effect of HEAM in combination with capsaicin in mice model of gastric lesions induced by absolute ethanol

Absolute ethanol administration induced the production of lesions in the gastric mucosa amounting to  $23.80 \pm 3.80\%$ .

The animals that received capsaicin (0.2 mg/kg), a gastroprotective agent, combined with absolute ethanol (0.2 ml/animal) exhibited an ulcerated area of  $6.94 \pm 0.96\%$ . Already the animals that received capsaicin (4 mg/kg) combined with absolute ethanol (0.2 ml/animal) showed a significant ( $p < 0.001$ ) decrease in ulcer area of 93.27% when compared with the control group. The ulceration of the gastric mucosa induced by absolute ethanol was reduced by 64.78% in the group pretreated with 200 mg/kg HEAM when compared with the control group. It was thus demonstrated that HEAM, combined with capsaicin (4 mg/kg), for the treatment of gastric lesions induced by absolute ethanol in mice caused a significant decrease in lesion area  $p < 0.001$  (Fig. 8).



**Figure 4** Role of nitric oxide (NO) in the gastroprotective effect of HEAM in mice model of gastric lesions induced by absolute ethanol. (A) Macroscopic appearance of the stomach mucosa: control group (a); groups treated with L-NAME (b), L-arginine (c), 200 mg/kg HEAM + L-NAME (d), 200 mg/kg HEAM + L-arginine (e) and 200 mg/kg HEAM (f). (B) Quantification of ulcerated area expressed in %. <sup>a</sup> $p < 0.001$  vs the lesion control (CL), <sup>b</sup> $p < 0.001$  vs L-NAME and <sup>c</sup> $p < 0.01$  vs control.

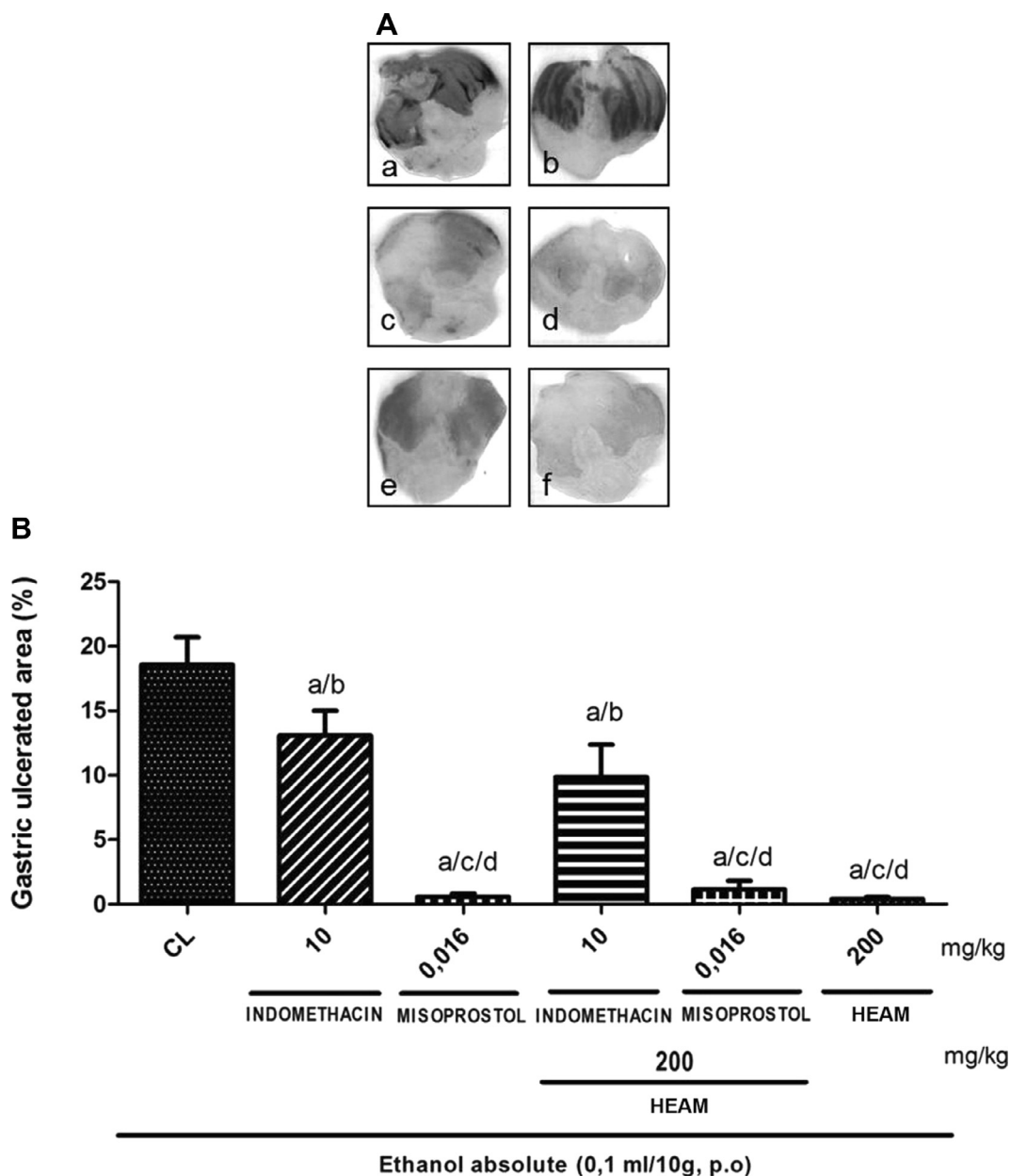
### 3.9. Effect of HEAM on intestinal transit in mice

In control animals, activated carbon traveled  $82.77 \pm 4.29\%$  of the small intestine of animals. The administration of HEAM (200 mg/kg) resulted in an intestinal transit rate of  $70.14 \pm 6.48\%$ , showing no significant change compared to the control (Fig. 9). Atropine (0.01 mg/kg), a muscarinic antagonist that reduces intestinal motility, decreased distance traveled to  $63.21 \pm 2.05\%$  when compared to the vehicle control group (saline),  $p < 0.05$  (Fig. 9).

## 4. Discussion

Studies on natural products, especially those derived from medicinal plants, have shown them to be an alternative source of new compounds with pharmacological potential. In folk medicine, a range of beneficial effects have been reported for these products, including their action against gastritis and gastric ulcers.

The in vivo pharmacological models have an important role in the search for new bioactive compounds with gastroprotective



**Figure 5** Role of prostaglandins in the gastroprotective effect of HEAM in mice model of gastric lesions induced by absolute ethanol. (A) Macroscopic appearance of the stomach mucosa: control group (a); groups treated with indomethacin (b), misoprostol (c), 200 mg/kg HEAM + indomethacin (d), 200 mg/kg HEAM + misoprostol (e) and 200 mg/kg HEAM (f). (B) Quantification of ulcerated area expressed in%. <sup>a</sup> $p < 0.001$  vs lesion control (CL), <sup>b</sup> $p < 0.01$  vs CL, <sup>c</sup> $p < 0.01$  vs indomethacin, <sup>d</sup> $p < 0.001$  vs indomethacin in combination with HEAM.

properties (Júnior et al., 2013). Given that gastric ulcers may occur due to multifactorial causes, gastric lesions can be evaluated in various experimental models and induced by different damaging agents (Samonina et al., 2004). The acute models that are more used to assess antiulcer activity of natural products in animal models are indomethacin-induced gastric lesions and absolute ethanol (Lapa et al., 2008). In this study, besides using these methods the effects of HEAM through the model of gastric lesions induced by acidified ethanol were also assessed.

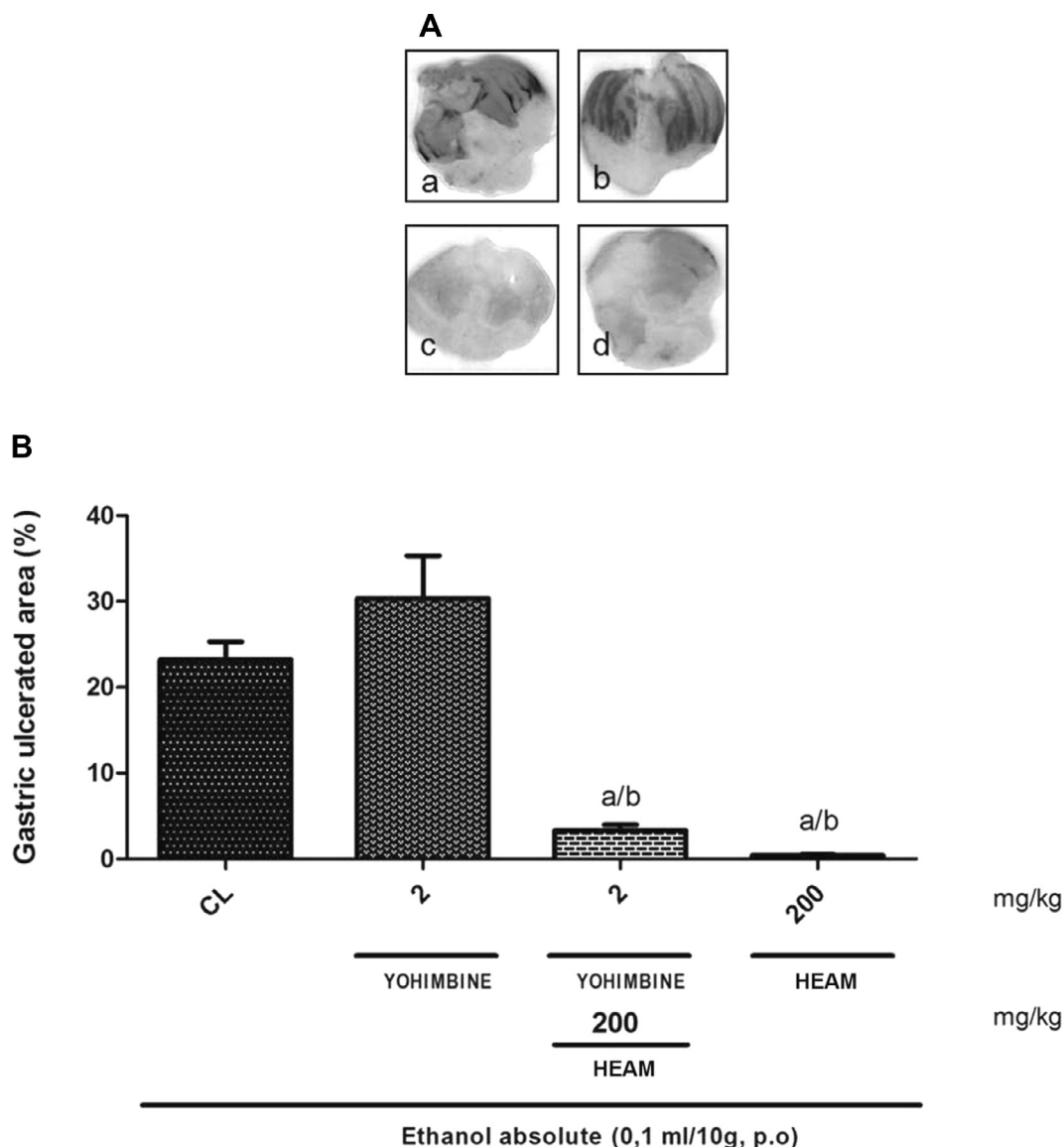
Gastric ulcers resulting from ethanol administration occur because of its direct action of necrotizing, in the gastric

mucosa. Furthermore, ethanol induced gastric lesions through the disruption of the protective mucus – bicarbonate barrier and the damage to the vascular endothelium, with subsequent microcirculation disorders, ischemia and production of free radicals (Pan et al., 2008).

In gastric lesions induced by acidified ethanol, ethanol and HCl act synergistically resulting in ulcer, through the potentiation of ethanol effects triggered by HCl (Adeyemi et al., 2006).

As regards indomethacin, most nonsteroidal antiinflammatory drugs (NSAIDs) act through the inhibition of cyclooxygenase (COX's) 1 and 2 in order to promote the reduction of





**Figure 6** Role of  $\alpha 2$ -noradrenergic receptors in the gastroprotective effect of HEAM in mice model of gastric lesions induced by absolute ethanol. (A) Macroscopic appearance of the stomach mucosa: control group (a); groups treated with yohimbine (b), 200 mg/kg HEAM + yohimbine (c) and 200 mg/kg HEAM (d). (B) Quantification of ulcerated area expressed in%. <sup>a</sup> $p < 0.001$  vs lesion control (CL), <sup>b</sup> $p < 0.001$  vs yohimbine.

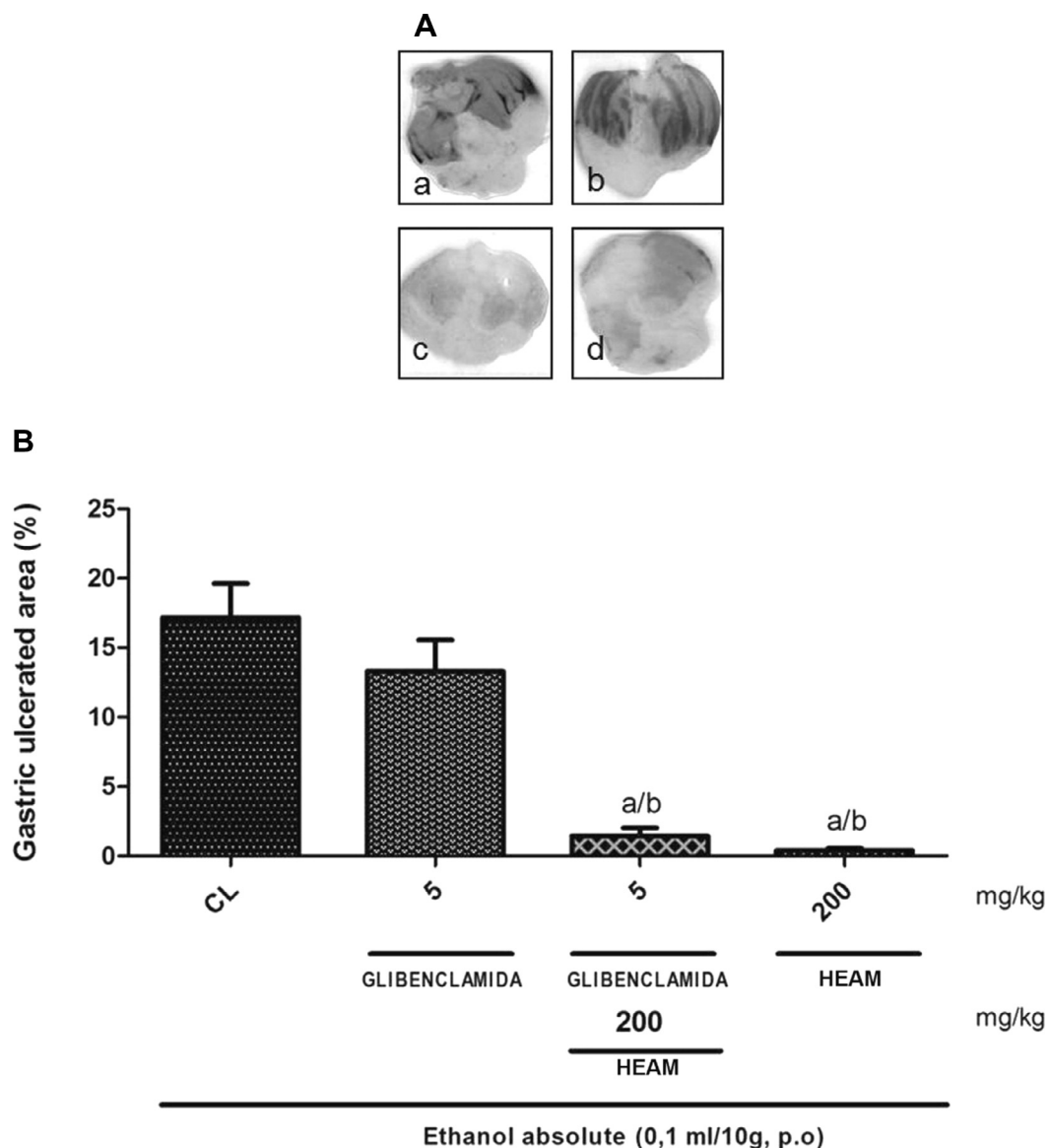
prostaglandins (PG's). Therefore, the inhibition of prostaglandin synthesis results in weakening of mucosal defense, reducing its ability to withstand aggressiveness (Chan and Leung, 2002). This is the principal mechanism by which this class of drugs causes damage to the gastrointestinal tract (Wallace, 1997).

The study of Hamid et al. (2012) showed that of the ethanolic extract of *A. muricata* leaves has gastroprotective properties against gastric lesions induced by absolute ethanol. Moghadamtousi et al. (2014) noted in their study that the ethyl acetate extract of *Annona muricata* leaves also showed gastroprotective effect against models of gastric lesions induced by absolute ethanol and that this anti-ulcer activity occurred because of the antioxidant effect of this species. In assessing the gastroprotective action of *A. muricata* L. leaves, we found that this plant not only protects mice against acute gastric

lesions induced by absolute ethanol but also acidified ethanol and indomethacin, all with a 99.99% confidence interval.

According to Bento et al. (2013), the leaves of *A. muricata* L. have the following classes of secondary metabolites: pyrogalllic tannins, flavonones, flavonoids, flavones and alkaloids; which possibly act in synergy to activate defense factors of the gastric mucosa, making this extract promising for developing new therapies to fight NSAID associated gastropathy and peptic ulcer disease. In the study conducted by Omoja et al. (2014), it was observed that the methanolic extract of the leaves of *A. muricata* has antiulcer activity and that the gastroprotective potential occurs because of the presence of saponins, alkaloids and tannins in their chemical composition.

However, to clarify its gastroprotective effect, we analyzed its possible mechanism of action, because several molecular



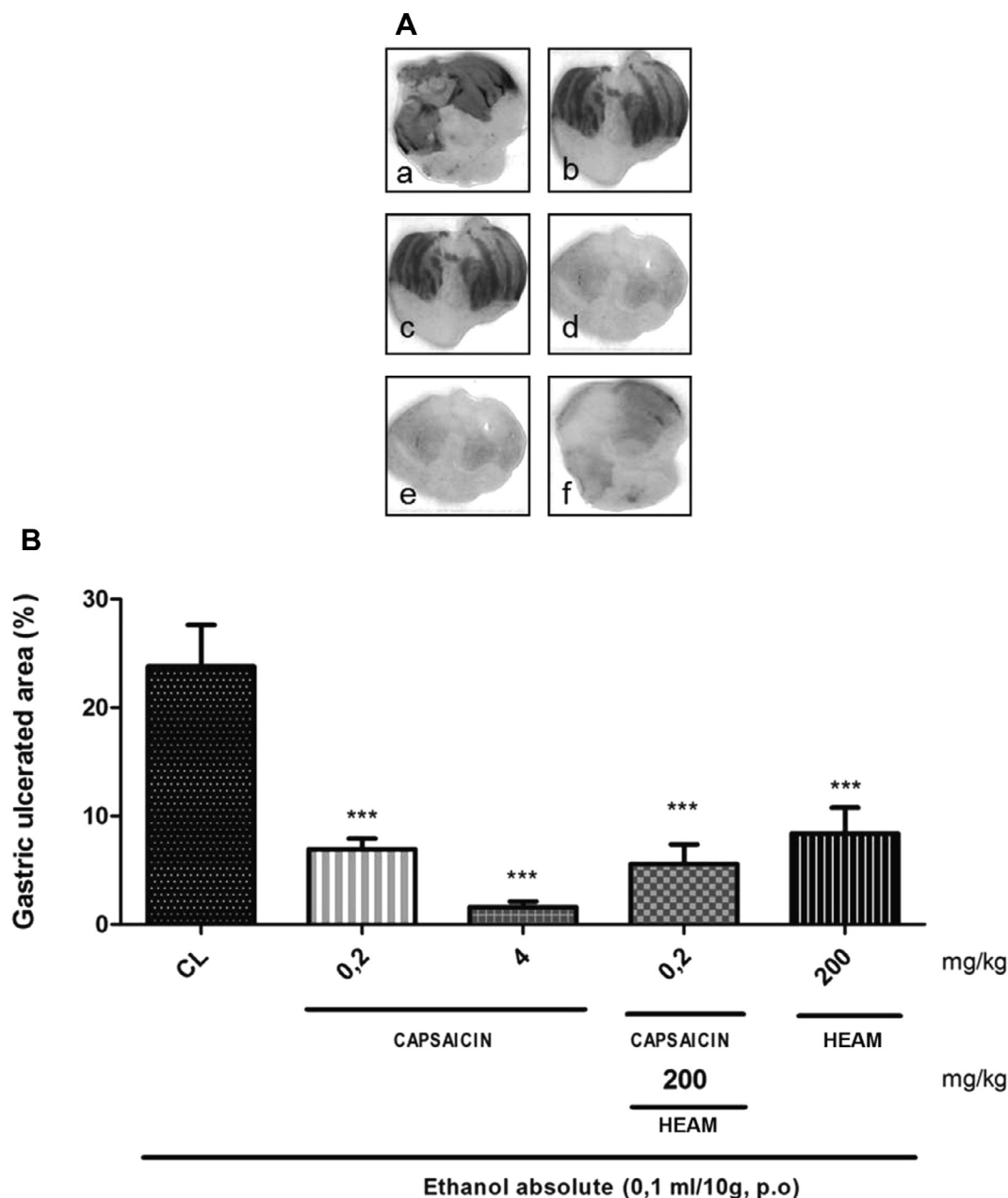
**Figure 7** Role of ATP-dependent  $K^+$  channels in the gastroprotective effect of HEAM in mice model of gastric lesions induced by absolute ethanol. (A) Macroscopic appearance of the stomach mucosa: control group (a); groups treated with glibenclamide (b), 200 mg/kg HEAM + glibenclamide (c) and 200 mg/kg HEAM (d). (B) Quantification of ulcerated area expressed in%. <sup>a</sup> $p < 0.001$  vs lesion control (CL), <sup>b</sup> $p < 0.001$  vs glibenclamide.

mechanisms are involved and act in the mucosa as protective measures. Regarding the numerous factors involved in the integrity of the gastric mucosa against ulcerogenic agents, we evaluated the effects of nitric oxide (NO), prostaglandins (PG's), ATP-sensitive potassium channels ( $K_{ATP}$ ) and  $\alpha 2$ -noradrenergic receptor and found that the prostaglandin pathway was the only one that proved to be the possible mechanism of action of the gastroprotective effect of HEAM.

Nitric oxide is an important determinant of great importance in the prevention and healing of injuries in the gastrointestinal tract (GIT), which acts by promoting the production of mucus and secretion of bicarbonate and maintenance of capillary blood flow, and as a cytoprotective agent of prostaglandins in the stomach (Wallace and Granger, 1996; Djahanguiri and Wallace, 1999).

In our study, we analyzed the role of this pathway in gastroprotection. We observed that prior administration of the NO inhibitor (L-NAME) did not block the protection afforded by HEAM against ulcers caused by absolute ethanol, and with the administration of NOS precursor (L-arginine), there were no changes in the protective action of HEAM. These data demonstrate the non-involvement of the NO pathway in anti-ulcerogenic paper, excluding the activities of NO in the management of the protective effect of HEAM, confirming the study Hamid et al. (2012).

Prostaglandins, found in almost all organs and tissues are synthesized from arachidonic acid through cyclooxygenase enzymes. COX-1 isoform (constitutive) is responsible for the production of most prostaglandins in the normal stomach



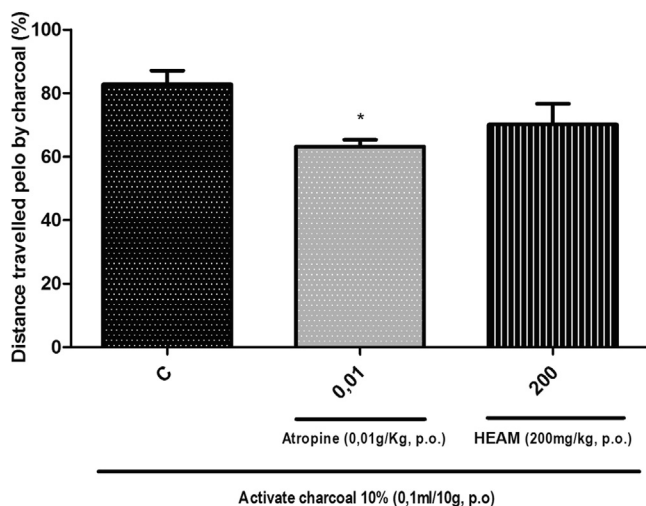
**Figure 8** Role of capsaicin-associated receptor in the gastroprotective effect of HEAM in mice model of gastric lesions induced by absolute ethanol. (A) Macroscopic appearance of the stomach mucosa: control group (a); groups treated with 0.2 mg/kg capsaicin (b), 4 mg/kg capsaicin (c), 200 mg/kg HEAM + 0.2 mg/kg capsaicin (d), 200 mg/kg HEAM + 4 mg/kg capsaicin (e) and 200 mg/kg HEAM (f). (B) Quantification of ulcerated area expressed in%. \*\*\* $p < 0.001$  vs lesion control (CL).

and COX-2 isoform (inducible) operates in the production of prostaglandins (Laine et al., 2008).

In the stomach, the protective action of prostaglandins is modulated by increased mucus production and bicarbonate secretion, regulation of gastric acid secretion, blocking the release of histamine by mast cells, maintenance of blood flow during exposure to irritants (Sakai et al., 1995), vasodilation and rapid wound healing (Wallace and Granger, 1996), because the capacity of prostaglandin to reduce gastric acid secretion contributes to the acceleration of healing of ulcers (Wallace, 2008). Prostaglandin E2 influences gastric acid secretion, where at low concentrations, it inhibits gastric acid secretion by interaction with EP3 receptors and has a protective

action against lesions induced by ethanol, by increasing cyclic guanosine monophosphate (Sakai et al., 1995). Therefore, the inhibition of prostaglandin synthesis, by NSAIDs ends with increased risk of damage to the mucosa and, consequently, gastroduodenal ulceration (Barros et al., 2008; Wallace, 2001; Hayllar and Bjarnason, 1995).

In analyzing the role of prostaglandins in the gastroprotective effect of HEAM, misoprostol, an analog of prostaglandin, and indomethacin, an inhibitor of prostaglandin synthesis (Rang et al., 2012), were used for the analysis of the likely involvement of this pathway. With regard to ulcers caused by indomethacin, pretreatment with HEAM provided protection of the gastric mucosa, and the effect was suppressed when



**Figure 9** The role of intestinal motility in the gastroprotective effect of HEAM in mice model of gastric lesions induced by absolute ethanol. Control group; groups treated with 0.01 mg/kg atropine; 200 mg/kg HEAM. Quantification of ulcerated area expressed in%. \* $p < 0.05$  vs control (C).

indomethacin was combined with ethanol compared to the group treated with misoprostol, indicating the involvement of prostaglandins in the gastroprotective effect of HEAM, because the inhibition of their synthesis by indomethacin reversed the gastroprotective effect.

Presynaptic  $\alpha 2$ -noradrenergic receptors participate in the control of gastric acid secretion, and are effective in protecting from harmful factors such as NSAIDs and ethanol. The antisecretory effects can be mediated by central and peripheral receptors, but the regulation of peripheral  $\alpha 2$  receptors induces a decrease in vagal acetylcholine levels, which decreases the gastric secretion and motility and increases blood flow. Among the agents that cause these effects, there is yohimbine, which acts by blocking these receptors (Yelken et al., 1999; Gyires et al., 2000; Hoffman, 2007). We examined the role of this pathway in mediating gastroprotection and noted that yohimbine was not able to reverse the gastroprotective effect of HEAM. These results indicated that HEAM does not act via modulation of the activity of peripheral  $\alpha 2$  receptors to exert its protective effect.

Glibenclamide reduces the permeability of cells to  $K^+$  by blocking  $K_{ATP}$  channels and  $Ca^{2+}$  entrance, causing depolarization and inducing gastric vasoconstriction and decreased blood flow in the affected region, promoting the formation of ulcers. The involvement of  $K_{ATP}$  channels in protection from ethanol-induced ulcers, could be connected to a  $K_{ATP}$  channel opening system, and secretion of intracellular content, with consequent endothelial relaxation in the gastric vasculature and increased blood flow in the region affected, thus preventing the formation of ulcers (Katzung et al., 2014; Campos et al., 2008). Our findings showed that HEAM when combined with glibenclamide retained its gastric protective effect, suggesting that the active principles of the extract did not have gastroprotective mechanism of action via ATP-dependent potassium channels.

Capsaicin is a substance that acts on sensory neurons, stimulating vanilloid receptor on the cell membrane, releasing neu-

ropeptides. Capsaicin acts as a potent gastroprotective agent, stimulating gastric microcirculation (Szolcsanyi and Bartho, 2001; Evangelista, 2006) and is involved in a local defense mechanism against the formation of gastric ulcers especially against gastric lesions induced by ethanol (Park et al., 2000). Therefore, we evaluated the possible action of HEAM in facilitating the gastroprotective effect of capsaicin. We found that when the HEAM was administered with capsaicin, its gastroprotective effect was maintained but did not differ significantly compared to capsaicin alone. Thus, we observed that the combination of HEAM and capsaicin did not modify the gastroprotective potential of the drug.

Another way by which HEAM could act and promote protection of the gastric mucosal was by increasing gastrointestinal motility through the M1 and M3 cholinergic receptors, inducing a faster gastric emptying and decreasing the aggressor effect of acid in the stomach and duodenum (Hansen, 2003). The results showed that the cholinergic system was not involved in the mechanism of action of HEAM by the lack of effect of the extract on gastrointestinal motility.

This study confirmed the gastroprotective action of *A. muricata* L. leaves and that this activity is modulated or mediated by the synthesis of prostaglandins, thereby determining the phytotherapeutic potential of this species to treat stomach ulcers and gastritis.

## 5. Conclusion

The hydroalcoholic extract of *A. muricata* L. leaves against gastric lesions induced by absolute ethanol, acidified ethanol or indomethacin inhibited or reduced the ulceration process by these agents, which was mediated by endogenous gastric prostaglandins. However, this effect on the synthesis or modulation of prostaglandins may be due to the different compounds present in HEAM acting together in the activation of protective factors (prostaglandins) and reducing the aggressive factors of gastric mucosa.

## Acknowledgments

This work was supported by Conselho Nacional de Desenvolvimento Científico e Tecnológico (CNPq), Fundação Cearense de Apoio ao Desenvolvimento Científico e Tecnológico (FUNCAP), Coordenação de Aperfeiçoamentos de Pessoal de Nível Superior (CAPES) and Universidade Regional do Cariri (URCA).

## References

- Adeyemi, O.O., Yemitan, O.K., Taiwo, A.E., 2006. Neurosedative and muscle-relaxant activities of ethyl acetate extract of *Baphia nitida* AFZEL. *J. Ethnopharmacol.* 106 (3), 312–316.
- Alali, F.Q., Liu, X.X., MscLaughlin, J.L., 1999. Annonaceous acetogenins: recent progress. *J. Nat. Prod.* 62 (3), 504–540.
- Alluri, R., Sagi, A.K., Pasala, P.K., 2011. Evaluation of gastric antiulcer and antioxidant activities in aqueous extracts of *Annona squamosa* and *Achyranthes aspera* in Rats. *Int. J. Phytopharmacology* 2 (2), 66–69.
- Barros, M.P., Lemos, M., Maistro, E.L., Leite, M.F., Sousa, J.P.B., Bastos, J.K., Andrade, S.F., 2008. Evaluation of antiulceractivity of the mains phenolic acids found in Brazilian Green Propolis. *J. Ethnopharmacol.* 120, 372–377.

- Bento, E.B., Matias, E.F.F., Brito-Júnior, F.E., Oliveira, D.R., Coutinho, H.D., Costa, J.G.M., Kerntopf, M.R., Menezes, I.R.A., 2013. Association between food and drugs: antimicrobial and synergistic activity of *Annona muricata* L. *Int. J. Food Prop.* 16, 738–744.
- Campos, D.A., Lima, A.F., Ribeiro, E.R., Silveira, E.R., Pessoa, O.D., Rao, V.S., Santos, F.A., 2008. Gastroprotective effect of a flavone from *Lonchocarpus araripensis*. *J. Pharm. Pharmacol.* 60 (3), 391–397.
- Chan, F.L., Leung, W.K., 2002. Peptic ulcer disease. *Lancet* 360, 933–941.
- Djahanguiri, B., 1969. The production of acute gastric ulceration by indomethacin in the rat. *Scand. J. Gastroenterol.* 4, 265.
- Djahanguiri, M.N., Wallace, J.L., 1999. Therapeutic potential of nitric oxide donors and inhibitors. *Am. J. Physiol.* 276, 1313–1316.
- Evangelista, S., 2006. Role of sensory neurons in restitution and healing of gastric ulcers. *Curr. Pharm. Des.* 12, 2977–2984.
- Gyires, K., Müllner, K., Rónai, A.Z., 2000. Functional evidence that gastroprotection can be induced by activation of central  $\alpha\beta$ -adrenoceptor subtypes in the rat. *Eur. J. Pharmacol.* 396, 131–135.
- Hamid, R.A., Foong, C.P., Ahmad, Z., Hussain, M.K., 2012. Antinociceptive and anti-ulcerogenic activities of the ethanolic extract of *Annona muricata* leaf. *Braz. J. Pharmacognosy* 22 (3), 630–641.
- Hansen, M.B., 2003. Neurohumoral control of gastrointestinal motility. *Physiol. Res.* 52 (1), 1–30.
- Hayllar, J., Bjarnason, I., 1995. NSAIDs, Cox-2 inhibitors, and the gut. *Lancet* 346, 521–522.
- Hernandes, L.S., 2010. Farmacologia e Fitoquímica dos extratos de *Pothomorphe umbellata* (L.) Miq., direcionadas à atividade antiúlcera (Dissertação de Mestrado). São Paulo.
- Hoffman, B.B., 2007. Fármacos antagonistas dos adrenoceptores. In: Katzung, B.G. (Ed.), *Farmacologia básica e clínica*, tenth ed. McGraw-Hill, São Paulo, pp. 127–141.
- Júnior, F.E.B., Oliveira, D.R., Bento, E.B., Leite, L.H.I., Souza, D.O., Siebra, A.L., Sampaio, R.S., Martins, A.O.P.B., Ramos, A.G.B., Tintino, S.R., Lacerda-Neto, L.J., Figueiredo, P.R.L., Oliveira, L.R., Rodrigues, C.K.S., Sales, V.S., Figueiredo, F.R.S.D.N., Nascimento, E.P., Monteiro, A.B., Amaro, E.N., Costa, J.G.M., Coutinho, H.D.M., Menezes, I.R.A., Kerntopf, M.R., 2013. Antiulcerogenic Activity of the Hydroalcoholic Extract of Leaves of *Croton campestris* A. St.-Hill in Rodents. *Evidence-Based Complementary and Alternative Medicine* 13.
- Junqueira, N.T.V., Oliveira, M.A.S., Icuma, I.M., Ramos, V.H.V., 1999. Cultura da Graviola. In: Silva, J.M.M. (Ed.), *Incentivo à fruticultura no Distrito Federal: Manual de fruticultura*, second ed. OCDF, Brasília.
- Katzung, B.G., Masters, S.B., Trevor, A.J., 2014. *Farmacologia básica e clínica*, 12th ed. Guanabara Koogan, Rio de Janeiro.
- Laine, L., Takeuchi, K., Tarnawski, A., 2008. Gastric mucosal defense and cytoprotection: bench to bedside. *Gastroenterology* 135, 41–60.
- Lapa, A.J. et al., 2008. Plantas medicinais: métodos de avaliação da atividade farmacológica. UNIFESP/EPM, Campinas (p. 144).
- Lima, M.D., 2007. Perfil cromatográfico dos extratos brutos das sementes de *Annona muricata* L. e *Annona squamosa* L. através da cromatografia líquida de alta eficiência (Dissertação de Mestrado). Universidade Federal de Alagoas, Maceió, AL, p. 102.
- Luna, J.S., Carvalho, J.M., Lima, M.R.F., Bieber, L.W., Bento, E.S., Franck, X., Santana, A.E.G., 2006. Acetogenins in *Annona muricata* L. (Annonaceae) leaves are potent molluscicides. *Nat. Prod. Res.* 20 (3), 253–257.
- Matos, F.J.A., 1997. *Introdução à fitoquímica experimental*, second ed. UFC, Fortaleza.
- Matsuda, H., Li, Y., Yoshikawa, M., 1999. Roles of capsaicin-sensitive sensory nerves, endogenous nitric oxide, sulfhydryls and prostaglandins in gastroprotection by momordin Ic, an oleanolic acid oligoglycoside, on ethanol-induced gastric mucosal lesions in rats. *Pharmacol. Lett.* 65 (2), 27–32.
- Mendonça, N.M., Silveira, C., Oliveira, J.M., Sartor, C.F.P., Felipe, D.F., Amaral, V., Cortez, L.E.R., 2013. Avaliação da atividade antiulcerogênica da *Baccharis trimera* (LESS) DC. em Ratos. *Rev. Saúde e Pesquisa* 6 (1), 21–26.
- Mizui, T., Shimono, N., Doteuchi, M., 1987. A possible mechanism of protection by polyamines against gastric damage induced by acidified ethanol in rats: polyamine protection may depend on its antiperoxidative properties. *Jpn. J. Pharmacol.* 44, 43–50.
- Moghadamtousi, S.Z., Rouhollahi, E., Karimian, H., et al., 2014. Gastroprotective activity of *Annona muricata* leaves against ethanol-induced gastric injury in rats via Hsp70/Bax involvement. *Drug Des. Devel. Ther.* 8, 2099–2110.
- Omoja, V.U., Ihedioha, T.E., Eke, G.I., Peter-AJuzie, I.K., Okezie, S.E., 2014. Evaluation of the acute toxicity, phytochemical constituents and anti-ulcer properties of methanolic leaf extract of *Annona muricata* in mice. *J. Intercult. Ethnopharmacol.* 3 (1), 37–43.
- Pan, J.S., He, S.Z., Xu, H.Z., Zhan, X.J., Yang, X.N., Xiao, H.M., Shi, H.X., Ren, J.L., 2008. Oxidative stress disturbs energy metabolism of mitochondria in ethanol-induced gastric mucosa injury. *World J. Gastroenterol.* 14, 5857–5867.
- Park, J.S., Choi, M.A., Kim, B.S., Han, I.S., Kurata, T., Yu, R., 2000. Capsaicin protects against ethanol-induced oxidative injury in the gastric mucosa of rats. *Life Sci.* 67, 3087–3093.
- Parmar, N.S., Parmar, S., 1998. Anti-ulcer potential of flavonoids. *Indian J. Physiol. Pharmacol.* 42 (3), 343–351.
- Rahgozar, M., Pazokitoroudi, H., Bakhtiarani, A., Djahanguiri, B., 2001. Diazoxide, a K(ATP) opener, accelerates restitution of ethanol or indomethacin-induced gastric ulceration in rats independent of polyamines. *J. Gastroen. Hepatol.* 16 (3), 290–296.
- Rang, H.P., Dale, M.M., Ritter, J.M., Flower, R.J., Henderson, G., 2012. *Farmacologia*, seventh ed. Elsevier Editora, Rio de Janeiro.
- Reis, C.N., 2011. *Annona muricata*: análise química e biológica dos frutos de graviola (Dissertação (Mestrado)), Universidade Estadual do Norte Fluminense Darcy Ribeiro. p. 150.
- Robert, A., Nezamis, J.E., Lancaster, C., Hanchar, A.J., 1979. Cytoprotection by prostaglandins in rats: prevention of gastric necrosis produced by alcohol, HCl, NaOH, hypertonic NaCl and thermal injury. *Gastroenterology* 7, 433–443.
- Sakai, H., Kumano, E., Ikari, A., Takeguchi, N., 1995. A gastric housekeeping Cl channel activated via prostaglandin EP3 receptor-mediated  $Ca^{2+}$  nitric oxide/cGMP pathway. *J. Biol. Chem.* 270, 18781–18785.
- Samonina, G.E., Kopylova, G.N., Lukjanzeva, G.V., et al., 2004. Antiulcer effects of amylin: a review. *Pathophysiology* 11 (1), 1–6.
- Singh, J., Kumar-Vr, S., Kadam, V., 2012. Antiulcer activity of *Annona reticulata* leaves extract in rats. *Int. J. Pharm. Pharm. Sci.* 4, 412–414.
- Szolcsanyi, J., Bartho, L., 2001. Capsaicin-sensitive afferents and their role in gastroprotection: an update. *J. Physiol.* 95, 181–188.
- Vásquez, P.F., Mendonça, M.S., Noda, S.N., 2014. Etnobotânica de plantas medicinais em comunidades ribeirinhas do Município de Manacapuru, Amazonas, Brasil. *Acta Amazônica* 44 (4), 457–472.
- Wallace, J.L., 1997. Nonsteroidal anti-inflammatory drugs and gastroenteropathy: the second hundred years. *Gastroenterology* 112 (3), 1000–1016.
- Wallace, J.L., 2001. Mechanisms of protection and healing: current knowledge and future research. *Am. J. Med.* 110, 19–23.
- Wallace, J.L., 2008. Prostaglandins, NSAIDs, and gastric mucosal protection: why doesn't the stomach digest itself? *Physiol. Rev.* 88 (4), 1547–1565.
- Wallace, J.L., Granger, D.N., 1996. The cellular and molecular basis of gastric mucosal defense. *FASEB J.* 10, 731–740.
- Yelken, B. et al., 1999. Clonidine pretreatment inhibits stress-induced gastric ulcer in rats. *Anesthesia & Analgesia* 89, 159–162.
- Zelickson, M.S., Bronder, C.M., Johnson, B.L., Camunas, J.A., Smith, D.E., Rawlinson, D., Von, S., Stone, H.H., Taylor, S.M., 2011. *Helicobacter pylori* is not the predominant etiology for peptic ulcers requiring operation. *Am. Surg.* 77, 1054–1060.
- Zuanazzi, J.A.S., Montanha, J.A., 2004. Flavonóides. In: Simões, C. M.O. et al. (Eds.), *Farmacognosia: da planta ao medicamento*. Editora da UFRGS/Editora da UFSC, Porto Alegre.