



Published in final edited form as:

*J Investig Med.* 2014 October ; 62(7): 927–933. doi:10.1097/JIM.000000000000102.

## Destruction of White Matter Integrity in Patients With Mild Cognitive Impairment and Alzheimer Disease

Xiaoyan Sun, MD, PhD<sup>\*,†,‡,§</sup>, David Salat, PhD<sup>‡,||,¶</sup>, Kristen Upchurch, MD<sup>\*,‡,§</sup>, Rebecca Deason, PhD<sup>\*\*</sup>, Neil Kowall, MD<sup>\*,‡,§</sup>, and Andrew Budson, MD<sup>\*,†,‡,§</sup> for the Alzheimer's Disease Neuroimaging Initiative

<sup>\*</sup>Department of Neurology, Boston, MA

<sup>†</sup>Center for Translational Neuroscience, Boston, MA

<sup>‡</sup>VA Boston Healthcare System, Boston, MA

<sup>§</sup>Boston University School of Medicine, Boston, MA

<sup>||</sup>Neuroimaging Research for Veterans Center, VA Boston Healthcare System, Boston, MA

<sup>¶</sup>Department of Radiology, Athinoula A. Martinos Center for Biomedical Imaging, Massachusetts General Hospital, Charlestown, MA

<sup>\*\*</sup>Department of Psychology, Texas State University, San Marcos, TX

### Abstract

**Background**—Accumulating evidence shows that gradual loss of white matter integrity plays an important role in the development of Alzheimer disease (AD).

**Objective**—The aim of this research was to study the microstructural integrity of white matter in AD in vivo.

**Methods**—Global fractional anisotropy, global axial diffusivity (AxD), and global radial diffusivity (RD) were analyzed in subjects with normal controls (NC), mild cognitive impairment (MCI), and AD using Alzheimer's Disease Neuroimaging Initiative data (total N = 210). We further compared specific white matter tracts among the 3 groups.

**Results**—Compared with the NC group, the MCI group had significantly increased global AxD and global RD. Compared with the NC and MCI groups, the AD group had significantly decreased global fractional anisotropy, increased global AxD, and increased global RD. With regard to specific white matter tracts, in the MCI group, we found increased AxD and increased RD in the external capsule, part of the lateral cholinergic pathway, in addition to the tracts connecting the limbic regions, predominantly in the left hemisphere. In the AD group, white matter abnormalities

Reprints: Xiaoyan Sun, MD, PhD, Department of Neurology, VA Boston Healthcare System, Boston, MA 02130. xysunny@hotmail.com.

Data used in preparation of this article were obtained from the Alzheimer's Disease Neuroimaging Initiative (ADNI) database (adni.loni.usc.edu). As such, the investigators within the ADNI contributed to the design and implementation of ADNI and/or provided data but did not participate in the analysis or writing of this report. A complete listing of ADNI investigators can be found at [http://adni.loni.usc.edu/wpcontent/uploads/how\\_to\\_apply/ADNI\\_Acknowledgement\\_List.pdf](http://adni.loni.usc.edu/wpcontent/uploads/how_to_apply/ADNI_Acknowledgement_List.pdf).

were widespread, including in the external capsule (cholinergic pathway) and limbic region tracts as well as tracts connecting anterior to posterior regions bilaterally.

**Conclusions**—The radiographic manifestation of damaged white matter microstructural integrity in the cholinergic pathway in MCI patients may provide a rational basis for the use of cholinesterase inhibitor drugs in the MCI stage of AD.

### Keywords

diffusion tensor imaging; Alzheimer disease; mild cognitive impairment; fractional anisotropy; axial diffusivity; radial diffusivity; cholinergic pathway

---

Accumulating evidence shows that the gradual loss of morphological and functional integrity of both gray and white matters is evident in brain imaging in the development of Alzheimer disease (AD).<sup>1,2</sup> To dissect the pathophysiological process of AD in vivo, it is necessary to investigate the evolution of anatomic microstructural changes in the brains of AD patients via neuroimaging techniques.

Gray matter atrophy, particularly in vivo hippocampal atrophy, has been extensively characterized in AD patients via magnetic resonance imaging (MRI). In addition, few studies report a significant volume reduction in the cholinergic nuclei of the basal forebrain in the mild cognitive impairment (MCI) and AD patients.<sup>3,4</sup> These gray matter changes are closely associated with the clinical presentation of AD dementia.<sup>5,6</sup> However, in vivo white matter changes in these brain region tracts have been less extensively characterized.<sup>6,7</sup>

There is increasing evidence that white matter pathology plays an important role in the development of AD dementia.<sup>8–10</sup> Because gray matter atrophy and white matter changes are typically found together radiographically in AD dementia, it has been suggested that white matter damage may secondarily result from neuronal loss.<sup>11</sup> In addition, white matter lesions are found independently from atrophic gray matter regions in patients with MCI and AD. This indicates that neurodegeneration may begin in axons and dendrites.<sup>11–14</sup> Given these findings, it is important to explore the role of white matter lesions in the pathogenesis of AD.

Diffusion tensor imaging (DTI) has proven to be a powerful tool to investigate the microstructural integrity of white matter.<sup>15</sup> Fractional anisotropy (FA) and mean diffusivity (MD) are 2 measures of DTI that detect summative directional and random diffusion of water molecules in brain tissue. Component analysis of the diffusion tensor parallel to (axial diffusivity, AxD) and perpendicular to (radial diffusivity, RD) the principal diffusion direction provides more detailed information about white matter tract microstructure.<sup>16</sup> Decreased FA, increased AxD, and increased RD have been reported in selected brain regions in patients with MCI and AD.<sup>6,16–19</sup> However, global microstructural changes of white matter are still under investigation in these patients.<sup>20</sup> Studying the process of white matter disruption in MCI and probable mild AD due to AD pathophysiology will increase our understanding of the mechanisms underlying patients' clinical symptoms as they progress from MCI to AD dementia.

In this study, we investigated how whole-brain white matter microstructural integrity differs among normal controls (NCs) and MCI and AD patients by comparing global FA, AxD, and RD measurements reported in the Alzheimer's Disease Neuroimaging Initiative (ADNI) database. We compared the regional FA, AxD, and RD of 52 tracts of NCs with those of the MCI group and with those of the AD group. On the basis of these comparative analyses, we formulated conclusions about the radiographic manifestation of clinical progression from MCI to mild AD dementia, as a probable evolution of DTI findings from decreased regional microstructural integrity in specific white matter tracts to globally reduced microstructural integrity.

To our knowledge, this study is the largest sample size to date of DTI investigations of MCI and AD dementia. Our study confirms previously described anatomic locations of cerebral white matter abnormalities in MCI and AD dementia. Furthermore, our study extends previous in vivo findings of cholinergic tract abnormalities in MCI and mild AD dementia by demonstrating DTI abnormalities of the external capsule, through which the lateral cholinergic pathway travels. Accumulating evidence of disrupted cholinergic pathway white matter tracts in MCI may provide a rational basis for the use of cholinesterase inhibitor therapy in the MCI stage of AD.

## MATERIALS AND METHODS

### ADNI Study

Data used in this study were obtained from the ADNI database ([adni.loni.usc.edu](http://adni.loni.usc.edu)). The ADNI was launched in 2003 by the National Institute on Aging, the National Institute of Biomedical Imaging and Bioengineering, the Food and Drug Administration, private pharmaceutical companies, and nonprofit organizations. The primary goal of ADNI has been to test whether serial MRI, positron emission tomography, other biological markers, and clinical and neuropsychological assessment can be combined to measure the progression of MCI and early AD. The principal investigator of this initiative is Michael W. Weiner, MD.<sup>21</sup> The ADNI is the result of efforts of many co-investigators from a broad range of academic institutions and private corporations, and subjects have been recruited from more than 50 sites across the United States and Canada. To date, more than 1500 adults, aged 55 to 90 years, have been recruited, consisting of cognitively healthy older individuals, people with early or late MCI, and people with early AD (for up-to-date information, see [www.adni-info.org](http://www.adni-info.org)). In our study, every subject with an initial analysis of DTI data including FA, AxD, and RD was included in this study. Institutional review board approval is obtained at each ADNI site, and informed consent is obtained from each participant or authorized representative. Demographic information was extracted from the ADNI database. There were 60 NCs, 106 MCI subjects, and 44 mild AD subjects.

### Image Process and Analysis

The DTI acquisition and analysis were described by Nir et al.<sup>22</sup> All subjects underwent whole-brain MRI scanning on 3-Tesla GE Medical Systems scanner at 14 acquisition sites across North America. Anatomical T1-weighted sequences and diffusion weighted images were collected. According to the described preprocessing protocol, head motion and eddy

current distortions were corrected. All extracerebral tissues were removed from the T1-weighted anatomical scans. Anatomical scans subsequently underwent intensity inhomogeneity normalization. More details of the preprocessing steps are described by Nir et al.<sup>22</sup>

The FA images from the Johns Hopkins University DTI atlas were registered for each subject based on an elastic registration algorithm.<sup>23</sup> The FA, a measure of the degree of diffusion anisotropy, was calculated from the standard formula. The AxD was defined as the primary (largest) eigenvalue ( $AxD = \lambda_1$ ) and captures the longitudinal diffusivity or the diffusivity parallel to axonal fibers. The RD, which captures the mean diffusivity perpendicular to axonal fibers, was calculated as the mean of the 2 smaller eigenvalues. Tract-based spatial statistics were performed according to the Functional Magnetic Resonance Imaging of the Brain Software Library software package and protocols outlined by the ENIGMA-DTI group.<sup>22,24</sup>

## Statistics

Repeated measures analysis of variance (ANOVA) was performed to compare the global differences across the 3 groups, with follow-up post hoc analyses performed as needed to explain the main effects and interactions. A general linear model with multivariate ANOVA (MANOVA) with post hoc test Bonferroni correction was performed to compare the FA, AxD, and RD of each tract between the groups.  $P < 0.05$  is considered to indicate a statistically significant difference between groups. SPSS (version 20; SPSS Inc., Cary, NC) was used for this statistical analysis.

## RESULTS

### Demographic Information of Study Population

Table 1 shows the demographic information of the subjects. There were no significant differences in age, Modified Hachinski score, and education across the 3 groups. As expected, there was a significant difference in Mini-Mental Status Examination (MMSE) scores across the 3 groups,  $F(2,207) = 150.07$ ,  $P < 0.001$ ,  $\eta^2 = 0.769$ . The mean MMSE score in the patients with AD was 23, consistent with mild AD dementia.

### Global Decreased FA, Increased AxD, and Increased RD in MCI and AD Patients Compared With Controls

Figure 1A shows the comparison of global FA among the NCs, MCI patients, and AD patients. There was a significant difference in global FA across the 3 groups,  $F(2,207) = 10.67$ ,  $P < 0.001$ ,  $\eta^2 = 0.093$ . Post hoc analysis showed that global FA was significantly decreased in the AD group compared with the NCs and the MCI group ( $P < 0.001$  and  $P = 0.002$ ). There was no significant difference in global FA between the controls and the MCI patients ( $P = 0.162$ ).

Figure 1B shows the comparison of global RD among the 3 groups. There was a significant difference in global RD across the 3 groups,  $F(2,207) = 16.25$ ,  $P < 0.001$ ,  $\eta^2 = 0.136$ . Post hoc analysis showed that global RD was significantly increased in the AD group compared

with the NCs and the MCI group ( $P < 0.001$  and  $P = 0.001$ ). There was a significant difference in global RD between the controls and the MCI patients ( $P = 0.012$ ).

Figure 1C shows the comparison of global AxD among the 3 groups. There was a significant difference in global AxD across the 3 groups,  $F(2,207) = 16.85$ ,  $P < 0.001$ ,  $\eta^2 = 0.140$ . Post hoc analysis showed that global AxD was significantly increased in the AD group compared with the NCs and the MCI group ( $P < 0.001$  and  $P = 0.001$ ). There was a significant difference in global AxD between the controls and the MCI patients ( $P = 0.009$ ).

### **Gradual Loss of White Matter Microstructural Integrity in the MCI and AD Patients Compared With Controls**

Next, a linear model of MANOVA was conducted to compare differences in the regional FA, RD, and AxD of 52 specific axonal tracts across the 3 groups.

#### **Decreased FA in the MCI and AD Patients**

A MANOVA revealed a significant multivariate main effect in FA for the diagnosis (normal vs MCI vs AD), Pillai trace = 0.67,  $F(104, 314) = 1.525$ ,  $P = 0.003$ ,  $\eta^2 = 0.336$ . The post hoc tests were performed to compare the regional FA of each specific axonal tract between NCs and MCI patients as well as between the NC and AD groups (Tables 2 and 3).

In the MCI patients, we found significantly decreased regional FA in a few specific tracts: bilateral fornices, left tapetum, left fornix (crus)/stria terminalis, and left splenium of corpus callosum. In contrast, in the AD patients, we found widespread destruction of white matter microstructural integrity in multiple specific tracts. Compared with the NCs, FA is significantly decreased in the AD patients in the following bilateral tracts: tapetum, fornix (crus)/stria terminalis, fornix, splenium of corpus callosum, genu of corpus callosum, body of corpus callosum, cingulum (hippocampus), cingulum, anterior corona radiata, posterior thalamic radiation, superior fronto-occipital fasciculus, inferior fronto-occipital fasciculus, cerebral peduncle, sagittal striatum, and anterior limb of the internal capsule. The FA was also significantly decreased in the AD in the right medial lemniscus.

#### **Increased RD in the MCI and AD Patients**

A MANOVA revealed a significant multivariate main effect for the diagnosis (normal vs MCI vs AD) in RD, Pillai trace = 0.67,  $F(104, 314) = 1.529$ ,  $P = 0.003$ ,  $\eta^2 = 0.336$ . The post hoc tests were performed to compare the regional RD of each specific axonal tract between NCs and MCI patients as well as between the NC and AD groups (Tables 2 and 3).

In the MCI patients, we found significantly increased regional RD in the following specific tracts: bilateral tapetum, bilateral fornix (crus)/stria terminalis, bilateral fornices, bilateral splenium of corpus callosum, bilateral retrolenticular part of the internal capsule, bilateral external capsule (Fig. 2), bilateral uncinate fasciculus, the left cingulum (hippocampus), left sagittal stratum, left posterior thalamic radiation, the left inferior fronto-occipital fasciculus, left superior corona radiata, and right posterior limb of the internal capsule.

In the AD patients, compared with the NCs, RD was significantly increased in the following bilateral tracts: tapetum, fornix (crus)/stria terminalis, fornix, splenium of corpus callosum,

genu of corpus callosum, body of corpus callosum, cingulum (hippocampus), cingulum, anterior corona radiata, superior fronto-occipital fasciculus, inferior fronto-occipital fasciculus, superior corona radiata posterior corona radiata, posterior thalamic radiation, sagittal striatum, anterior limb of the internal capsule, bilateral external capsule (Fig. 2), and posterior limb of the internal capsule. The RD was also significantly increased in the AD patients in the following unilateral tracts: left cerebral peduncle and left superior longitudinal fasciculus.

### Increased AxD in the MCI and AD Patients

A MANOVA revealed a significant multivariate main effect in AxD for the diagnosis (MCI vs AD), Pillai trace = 0.62,  $F(104, 314) = 1.377$ ,  $P = 0.019$ ,  $\eta^2 = 0.313$ . The post hoc tests were performed to compare the regional AxD of each specific axonal tract between NCs and MCI patients as well as between the NC and AD dementia groups (Tables 2 and 3).

In the MCI patients, we found significantly increased regional AxD in these tracts: bilateral fornix (crus)/stria terminalis, bilateral fornices, bilateral splenium of corpus callosum, bilateral retrolenticular part of the internal capsule, bilateral external capsule (Fig. 2), bilateral sagittal stratum, left tapetum, left cingulum (hippocampus), left superior longitudinal fasciculus, left posterior thalamic radiation, left body of corpus callosum, left genu of corpus callosum, left tapetum, left superior corona radiata, left posterior limb of the internal capsule, and right inferior fronto-occipital fasciculus.

In the AD patients, compared with the NCs, AxD was significantly increased in these bilateral tracts: tapetum, fornix (crus)/stria terminalis, fornices, splenium of corpus callosum, genu of corpus callosum, body of corpus callosum, cingulum (hippocampus), cingulum, anterior corona radiata, superior corona radiata, posterior corona radiata, superior fronto-occipital fasciculus, inferior fronto-occipital fasciculus, posterior thalamic radiation, sagittal striatum, posterior limb of the internal capsule, retrolenticular part of the internal capsule, bilateral external capsule (Fig. 2), and uncinata fasciculus. The AxD was also significantly increased in the AD patients in the left posterior limb of the internal capsule.

## DISCUSSION

Although postmortem studies of white matter changes in AD have been reported for decades,<sup>25–28</sup> investigation of white matter microstructure in vivo only became possible after the development of DTI.<sup>19</sup> Many studies using DTI have focused on changes in white matter in selected brain regions rather than on the global microstructural integrity of cerebral white matter.<sup>29–32</sup> Studying white matter disruption in MCI and AD dementia may advance our understanding of the mechanisms underlying patients' clinical symptoms as a subset progresses from MCI to AD.

In this study, we report decreased global FA, increased global RD, and increased global AxD in AD dementia patients compared with MCI patients and NCs, using ADNI data. We did not find a significant decrease in global FA in MCI patients compared with NCs, consistent with previous findings.<sup>20</sup> With regard to diffusivity, increased global RD and global AxD were readily found in MCI patients compared with controls in our study. One possible

explanation is that FA is a less sensitive method for the detection of early AD pathology, as reported by other studies.<sup>17,22</sup> However, our results can also be interpreted as clinically meaningful. The reduced global FA of white matter in AD dementia patients may be the radiographic representation of dementia. In line with this interpretation, a significant correlation between measures of white matter abnormality and dementia severity has been reported by others. Our results, along with those of other investigators, suggest that it may be possible to use quantitative radiographic measures of white matter destruction as surrogate markers for monitoring the clinical progression of AD.<sup>33,34</sup>

In this study, we also investigated DTI measures of specific white matter tracts in AD dementia and MCI. Our study extends previous *in vivo* findings of cholinergic tract white matter abnormalities in MCI and AD dementia.<sup>3,4,35–38</sup> To our knowledge, this is the first report of increased RD and AxD in the external capsule in MCI and AD dementia patients. The external capsule and uncinate fasciculus comprise the capsular division of the lateral cholinergic pathway. The capsular division of the lateral cholinergic pathway innervates frontal, parietal, and temporal neocortices.<sup>39</sup> The finding of damage in the lateral cholinergic pathway in MCI and AD dementia is consistent with AD pathology, given that degeneration of cholinergic neurons of the basal forebrain is a distinctive neuropathological feature of AD.

Evidence of damage to the cholinergic pathway in MCI patients is supportive of early medical intervention with cholinesterase inhibitors in the MCI stage of AD in clinical practice. In Likitjaroen and colleagues'<sup>40</sup> longitudinal randomized, placebo-controlled, double-blinded study of AD patients treated with the cholinesterase inhibitor galantamine, increased FA was found in AD dementia patients after 6 months of treatment with galantamine. In contrast, the AD dementia patients who received placebo had decreased FA in the posterior part of corpus callosum at the 6-month point of the study.<sup>41</sup> Such findings suggest that DTI measurements such as RD and AxD could potentially be used to monitor AD patients' response to treatment with cholinesterase inhibitors.

Congruent with previously published studies, in the MCI patients, we found decreased FA, increased RD, and increased AxD in association fibers and commissural fibers involving the corpus callosum, hippocampus, and amygdala. White matter tracts associated with the hippocampus and the amygdala form part of the Papez circuit,<sup>42,43</sup> and damage to the Papez circuit is known to be linked to episodic memory impairment.<sup>44</sup> Therefore, the *in vivo* radiographic finding of reduced FA and increased diffusivity in specific white matter tracts associated with the Papez circuit is consistent with the clinical presentation of MCI due to the AD pathophysiologic process.

In addition, our finding of reduced FA and increased diffusivity in the splenium of the corpus callosum in MCI patients is consistent with the postulation that the pathophysiological process of AD is partially a disconnection syndrome.<sup>45</sup> In AD dementia patients, we found widespread reduced FA and increased diffusivity, indicating a general disruption of connectivity not seen in the MCI patients. Disconnection of neuroanatomic structures due to damaged white matter tracts may be one of the mechanisms underlying the clinical presentation of the initial stage of AD.<sup>46</sup>

In this study, we observed the following pattern of damaged white matter tracts in AD: (1) in both the MCI and AD dementia patients, when the damage to white matter tracts is unilateral, the damaged tracts are more often in the left hemisphere than in the right. Of relevance to this finding, Thompson and colleagues<sup>47</sup> demonstrated that gray matter loss in AD is more prominent in the left hemisphere than in the right. (2) Damaged white matter tracts are limited primarily to the limbic region in the MCI patients, in contrast to the AD dementia patients, in whom damaged white matter tracts extend from the limbic region to the thalamic and cortical regions, consistent with the results of other published studies.<sup>19</sup> (3) In the MCI patients, damaged white matter tracts are found primarily in posterior brain regions, whereas in the AD dementia patients, they are also found in the anterior and lateral brain regions. (4) Regarding fiber classification, association fibers and commissural fibers are damaged in the MCI patients, whereas in the AD dementia patients, there are also abnormalities in some projection fibers. All together, this anatomic pattern of white matter changes measured by FA and directional diffusivity may represent a temporal clinical progression from predementia to dementia in AD.<sup>48,49</sup>

The limitations of our study include the following. First, because this is a cross-sectional study, we are not able to use DTI to elucidate dynamic changes in AD progression, and the role of DTI in predicting disease evolution remains unknown. Second, in this study, we do not have data showing the relationship between white matter and gray matter in cerebral regions affected in AD. Further study of the relationship between white matter and gray matter changes could provide insights into the mechanisms of neurodegeneration underlying clinical manifestations of the AD pathophysiologic process. Understanding the role of damaged white matter in the development of AD clinically and pathophysiologically may lead to the identification of new targets for treatment.

## Acknowledgments

Supported by VA Special Fellowships in Advanced Geriatrics (salary for Dr Sun and Dr Upchurch). The infrastructure for this work was provided by the VA Boston Healthcare System and by Boston University Alzheimer's Disease Center (which is funded by the National Institutes of Health [NIH]). Data collection and sharing for this project were funded by the ADNI (National Institutes of Health Grant U01 AG024904) and DOD ADNI (Department of Defense Award Number W81XWH-12-2-0012). The ADNI is funded by the National Institute on Aging and the National Institute of Biomedical Imaging and Bioengineering and through generous contributions from the following: Alzheimer's Association; Alzheimer's Drug Discovery Foundation; BioClinica, Inc; Biogen Idec, Inc; Bristol-Myers Squibb Company; Eisai, Inc; Elan Pharmaceuticals, Inc; Eli Lilly and Company; F. Hoffmann-La Roche Ltd and its affiliated company Genentech, Inc; GE Healthcare; Innogenetics, NV; IXICO Ltd; Janssen Alzheimer Immunotherapy Research & Development, LLC; Johnson & Johnson Pharmaceutical Research & Development LLC; Medpace, Inc; Merck & Co, Inc; Meso Scale Diagnostics, LLC; NeuroRx Research; Novartis Pharmaceuticals Corporation; Pfizer, Inc; Piramal Imaging; Servier; Synarc, Inc; and support ADNI clinical sites in Canada. Private sector contributions are facilitated by the Foundation for the Takeda Pharmaceutical Company. The Canadian Institutes of Health Research is providing funds to the NIH ([www.fnih.org](http://www.fnih.org)). The grantee organization is the Northern California Institute for Research and Education, and the study is coordinated by the Alzheimer's Disease Cooperative Study at the University of California, San Diego. The VADNI data are disseminated by the Laboratory for Neuro Imaging at the University of Southern California.

## References

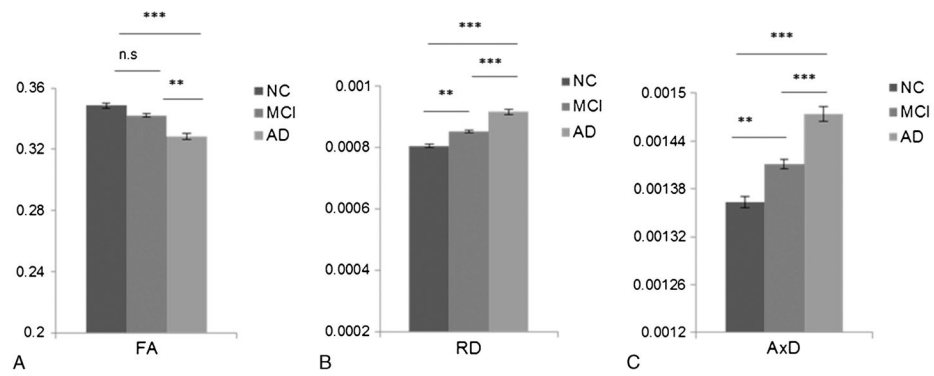
1. Kantarci K. Magnetic resonance markers for early diagnosis and progression of Alzheimer's disease. *Expert Rev Neurother*. 2005; 5:663–670. [PubMed: 16162090]



2. Stout JC, Jernigan TL, Archibald SL, et al. Association of dementia severity with cortical gray matter and abnormal white matter volumes in dementia of the Alzheimer type. *Arch Neurol.* 1996; 53:742–749. [PubMed: 8759980]
3. Kilimann I, Grothe M, Heinsen H, et al. Subregional basal forebrain atrophy in Alzheimer's disease: a multicenter study. *J Alzheimers Dis.* 2014; 40:687–700. [PubMed: 24503619]
4. Teipel SJ, Meindl T, Grinberg L, et al. The cholinergic system in mild cognitive impairment and Alzheimer's disease: an in vivo MRI and DTI study. *Hum Brain Mapp.* 2011; 32:1349–1362. [PubMed: 20672311]
5. Schliebs R, Arendt T. The significance of the cholinergic system in the brain during aging and in Alzheimer's disease. *J Neural Transm.* 2006; 113:1625–1644. [PubMed: 17039298]
6. Teipel SJ, Grothe M, Lista S, et al. Relevance of magnetic resonance imaging for early detection and diagnosis of Alzheimer disease. *Med Clin North Am.* 2013; 97:399–424. [PubMed: 23642578]
7. Masdeu JC, Kreisl WC, Berman KF. The neurobiology of Alzheimer disease defined by neuroimaging. *Curr Opin Neurol.* 2012; 25:410–420. [PubMed: 22766722]
8. Chevalier-Larsen E, Holzbaur EL. Axonal transport and neurodegenerative disease. *Biochim Biophys Acta.* 2006; 1762:1094–1108. [PubMed: 16730956]
9. Gold BT, Johnson NF, Powell DK, et al. White matter integrity and vulnerability to Alzheimer's disease: preliminary findings and future directions. *Biochim Biophys Acta.* 2012; 1822:416–422. [PubMed: 21803153]
10. Stokin GB, Lillo C, Falzone TL, et al. Axonopathy and transport deficits early in the pathogenesis of Alzheimer's disease. *Science.* 2005; 307:1282–1288. [PubMed: 15731448]
11. Agosta F, Pievani M, Sala S, et al. White matter damage in Alzheimer disease and its relationship to gray matter atrophy. *Radiology.* 2011; 258:853–863. [PubMed: 21177393]
12. Canu E, McLaren DG, Fitzgerald ME, et al. Microstructural diffusion changes are independent of macrostructural volume loss in moderate to severe Alzheimer's disease. *J Alzheimers Dis.* 2010; 19:963–976. [PubMed: 20157252]
13. Salat DH, Tuch DS, van der Kouwe AJ, et al. White matter pathology isolates the hippocampal formation in Alzheimer's disease. *Neurobiol Aging.* 2010; 31:244–256. [PubMed: 18455835]
14. Stricker NH, Salat DH, Foley JM, et al. Decreased white matter integrity in neuropsychologically defined mild cognitive impairment is independent of cortical thinning. *J Int Neuropsychol Soc.* 2013; 19:925–937. [PubMed: 23809097]
15. Oishi K, Mielke MM, Albert M, et al. DTI analyses and clinical applications in Alzheimer's disease. *J Alzheimers Dis.* 2011; 26(suppl 3):287–296. [PubMed: 21971468]
16. Bosch B, Arenaza-Urquijo EM, Rami L, et al. Multiple DTI index analysis in normal aging, amnesic MCI and AD. Relationship with neuropsychological performance. *Neurobiol Aging.* 2012; 33:61–74. [PubMed: 20371138]
17. Boespflug EL, Storrs J, Sadat-Hossieny S, et al. Full diffusion characterization implicates regionally disparate neuropathology in mild cognitive impairment. *Brain Struct Funct.* 2014; 219:367–379. [PubMed: 23344962]
18. Clerx L, Visser PJ, Verhey F, et al. New MRI markers for Alzheimer's disease: a meta-analysis of diffusion tensor imaging and a comparison with medial temporal lobe measurements. *J Alzheimers Dis.* 2012; 29:405–429. [PubMed: 22330833]
19. Sexton CE, Kalu UG, Filippini N, et al. A meta-analysis of diffusion tensor imaging in mild cognitive impairment and Alzheimer's disease. *Neurobiol Aging.* 2011; 32:2322, e5–e18.
20. Douaud G, Jbabdi S, Behrens TE, et al. DTI measures in crossing-fibre areas: increased diffusion anisotropy reveals early white matter alteration in MCI and mild Alzheimer's disease. *Neuroimage.* 2011; 55:880–890. [PubMed: 21182970]
21. Weiner MW, Veitch DP, Aisen PS, et al. The Alzheimer's Disease Neuroimaging Initiative: a review of papers published since its inception. *Alzheimers Dement.* 2012; 8:S1–S68. [PubMed: 22047634]
22. Nir TM, Jahanshad N, Villalon-Reina JE, et al. Effectiveness of regional DTI measures in distinguishing Alzheimer's disease, MCI, and normal aging. *Neuroimage Clin.* 2013; 3:180–195. [PubMed: 24179862]

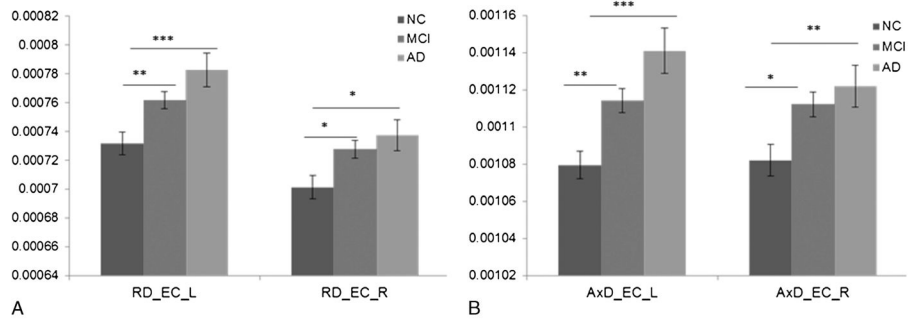
23. Mori S, Oishi K, Jiang H, et al. Stereotaxic white matter atlas based on diffusion tensor imaging in an ICBM template. *Neuroimage*. 2008; 40:570–582. [PubMed: 18255316]
24. Smith SM, Jenkinson M, Johansen-Berg H, et al. Tract-based spatial statistics: voxelwise analysis of multi-subject diffusion data. *Neuroimage*. 2006; 31:1487–1505. [PubMed: 16624579]
25. Brun A, Englund E. A white matter disorder in dementia of the Alzheimer type: a pathoanatomical study. *Ann Neurol*. 1986; 19:253–262. [PubMed: 3963770]
26. Englund E, Brun A, Alling C. White matter changes in dementia of Alzheimer's type. Biochemical and neuropathological correlates. *Brain*. 1988; 111(Pt 6):1425–1439. [PubMed: 3208064]
27. Sjobeck M, Haglund M, Englund E. Decreasing myelin density reflected increasing white matter pathology in Alzheimer's disease—a neuropathological study. *Int J Geriatr Psychiatry*. 2005; 20:919–926. [PubMed: 16163742]
28. Kowall NW, Kosik KS. Axonal disruption and aberrant localization of tau protein characterize the neuropil pathology of Alzheimer's disease. *Ann Neurol*. 1987; 22:639–643. [PubMed: 3122646]
29. Stahl R, Dietrich O, Teipel SJ, et al. White matter damage in Alzheimer disease and mild cognitive impairment: assessment with diffusion-tensor MR imaging and parallel imaging techniques. *Radiology*. 2007; 243:483–492. [PubMed: 17456872]
30. Sydykova D, Stahl R, Dietrich O, et al. Fiber connections between the cerebral cortex and the corpus callosum in Alzheimer's disease: a diffusion tensor imaging and voxel-based morphometry study. *Cereb Cortex*. 2007; 17:2276–2282. [PubMed: 17164468]
31. Teipel SJ, Stahl R, Dietrich O, et al. Multivariate network analysis of fiber tract integrity in Alzheimer's disease. *Neuroimage*. 2007; 34:985–995. [PubMed: 17166745]
32. Zimny A, Szewczyk P, Trypka E, et al. Multimodal imaging in diagnosis of Alzheimer's disease and amnesic mild cognitive impairment: value of magnetic resonance spectroscopy, perfusion, and diffusion tensor imaging of the posterior cingulate region. *J Alzheimers Dis*. 2011; 27:591–601. [PubMed: 21841260]
33. Fjell AM, Amlien IK, Westlye LT, et al. Mini-mental state examination is sensitive to brain atrophy in Alzheimer's disease. *Dement Geriatr Cogn Disord*. 2009; 28:252–258. [PubMed: 19786777]
34. Heo JH, Lee ST, Kon C, et al. White matter hyperintensities and cognitive dysfunction in Alzheimer disease. *J Geriatr Psychiatry Neurol*. 2009; 22:207–212. [PubMed: 19433863]
35. Behl P, Bocti C, Swartz RH, et al. Strategic subcortical hyperintensities in cholinergic pathways and executive function decline in treated Alzheimer patients. *Arch Neurol*. 2007; 64:266–272. [PubMed: 17296844]
36. Bocti C, Swartz RH, Gao FQ, et al. A new visual rating scale to assess strategic white matter hyperintensities within cholinergic pathways in dementia. *Stroke*. 2005; 36:2126–2131. [PubMed: 16179569]
37. Kim HJ, Moon WJ, Han SH. Differential cholinergic pathway involvement in Alzheimer's disease and subcortical ischemic vascular dementia. *J Alzheimers Dis*. 2013; 35:129–136. [PubMed: 23364137]
38. Medina D, DeToledo-Morrell L, Urresta F, et al. White matter changes in mild cognitive impairment and AD: a diffusion tensor imaging study. *Neurobiol Aging*. 2006; 27:663–672. [PubMed: 16005548]
39. Selden NR, Gitelman DR, Salamon-Murayama N, et al. Trajectories of cholinergic pathways within the cerebral hemispheres of the human brain. *Brain*. 1998; 121(Pt 12):2249–2257. [PubMed: 9874478]
40. Likitjaroen Y, Meindl T, Friese U, et al. Longitudinal changes of fractional anisotropy in Alzheimer's disease patients treated with galantamine: a 12-month randomized, placebo-controlled, double-blinded study. *Eur Arch Psychiatry Clin Neurosci*. 2012; 262:341–350. [PubMed: 21818628]
41. Kilimann I, Likitjaroen Y, Hampel H, et al. Diffusion tensor imaging to determine effects of antidementia treatment on cerebral structural connectivity in Alzheimer's disease. *Curr Pharm Des*. 2013; 19:6416–6425. [PubMed: 23432714]
42. Shah A, Jhavar SS, Goel A. Analysis of the anatomy of the Papez circuit and adjoining limbic system by fiber dissection techniques. *J Clin Neurosci*. 2012; 19:289–298. [PubMed: 22209397]

43. Triarhou LC. Centenary of Christfried Jakob's discovery of the visceral brain: an unheeded precedence in affective neuroscience. *Neurosci Biobehav Rev.* 2008; 32:984–1000. [PubMed: 18479750]
44. Hornberger M, Wong S, Tan R, et al. In vivo and post-mortem memory circuit integrity in frontotemporal dementia and Alzheimer's disease. *Brain.* 2012; 135:3015–3025. [PubMed: 23012333]
45. Reid AT, Evans AC. Structural networks in Alzheimer's disease. *Eur Neuropsychopharmacol.* 2013; 23:63–77. [PubMed: 23294972]
46. Delbeuck X, Van der Linden M, Collette F. Alzheimer's disease as a disconnection syndrome? *Neuropsychol Rev.* 2003; 13:79–92. [PubMed: 12887040]
47. Thompson PM, Hayashi KM, de Zubicaray G, et al. Dynamics of gray matter loss in Alzheimer's disease. *J Neurosci.* 2003; 23:994–1005. [PubMed: 12574429]
48. Alves GS, O'Dwyer L, Jurcoane A, et al. Different patterns of white matter degeneration using multiple diffusion indices and volumetric data in mild cognitive impairment and Alzheimer patients. *PLoS One.* 2012; 7:e52859. [PubMed: 23300797]
49. Zhang Y, Schuff N, Jahng GH, et al. Diffusion tensor imaging of cingulum fibers in mild cognitive impairment and Alzheimer disease. *Neurology.* 2007; 68:13–19. [PubMed: 17200485]



**FIGURE 1.**

Significantly decreased global FA, increased global RD, and global AxD in the MCI and AD patients compared with the NCs. Comparison of global FA, RD, and AxD among the 3 groups. A, Global FA is significantly reduced in the AD group compared with the NC and MCI groups. No significant difference of FA between the NC and MCI groups is observed. B, Global RD is significantly increased in the AD and MCI groups compared with the NC group. C, The global AxD is significantly increased in the AD and MCI groups compared with the NC group. Error bar represents mean (SEM).



**FIGURE 2.**

Increased RD and AxD of the external capsule (EC) in the MCI and AD patients compared with the NCs. A, Comparison of RD of the left and right external capsule between the MCI patients and NCs as well as between the AD patients and NCs. B, Comparison of AxD of the left and right EC between the MCI patients and NCs as well as between the AD patients and NCs. Error bar represents mean (SEM). \* $P < 0.05$ , † $P < 0.01$ , ‡ $P < 0.001$ .

**TABLE 1**

## Demographic Information of the Subjects

	NCs (n = 60), Mean (SD)	MCI (n = 106), Mean (SD)	AD (n = 44), Mean (SD)	<i>P</i>
Age, y	72.9 (6.0)	73.4 (6.6)	75.8 (8.2)	0.076
Gender (female), %	53	39	34	Not applicable
Education, y	16.7 (3.2)	16.1 (3.2)	15.3 (3.0)	0.079
MMSE	28.8 (1.3)	27.8 (1.8)	23.0 (2.2)	<0.001
MODHACH	0.6 (0.6)	0.8 (0.8)	0.6 (0.7)	0.061

MMSE indicates Mini-Mental State Examination; MODHACH, Modified Hachinski Ischemic score.

Mean (SD) is reported in age, education, MMSE, and MODHACH. Gender is reported as percentage.

**TABLE 2**  
 Comparison of FA, RD, and AxD in the Left Hemisphere Tracts Between NCs and MCI as Well as NCs and AD

	MCI			AD		
	FA	RD	AxD	FA	RD	AxD
Formix (crus)/stria terminalis	†	†	†	†	†	†
Formix	†	†	†	†	†	†
Splenium of corpus callosum	*	†	†	†	†	†
Tapetum	*	†	†	†	†	†
Cingulum (hippocampus)	†	†	†	†	†	†
Posterior thalamic radiation	*	†	†	†	†	†
Genu of corpus callosum	†	†	†	†	†	†
Body of corpus callosum	†	†	†	†	†	†
Retrolenticular part of the internal capsule	*	†	†	†	†	†
Sagittal stratum	*	*	*	†	†	†
External capsule	†	†	†	†	†	†
Uncinate fasciculus	*			†	†	†
Superior fronto-occipital fasciculus				†	†	†
Inferior fronto-occipital fasciculus	*			†	†	†
Cingulum		*	*	†	†	†
Superior corona radiata	*		†	†	†	†
Posterior corona radiata				†	†	†
Anterior corona radiata				†	†	†
Cerebral peduncle				†	*	†
Anterior limb of the internal capsule				†	†	†
Posterior limb of the internal capsule			*		*	†
Superior longitudinal fasciculus			*		*	†
Medial lemniscus						
Superior cerebellar peduncle						
Corticospinal tract						
Inferior cerebellar peduncle						

Comparison of FA, RD, and AxD in 26 tracts of the left hemisphere between the MCI patients and NCs as well as between the AD patients and NCs.

\*  $P < 0.05$ ,  
†  $P < 0.01$ ,  
‡  $P < 0.001$ .

Author Manuscript

Author Manuscript

Author Manuscript

Author Manuscript



**TABLE 3**  
 Comparison of FA, RD, and AxD in the Right Hemisphere Tracts Between NCs and MCI as Well as NCs and AD

	MCI			AD		
	FA	RD	AxD	FA	RD	AxD
Formix (crus)/stria terminalis		*	*	†	†	†
Formix	*	†	*	†	†	†
Splenium of corpus callosum	*	*	*	†	†	†
Tapetum		*	*	†	†	†
Cingulum (hippocampus)				†	†	†
Posterior thalamic radiation				†	†	†
Genu of corpus callosum (L)				†	†	†
Body of corpus callosum (L)				†	†	†
Retrolenticular part of the internal capsule		*	†		†	†
Sagittal stratum		†		*	†	†
External capsule		*	*		*	†
Uncinate fasciculus (L)		*	*		†	†
Superior fronto-occipital fasciculus				†	†	†
Inferior fronto-occipital fasciculus			*	†	†	†
Cingulum				*	†	†
Superior corona radiata				†	†	†
Posterior corona radiata				*	*	†
Anterior corona radiata				†	†	†
Cerebral peduncle				†		
Anterior limb of the internal capsule				†	†	
Posterior limb of the internal capsule		*			*	†
Superior longitudinal fasciculus						†
Medial lemniscus					*	
Superior cerebellar peduncle						
Corticospinal tract						
Inferior cerebellar peduncle						

Comparison of FA, AD, and AxD in 26 tracts of the right hemisphere between the MCI patients and NCs as well as between the AD patients and NCs.

\*  $P < 0.05$ ,  
†  $P < 0.01$ ,  
‡  $P < 0.001$ .

Author Manuscript

Author Manuscript

Author Manuscript

Author Manuscript