

# Complete resolution of left atrial appendage thrombosis with oral dabigatran etexilate in a patient with Myotonic Dystrophy type 1 and atrial fibrillation

ANNA RAGO<sup>1</sup>, ANDREA ANTONIO PAPA<sup>1,2</sup>, GIULIA ARENA<sup>3</sup>, MARCO MOSELLA<sup>4</sup>, ANTONIO CASSESE<sup>1</sup>, ALBERTO PALLADINO<sup>2</sup> AND PAOLO GOLINO<sup>1</sup>

<sup>1</sup> Department of Cardiology, University of Campania "L. Vanvitelli", Monaldi Hospital, Naples, Italy; <sup>2</sup> Cardiomyology and Medical Genetics, University Hospital "L. Vanvitelli", Naples, Italy; <sup>3</sup> Department of Cardiology, Umberto I Hospital, Nocera, Salerno, Italy; <sup>4</sup> Division of Pneumology, Department of Clinical Medicine and Surgery, "Federico II" University, Monaldi Hospital, Naples, Italy

**Myotonic Dystrophy type 1 (DM1) is the most common muscular dystrophy in adult life characterized by muscle dysfunction and cardiac conduction abnormalities. Atrial fibrillation frequently occurs in DM1 patients. It's related to the discontinuous and inhomogeneous propagation of sinus impulses and to the prolongation of atrial conduction time, caused by progressive fibrosis and fatty replacement of the myocardium. AF predisposes to a hyper-coagulable state and to an increased risk of thromboembolism. We report the first case of complete resolution of left atrial appendage thrombosis with oral dabigatran etexilate in a myotonic dystrophy type I patient with atrial fibrillation scheduled for transesophageal echocardiogram-guided direct current cardioversion.**

**Key-words:** myotonic dystrophy, atrial fibrillation, dabigatran etexilate, atrial thrombus

## Introduction

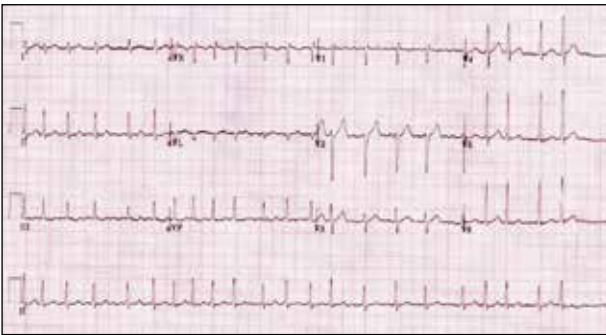Myotonic dystrophy type 1 (DM1) is the most common muscular dystrophy in adult life with an incidence of 1:8000 births and a worldwide prevalence ranging from 2.1 to 14.3/100.000 inhabitants. Cardiac involvement is noticed in about 80% of cases, and it often precedes the skeletal muscle one (1). Paroxysmal atrial arrhythmias (atrial fibrillation, atrial flutter, atrial tachycardia) frequently occur in DM1 patients with a prevalence up to 25% (2) and seem to increase mortality in this popula-

tion (3). Modern pacemakers (PMs) and implantable cardiac defibrillators (ICDs) include detailed algorithms and functions to facilitate the diagnosis and management of frequent paroxysmal atrial tachy-arrhythmias often undetected during conventional clinical follow-up (4-11). Atrial fibrillation (AF) predisposes to a hypercoagulable state and an increased risk of thromboembolism (TE) (12, 13). The incidence of left atrial appendage thrombosis before direct current cardioversion (DCC) has been widely studied in AF population, ranging from 6 to 18% (14, 15). Non-Vitamin K Antagonist oral anticoagulants (NOAC) are increasingly used for the prevention and treatment of thrombi formation owing to the inherent limitations of Vitamin K antagonist oral anticoagulants (VKAs) (16). We report the first case of a left atrial appendage thrombosis effectively treated by dabigatran etexilate, a direct inhibitor of thrombin, in a DM1 patient with AF scheduled for transesophageal echocardiogram (TEE)-guided direct current cardioversion (DCC).

## Case report

A 45-year-old DM1 woman with arterial hypertension, previously implanted with a dual chambers pacemaker for advanced atrioventricular block, came to our observation for PM check and cardiologic therapy optimization before cataract surgery. She was taking perindopril (4 mg/die) and magnesium pidolate (2.25 g/die).

She referred a recent onset of palpitations and dyspnea. Standard (12-lead electrocardiogram) ECG confirmed the diagnosis of atrial fibrillation with a mean ventricular rate of 160 bpm (Fig. 1). PM interrogation showed atrial high rate electrograms (AHRE) faster than 220 bpm, that lasted longer than 5 minutes with irregularity and incoherence of RR intervals (Fig. 2) and arose five days before the cardiologic evaluation. Transthoracic echocardiogram showed a slightly reduced left ventricular systolic function (Simpson's biplane ejection fraction: 48%) and a mild left atrial enlargement (left atrial volume index: 29 mL/m<sup>2</sup>). Considering the patients' symptoms and the need to restore sinus rhythm before surgical procedure, a TEE-guided DCC was performed, which showed the presence of a thrombus in left atrial appendage (Fig. 3). The patient started a beta-blocker therapy for rate control (bisoprolol 2.5 mg/die) and oral anticoagulant therapy (warfarin 5 mg/die) to dissolve the thrombus and prevent

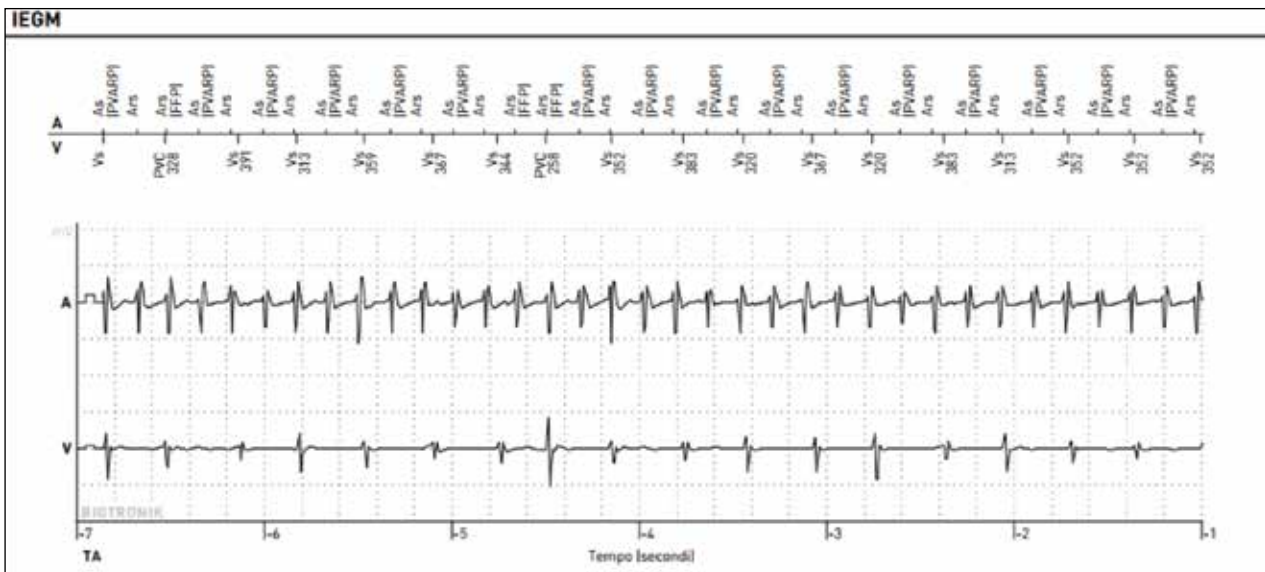


**Figure 1.** Atrial fibrillation detected by standard 12-lead electrocardiogram.

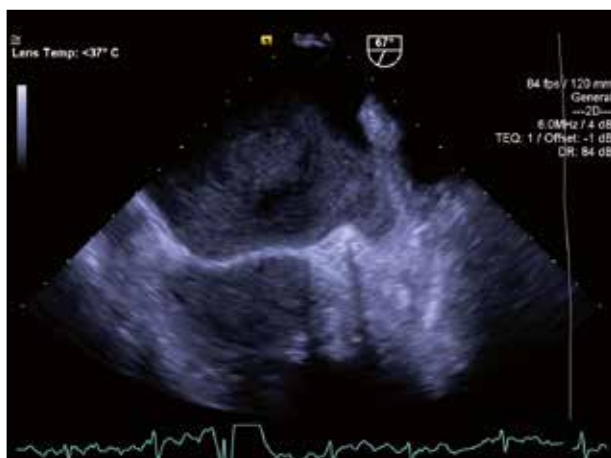the risk of systemic thrombo-embolic events. However, at one-month follow-up, due to a non-optimal response to warfarin therapy, evaluated by the International Normalized Ratio (INR) of the prothrombin time, a switch from VKA to NOAC therapy with dabigatran was performed at a dosage of 150 mg/bid. Eight weeks after, TEE revealed the complete resolution of the left atrial appendage thrombus (Fig. 4), allowing us to perform a safe and successful direct current cardioversion, that restored the sinus rhythm at 65 bpm. The therapy with dabigatran was prolonged for 4 weeks after cardioversion due to the high risk of thromboembolic events (CHA2DS2-Vasc Score: 2). At the date, twelve months after DCC procedure, no bleeding events or side-effects are reported.

## Discussion

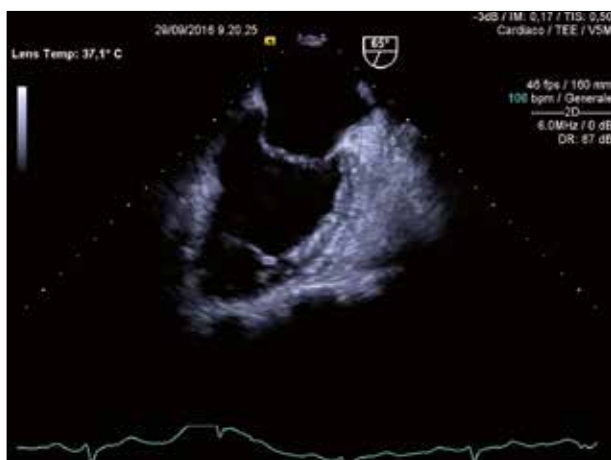Cardiac involvement in DM1 patients occurs as a degenerative process with progressive fibrosis and fatty replacement not only limited to the specialized conduction system, but also extended to initially unaffected areas of the atrial myocardium (17). This anatomic-pathological substrate, causing the discontinuous and inhomogeneous propagation of sinus impulses and the prolongation of atrial conduction time, may facilitate the onset and perpetuation of atrial arrhythmias in these patients (18-24), as usually happens in other clinical conditions (25-30). AF is one of the most common supraventricular arrhythmias observed in DM1 population, characterized by chaotic and uncoordinated atrial activity which predisposes to a hypercoagulable state and an increased risk of TE (12, 13). DCC quickly and effectively converts AF



**Figure 2.** Atrial high rates electrograms detected by pacemaker diagnostics.



**Figure 3.** Transesophageal echocardiographic evaluation. See the presence of a thrombus in left atrial appendage.



**Figure 4.** Transesophageal echocardiography evaluation eight weeks after treatment with dabigatran etexilate.

to sinus rhythm; however, it carries an inherent risk of stroke, which is substantially reduced by the administration of anticoagulation therapy. An early initiation of such therapy is important in all patients scheduled for cardioversion. Patients who have been in AF for periods longer than 48 h should start oral anticoagulation therapy at least 3 weeks before cardioversion and will continue it for at least 4 weeks afterwards (31). However, the difficulties in achieving an optimal anticoagulation with conventional warfarin therapy, likely related to several factors such as the slow onset of action, variable pharmacologic effects, numerous food and drug interactions and periodic closely target INR monitoring (32) make it difficult the therapeutic management in clinical practice and reduce the real-life patients' compliance. All these challenges have prompted an extensive research and developed NOAC,

now available for stroke prevention in AF patients and used in various clinical settings (33-38). Dabigatran etexilate, a direct inhibitor of thrombin, emerged as the first new generation oral anticoagulants potentially able to replace warfarin in preventing arterial TE in patients with AF (39-41). A post-hoc analysis of the Randomized Evaluation of Long-Term Anticoagulation Therapy (RE-LY) study in patients who underwent cardioversion with or without TEE guidance, showed that dabigatran treatment has a low and comparable frequency of adverse events compared to warfarin (42). These results were confirmed by a long term propensity score matched study in real world setting (43). The potential thrombolytic effect of dabigatran has been previously described (43, 44) as it is able to create a easier and faster anticoagulation milieu while inhibiting thrombin binding to fibrin and fibrin degradation products. In contrast warfarin anticoagulation, in its loading phase, could also exert a transient thrombogenic action (45).

## Conclusions

The present case is the first report of a complete left atrial appendage thrombosis resolution obtained by oral dabigatran etexilate in a DM1 patient with AF, scheduled for TEE guided direct electrical cardioversion. The use of NOAC therapy should be particularly useful in this population of patients, for their variable cognitive impairment and consequent poor compliance with periodic INR monitoring.

## References

1. Nigro G, Comi LI, Politano L, et al. Cardiomyopathies associated with muscular dystrophies. In: Engel AG, Franzini-Armstrong C, Eds. *Myology*. 3rd ed. New York: McGraw-Hill 2004, pp. 1239-56.
2. Russo V, Rago A, Ciardiello C, et al. The role of the atrial electro-mechanical delay in predicting atrial fibrillation in myotonic dystrophy type 1 patients. *J Cardiovasc Electrophysiol* 2016;27:65-72.
3. Petri H, Witting N, Ersbøll MK, et al. High prevalence of cardiac involvement in patients with myotonic dystrophy type 1: a cross-sectional study. *Int J Cardiol* 2014;174:31-6.
4. Lazarus A, Varin J, Babuty D, et al. Long-term follow-up of arrhythmias in patients with myotonic dystrophy treated by pacing: a multicenter diagnostic pacemaker study. *JACC* 2002;40:1645-52.
5. Russo V, Rago A, Papa AA, et al. Does a high percentage of right ventricular pacing influence the incidence of paroxysmal atrial fibrillation in myotonic dystrophy type 1 patients? *Kardiol Pol* 2013;71:1147-53.
6. Nigro G, Russo V, Politano L, et al. Does Bachmann's bundle pacing prevent atrial fibrillation in myotonic dystrophy type 1 patients? A 12 months follow-up study. *Europace* 2010;12:1219-23.

7. Russo V, Nigro G, Papa AA, et al. Far field R-wave sensing in myotonic dystrophy type 1: right atrial appendage versus Bachmann's bundle region lead placement. *Acta Myol* 2014;33:94-9.
8. Russo V, Rago A, Politano L, et al. The effect of atrial preference pacing on paroxysmal atrial fibrillation incidence in myotonic dystrophy type 1 patients: a prospective, randomized, single-blind cross over study. *Europace* 2012;14:486-9.
9. Nigro G, Russo V, Rago A, et al. Right atrial preference pacing algorithm in the prevention of paroxysmal atrial fibrillation in myotonic dystrophy type 1 patients: a long term follow-up study. *Acta Myologica* 2012;31:139-43.
10. Russo V, Nigro G, Rago A, et al. Atrial fibrillation burden in myotonic dystrophy type 1 patients implanted with dual chamber pacemaker: the efficacy of the overdrive atrial algorithm at 2 year follow-up. *Acta Myologica* 2013;32:142-7.
11. Russo V, Nigro G, Meo F, et al. The effect of atrial preference pacing on atrial fibrillation electrophysiological substrate in myotonic dystrophy type 1 population. *Acta Myologica* 2014;33:127-35.
12. Stewart S, Hart CL, Hole DJ, et al. Population prevalence, incidence, and predictors of atrial fibrillation in the Renfrew/Paisley study. *Heart* 2001;86:516-21.
13. Watson T, Shantsila E, Lip GY. Mechanisms of thrombogenesis in atrial fibrillation: Virchow's triad revisited. *Lancet* 2009;373:155-66.
14. Roijer A, Eskilsson J, Olsson B. Transoesophageal echocardiography-guided cardioversion of atrial fibrillation or flutter. Selection of a low-risk group for immediate cardioversion. *Eur Heart J* 2000;21:837-47.
15. Stoddard MF, Dawkins P, Prince CR, et al. Transesophageal echocardiographic guidance of cardioversion in patients with atrial fibrillation. *Am Heart J* 1995;129:1204-15.
16. Russo V, Rago A, Proietti R, et al. Efficacy and safety of the target-specific oral anticoagulants for stroke prevention in atrial fibrillation: the real-life evidence. *Ther Adv Drug Saf* 2017;8:67-75.
17. Russo V, Meo F, Rago A, et al. Paroxysmal atrial fibrillation in myotonic dystrophy type 1 patients: P wave duration and dispersion analysis. *Eur Rev Med Pharmacol Sci* 2015;19:1241-8.
18. Russo V, Rago A, Nigro G. Atrial electromechanical delay in myotonic dystrophy type 1 patients. *Eur Rev Med Pharmacol Sci* 2015;19:3991-2.
19. Russo V, Rago A, Nigro G. Sudden cardiac death in neuromuscular disorders: time to establish shared protocols for cardiac pacing. *Int J Cardiol* 2016;207:284-5.
20. Russo V, Nigro G, Papa AA, et al. Adenosine-induced sinus tachycardia in a patient with myotonic dystrophy type 1. *Acta Myologica* 2014;33:104-6.
21. Russo V, Rago A, Meo F, et al. Ventricular fibrillation induced by coagulating mode bipolar electrocautery during pacemaker implantation in myotonic dystrophy type 1 patient. *Acta Myologica* 2014;33:149-51.
22. Russo V, Rago A, D'Andrea A, et al. Early onset "electrical" heart failure in myotonic dystrophy type 1 patient: the role of ICD biventricular pacing. *Anadolu Kardiyol Derg* 2012;12:517-9.
23. Nigro G, Russo V, Vergara P, et al. Optimal site for atrial lead implantation in myotonic dystrophy patients. The role of Bachmann's Bundle stimulation. *PACE* 2008;31:1463-6.
24. Nigro G, Russo V, Politano L, et al. Right atrial appendage versus Bachmann's bundle stimulation: a two year comparative study of electrical parameters in myotonic dystrophy type 1 patients. *PACE* 2009;32:1192-7.
25. Rago A, Russo V, Papa AA, et al. The role of the atrial electromechanical delay in predicting atrial fibrillation in beta thalassemia major patients. *JICE* 2016;48:147-57.
26. Russo V, Di Meo F, Rago A, et al. Impact of continuous positive airway pressure therapy on atrial electromechanical delay in obesity-hypoventilation syndrome patients. *J Cardiovasc Electrophysiol* 2016;27:327-34.
27. Russo V, Rago A, Di Meo F, et al. Atrial septal aneurysms and supraventricular arrhythmias: the role of atrial electromechanical delay. *Echocardiography* 2015;32:1504-14.
28. Russo V, Rago A, Pannone B, et al. Atrial fibrillation and beta thalassemia major: the predictive role of the 12-lead electrocardiogram analysis. *Indian Pacing Electrophysiol J* 2014;25:121-32.
29. Russo V, Rago A, Pannone B, et al. Early electrocardiographic evaluation of atrial fibrillation risk in beta-thalassemia major patients. *Int J Hematol* 2011;93:446-51.
30. Kirchhof P, Benussi S, Kotecha D, et al. ESC Guidelines for the management of atrial fibrillation developed in collaboration with EACTS. The Task Force for the management of atrial fibrillation of the European Society of Cardiology (ESC). *Eur Heart J* 2016;37:2893-962.
31. Proietti R, Joza J, Arensi A, et al. Novel nonpharmacologic approaches for stroke prevention in atrial fibrillation: results from clinical trials. *Med Devices (Auckl)* 2015;8:103-14.
32. Danna P, Proietti R, Sagone A, et al. Does left atrial appendage closure with a cardiac plug system reduce the stroke risk in nonvalvular atrial fibrillation patients? A single-center case series. *Pacing Clin Electrophysiol* 2013;36:347-53.
33. Russo V, Rago A, Papa AA, et al. Use of non-vitamin K antagonist oral anticoagulants in atrial fibrillation with malignancy: clinical practice experience in a single institution and literature review. *Semin Thromb Hemost* 2017 Dec 8. doi: 10.1055/s-0037-1607436.
34. Russo V, Rago A, Papa AA, et al. Budget impact analysis of rivaroxaban vs warfarin anticoagulation strategy for direct current cardioversion in non-valvular atrial fibrillation patients: the MonaldiVert economic study. *Minerva Cardioangiol* 2017;66:1-5.
35. Russo V, Di Napoli L, Bianchi V, et al. A new integrated strategy for direct current cardioversion in non-valvular atrial fibrillation patients using short term rivaroxaban administration: The MonaldiVert real life experience. *Int J Cardiol* 2016;1;224:454-5.

36. Stabile G, Russo V, Rapacciuolo A, et al. Transesophageal echocardiography in patients with persistent atrial fibrillation undergoing electrical cardioversion on new oral anticoagulants: a multi center registry. *Int J Cardiol* 2015;184:283-4.
37. Bertaglia E, Anselmino M, Zorzi A, et al. NOACs and atrial fibrillation: incidence and predictors of left atrial thrombus in the real world. *Int J Cardiol* 2017;249:179-83.
38. Connolly SJ, Ezekowitz MD, Yusuf S, et al. RE-LY steering committee and investigators dabigatran versus warfarin in patients with atrial fibrillation. *N Engl J Med* 2009;361:1139-51.
39. Russo V, Bianchi V, Cavallaro C, et al. Efficacy and safety of dabigatran in a "real-life" population at high thromboembolic risk and hemorrhagic risk: data from Monaldi Care registry. *Eur Rev Pharmacol Sci* 2015;19:3961-7.
40. Russo V, Rago A, D'Onofrio A, et al. The clinical performance of dabigatran in the Italian real-life experience. *J Cardiovasc Med (Hagerstown)* 2017;18:922-3.
41. Nagarakanti R, Ezekowitz MD, Oldgren J, et al. Dabigatran versus warfarin in patients with atrial fibrillation: an analysis of patients undergoing cardioversion. *Circulation* 2011;123:131-6.
42. Russo V, Rago A, Papa AA, et al. Efficacy and safety of dabigatran in patients with atrial fibrillation scheduled for transesophageal echocardiogram-guided direct electrical current cardioversion: a prospective propensity score-matched cohort study. *J Thromb Thrombolysis* 2018;45:206-12.
43. Vidal A, Vanerio G. Dabigatran and left atrial appendage thrombus. *J Thromb Thrombolysis* 2012;34:545-7.
44. Morita S, Ajiro Y, Uchida Y. Dabigatran for left atrial thrombus. *Eur Heart J* 2013;34:2745.
45. Azoulay L, Dell'Aniello S, Simon TA. Initiation of warfarin in patients with atrial fibrillation: early effects on ischaemic strokes. *Eur Heart J* 2013;35:1881-7.