

Pediatrics

Neo-glans reconstruction after glans amputation during circumcision using autologous buccal mucosal graft



Andry Giovanni*, Irfan Wahyudi, Arry Rodjani

Urology Department, Cipto Mangunkusumo Hospital, Faculty of Medicine Universitas Indonesia, Jakarta, Indonesia

ARTICLE INFO

Article history:

Received 1 November 2017

Received in revised form

16 January 2018

Accepted 18 January 2018

Available online 31 January 2018

Keywords:

Buccal mucosa graft

Neoglans reconstruction

Penile amputation

1. Introduction

Genitourinary trauma comprises 2–10% of all hospital admission, which external genitalia trauma is involved in 33–36% of the cases. Amongst external genitalia traumas, penile or glans amputation is very rare case.¹ During circumcision, glans injury is mostly due to glans trapped in the circumcision clamp or while performing guillotine technique, which usually results in partial or total amputation of glans penis.

After 24 hour of injury, it is not recommended to reattached the glans, penile lengthening can be performed using proximal lengthening using gracilis muscle, scrotal flap or distal lengthening using rectus abdominis fascial island flap covered by skin graft or scrotal flap. A few studies has report the use of buccal mucosal graft in glans reconstruction.^{2,3} In this study we describe this novel technique of neoglans reconstruction using autologous buccal mucosal graft in paediatric iatrogenic amputation during circumcision.

2. Case

A 5-year-old child presented to our urology clinic at Cipto

Mangunkusumo Hospital in Jakarta, Indonesia with a lost glans penis that had occurred during circumcision when the baby was 2 days old. The baby experienced circumcision performed at rural clinic by a medical doctor. After the procedure, the parent complained that the infant could not pass urine freely and the penis was disfigured.

On physical examination, the penis was normal in length and consistency. The skin of the shaft was normal in appearance, but the tip showed scar tissue and stenosed external urethral meatus as showed in Fig. 1. Penile length measured 3 cm. There was no remarkable result on laboratory examination, renal function and ultrasound.

3. Surgical procedure

With the infant under general anaesthesia, a circumferential incision was made at the distal end of the remaining penis, 1 cm around the urethral meatus. Skin degloving was performed (Fig. 2). The urethral meatus was dissected for a distance of about 5 mm to free end of the urethra and was stented with a silicon 6-fr Foley Catheter. Penile shaft was measured and we found raw surface was 40 mm in diameter and 35 mm long.

The oral cavity was opened, and lower lip was exposed. Inner mucosal segment of lower lip (10 mm × 40 mm) was marked. The sub-mucosa was then incised and dissected. The graft was defatted.

The graft was anastomosed with the urethral mucosa and penile skin by use of PDS 5/0 interrupted sutures. The graft was also fixed with anchor suture in its centre. Postoperatively, closed wound dressing with Vaseline gauze was applied to the recipient site maintained for 10 days.

4. Results

After 2 weeks, the dressing was removed (Fig. 3). Catheter was removed after 1 month and the patient can urinate with good stream and without any complain. Follow-up demonstrated healthy appearing buccal mucosa that appropriately simulates the glans penis. The graft improved in cosmetic appearance over time. At 6 months follow up, patient had a widely patent urethral meatus with no scarring at the distal end of the penis with acceptable cosmetic.

* Corresponding author. Jl. Diponegoro no 71, Jakarta Pusat, P.O box 10310, Indonesia.

E-mail address: giovanny.andry@gmail.com (A. Giovanni).

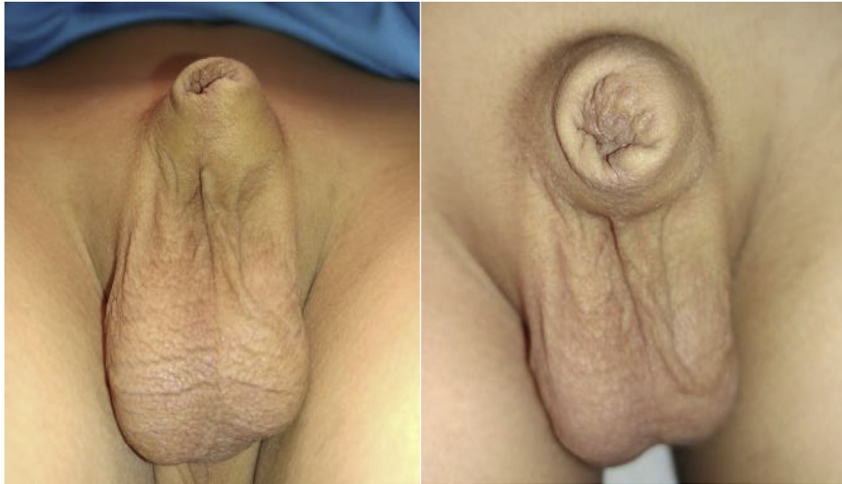

Fig. 1. The amputated glans penis 5 year after circumcision. The penis is disfigured and urethral meatus was covered with fibrotic tissue.

5. Discussion

In case of penile amputation more than 24 hours, it is not recommended to reattach the stump. In this situation, skin grafts and a variety of pedicled and free flaps are available for genital reconstruction. Cook et al., in 2005 reported the first reconstructive surgery using buccal mucosa graft to stimulate the coronal sulcus after traumatic penile amputation with good result.³ Recently, in 2014, Appiah et al. also reported the use of buccal mucosa graft for neo-glanuloplasty after circumcision injury, which shows good result at the 6th month follow up.⁴

In this study, we used buccal mucosa from inner lower lips as graft. Inner lower lip was chosen as graft donor since the mucosa was thinner than cheek mucosa, and also technically the procedure was simple. Therefore, in paediatric case with small raw surface area, inner lower lip is more suitable. After 6 months follow up, the

patient could urinate without any complain. As healing process continues, the glans has resembled normal glans mucosa.

Buccal mucosa graft has several advantage over skin graft since the tissue is tough, resilient, no problem with hair growth. The process of harvesting is simple and does not create visible donor site scar.^{2,5} Potential problem in this technique is high risk of graft mobility at the recipient site which can impair neovascularization for adequate graft take. We overcome this problem by using anchoring stitches in both cases. Graft contraction could also give another problem which cause meatal stenosis. In our patients, we did not find this complication in 6 months follow up.

Limitation in our study was low incidence of glans or penile amputation case and limited follow up period up to 6 months. We suggest that a study with longer follow up period could give more information regarding long term result of buccal mucosa graft in neo-glans reconstruction, with increasing number of cases and

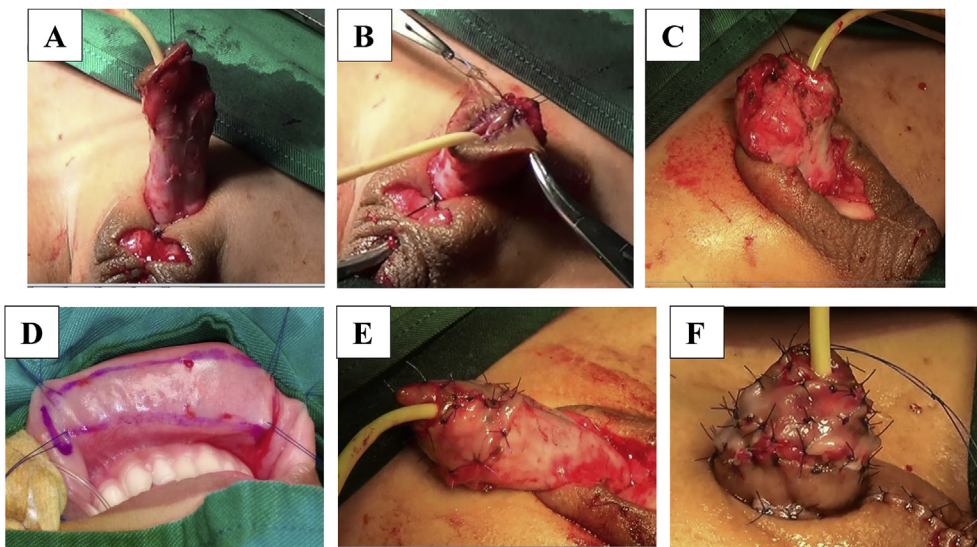


Fig. 2. Operative steps. A) degloving of penis; B) perimeatal excision design; C) perimeatal excision; D) inner lower lip graft harvesting; E) graft anastomosis; F) post-operative result.

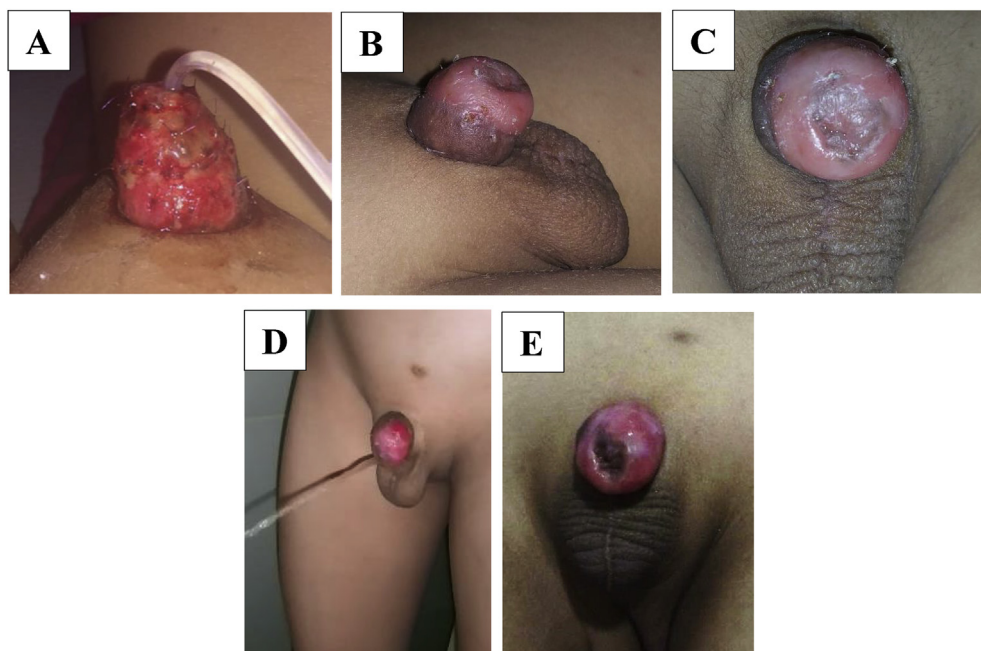


Fig. 3. Post-operative follow up. A) 10 days after surgery; B) 3 months after surgery, lateral view; C) 3 months after surgery, front view; D) normal micturition; E) 6 months after surgery.

operator experience, not only cosmetic and voiding function but also skin sensation and pain perception.

6. Conclusion

The case presented showed that buccal urethral graft in neo-glans reconstructive surgery gives good cosmetic and functional result. Neo-glans reconstruction using buccal mucosa graft may be considered as a potential option for management of glans amputation. A larger study with more cases and longer follow up period is needed to provide long term result of neo-glans reconstruction using buccal mucosa graft.

Acknowledgement

There were no grant or funding in this research. We declared that there were no conflict of interest. All the patient has been asked for permission for taking picture and taking medical

information.

Appendix A. Supplementary data

Supplementary data related to this article can be found at <https://doi.org/10.1016/j.eucr.2018.01.019>.

References

1. Virasoro R, Tonkin JB, McCammon KA, Jordan GH. Penile amputation: cosmetic and functional results. *Sex Med Rev.* 2015;3(3):214–222.
2. Aboutaleb H. Reconstruction of an amputated glans penis with a buccal mucosal graft: case report of a novel technique. *Kor J Urol.* 2014;55(12):841–843.
3. Cook A, Khoury AE, Bagli DJ, Farhat WA, Pippi Salle JL. Use of buccal mucosa to simulate the coronal sulcus after traumatic penile amputation. *Urology.* 2005;66(5), 1109.
4. Appiah K, Amoah G, Azorliade R, et al. Glanuloplasty with oral mucosa graft following total glans penis amputation. *Case Rep Urol.* 2014;2014, 671303.
5. Bhargava S, Chapple CR. Buccal mucosal urethroplasty: is it the new gold standard? *BJU Int.* 2004;93(9):1191–1193.