



Contents lists available at ScienceDirect

International Journal of Surgery Case Reports

journal homepage: www.casereports.com

Anomalous origin of the right coronary artery with an interarterial course and intramural part

Simon Fuglsang^{a,*}, Johan Heiberg^a, Jørgen Byg^b, Vibeke Elisabeth Hjortdal^a^a Department of Cardiothoracic and Vascular Surgery, Aarhus University Hospital Skejby, Denmark^b Department of Cardiology, Hospital of Southern Jutland, Denmark

ARTICLE INFO

Article history:

Received 20 April 2015

Received in revised form 16 July 2015

Accepted 18 July 2015

Available online 28 July 2015

Keywords:

Coronary artery anomaly

Congenital heart disease

Congenital heart surgery

Exercise related pain

Surgical approach

ABSTRACT

INTRODUCTION: An anomalous origin and course of the right coronary artery (RCA)¹ is a very rare congenital anomaly that can be fatal if it remains undiscovered.**PRESENTATION OF CASE:** In this case report, we present a patient with a one-year history of exercise-induced angina and dyspnea caused by anomalous origin of the RCA from the left sinus, and anomalous course between the aorta and the pulmonary artery.**DISCUSSION:** Possible mechanisms of this disease's symptomatology are compression of the RCA between the aorta and the pulmonary artery in its anomalous inter-arterial course, and squeezing of the RCA in the proximal intramural part.**CONCLUSION:** In this report, we present some unique images of the RCAs course, which contribute to the understanding of this disease's symptomatology. The patient successfully underwent surgery with Right Internal Mammary Artery to RCA (RIMA–RCA)² bypass with complete remission of all symptoms.© 2015 The Authors. Published by Elsevier Ltd. on behalf of Surgical Associates Ltd. This is an open access article under the CC BY-NC-ND license (<http://creativecommons.org/licenses/by-nc-nd/4.0/>).

1. Introduction

An anomalous origin of the right coronary artery from the left sinus of Valsalva is a rare congenital anomaly found in approximately 0.1% of patients undergoing angiography [1]. The anomalous inter-arterial course in found in 99% of patients with anomalous RCA [2]. The clinical manifestations are highly variable, and the condition has been associated with sudden cardiac death, myocardial ischemia, syncope, but it is mainly clinically silent [3,4].

2. Presentation of case

A 39-year-old woman with a one-year history of exercise-related angina, dyspnea, and palpitations was referred to our clinic. The patient had not experienced dizziness or syncope/near-syncope, and she had no risk factors for atherosclerosis. Echocardiography was normal but coronary angiography revealed anomalous origin of the right coronary artery, departing independently from the left coronary Sinus of Valsalva, close to the origin of the left coronary artery. The proximal part of the RCA seemed to be coursing intramurally in the aortic vessel wall before running

between the aorta and pulmonary artery (Figs. 1 and 2). A positive ischemia test was performed on an ergometer bicycle and Positron Emissions Tomography–Computed Tomography (PET–CT)³ showed stress-induced ischemia of the myocardium supplied by the RCA.

A RIMA–RCA bypass was made with no complications and the patient was discharged 4 days later. At the 6-week follow-up the patient's symptoms had subsided completely.

3. Discussion

As described, coronary anomalies have been associated with a wide range of cardiac symptoms; however, the mechanisms behind the symptoms are poorly understood. Pinching of the anomalous RCA between the aorta and the pulmonary artery caused by the increased cardiac output during exercise has been proposed [5]. Also, an intussusception of the initial part of the RCA in the aortic wall, resulting in an intramural part, may make it vulnerable for compression by the expanding aorta on increased cardiac output [3].

Up to one-third of sudden cardiac deaths in the young population are caused by coronary anomalies, and especially an intramural and inter-arterial course, as suspected in this case, is associated with the severe symptoms [6,7]. An early diagnosis is crucial [8].

¹ RCA = right coronary artery.² RIMA–RCA = right Internal mammary artery to right coronary artery.

* Corresponding author at: Ivar Huitfeldtsgade 26, 2. 8200 Aarhus N, Denmark.

Fax: +45 78453079.

E-mail address: simonfuglsang@gmail.com (S. Fuglsang).³ PET–CT = positron emissions tomography–computed tomography.

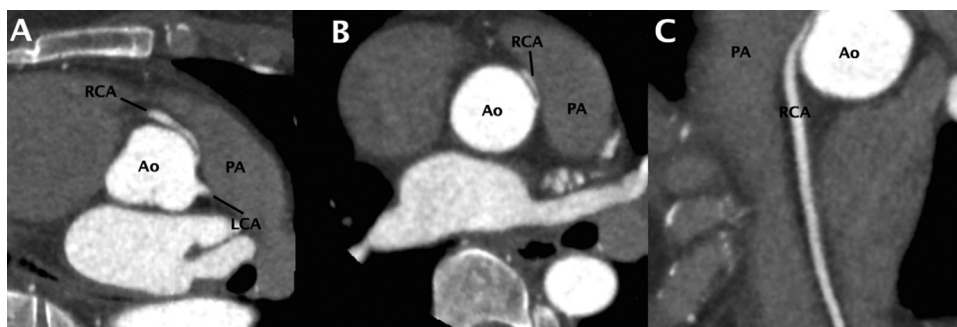


Fig. 1. Computer tomography showing the origin of the RCA. The RCA departing from the left coronary sinus close to the pulmonary artery with a course anteriorly to aorta. Normal morphology of the left coronary artery.

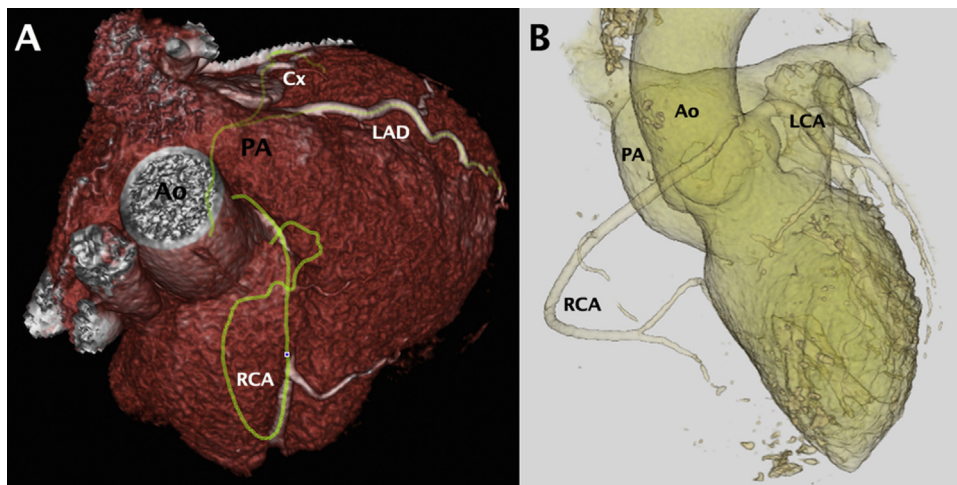


Fig. 2. 3D reconstruction of a Computed Tomography image showing an anomalous origin and course of the RCA.

Table 1
Key case series.

| Paper | Coronary artery anomaly | Inter-arterial course | Intramural part | Symptoms | Management strategy |
|-------|---|-----------------------|-----------------|---|---|
| [11] | The left coronary artery originating from the right sinus of Valsalva | Yes | No | Exercise-induced syncope | Creation of a neo-ostium in the left coronary sinus, and patch angioplasty using pulmonary arterial wall tissue |
| [12] | The right coronary artery originating from the left sinus of Valsalva | Yes | No | Chest pain | Surgical approach using the right gastroepiploic artery as coronary bypass graft |
| [13] | The left coronary artery originating from the right sinus of Valsalva | Yes | No | Exercised-induced chest pain and presyncopal symptoms | Increase of the distance between the main pulmonary artery and the aorta by mobilization of the pulmonic root and pulmonary bifurcation |
| [14] | The right coronary artery originating from the left sinus of Valsalva | Yes | Yes | Chest pain and dyspnea on exertion | Stenting of the proximal intramural part of the RCA using percutaneous coronary intervention |
| [15] | The right coronary artery originating from the left sinus of Valsalva | Yes | No | Exercise-induced chest pain and dyspnea | Beating heart coronary ostial translocation with an anastomosis assist device |

This case report describes a rare condition with a potential fatal outcome, and thereby underlines the importance of early awareness of the condition. Also, it is absolute essential to optimize the image information about the aorta annulus anatomy with individualized projections. In this case we analyzed the images using 'Toshiba Aquilion One' software, and were moreover, we are able to present unique images of the RCAs entire course demonstrating its vulnerability between the aorta and the pulmonary artery. Different management strategies have been used, but recently the primary strategy has shifted from medical observation to surgical

treatment, however still depending on the symptoms [9]. Among the surgical techniques used are the bypass graft surgery, reimplantation of the coronary ostium, unroofing technique, and direct translocation of the pulmonary artery [10]. Some of these symptoms and management strategies from other case series have been highlighted in Table 1.

Conflict of interest

No conflicts to declare.

Funding

No funding was received for this study.

Ethical approval

The study was exempt from formal approval by The Regional Committee on Biomedical Research Ethics of the Central Denmark Region.

Consent

Informed consent was obtained from the patient for publication of this case report and accompanying images.

Authors contribution

All authors have taken part in conception and interpretation of data, drafting or revising the manuscript critically, and final approval of the manuscript submitted.

Guarantor

Simon Fuglsang.

References

- [1] O. Yamanaka, R.E. Hobbs, Coronary artery anomalies in 126,595 patients undergoing coronary arteriography, *Cathet. Cardiovasc. Diagn.* 21 (1) (1990) 28–40.
- [2] J.A. Poynter, I. Bondarenko, E.H. Austin, W.M. DeCampi, J.P. Jacobs, G. Ziemer, P.M. Kirshbom, C.I. Tchervenkov, T. Karamlou, E.H. Blackstone, H.L. Walters 3rd, J.W. Gaynor, C.M. Mery, J.M. Pearl, J.A. Brothers, C.A. Caldarone, W.G. Williams, M.L. Jacobs, C. Mavroudis, A. W. G. Congenital heart surgeons' society, Repair of anomalous aortic origin of a coronary artery in 113 patients: a congenital heart surgeons' society report, *World J. Pediatr. Congenit. Heart Surg.* 5 (4) (2014) 507–514.
- [3] P. Angelini, Coronary artery anomalies: an entity in search of an identity, *Circulation* 115 (10) (2007) 1296–1305.
- [4] M. Krupiński, M. Urbańczyk-Zawadzka, B. Laskowicz, M. Irzyk, R. Banyś, P. Klimeczek, K. Gruszczynska, J. Baron, Anomalous origin of the coronary artery from the wrong coronary sinus evaluated with computed tomography: 'high-risk' anatomy and its clinical relevance, *Eur. Radiol.* 24 (10) (2014) 2353–2359.
- [5] P. Angelini, Coronary artery anomalies – current clinical issues: definitions, classification, incidence, clinical relevance, and treatment guidelines, *Tex. Heart Inst. J.* 29 (4) (2002) 271–278.
- [6] S. Kaushal, C.L. Backer, A.R. Popescu, B.L. Walker, H.M. Russell, P.R. Koenig, C.K. Rigsby, C. Mavroudis, Intramural coronary length correlates with symptoms in patients with anomalous aortic origin of the coronary artery, *Ann. Thorac. Surg.* 92 (3) (2011) 986–992.
- [7] J.E. Shriki, J.S. Shinbane, M.a. Rashid, a. Hindoyan, J.G. Withey, a. DeFrance, M. Cunningham, G.R. Oliveira, B.H. Warren, a. Wilcox, Identifying, characterizing, and classifying congenital anomalies of the coronary arteries, *Radiographics* 32 (2) (2012) 453–468.
- [8] Y.L. Bae, Anomalous right coronary artery from the left coronary sinus with an interarterial course: is it really dangerous? *Kor. Circ. J.* 39 (5) (2009) 175–179.
- [9] R.a. Krasuski, D. Magyar, S. Hart, V. Kalahasti, R. Lorber, R. Hobbs, G. Pettersson, E. Blackstone, Long-term outcome and impact of surgery on adults with coronary arteries originating from the opposite coronary cusp, *Circulation* 123 (2) (2011) 154–162.
- [10] R.L. Romp, J.R. Herlong, C.K. Landolfo, S.P. Sanders, C.E. Miller, R.M. Ungerleider, J. Jagers, C. Backer, S. Bradley, C. Mavroudis, J.W. Brown, Outcome of unroofing procedure for repair of anomalous aortic origin of left or right coronary artery, *Ann. Thorac. Surg.* 76 (2) (2003) 589–596.
- [11] K. Kumagai, H. Kin, A. Ikai, H. Okabayashi, Successful neo-ostium creation using pulmonary artery tissue in a case of anomalous origin of the left coronary artery from the right sinus of Valsalva, *Interact. Cardiovasc. Thorac. Surg.* 18 (February 2014) 695–697.
- [12] W. Heo, H.-K. Min, D.K. Kang, H.J. Jun, Y.-H. Hwang, H.C. Lee, Three different situations and approaches in the management for anomalous origin of the right coronary artery from the left coronary sinus: case report, *J. Cardiothorac. Surg.* 9 (1) (2014) 21–26.
- [13] K. Nimdet, J. Soongswang, S. Sriyodchati, An interarterial course of anomalous coronary artery and an alternative surgical option, *Cardiol. Young* 22 (05) (2012) 536–538.
- [14] R. Vadivelu, S. Bagga, Is endovascular therapy the right choice for treatment of functional compression of anomalous right coronary artery arising from left coronary sinus with interarterial course? *Case Rep.* 2013 (January) (2013) 1–6.
- [15] Y. Inoue, H. Kawajiri, S. Suzuki, T. Tamura, Novel beating heart repair for anomalous origin of right coronary artery, *Ann. Thorac. Surg.* 96 (6) (2013) e141–e143.

Open Access

This article is published Open Access at sciendo.com. It is distributed under the [IJSCR Supplemental terms and conditions](#), which permits unrestricted non commercial use, distribution, and reproduction in any medium, provided the original authors and source are credited.