

Research article

## The diagnostic value of liver biopsy

Claudia Spycher<sup>1</sup>, Arthur Zimmermann<sup>2</sup> and Juerg Reichen<sup>\*1</sup>

Address: <sup>1</sup>Department of Clinical Pharmacology, University of Berne, Switzerland and <sup>2</sup>Department of Pathology, University of Berne, Switzerland

E-mail: Claudia Spycher - claudia.spycher@lycos.com; Arthur Zimmermann - zimmerma@patho.unibe.ch; Juerg Reichen\* - reichen@ikp.unibe.ch

\*Corresponding author

Published: 31 October 2001

Received: 4 September 2001

*BMC Gastroenterology* 2001, 1:12

Accepted: 31 October 2001

This article is available from: <http://www.biomedcentral.com/1471-230X/1/12>

© 2001 Spycher et al; licensee BioMed Central Ltd. Verbatim copying and redistribution of this article are permitted in any medium for any non-commercial purpose, provided this notice is preserved along with the article's original URL. For commercial use, contact [info@biomedcentral.com](mailto:info@biomedcentral.com)

### Abstract

**Background:** Since the introduction of molecular diagnostic tools such as markers for hepatitis C and different autoimmune diseases, liver biopsy is thought to be useful mainly for staging but not for diagnostic purposes. The aim was to review the liver biopsies for 5 years after introduction of testing for hepatitis C, in order to evaluate what diagnostic insights – if any – remain after serologic testing.

**Methods:** Retrospective review of all liver biopsies performed between 1.1.1995 and 31.12.1999 at an academic outpatient hepatology department. The diagnoses suspected in the biopsy note were compared with the final diagnosis arrived at during a joint meeting with the responsible clinicians and a hepatopathologist.

**Results:** In 365 patients, 411 diagnoses were carried out before biopsy. 84.4 % were confirmed by biopsy but in 8.8 %, 6.8 % and 10.5 % the diagnosis was specified, changed or a diagnosis added, respectively. Additional diagnoses of clinical relevance were unrecognized biliary obstruction and additional alcoholic liver disease in patients with chronic hepatitis C. Liver biopsy led to change in management for 12.1 % of patients.

**Conclusion:** Even in the era of advanced virological, immunological and molecular genetic testing, liver biopsy remains a useful diagnostic tool. The yield is particularly high in marker negative patients but also in patients with a clear-cut prebiopsy diagnosis, liver biopsy can lead to changes in patient management.

### Background

Liver biopsy has been the gold standard for diagnosing liver disease; however, the detection of the hepatitis C virus and the development diagnostic testing [1], the development of criteria for autoimmune hepatitis [2] as well as the detection of novel autoantibodies [3] makes diagnosis of many liver diseases based on virological and serological testing much easier and precise.

We had shown in an earlier study before anti-HCV testing became available that liver biopsy changed diagnosis and management in a sizable percentage of cases [4]. The aim of the present study was to evaluate the diagnostic value of liver biopsy in the era of testing for hepatitis C. To this effect, we retrospectively analyzed the 380 liver biopsies performed between 1.1.1995 to 31.12.1999 in our department.

## Methods

The charts of all patients who underwent percutaneous liver biopsy in the Department between 1.1.1995 to 31.12.1999 were reviewed and pre- and postbiopsy diagnosis extracted. Liver biopsies were performed on an outpatient basis either by the Menghini technique after ultrasound examination of the liver or by direct ultrasound guided biopsy. The choice of the method was left to the attending physician. To qualify for outpatient liver biopsy prothrombin time as assessed by the Quick value had to be above 60 %, platelets > 60'000 and there had to be no history of excessive bleeding. Moreover, patients with focal lesions, dilated bile ducts or signs of hepatic decompensation were excluded.

Prebiopsy diagnosis was done based on history, physical examination and extensive laboratory investigations. The prebiopsy diagnosis was recorded in the biopsy note by the physician performing the liver biopsy. More than one diagnosis was possible per patient. Hepatitis B was suspected when HB<sub>s</sub> and/or anti-HB<sub>c</sub> were present. Hepatitis C was diagnosed based on a positive anti-HCV test; in such patients HCV-RNA was also determined. Autoimmune hepatitis was suspected when IgG were elevated and/or when autoantibodies (ANA, ASM, SLA, LKM) were present. Primary biliary cirrhosis was suspected in the presence of a cholestatic enzyme pattern and positive antimitochondrial antibodies. Hemochromatosis was suspected when iron saturation was above 45 and 50 % in women and men, respectively and with ferritin in the pathological range. Alcoholic liver disease was suspected when a corresponding history was present and/or with an AST/ALT ratio above 1 and a markedly elevated – glutamyl transpeptidase. Non-alcoholic steatohepatitis / steatosis was suspected when there was a negative history for alcohol abuse, usually confirmed by a third person. Wilson's disease was suspected in patients with low serum caeruloplasmin and elevated urinary copper excretion.  $\alpha_1$ -antitrypsin deficiency was invoked when serum  $\alpha_1$ -antitrypsin was low.

Post-biopsy diagnosis was arrived at in a common conference where the biopsy and all serological tests were reviewed together with the hepatopathologist (AZ). Grading and staging was done according to Batts and Ludwig [5].

Liver and other biochemical tests were performed by standard autoanalyzer methods in the central clinical laboratory of the university hospital. Serum bile acids were determined by a commercially available radioimmunoassay. Galactose elimination capacity was determined as previously described [6,7] and the aminopyrine breath test using <sup>13</sup>C-dimethyl-aminopyrine instead of the previously reported <sup>14</sup>C-labeled compound [8].

Results are reported as median and range or mean  $\pm$  standard deviation as indicated in the text. Predictive value of the different tests with respect to activity and stage was performed using Statistica (Statsoft Inc., Tulsa OK). Multiple analysis of variance was performed with the respective module; significant differences were localized by Tukey's honest significant difference test.

## Results

In the period reviewed – 1.1.1995 – 31.12.1999 – liver biopsy was performed on an outpatient basis in 380 patients. In three patients no material could be obtained; another 12 liver biopsies were performed in transplanted patients. Since most of our liver biopsies in transplanted patients are performed on an inpatient basis these 12 biopsies were not further analyzed leaving 365 biopsies as the basis for this report.

There were 126 female and 239 male patients with a median age of 42 (range 16–75) years. The main laboratory findings are given in table 1. Besides the diagnostic categories listed in table 1 there were four cases of Kupffer cell siderosis, 4 cases were normal or could not be classified, 3 patients underwent staging biopsy for Hodgkin's lymphoma, 3 cases of  $\alpha_1$ -antitrypsin deficiency, 2 granulomatous hepatitis and one each of nodular regenerative hyperplasia and vasculitis in the context of Wegener's granulomatosis.

There were 411 diagnoses before biopsy; 347 (84.4 %) of which were confirmed by biopsy. In 64 cases diagnosis was specified (36; 8.8 %), changed (28; 6.8 %) or added (43; 10.5 %). The details of these changes in diagnoses are compiled in table 2. There were 43 diagnoses not considered before performing the liver biopsy added after liver biopsy (table 3). In the post-biopsy evaluation, 311 patients carried one, 50 patients two and 4 three diagnoses.

There were 32 (8.8 %) patients with marker negative liver disease (No autoantibodies, HB<sub>s</sub> and anti-HB<sub>c</sub> negative, anti-HCV negative, iron parameters not suggesting hemochromatosis, ALT/AST ratio +  $\gamma$ -GT + MCV not suggestive of alcohol abuse). The findings in this group are reported in table 4. The most frequent prebiopsy diagnoses were steatosis and unknown hepatopathy in 14 and 9 patients, respectively. The most frequent postbiopsy diagnosis was steatosis or alcoholic liver disease in 14 patients. Only one biopsy was reported as normal. Clinically relevant diagnoses – leading to changes in management or further diagnostic testing were found in 5 patients, namely 3 cases of obstruction and two of marker negative autoimmune hepatitis.

**Table 1: Main laboratory parameters in the different diagnostic groups. Median and range are given.**

Final Dx	N	BR	ALT	Alk. P.	$\gamma$ -GT	Albumin	Ferritin	GEC	ABT
CHC	215	11 3-51	105 12-852	69 26-240	48 6-1105	39 27-53	152 7-4404	5.6 3.3-8.8	0.6 .04-1.76
(N)ASH	68	14 7-126	72 20-852	90 42-333	119 12-2930	38 25-48	311 7-4404	5.7 3.4-8.3	.43 .03-1.23
CHB	37	14 5-32	120 18-510	71 39-1074	30 7-754	37 27-45	129 86-532	5.4 3.7-6.9	.58 .09-.84
HC	24	12 5-55	65 16-224	84 62-142	35 7-260	37 22-50	857 237-3729	5.7 4.0-8.0	.55 .15-1.76
PBC	23	11 5-134	82 13-423	171 68-566	175 26-1505	36 32-40	101 10-812	5.9 3.0-8.3	.66 .22-1.34
AIH	11	22 5-522	242 22-1360	117 78-283	91 40-600	32 24-41	196 8-4013	5.5 3.0-7.1	.40 .04-.70
CHOL	9	17 4-25	65 23-293	98 69-274	218 106-1199	40 24-43	95 40-333	6.9 4.6-6.9	.51 .42-.54

**Table 2: Modification of diagnosis by liver biopsy**

Pre-biopsy (n)	Diagnosis changed	Diagnosis specified
Steatosis / NASH (18)	Cholestasis (2) Chronic hepatitis (1) Gran. Hepatitis (1)	Alcoholic hepatitis (3) NASH (5) Alcoholic cirrhosis (1) Steatosis (5)
Alcoholic liver disease (12)	No evidence of ALD (7)	Steatosis (2) Alcoholic hepatitis (3)
Ai liver disease (11)	Ruled out (1) Portal fibrosis (1) Steatosis (1)	Ai cholangiopathy (3) PBC (1) Overlap syndrome (4)
Hemochromatosis (8) Cholestasis (7)	Ruled out (5) Toxic hepatitis (1) Alcoholic hepatitis (1) Autoimmune hepatitis (1)	Kupffer cell siderosis (3) Obstruction (2) Ai cholangiopathy (1) PSC (1)
Cryptogenic cirrhosis (4)	Portal fibrosis (1) Steatosis (1)	Ai hepatitis (1) PSC (1)
Wilson's disease (3) Toxic hepatitis (1)	Ruled out (3) Alcoholic hepatitis (1)	

Ai stands for autoimmune, PSC and PBC for primary sclerosing cholangitis and primary biliary cirrhosis, respectively. Toxic hepatitis infers drug or industrial toxin-induced liver damage.

The different liver tests (ALT, alkaline phosphatase,  $\gamma$ -GT, bilirubin, albumin, prothrombin time, serum bile acids, galactose elimination capacity and aminopyrine breath test) were analyzed for their potential to recognize stage in the major diagnostic groups reported in table 1. Overall, there was a marked effect of fibrosis on the liver tests by multiple analysis of variance for all patients (Rao's R 3.77  $p < 10^{-6}$ ); localization of differences (Tukey's honest significance test) revealed that prothrombin

time and platelet count differentiated between stage 4 and the other stages. Only galactose elimination capacity was able to differentiate between all stages (figure 1) but the overlap was too large to make this clinically relevant. Similar results were obtained when only patients with viral hepatitis (Rao's R 3.66,  $p < 10^{-6}$ ) were tested but not for patients with alcoholic liver disease or NASH; the n in the other groups was too small to perform analysis of variance. None of the liver tests including ALT predicted

**Table 3: Diagnoses added to a bioptically confirmed diagnosis**

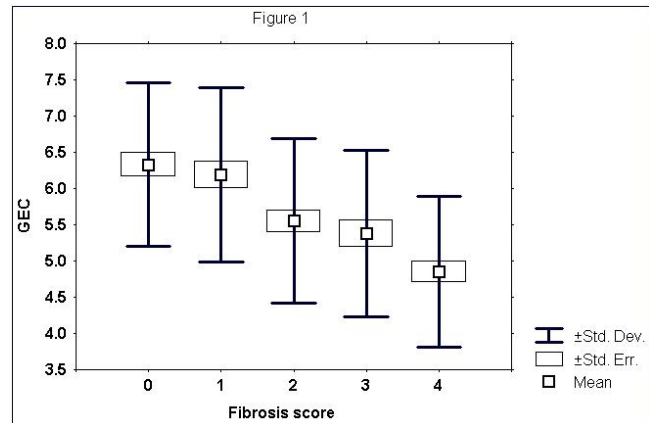
Confirmed diagnosis (n)	Added diagnosis (n)
Hepatitis C (30)	Alcoholic liver disease (17) Steatosis (3) NASH (2) Iron overload (6) Autoimmune hepatitis (1) Granulomatous hepatitis (1)
Iron overload (5)	Hepatitis C (2) Alcoholic liver disease (2) Steatosis (1)
PBC (3) or PSC (1)	Steatosis (2) Alcoholic liver disease (1)
Steatosis (3)	Cholestasis (2) Biliary obstruction (1)
Alcoholic liver disease (1)	Chronic hepatitis C (1)
Chronic hepatitis B (1)	Steatosis (1)

**Table 4: Pre- and postbiopsy diagnoses in marker negative liver disease**

Pre-biopsy diagnosis	Postbiopsy diagnosis
Steatosis (14)	Steatosis (9) Cholestasis (2) Obstruction (1) Granulomatous hepatitis (1) Chronic active hepatitis (1)
Unknown (9)	Steatosis (2) Autoimmune hepatitis (1) Obstruction (1) Granulomatous hepatitis (1) Sepsis (1) Nodular regenerative hyperplasia (1) Vasculitis (1) Normal (1)
Cholestasis (4)	Alcoholic liver disease (1) Obstruction (1) PSC (2)
Alcoholic liver disease (3)	Alcoholic liver disease (2) PSC (1)
Autoimmune hepatitis (1)	Autoimmune hepatitis (1)
Toxic hepatitis (1)	Toxic hepatitis (1)

activity in the whole patient group or in the patients with hepatitis C and/or B.

There were was one major complication in this series: one patient had to be hospitalized because of a bile leak and associated severe pain. Sonography performed two



**Figure 1**  
Box and whisker plot of galactose elimination capacity (GEC) in different stages of liver disease. Staging was performed according to Batts and Ludwig [5]. Means, standard deviations and standard errors of the mean are indicated. Galactose elimination capacity was the only test differing significantly ( $p < 0.05$ ) between all stages.

weeks earlier had been normal while postbiopsy sonography demonstrated dilated bile ducts and further work-up showed a small ampullary carcinoma. Two other patients had to be hospitalized over night because of severe pain after liver biopsy; in none of them was there any significant pathology revealed by sonography and careful follow-up; both were discharged free of pain the next morning.

**Discussion**

Our data demonstrate that liver biopsy even in this age of advanced serological testing modified or added to diagnosis in a sizable percentage of cases. While this was not clinically relevant or represented a more precise diagnostic label (e.g. overlap syndrome when the prebiopsy diagnosis was primary biliary cirrhosis), it led to additional diagnoses which affected the patients clinical management in at least 12 cases (3.3 %) to a major and in another 41 (8.8%) in a minor fashion. The number of changed diagnoses is similar to that reported in asymptomatic patients from the Mayo clinic [9] and – surprisingly – remains comparable to that others and ourselves had reported in the pre-hepatitis C testing era [10,4].

Hepatitis C was the most common indication for liver biopsy in our patient population, an experience similar to that reported recently from France [11]. It is not surprising that diagnosis was modified most often in this disease, the finding of additional toxic damage due to ethanol being the most frequent finding (table 3). In spite of a thorough history and assessment of the usual markers of alcohol abuse significant alcohol toxicity was

discovered only in the biopsy in 17 patients (7.9 %). This is quite a relevant finding as alcohol intake is a well known modifier of disease progression in chronic hepatitis C [12]. In one case each autoimmune and granulomatous hepatitis were found. The prevalence of granulomata was thus much rarer in our series (0.5 %) than the 10 % reported recently in hepatitis C [13].

This report deals with only day-care procedures which has been the standard in our institution for the past 20 years; this has been shown to markedly enhance patient acceptance [11]. It could bias the findings somewhat, however, since patients with advanced liver disease, most patients after orthotopic liver transplantation and patients with focal lesions were hospitalized for liver biopsy and not analyzed in the present report. We had only one major complication in this series which could have been avoided had sonography been performed the day of the biopsy. Thus, Lindor *et al.* reported that sonography markedly reduced morbidity and hospitalization [14].

Of particular interest when investigating the diagnostic value of liver biopsy is the marker negative patient. This constellation was found in 8.8 % of our patients, a percentage similar to that recently reported by other investigators [15,16]. In the series of Daniel *et al.* mostly steatosis was detected [15]; therefore, they found liver biopsy only useful for staging. Our results are more resembling those of Berasain and colleagues [16] where relevant pathology other than steatosis or NASH was detected in almost half of the patients. In our series there were several unexpected diagnoses made which affected patient management (table 4). Berasain *et al.* also found HBV-DNA or HCV-RNA in 26.7 % of patients with marker negative liver disease [16]; in our series we did not test routinely for these viruses when the usual markers were negative.

The value of liver biopsy in staging remains uncontested [17]; in line with other investigations [18,19] we found none of the usual liver tests to predict fibrosis or cirrhosis. Platelets and prothrombin time were significantly lower in patients with stage 4 disease but the overlap was too large to make this a clinically useful parameter; this is in line with a recent investigation in hepatitis C where the Bonacini score (consisting of AST/ALT ratio, platelet count and INR) was unable to reliably predict stage [19]. The only test differing significantly between the five stages was the galactose elimination capacity. This is in line with a smaller series of patients with hepatitis C reported by Mion and colleagues [20]; again the overlap was too large to give this difference clinical significance, however. Besides the staging, the liver biopsy gives several clues with respect to anticipated response to interferon treatment [21].

To which extent markers of fibrosis such as PIIIP, collagen IV and serum hyaluronate could replace the liver biopsy in staging cannot be answered from our study since none of these markers had been measured in our patients. However, good specificity and sensitivity has been reported by several investigators, in particular for hyaluronate [22–24]. Recently, a combination of different serum proteins, serum bilirubin and g-glutamyl-transpeptidase has been reported to be useful in predicting fibrosis in patients with chronic hepatitis C [25].

## Conclusion

In conclusion, even with advanced serological testing unrecognized diseases can be found in liver biopsy in a sizeable number of patients. In the present study this was particularly true for hepatitis C, where additional diagnoses – in particular alcoholic liver disease – was found in the biopsy in over half of all patients. This leads to changes in management in about 5 % of patients. Liver biopsy remains a useful diagnostic tool not only for staging, but also for diagnostic purposes.

## Competing interests

none

## Acknowledgements

The authors thank Ms R. Steiner-Stingelin for editorial help. We appreciate the help and dedication of the nurses in contributing to all our studies. JR is supported by a grant from the Swiss National Foundation for Scientific Research (63476.00).

## References

1. Kuo G, Choo QL, Alter HJ, Gitnick GL, Redeker AG, Purcell RH, *et al.*: **An assay for circulating antibodies to a major etiologic virus of human non-A non-B hepatitis.** *Science* 1989, **244**:362-364
2. Alvarez E, Berg PA, Bianchi FB, Bianchi L, Burroughs AK, Cancado EL, *et al.*: **International Autoimmune Hepatitis Group Report: review of criteria for diagnosis of autoimmune hepatitis.** *J Hepatol* 1999, **31**:929-938
3. Obermayer-Straub P, Strassburg CP, Manns MP: **Autoimmune hepatitis.** *J Hepatol* 2000, **32**:181-197
4. Giger A, Reichen J: **Die Leberbiopsie beim ambulanten Patienten. Diagnostische Wertigkeit im Vergleich zu konventionellen und quantitativen Leberfunktionsprüfungen.** *Schweiz Med Wochenschr* 1993, **123**:1474-1481
5. Batts KP, Ludwig J: **Chronic hepatitis. An update on terminology and reporting.** *Am J Surg Pathol* 1995, **19**:1409-1417
6. Heri M, Bircher J: **Die Galaktose-eliminationskapazität- ein zuverlässiger Test zur quantitativen Erfassung der Leberfunktion.** *Schweiz Med Wochenschr* 1971, **101**:735-736
7. Reichen J, Widmer T, Cotting J: **Accurate prediction of death by serial determination of the galactose elimination capacity in primary biliary cirrhosis-A comparison with the Mayo model.** *Hepatology* 1991, **14**:504-510
8. Miotti T, Bircher J, Preisig R: **The 30 minute aminopyrine breath test: Optimization of sampling times after intravenous administration of 14C-aminopyrine.** *Digestion* 1988, **39**:241-250
9. Sorbi D, McGill DB, Thistle JL, Therneau TM, Henry J, Lindor KD: **An assessment of the role of liver biopsies in asymptomatic patients with chronic liver test abnormalities.** *Am J Gastroenterol* 2000, **95**:3206-3210
10. VanNess MM, Diehl AM: **Is liver biopsy useful in the evaluation of patients with chronically elevated liver enzymes?** *Ann Intern Med* 1989, **111**:473-478

11. Cadranel JF, Rufat P, Degos F, Grp Epidemiology French Assoc Stu: **Practices of liver biopsy in France: Results of a prospective nationwide survey.** *Hepatology* 2000, **32**:477-481
12. Wiley TE, McCarthy M, Breidi L, Layden TJ: **Impact of alcohol on the histological and clinical progression of hepatitis C infection.** *Hepatology* 1998, **28**:805-809
13. Goldin RD, Levine TS, Foster GR, Thomas HC: **Granulomas and hepatitis C.** *Histopathology* 1996, **28**:265-267
14. Lindor KD, Bru C, Jorgensen RA, Rakela J, Bordas JM, Gross JB, et al: **The role of ultrasonography and automatic-needle biopsy in outpatient percutaneous liver biopsy.** *Hepatology* 1996, **23**:1079-1083
15. Daniel S, Ben Menachem T, Vasudevan G, Ma CK, Blumenkehl M: **Prospective evaluation of unexplained chronic liver transaminase abnormalities in asymptomatic and symptomatic patients.** *Am J Gastroenterol* 1999, **94**:3010-3014
16. Berasain C, Betes M, Panizo A, Ruiz J, Herrero JI, Civeira MP, et al: **Pathological and virological findings in patients with persistent hypertransaminasaemia of unknown aetiology.** *Gut* 2000 Sep; **47**:429-435
17. Bravo AA, Sheth SG, Chopra S: **Current concepts: Liver biopsy.** *N Engl J Med* 2001, **344**:495-500
18. Heintges T, Mohr L, Hensel F, Petry W, Borchard F, Häussinger D, et al: **Value of liver biopsy prior to interferon therapy for chronic viral hepatitis.** *Dig Dis Sci* 1998, **43**:1562-1565
19. Saadeh S, Cammell G, Carey WD, Younossi Z, Barnes D, Easley K: **The role of liver biopsy in chronic hepatitis C.** *Hepatology* 2001, **33**:196-200
20. Mion F, Rousseau M, Scoazec JY, Berger F, Minaire Y: **[13C]-galactose breath test: correlation with liver fibrosis in chronic hepatitis C.** *Eur J Clin Invest* 1999, **29**:624-629
21. Kaserer K, Fiedler R, Steindl P, Müller CH, Wrba F, Ferenci P: **Liver biopsy is a useful predictor of response to interferon therapy in chronic hepatitis C.** *Histopathology* 1998, **32**:454-461
22. Oberti F, Valsesia E, Pilette C, Rousselet MC, Bedossa P, Aubé C, et al: **Noninvasive diagnosis of hepatic fibrosis or cirrhosis.** *Gastroenterology* 1997, **113**:1609-1616
23. Castera L, Hartmann DJ, Chapel F, Guettier C, Mal F, Lons T, et al: **Serum laminin and type IV collagen are accurate markers of histologically severe alcoholic hepatitis in patients with cirrhosis.** *J Hepatol* 2000, **32**:412-418
24. Teare JP, Sherman D, Greenfield SM, Simpson J, Bray G, Catterall AP, et al: **Comparison of Serum Procollagen-III Peptide Concentrations and PGA Index for Assessment of Hepatic Fibrosis.** *Lancet* 1993, **342**:895-898
25. Imbert-Bismut F, Ratziu V, Pieroni L, Charlotte F, Benhamou Y, Poynard T, et al: **Biochemical markers of liver fibrosis in patients with hepatitis C virus infection: a prospective study.** *Lancet* 2001, **357**:1069-1075

Publish with **BioMed Central** and every scientist can read your work free of charge

"BioMedcentral will be the most significant development for disseminating the results of biomedical research in our lifetime."

Paul Nurse, Director-General, Imperial Cancer Research Fund

Publish with **BMC** and your research papers will be:

- available free of charge to the entire biomedical community
- peer reviewed and published immediately upon acceptance
- cited in PubMed and archived on PubMed Central
- yours - you keep the copyright



BioMedcentral.com

Submit your manuscript here:

<http://www.biomedcentral.com/manuscript/>

[editorial@biomedcentral.com](mailto:editorial@biomedcentral.com)