

# GLASGOW MEDICAL JOURNAL

VOL. 33 (Vol. 151 Old Series).

JULY 1952

No. 7

THE JOURNAL OF THE ROYAL MEDICO-CHIRURGICAL SOCIETY OF GLASGOW

## HAEMOLYTIC ANAEMIAS OF VARIOUS TYPES TREATED WITH ACTH AND CORTISONE.

Report of Ten Cases, including One of Acquired Type in which  
Erythropoietic Arrest occurred during a Crisis.

L. J. DAVIS, M.D., F.R.C.P., F.R.F.P.S.G.,  
ARTHUR C. KENNEDY, M.B., Ch.B., F.R.F.P.S.G., M.R.C.P.Ed.,  
A. G. BAIKIE, M.B., Ch.B.\* and  
ALEXANDER BROWN, M.D., F.R.C.P.Ed., F.R.F.P.S.G.

from the University Department of Medicine, the Royal Infirmary, Glasgow.

Shortly after the introduction of cortisone and ACTH into therapeutics the effects of these substances in various haematological disorders were observed by investigators in the United States. Promising results in certain types of acquired haemolytic anaemia were first reported by Dameshek (1950) and by Gardner (1950). These authors subsequently described their investigations in greater detail and confirmed their earlier results in a larger group of patients suffering from acquired haemolytic anaemia (Dameshek *et al.*, 1951; Gardner *et al.*, 1951). Wintrobe *et al.* (1951) also reported beneficial results in three of four cases of acquired haemolytic anaemia. In this country Davidson *et al.* (1951) reported a successful trial in one case of acquired haemolytic anaemia and negative results following short courses of treatment in two cases of congenital acholuric jaundice.

These reports have become generally accepted as confirming the view that favourable results are likely to be obtained only in those types of acquired haemolytic anaemia which show evidence of abnormal antibody production as indicated by a positive Coombs test or similar reaction. It should be noted, however, that there appear to have been very few clinical trials in congenital acholuric jaundice.

Since supplies of cortisone and ACTH became available to us in February, 1951, we have attempted to assess their effect in as many types of haemolytic anaemia as possible. The results in the majority of our cases have been summarized in a report to the Medical Research Council (1952), and we now present a more detailed account of our investigations.

\* McIntyre Clinical Research Scholar, Glasgow Royal Infirmary.

## MATERIAL, AND METHODS.

The clinical material consisted of ten patients with haemolytic anaemia. Four were of the idiopathic acquired variety, four were of the congenital acholuric type, while the remaining two were symptomatic haemolytic anaemias.

The laboratory methods employed throughout were those in standard use. Daily observations on the direct eosinophil count were made by the method of Randolph (1944). Particular mention may be made of the urobilinogen assays and tests for the presence of antibodies. Faecal urobilinogen excretion was determined quantitatively by the method of Watson on a four-day faecal collection, the upper level of normal being taken as 280 mg. per day (Watson, 1936). Urinary urobilinogen was tested for qualitatively in fresh urine specimens by Ehrlich's aldehyde reagent, which was prepared with analytical quality hydrochloric acid; chloroform extraction was carried out to eliminate fallacies (Wilson & Davidson, 1949). In some of the cases urinary urobilinogen was determined quantitatively on a 24-hour collection (Watson, 1936). In performing the Coombs test the blood samples were kept at 4°C. and 37°C. until the cells had been separated and washed, except in Case 2 prior to the first period of treatment when the separation and washing were performed at room temperature. In all cases the test was performed with controls. In three of the four cases in which a positive Coombs test was obtained the titre was determined with two anti-human globulin sera obtained from different sources. Auto-agglutinins were tested for by suspending the patient's red cells in both saline and albumin. Evidence of auto-haemolysis was sought by the simple procedure of incubating heparinized venous blood under paraffin (Dacie *et al.*, 1938).

When supplies of cortisone and ACTH permitted, relatively high dosage was employed in the hope that any beneficial effect exerted by these substances would be readily apparent in a relatively short term study. With the exception of a short course of intravenous ACTH in Case 4, ACTH and cortisone were given by intramuscular injection; ACTH at six-hour intervals and cortisone twelve-hourly. In all the patients clinical and radiological examination of the lungs was carried out before treatment was started, to exclude tuberculosis. Dietary salt was restricted during the period of treatment, and potassium chloride 3 g. per day given by mouth. Fluid intake and output were recorded, and the patients were weighed three times weekly. Careful clinical watch was kept for the development of oedema or alteration in facial appearance. Blood pressure readings were taken daily. Plasma electrolyte levels were estimated before and at frequent intervals during treatment, and electrocardiograms were performed periodically.

## CASES OF IDIOPATHIC ACQUIRED HAEMOLYTIC ANAEMIA.

*Case 1.* Bernard McL., a foundry worker aged 40 years, was admitted to hospital on the present occasion on 25th January, 1951. He had been well until 1949 when he developed jaundice and was admitted to another hospital where investigations revealed the characteristic features of a severe haemolytic anaemia. Splenectomy was performed in September, 1949, but had no beneficial effect on the haemolytic process. From the time of the operation until the present admission repeated transfusions had been required, a total of ninety pints of blood being given. There was no previous history, or family history, of jaundice or anaemia.

*Clinical examination.* The patient was pale and icteric. The liver was palpable one inch below the right costal margin. No other significant abnormalities were detected.

*Laboratory findings.* During the eight-day period of observation before therapy was commenced the blood levels fell from R.B.C. 1.93 million per cu.mm., Hb. 61



per cent, to R.B.C. 1.37 million per cu.mm., Hb. 47 per cent, while the reticulocyte count ranged from 8 to 21 per cent and the white cell count remained elevated (10-22,000/cu.mm.), due to a polymorphonuclear increase. Stained blood films showed polychromasia, microspherocytosis, and numerous normoblasts. Numerous iron-positive inclusion bodies of the Pappenheimer type (McFadzean & Davis, 1947) were present in nucleated and non-nucleated red cells. Sternal puncture revealed very active normoblastic erythropoiesis; inclusion bodies of the Pappenheimer type were present in the red cell precursors. The white cells were normal. Erythrocyte fragility in hypotonic saline was increased, haemolysis commencing at 0.64 per cent and being complete at 0.40 per cent. The direct Coombs test was positive on cells separated from serum at room temperature. An auto-agglutinin was demonstrated in albumin at a titre of 1:64 at 4°C. The acid haemolysis test was negative, as also were the Wassermann and Kahn reactions. Faecal urobilinogen excretion was greatly increased (4,316 mg./day). Urobilinogen was demonstrable qualitatively in the urine and one estimation showed a urinary excretion of 18 mg. in twenty-four hours. The icteric index was 22.

*Treatment and results.* Treatment was maintained for twenty-five days, a total of 2,000 mg. cortisone and 1,100 mg. ACTH being given. The daily dosage of ACTH was for the greater part 100 mg., and that of cortisone 100-200 mg. The patient was in a haemolytic crisis when treatment was started, and by the third day of treatment his condition had deteriorated so much that it was considered necessary to give him two pints of blood. A further transfusion of two pints had to be given on the ninth day of treatment. Thereafter the patient's clinical condition showed some improvement, and as will be seen by reference to Fig. 1, there was a

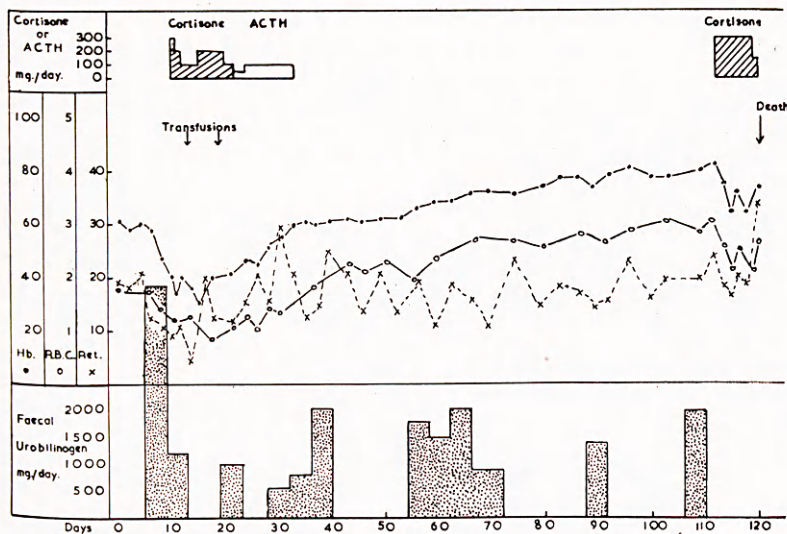


Fig. 1. Case 1. Acquired haemolytic anaemia (post-splenectomy). Slight rise of blood levels after cortisone but persistence of marked haemolysis with ultimate death.

progressive although moderate rise in the red cell count during a period of about three months following his first course of treatment. Despite this improvement, the patient's clinical condition remained unsatisfactory, and evidence of excessive haemolysis persisted. He was never free from jaundice, the excretion of faecal urobilinogen remained very high, and reticulocytosis persisted (11-25%). The

Coombs test repeated during treatment and on three occasions after treatment (on the 37th, 63rd & 110th days) was positive on all occasions. There were two minor haemolytic episodes of about twenty-four hours duration, characterized by lumbar pain, vomiting and increased jaundice. A third and more severe episode was accompanied by rapid clinical deterioration. The second course of cortisone was then started, but did not appear to exert any beneficial influence and death occurred ten days after the onset of this crisis.

Before and after hormone therapy the eosinophil count ranged between 232 and 522 per cu.mm. During both courses of treatment eosinophils were frequently absent and were never more than 88 per cu.mm.

At autopsy the changes characteristic of haemolytic anaemia were found.

*Comment.* The administration of cortisone and ACTH was followed by a rise in the patient's red cell count and by some temporary amelioration of his clinical state, but his subsequent course shows that any benefit produced was neither substantial nor permanent.

*Case 2.* Mrs. Eliz. B., a housewife aged 62 years, was admitted to hospital on 23rd February, 1951, complaining of progressive weakness, dyspnoea on exertion and increasing pallor, of about twelve months' duration. There was no past history suggestive of haemolytic episodes. During the last five years she had been under psychiatric treatment for recurrent depression. There was no family history of jaundice or anaemia.

*Clinical examination.* She was an obese pale woman. No obvious evidence of jaundice was present. The spleen was enlarged two inches and the liver one inch below the costal margin.

*Laboratory findings.* Blood examination showed a moderately severe anaemia associated with persistent reticulocytosis, and a normal total and differential white cell count (R.B.C. 2.76 million/cu.mm., Hb. 68%, reticulocytes 10%, W.B.C. 6,000/cu.mm.). Stained blood films showed polychromasia and a few nucleated red blood cells. Microspherocytosis was not evident. Sternal puncture revealed very active normoblastic erythropoiesis. No inclusion bodies of the Pappenheimer type were observed. The white cells were normal. Erythrocyte fragility in hypotonic saline was not increased, haemolysis commencing at 0.48 per cent and being complete at 0.34 per cent. The Coombs test was positive at 4°C. and at 37°C. in titres of 1 : 320 and 1 : 80 respectively. No auto-agglutinins were detected. The Wassermann and Kahn reactions were negative. As estimated over two four-day periods prior to treatment, the faecal excretion of urobilinogen was much increased (975 mg./day : 1,089 mg./day). Urinary urobilinogen excretion was 2.1-1.4 mg. per day.

*Treatment and results.* Cortisone in a total dosage of 5,175 mg. was given over a period of twenty-six days. Within a few days of commencement of treatment a definite improvement occurred in the patient's general condition, and, as will be seen from Fig. 2, this was accompanied by a sustained rise in the red cell count and a fall in reticulocytes to normal levels. The output of urobilinogen in the faeces fell to lower, though still abnormal levels (560 mg./day). When repeated on the fifth day of treatment, the Coombs test was negative at 37°C. and positive at 4°C. in a titre of 1 : 20. On the twentieth day of treatment, after 4,000 mg. of cortisone, positive results at a titre of 1 : 20 at 37°C. and 1 : 40 at 4°C. were obtained. The spleen became smaller until, by the end of the period of treatment, it was no longer palpable. Before and after treatment the direct eosinophil count varied from 322 to 88 per cu.mm.; during treatment it ranged between 0 and 22 per cu.mm.

Unfortunately, the patient's mental state which, as already noted, had been unsatisfactory for some years previously, showed a serious deterioration which



necessitated her transfer to a mental hospital, where her subsequent course was followed by us by the courtesy of the Medical Superintendent. No haematological relapse occurred for about six months but thereafter there was a gradual but progressive fall in the haemoglobin and red cell levels with recurrence of reticulocytosis and enlargement of the spleen. Death took place twelve months after cessation of cortisone therapy the blood levels being: Hb. 29%, R.B.C. 0.75 million/cu.mm., reticulocytes 26%. Throughout this period she remained insane.

*Comment.* A significant improvement in the patient's haemolytic process and in her clinical state followed the administration of cortisone. We are of the opinion that there is little doubt that this effect can be attributed to the cortisone. Her subsequent course, however, shows that this beneficial effect, although it was well sustained for a time, was not permanent since she gradually relapsed after some months and eventually died. It is regrettable that her mental state rendered the question of splenectomy impracticable.

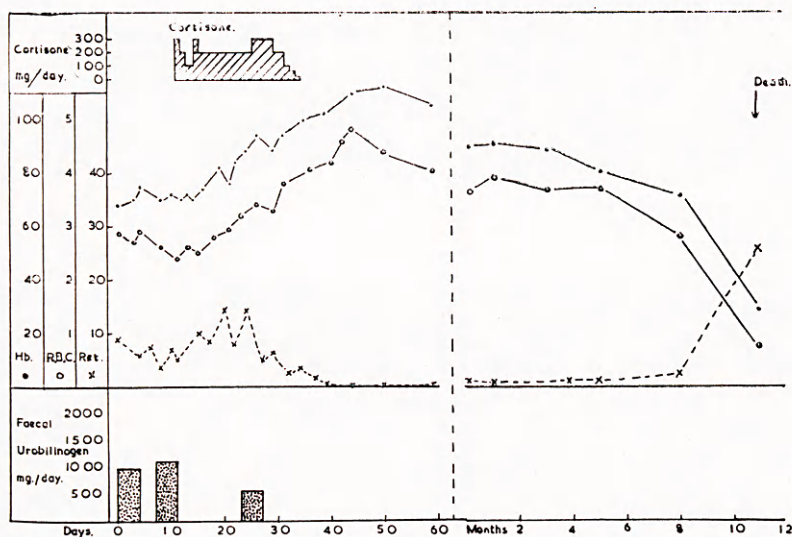


Fig. 2. Case 2. Acquired haemolytic anaemia. Remission of a few months duration induced by cortisone. Subsequent fatal relapse. Note change of scale on abscissa.

*Case 3.* Mrs. Mary D., a housewife aged 48 years, was admitted to hospital on 5th April, 1951. She had been well until her first pregnancy at the age of 28 when she became anaemic. She also developed anaemia during a second pregnancy five years later. At this time splenomegaly and urobilinuria were noted. In 1947 she developed biliary colic. Gall-stones were shown to be present, but no surgical treatment was undertaken. There was no family history of jaundice or anaemia.

*Clinical examination.* She was a pale, well-nourished woman with slight jaundice. The spleen was enlarged two inches below the costal margin. The liver was not enlarged, and no other significant abnormalities were noted.

*Laboratory findings.* Blood examination revealed a moderately severe anaemia with a persistent reticulocytosis, and a normal total and differential white cell count (R.B.C. 2.27 million/cu.mm., Hb. 61%, reticulocytes 8%, W.B.C. 6,200/cu.mm.). Blood films showed polychromasia and scanty nucleated red blood cells. There was no microspherocytosis. Examination of the sternal marrow revealed very active

normoblastic erythropoiesis. No inclusion bodies of the Pappenheimer type were observed in any of the red cell series. The white cells were normal. Erythrocyte fragility in hypotonic saline was normal, haemolysis commencing at 0.44 per cent and being complete at 0.32 per cent. The Coombs test was negative at 4°C. and 37°C. and no auto-agglutinins were detected. The acid haemolysis test, and the Wassermann and Kahn reactions were negative. The faecal excretion of urobilinogen was 1,568 mg. per day. Urobilinogen was present in the urine. The serum bilirubin concentration was 3.2 mg. per cent.

*Treatment and results.* Initially cortisone was given in dosage of 200 mg. daily for sixteen days (Fig. 3). During this period the red cell level rose slightly and the faecal excretion of urobilinogen, while remaining excessive, fell to 490 mg. per day

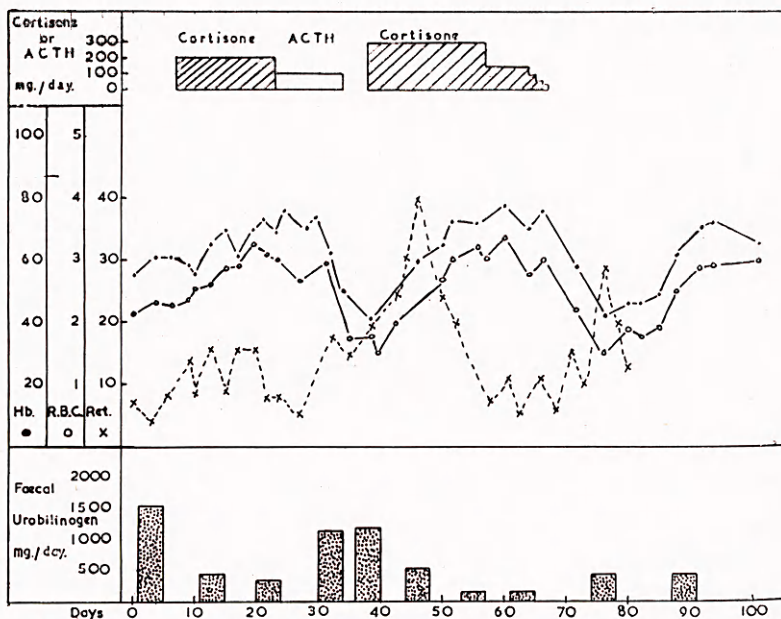
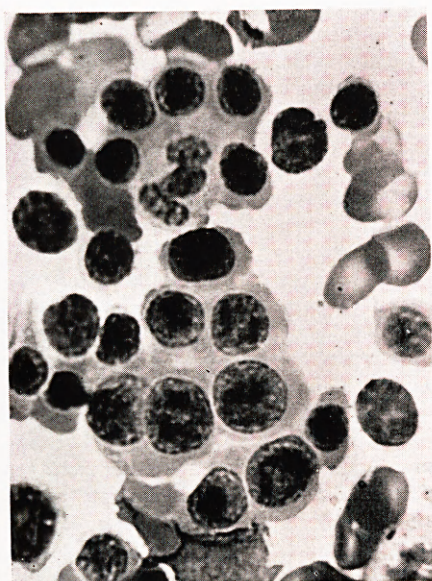


Fig. 3. Case 3. Acquired haemolytic anaemia. Cyclical variations in blood levels.

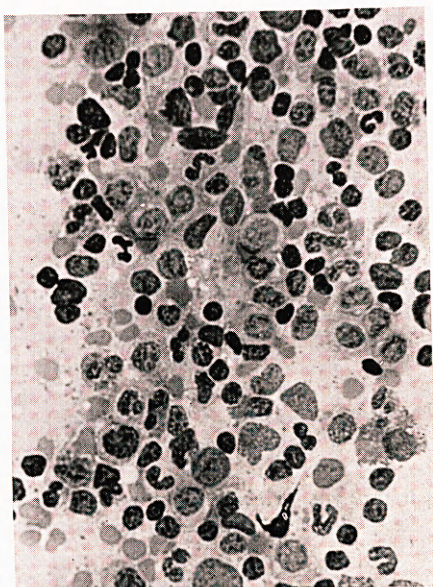
(5th-8th day) and 372 mg. per day (14th-17th day). ACTH 100 mg. daily was then given for eleven days during which time the red cell level fell and the faecal urobilinogen rose (1,170 mg. per day). After an interval of four days without treatment a second and more intensive course of cortisone was given. During this course the red cell count rose steadily and the faecal excretion of urobilinogen fell to 525 mg. per day, 176 mg. per day and 176 mg. per day. After withdrawal of cortisone the red cell level fell again and the faecal excretion of urobilinogen rose to 433 mg. per day. Eight days later, however, a spontaneous rise in the blood levels occurred which was similar in degree to the preceding rises which had occurred during treatment. At no time was there any discernible change in the size of the spleen or liver. Before and after treatment the direct eosinophil count ranged from 222 to 133 per cu.mm. During treatment it was never higher than 22 per cu.mm.

Close observation of the patient after discharge from hospital showed that the haemolytic process continued as during the hospital admission. An uneventful splenectomy was performed after an interval of eight months. Since then, the patient has been well during a period of four months. A recent blood count gave the following figures: Hb. 98%, R.B.C. 5.23 million/cu.mm.

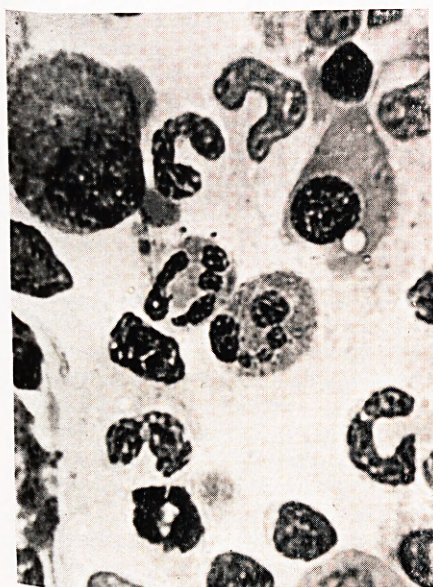




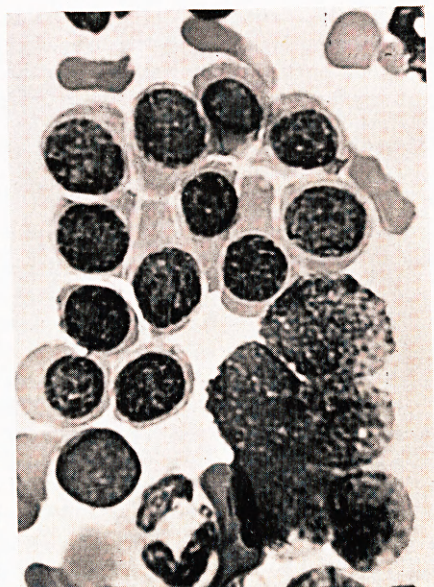(a)



(b)



(c)



(d)

Fig. 4. Case 4. Bone marrow smears from a case of idiopathic acquired haemolytic anaemia in which a haemolytic crisis was associated with almost complete aplasia of erythroid elements:—

- (a) Before crisis : Active normoblastic erythropoiesis ( $\times 1000$ ).  
 (b) & (c) During crisis : Cellular myeloid picture with absence of normoblasts ( $\times 350$  &  $1030$ ).  
 (d) After crisis : Active normoblastic erythropoiesis ( $\times 1000$ ).



*Comment.* Some degree of haematological improvement occurred during each course of therapy, but for reasons discussed later these remissions are not considered to be significantly different from those occurring spontaneously before and after treatment. We are therefore of the opinion that in this case the effect of treatment was essentially negative. It should be noted that the Coombs test was negative.

*Case 4.* Wm. W., a food packer aged 46 years, was admitted to another hospital on 22nd December, 1951, with the characteristic features of a severe haemolytic anaemia. During the past five months he had complained of progressive tiredness, dyspnoea, and had become pale and jaundiced. A year previously he had been treated for pneumonia with sulphonamide drugs. There was no personal or family history of previous anaemia or jaundice. The red cell count was 2 million per cu.mm., the haemoglobin 40 per cent, the white cell count 4,000 per cu.mm. and the reticulocytes 8 per cent. Sternal marrow biopsy revealed active normoblastic erythropoiesis. The direct Coombs test was negative. Cold agglutinins were found in a titre of 1 : 8. The Wassermann and Kahn reactions were negative. The faecal urobilinogen excretion was markedly elevated. His condition progressively deteriorated, and the haemoglobin fell to low levels despite several blood transfusions. On the twenty-first day a further sharp deterioration in his condition occurred, and he was transferred to the Royal Infirmary for trial with ACTH.

*Clinical examination.* The patient was extremely pale and deeply jaundiced. His pulse was very rapid and the tension was poor, dyspnoea was evident and he was clearly in a state of severe peripheral failure. Gross enlargement of the spleen was present, the lower border being two inches below the umbilicus.

*Laboratory findings.* Blood examination revealed R.B.C. 600,000 per cu.mm., Hb. 14 per cent, W.B.C. 500 per cu.mm., platelets 78,000 per cu.mm. No reticulocytes were seen. There was no spherocytosis. Sternal puncture performed at this time showed a picture which was quite unlike that revealed by the first puncture (Fig. 4). The marrow was still hypercellular but very few normoblasts were seen. Most of the cells belonged to the myeloid series. Indeed the picture was quite unlike that of a haemolytic anaemia. No inclusion bodies of the Pappenheimer type were seen either in the peripheral blood or in the marrow. The Coombs test was repeated and was now found to be positive at 1 : 40 at 37°C. and at 1 : 2560 at 4°C. Cold agglutinins in serum were demonstrable in a titre of 1 : 32. Red cell fragility in hypotonic saline was normal. Serum bilirubin was 4.2 mg. per cent.

*Treatment and results.* Treatment with ACTH was commenced immediately, 75 mg. being given intravenously during the first thirty-six hours. Thereafter 25 mg. were given intramuscularly at six-hour intervals for eleven days and then tapered off over two days. The total ACTH administered was 1,250 mg. Within an hour of commencement of treatment improvement in the patient's clinical condition was noted: the features of peripheral circulatory failure lessened, and subjective improvement occurred. In view of the patient's dangerously low blood levels, transfusions were commenced two hours after his admission to hospital. These were continued during the next three days totalling twelve pints. These massive transfusions were deemed necessary because successive transfusions showed little effect in raising the haemoglobin levels; after ten pints had been given the haemoglobin was only 38 per cent. Subsequently, however, the blood levels rose satisfactorily (Fig. 5) without further transfusions and this was accompanied by a further striking improvement in the patient's clinical state. The reticulocytes remained at less than 1 per cent, the white cell count below 4,000 per cu.mm. and platelets less than 40,000 per cu.mm. On the sixth day of treatment reticulocytes were present although still scanty, and the white cell count rose to 8,000 per cu.mm. and platelets to 266,000



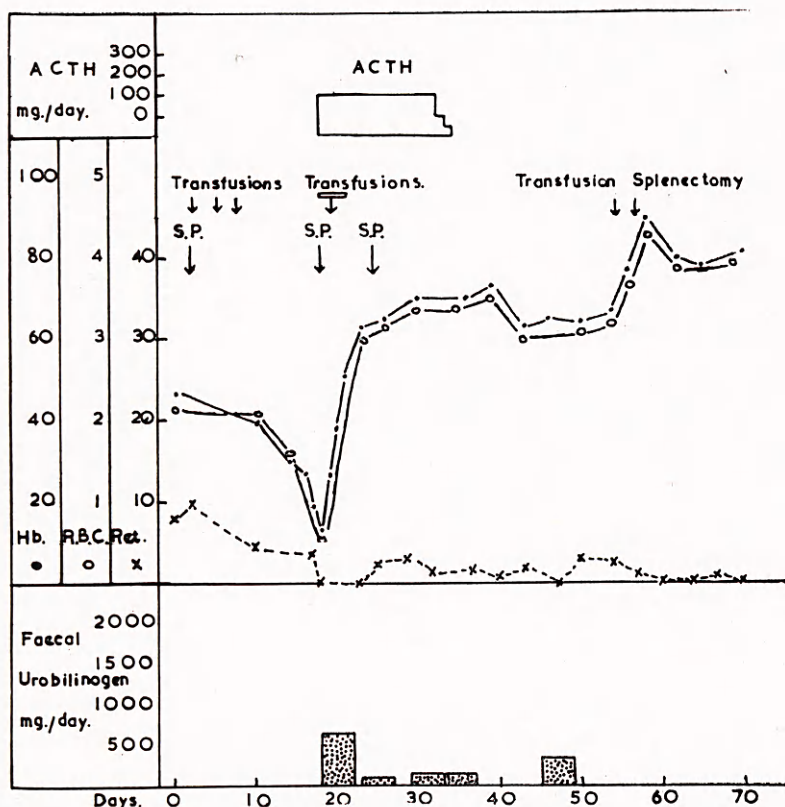


Fig. 5. Case 4. Acquired haemolytic anaemia. Recovery from severe haemolytic crisis (S.P. = sternal puncture—see Fig. 4).

per cu.mm. Examination of the sternal marrow on the sixth day revealed extremely active normoblastic erythropoiesis (Fig. 4), in striking contrast to the appearances of five days before. The direct Coombs test was repeated on the same day when it was found to be positive in titres of 1 : 20 and 1 : 80 at 37°C. and 4°C. respectively. Auto-agglutinins were then demonstrable only in titres of 1 : 2 in albumin at 37°C. and in albumin and in saline at 4°C. The faecal excretion of urobilinogen which was 660 mg. per day during the first four days of treatment fell to 99 mg. per day. The serum bilirubin fell to normal levels. During the remaining ten days of ACTH therapy there was continued clinical and haematological improvement and slight diminution of spleen size. No clinical or haematological relapse followed the cessation of hormone therapy, although the faecal excretion of urobilinogen rose to 363 mg. per day, and considerable enlargement of the spleen persisted.

In view of the splenomegaly it was considered advisable that the spleen should be removed. This was successfully accomplished fourteen days later. The spleen weighed 1,700 g. and histologically showed the changes characteristic of haemolytic anaemia. The patient made a rapid recovery from the operation and has remained well since. The blood levels three months after the operation were: Hb. 99%, R.B.C. 4.90 million/cu.mm., reticulocytes less than 1%. The Coombs test was repeated on three occasions after treatment and has remained positive. On the last occasion, three months after splenectomy, the titre was 1 : 40 at 37°C and 1 : 80 at 4°C.

*Comment.* It might be argued that the recovery shown by this patient from his extremely parlous state is attributable to the massive blood transfusions he received. It was, however, our conviction at the time that the sudden improvement in his clinical state did not occur as the result of blood transfusions alone, and that the effect of ACTH was beneficial. Indeed, we are of the opinion that the patient's life was saved by it. It is, of course, impossible to estimate how long the remission would have been maintained if splenectomy had not been performed. An interesting feature in this case was the marrow changes that occurred at the time of the crisis. This feature will be discussed in more detail later.

#### CASES OF SYMPTOMATIC HAEMOLYTIC ANAEMIA.

*Case 5.* Miss Janet S., a book-keeper aged 18 years, was admitted to hospital on 12th December, 1950, with the diagnosis of disseminated lupus erythematosus.

*Clinical examination.* The patient was pale and icteric. The characteristic lesions of lupus erythematosus were present on the face, hands and arms. Oedema of the legs and basal râles were present. There was an irregular pyrexia. The spleen and the axillary lymph glands were enlarged. The heart was enlarged and an apical systolic murmur was present.

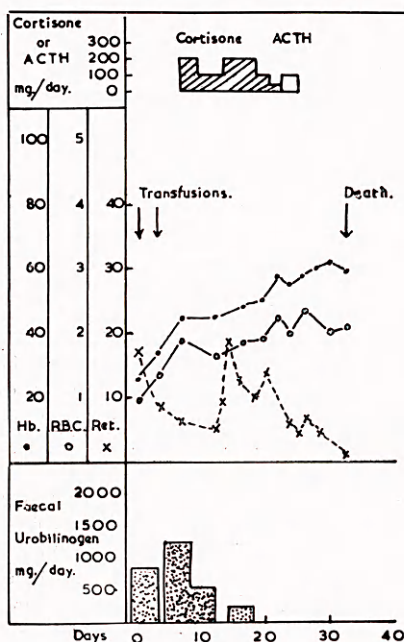


Fig. 6. *Case 5.* Disseminated lupus erythematosus with symptomatic haemolytic anaemia. Slight haematological improvement after cortisone and ACTH (no clinical benefit occurred in this patient).

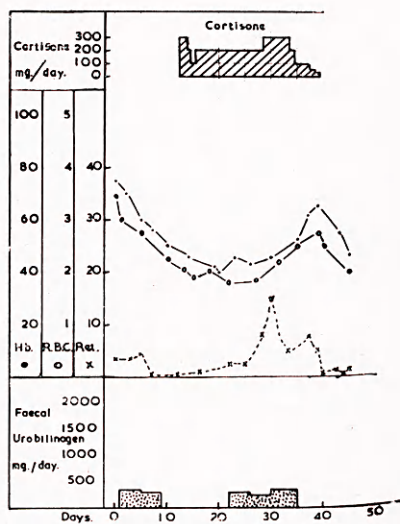


Fig. 7. *Case 6.* Reticulo-sarcoma with symptomatic haemolytic anaemia. Failure of cortisone.

*Laboratory findings.* Blood examination revealed a severe anaemia associated with a high reticulocyte count, a high white cell count, and thrombocytopenia (R.B.C. 0.98 million/cu.mm., Hb. 26%, reticulocytes 17%, W.B.C. 18,000/cu.mm., platelets 80,000/cu.mm.). Stained blood films showed microspherocytosis, polychromasia, and occasional nucleated red cells. Sternal puncture revealed very active normoblastic erythropoiesis. No inclusion bodies of the Pappenheimer type



were seen in any of the red cell series. The white cells were normal. Erythrocyte fragility in hypotonic saline was increased, haemolysis commencing at 0.60 per cent and being complete at 0.48 per cent. The erythrocyte sedimentation rate was 165 mm. in one hour (Westergren). A positive Coombs test was obtained at 4°C. and at 37°C. Auto-agglutinins were demonstrated in saline at titre of 1 : 32 at 37°C. and at titre of 1 : 4 at 4°C. The Wassermann and Kahn reactions were positive. As estimated over two four-day periods, the faecal excretion of urobilinogen was much increased (857 mg./day : 1,283 mg./day). Serum bilirubin was 2.9 mg. per cent. The total plasma proteins were normal but the gamma-globulin fraction was high. Albumin was present in the urine.

*Treatment and results.* Blood levels were raised by transfusion to R.B.C. 1.88 million per cu.mm., and Hb. 45 per cent before cortisone was given. Over a period of eighteen days a total of 2,200 mg. cortisone and 300 mg. ACTH was given (Fig. 6). Red cell and haemoglobin levels rose slightly and the reticulocyte level decreased during the period of treatment. The Coombs test became negative on completion of treatment and auto-agglutinins were no longer demonstrable at 37°C. although they remained demonstrable in low titre (1 : 8) at 4°C. Faecal urobilinogen excretion fell to 588 mg. per day (3rd-6th day of treatment) and later to 253 mg. per day (9th-13th day of treatment). Traces of urobilinogen were present in the urine but were immeasurable. Before treatment eosinophils ranged from 0 to 44 per cu.mm., but during and after hormone therapy none were found. A slight degree of clinical improvement occurred but this was only temporary. The congestive cardiac failure became progressively more severe and the general condition deteriorated although the red cell and haemoglobin levels were maintained. Death occurred eight days after treatment was stopped. At autopsy there was increased marrow activity in the long bones. Small haemorrhages were found in brain and lungs and rheumatic-like vegetations were present on the mitral valve. Histologically, lesions consistent with a diagnosis of acute lupus erythematosus were seen in the skin, in the kidneys, and in the arteries of the brain and spleen.

*Case 6.* Matthew D., an agricultural worker aged 18 years, had been well until 1948 when swelling of the cervical glands occurred. Biopsy revealed the histological features of reticulo-sarcoma. Two courses of x-ray therapy were given and the patient remained in moderate health until November, 1950, when he developed anorexia, listlessness, and pallor. The patient was transferred to our care on 1st March, 1951, for trial with cortisone. There was no family history of anaemia or jaundice.

*Clinical examination.* On 1st March, 1951, clinical examination showed pallor, moderate obesity, and enlargement of the spleen to three-and-a-half inches below the costal margin. No enlargement of the superficial lymph glands was present but prominence of the left hilar shadow was present radiologically. There was no jaundice.

*Laboratory findings.* During the period of observation before treatment was started the blood levels fell from R.B.C. 3.46 million per cu.mm., and Hb. 75 per cent, to R.B.C. 2.26 million per cu.mm., and Hb. 50 per cent. The reticulocytes were elevated to 3.5 per cent. There was a persistent leucopenia. Stained blood films showed anisocytosis, a reduction in the percentage of granular cells, and a high proportion of atypical mononuclear cells with pale blue abundant cytoplasm and large indented, relatively lightly staining, nuclei (neutrophil polymorphs 30%, lymphocytes 36%, atypical mononuclears 34%). No microspherocytes were present. Scanty, small granules of marrow were obtained by sternal puncture. Very active normoblastic erythropoiesis was present and large reticulum cells were scattered

throughout. No inclusion bodies of the Pappenheimer type were observed in any of the red cell series. Erythrocyte fragility in hypotonic saline was normal. The Coombs test was negative at 4°C. and 37°C., and no auto-agglutinins were detected. The acid haemolysis test was negative. The erythrocyte sedimentation rate was 33 mm. in one hour (Westergren). As estimated over two four-day periods prior to treatment the faecal excretion of urobilinogen was slightly increased (350 mg./day : 319 mg./day). Urinary urobilinogen excretion was 10.5 mg. per day on one twenty-four hour collection. The icteric index was within normal levels on three occasions.

*Treatment and results.* Cortisone was given for twenty-seven days, for the most part in a dosage of 200 mg. daily, to a total of 5,275 mg. (Fig. 7). The haemoglobin and red cell levels were falling during the period before treatment was started and they continued to fall for ten days after cortisone was commenced. The levels remained static from the eleventh to nineteenth days of treatment and then gradually rose, but at the end of the twenty-seven days of treatment the levels were essentially the same as at the start. After cortisone was withdrawn a further fall in the haemoglobin and red cell levels occurred. The output of urobilinogen in the faeces showed a slight fall during the period when the blood levels were rising but rose again before cortisone was withdrawn.

During the course of cortisone there was reduction in the size of the spleen and a temporary fall in the erythrocyte sedimentation rate but the general clinical picture was one of deterioration. The patient died at home seven weeks after cortisone was stopped. No autopsy was carried out. At no time before, during, or after therapy were eosinophils found in the peripheral blood.

*Comment.* In both of the cases of symptomatic haemolytic anaemia a slight rise in the red cell counts occurred during the administration of cortisone and ACTH, and in Case 5 a positive Coombs test became negative. In neither case, however, was the effect on blood levels sufficient to warrant a conclusion that the haemolytic process was significantly affected. Moreover the clinical condition of the patients continued to deteriorate and death occurred from the basic disease process in each case. It is therefore concluded that no benefit was obtained.

#### CASES OF CONGENITAL ACHOLURIC JAUNDICE.

*Case 7.* Miss Helen A., kitchen maid aged 56 years, was admitted to hospital on 18th April, 1951. She was first noticed to have jaundice at the age of 13 years and since then it had persisted in varying degree, and she had had attacks of bilious vomiting which tended to lessen in severity and frequency as she grew older. Biliary colic developed at the age of 15 years and in the next two years she underwent three operations for gall-stones; since then she had in this respect been symptom-free. Her mother died in giving birth to her, and of her father she had no recollection. There being no other relatives, she had been brought up in an orphanage. For that reason no detailed family history was obtainable.

*Clinical examination.* The patient was an obese woman and obviously jaundiced. The spleen was enlarged to three inches below the costal margin. There was no enlargement of the liver. No other significant abnormalities were noted.

*Laboratory findings.* Blood examination revealed a mild degree of anaemia associated with a persistently elevated reticulocyte count and a normal total and differential white cell count (R.B.C. 3.40 million/cu.mm., Hb. 80%, reticulocytes 7%, W.B.C. 6,400/cu.mm.). Stained blood films showed polychromasia and microspherocytosis. Sternal marrow puncture revealed very active normoblastic erythropoiesis. No inclusion bodies of the Pappenheimer type were observed in any of the red cell series. The white cells were normal. Erythrocyte fragility in hypotonic



saline was increased, haemolysis commencing at 0.64 per cent and being complete at 0.40 per cent. The Coombs test was negative at 4°C. and 37°C. No auto-agglutinins were detected and the acid haemolysis test was negative. The Wassermann and Kahn reactions were negative. The faecal excretion of urobilinogen was moderately increased (350 mg. per day). Urobilinogen was demonstrable quantitatively in the urine. The icteric index was 55.

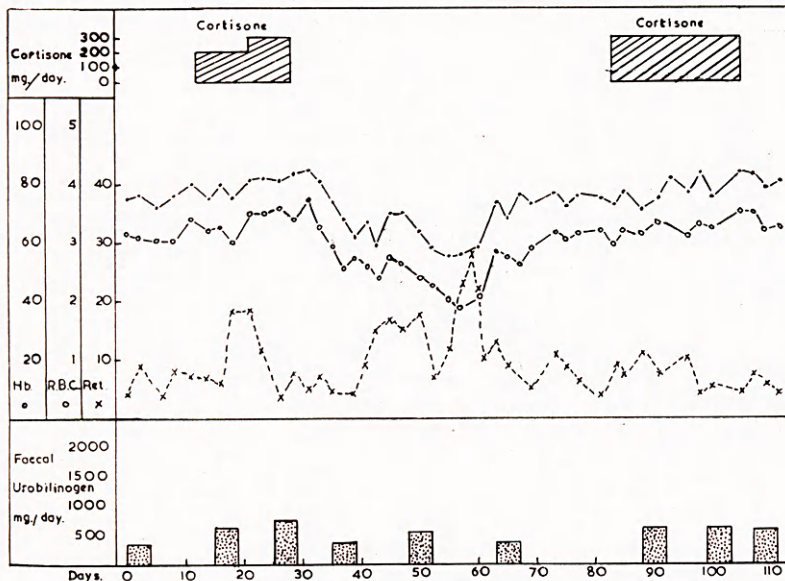


Fig. 8. Case 7. Congenital acholuric jaundice. Failure of cortisone on two occasions to produce remission. Note spontaneous cyclical fall and rise in red cell count.

*Treatment and results.* Cortisone was given initially for sixteen days to a total of 3,900 mg. (Fig. 8). Little alteration in the red cell count occurred, although the reticulocyte level increased. The excretion of urobilinogen in the faeces rose during this period of treatment (640 mg./day : 755 mg./day). After withdrawal of cortisone a steady fall in the red cell level occurred, but this fall was followed by a spontaneous gradual rise. During this period without treatment the faecal excretion of urobilinogen remained excessive (287 mg./day ; 544 mg./day ; 353 mg./day). A second and more intensive course of cortisone was now given the dosage being 300 mg. daily for twenty-two days. This produced no significant alteration in red cell levels and the faecal urobilinogen rose (644 mg./day : 678 mg./day). Neither during nor after treatment was there any change in the size of the spleen. Before and after treatment the eosinophil count varied from 0 to 88 per cu.mm. : during treatment it varied from 0 to 44 per cu.mm.

Over a period of three months after cortisone therapy the blood levels showed a cyclical rise and fall similar to that observed during therapy, and excretion of urobilinogen in the faeces remained excessive. Splenectomy was then performed but unfortunately the patient died in the immediate post-operative period from paralytic ileus. Autopsy revealed the characteristic findings of haemolytic anaemia.

*Case 8.* Mrs. Margaret W., a housewife aged 44 years, was admitted to hospital on 8th May, 1951. She had jaundice on three occasions in childhood, and ever since the age of 20 years she had recurrent attacks of headache, vomiting and shivering. One

year before admission she had ulcers on the left lower leg. Breathlessness on effort and slight swelling of the ankles had been present for nine months. There was no past history of rheumatic fever.

The patient's mother had intermittent jaundice, nausea and vomiting throughout her life. Of the patient's five children, four were found to have increased red cell fragility but only one, a boy of 17 years, was anaemic. This boy showed all the features of acholuric jaundice for which splenectomy was performed with good results.

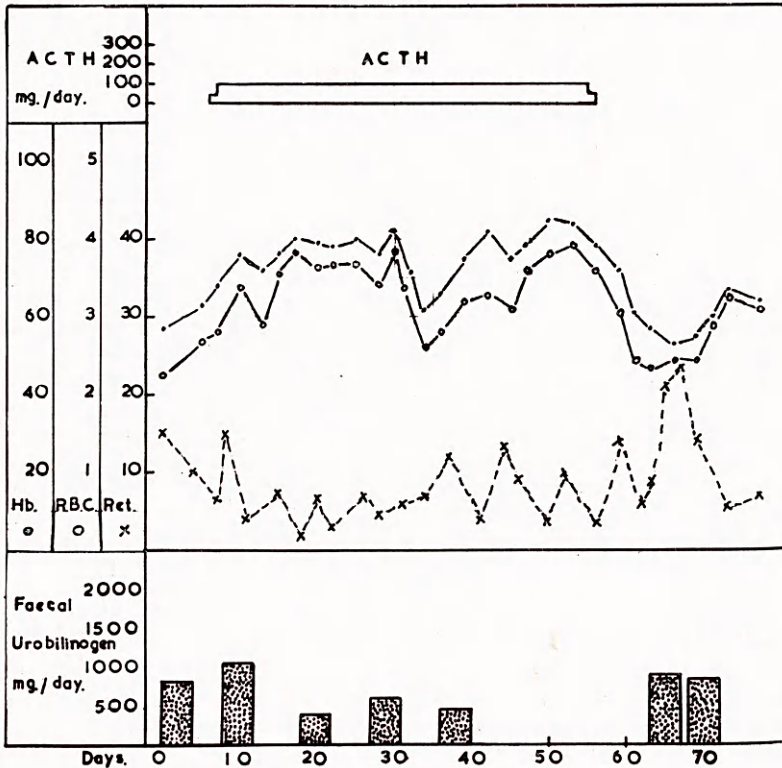


Fig. 9. Case 8. Congenital acholuric jaundice. Failure of ACTH.

*Clinical examination.* She was a pale, well-nourished woman with slight jaundice and a mitral facies. The heart was moderately enlarged and presented the characteristic auscultatory findings of mitral stenosis. There was slight oedema of the ankles and sacral region. The spleen was enlarged three inches below the costal margin. There was no enlargement of the liver.

*Laboratory findings.* Blood examination revealed a moderately severe anaemia associated with a persistent reticulocytosis and a normal total and differential white cell count (R.B.C. 2.24 million/cu.mm., Hb. 57%, reticulocytes 15%, W.B.C. 4,000/cu.mm.). Stained blood films showed polychromasia and microspherocytosis. Bone marrow obtained by sternal puncture was hypercellular and showed very active normoblastic erythropoiesis. No inclusion bodies of the Pappenheimer type were observed in any of the red cell series. The white cells were normal. Erythrocyte fragility in hypotonic saline was increased, haemolysis commencing at 0.60 per cent and being complete at 0.44 per cent. The Coombs test was negative at 4°C. and



37°C. No auto-agglutinins were detected and the acid haemolysis test was negative. The Wassermann and Kahn reactions were negative. The faecal excretion of urobilinogen was greatly increased (813 mg./day). Urobilinogen was demonstrable qualitatively in the urine and quantitative estimation on a twenty-four hour collection gave the figure of 17.6 mg. per day. The icteric index was 15.

*Treatment and results.* ACTH was given for fifty days in a daily dosage of 100 mg. except on the first and last day when a dose of 50 mg. daily was administered (Fig. 9). At the start of treatment the red cell level was rising and this rise continued, a peak value of 3.86 million per cu.mm. being reached on the twenty-fifth day. A sharp fall of the red cell count to 2.70 million per cu.mm. then occurred and was followed by a rise to the previous level which was maintained for the remainder of the period of ACTH therapy. After withdrawal of ACTH the red cell level fell to 2.30 million per cu.mm. This fall, however, was followed by a spontaneous rise to 3.25 million per cu.mm. Throughout the period of ACTH treatment the faecal urobilinogen remained in excess of normal, the values ranging from 1,073 mg. per day to 397 mg. per day. After ACTH was withdrawn the faecal excretion of urobilinogen was 874 mg. per day and 906 mg. per day. During the after treatment splenomegaly remained unchanged.

Before treatment the direct eosinophil count varied from 44 to 133 per cu.mm. ; during the period of therapy it varied from 0 to 88 per cu.mm.

Careful observation of the patient in the year that has elapsed since ACTH therapy has shown that there has been no alteration in the degree of the haemolytic anaemia. The patient refused splenectomy.

*Case 9.* Barbara W., aged 11 years, was admitted to another hospital on 24th June, 1951. She gave a history of anorexia, abdominal pain, vomiting, diarrhoea and increasing pallor over the previous two weeks. Investigations revealed a very severe anaemia associated with reticulocytosis, microspherocytosis, splenomegaly, urobilinuria and jaundice. Blood transfusion was carried out with good effect. She had suffered from attacks of vomiting, abdominal pain and jaundice several times a year from infancy. Her mother, who died in labour in 1947 at home, had suffered from bouts of nausea, vomiting and jaundice throughout her life. No history of anaemia or jaundice in the child's father or two sisters was obtained. She was transferred to this Unit on 8th August, 1951.

*Clinical examination.* Pallor and enlargement of the spleen two and a half inches below the costal margin were the main features. There was no jaundice, and no other significant abnormality.

*Laboratory findings.* Blood examination during a prolonged period of observation before treatment revealed a moderate degree of anaemia associated with a persistent reticulocytosis (6-32%) and a normal total (5,000/cu.mm.) and differential white cell count. As will be seen from Fig. 10 the haemoglobin and red cell levels fell spontaneously from peak values of 88 per cent and 4.2 million per cu.mm. respectively to 62 per cent and 2.3 million per cu.mm. and then rose to reach immediate pre-treatment levels of 70 per cent and 3.04 million per cu.mm. Stained blood films showed polychromasia and microspherocytosis. Sternal marrow puncture revealed a very active normoblastic erythropoiesis. No inclusion bodies of the Pappenheimer type were observed in any of the red cell series. The white cells were normal. Erythrocyte fragility in hypotonic saline was increased, haemolysis commencing at 0.68 per cent and being complete at 0.44 per cent. The Coombs test was negative at 4°C. and 37°C. No auto-agglutinins were detected and the acid haemolysis test was negative. The Wassermann and Kahn reactions were negative. As estimated over three four-day periods prior to treatment with ACTH the faecal excretion of

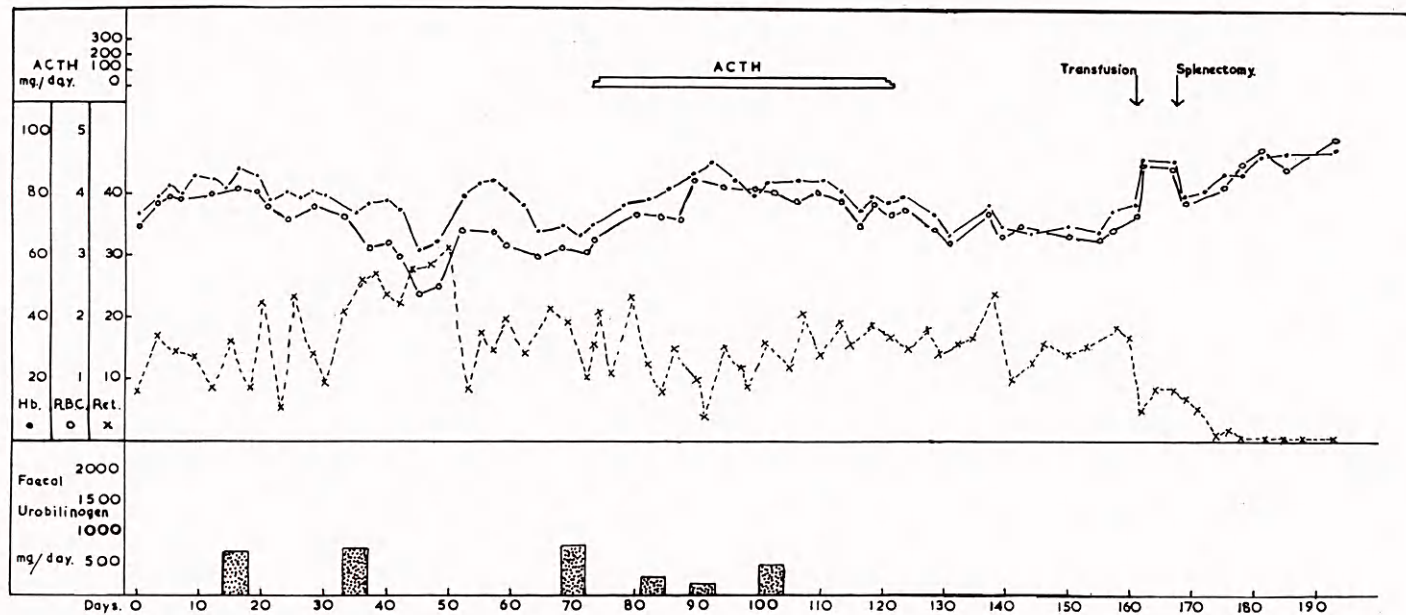


Fig. 10. Case 9. Congenital acholuric jaundice. Failure of ACTH.



urobilinogen was greatly increased (696 mg./day; 748 mg./day; 810 mg./day). Urobilinogen was demonstrable qualitatively in the urine and quantitative estimation on a twenty-four hour collection gave the figure of 5.6 mg. per day. The icteric index varied between 11 and 17.

*Treatment and results.* ACTH was administered for forty-eight days, a total of 2,780 mg. being given. Apart from the first day and the last two days when smaller amounts were given, the daily dose was 60 mg. (Fig. 10). At the onset of treatment the haemoglobin and red cell levels were rising and this rise continued for twenty days, peak values of 91 per cent and 4.45 million per cu.mm. being reached. Thereafter a gradual fall in haemoglobin and red cell levels occurred and this fall persisted throughout the remaining twenty-eight days of ACTH treatment. The reticulocyte count remained elevated (4-23%) during the course of ACTH therapy.

Before treatment the direct eosinophil count varied from 11 to 355 per cu.mm. At the beginning of treatment a distinct eosinopenia occurred, eosinophils being frequently absent from the peripheral blood and never being more than 77 per cu.mm. After eleven days of ACTH therapy a progressive rise in the eosinophil count occurred and in the latter half of the course of ACTH it ranged between 88 and 726 per cu.mm.

Three months after the course of ACTH an uneventful splenectomy was performed. In the six months since the operation the child has remained well and the blood levels have been normal.

*Case 10.* Mrs. M. McA., a housewife aged 59 years, was admitted to hospital on 24th April, 1952. Two years before admission she developed pallor and jaundice which lasted for a few weeks. One year later she became readily tired, dyspnoeic and pale, and remained so for about three months. Shortly before admission she suffered from colicky pain in the right upper abdomen. The only past history of significance was of jaundice at the age of 26 years. No family history of anaemia or jaundice was obtained but a sister was found to have increased erythrocyte fragility in hypotonic saline.

*Clinical examination.* She was a well-nourished, pale, icteric female. The spleen was enlarged to two inches below the costal margin. No other clinical findings of significance were present. Gall-stones were demonstrable radiologically.

*Laboratory findings.* Blood examination showed a moderate degree of anaemia associated with a persistent reticulocytosis and a normal total and differential white cell count (R.B.C. 3.32 million/cu.mm., Hb. 67%, reticulocytes 10%, W.B.C. 4,800/cu.mm.). Stained blood films showed anisocytosis, poikilocytosis, polychromasia, and spherocytosis. Sternal puncture revealed very active normoblastic erythropoiesis. No inclusion bodies of the Pappenheimer type were present in the red cell precursors. The white cells were normal. Erythrocyte fragility in hypotonic saline was increased, haemolysis commencing at 0.72 per cent and being complete at 0.36 per cent. The direct Coombs test was negative at 4°C. and 37°C. No auto-agglutinins were detected. The acid haemolysis test and the Wassermann and Kahn reactions were negative. The faecal excretion of urobilinogen was 364 mg. per day. Urobilinogen was present in the urine. The icteric index was 22.

*Treatment and results.* A ten-day course of cortisone was given, 200 mg. daily for five days, and 300 mg. daily for five days. As will be seen by reference to Fig. 11 no significant alteration in blood levels occurred, while the faecal excretion of urobilinogen rose to 750 mg. per day. Before cortisone therapy the direct eosinophil count was 110 per cu.mm.; during therapy it ranged from 0 to 22 per cu.mm. Sixteen days after cortisone therapy splenectomy was successfully performed. Following the operation there has been a progressive rise in the haemoglobin and red cell levels and a fall in reticulocytes.

*Comment.* It is concluded that no benefit was obtained from the administration of cortisone and ACTH in the four cases of congenital acholuric jaundice and that alterations in blood levels during the administration of these substances were due to cyclical variations in the haemolytic process unrelated to treatment.

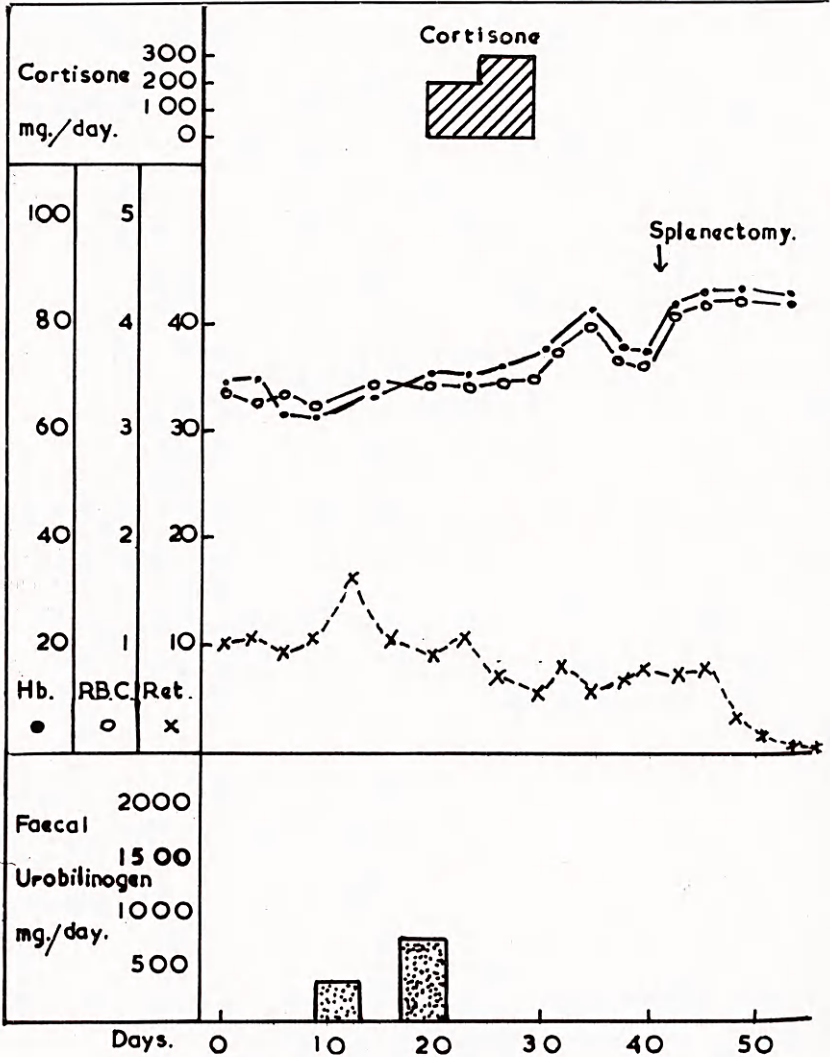


Fig. 11. Case 10. Congenital acholuric jaundice. Failure of cortisone.

SIDE EFFECTS OF TREATMENT.

While the investigation was primarily intended to observe the effects of ACTH and cortisone in haemolytic anaemia, it is considered desirable to report the side-effects observed during this investigation.



During ACTH or cortisone therapy oedema of the ankles developed in four patients (Cases 1, 2, 3 & 6). With restriction of fluid intake the oedema disappeared or lessened, and in none of these patients did it persist after the cessation of treatment. In Cases 5 and 8 the signs of cardiac decompensation already present became more marked following treatment. In Cases 2, 3, 6, 7 and 9 hypertension appeared during treatment but in every case it disappeared within a few days of cessation.

Alteration in facial contour to the state descriptively termed 'moon-face' occurred in Cases 3, 8 and 9. In all cases the facial appearance returned to normal after therapy was completed.

In Case 2 there was a five-year history of recurrent attacks of depression and these had led the patient to seek psychiatric treatment. At the start of cortisone treatment her emotional state was not noticeably abnormal but after three weeks of cortisone depression became extremely marked. The patient discharged herself from hospital and entered a mental hospital as a voluntary patient. In the twelve months after cortisone therapy, depression persisted and the patient remained an inmate of a mental hospital. It is difficult to dissociate this mental deterioration from the administration of cortisone and it would appear desirable to use ACTH or cortisone with great caution in patients with a previous history of mental illness.

No significant alteration in the plasma electrolyte levels occurred except in Case 9 in which the serum potassium fell to 12.5 mg. per cent towards the end of ACTH treatment. No changes in the electrocardiogram were noted in any of the patients. In no case was there any clinical or radiological evidence of activation of a latent pulmonary tuberculosis and none of the patients developed acute infections during or after hormone therapy.

#### DISCUSSION.

In haemolytic anaemias the effects of any form of therapy need to be evaluated with caution because of the tendency of so many of these cases to undergo spontaneous remissions of variable degree and duration. Indeed, in certain types of acute haemolytic anaemia, such as those associated with virus infections, permanent remission is common. Consequently, in the assessment of therapy, full consideration must be given to the natural history of the disease, and no undue significance should be attached to minor or short-term remissions. The need for this caution is well illustrated by Case 3. Inspection of Fig. 3 shows that each of the two courses of treatment given in this case was accompanied by a degree of haematological remission, and by a fall in the excretion of urobilinogen. On the basis of two months' investigation it might therefore be concluded that a significant therapeutic effect was being obtained. When these remissions are assessed in the light of the patient's previous

history, however, the validity of such a conclusion becomes doubtful because it seemed that her previous general clinical condition over a period of many months had not been particularly worse or better than during the period of investigation. The occurrence of a third remission after treatment was stopped provides further reason for rejecting the suggestion that the course of this patient's disease was materially influenced by cortisone or ACTH. Very similar patterns are shown by Figs. 8, 9 and 10 which illustrate cases of congenital acholuric jaundice.

Case 2 provides a contrast, because in this patient the administration of cortisone was accompanied by a progressive and sustained improvement in the haematological and general clinical condition such as had not occurred since the onset of her illness. This improvement persisted for months after the cessation of treatment, although relapse subsequently occurred. We submit that in this case the remission may reasonably be attributed to the treatment. Similarly in Case 4, for reasons already given, it is our opinion that the rapid and sustained improvement which occurred symptomatically and haematologically was in large part due to the ACTH. Of the ten cases only two, namely Cases 2 and 4 showed substantial remissions which we can accept as attributable to the treatment. Both of these gave a positive Coombs test. Of the others showing no substantial degree of clinical or haematological remissions, most of them were Coombs-negative, but two (Cases 1 & 5) were Coombs-positive.

Since the work of Boorman *et al.* (1946) it has been widely accepted that the positive Coombs test demonstrable in many cases of acquired haemolytic anaemia is due to an antibody which is concerned in the haemolytic process. There were, therefore, reasons for believing that ACTH or cortisone, by virtue of their effect on antibody production, might exert a favourable effect in cases giving a positive Coombs reaction, although they might be of no benefit in other types of haemolytic anaemia, such as congenital acholuric jaundice, giving a negative Coombs reaction. In our own series, however, of four cases which were Coombs positive, two responded to treatment (Cases 2 & 4) and two failed to do so (Cases 1 & 5). It should be noted that in one of these (Case 1) the spleen had previously been removed, and that in the other (Case 5) the patient was in the advanced stage of a fatal malady.

Recent reports have thrown doubt upon the original claim that the Coombs test reflects a fundamental etiological difference between the acquired and congenital types. Thus Wright *et al.* (1951) found incomplete antibodies similar to those revealed by the Coombs test in eight out of twenty-five cases of congenital acholuric jaundice. Moreover, in some of these patients treated successfully by splenectomy, the reduction in haemolysis was not necessarily accompanied by a corresponding reduction in the titre of incomplete antibodies. It would therefore appear premature



to attach undue importance to the Coombs test in predicting whether a case of haemolytic anaemia may benefit from cortisone or ACTH.

The behaviour of the bone marrow in Case 4 of our series is of interest not only in relation to the mechanism of the crisis in haemolytic anaemias in general, but also in relation to the possible mechanism of ACTH in producing remission. Observations have already been published (Owren, 1948; Dameshek & Bloom, 1948) suggesting that in congenital acholuric jaundice the haemolytic crisis may to some extent be due to a temporary depression of erythropoiesis. These authors record arrest of erythropoiesis in the bone marrow of patients during crisis, with subsequent restoration of normoblastic activity during the succeeding remission. As far as we are aware this phenomenon has not previously been recorded in a case of acquired haemolytic anaemia. In our Case 4 there was an almost complete cessation of normoblastic activity and disappearance of reticulocytes from the peripheral blood at the height of the crisis (Fig. 4c & d). This was accompanied by a relative increase in the myeloid series of cells in the bone marrow, although the peripheral blood showed a leucopenia and a thrombocytopenia. It is interesting to speculate whether the recovery of the patient following the administration of ACTH was due primarily to the direct stimulation of erythropoiesis, to the neutralization of some humoral influence depressing erythropoiesis (Dameshek & Bloom, 1948), or to the neutralization of a haemolytic antibody. Owren (1948) believes that the haemolytic crisis in acholuric jaundice is entirely due to cessation of marrow activity, while Dameshek and Bloom (1948) contend that, although maturation arrest occurs, it is accompanied by increased haemolysis. In our case, during the period of erythropoietic inactivity, the serum bilirubin was very high and the excretion of faecal urobilinogen was excessive. Moreover, considerable quantities of blood were transfused with relatively little benefit. It would thus appear that haemolysis remained abnormally active during this period. At a later stage, when ACTH was being given, haemolysis appeared to be reduced, and at this time the bone marrow showed active regenerative changes. It is therefore impossible to conclude whether the ACTH influenced the regeneration of the bone marrow, or the reduction in haemolysis, or indeed both.

Further experience with these substances in all types of haemolytic anaemia is clearly desirable before their therapeutic scope can be defined, or their mode of action understood. In the light of experience which has so far been acquired in this field, ACTH or cortisone is likely to be of value only in cases of acquired haemolytic anaemia, and for the most part probably only as a measure of short term policy. In the more acute cases in which the underlying causes of the haemolysis are transient, it is possible that no further treatment may be necessary, but in the more chronic cases, especially those with substantial splenomegaly, it would

seem highly doubtful whether ACTH or cortisone will effect a permanent remission. In such cases the most useful employment for these drugs will probably be in tiding the patient over a haemolytic crisis pending splenectomy.

#### SUMMARY.

An account is given of ten patients with haemolytic anaemia receiving therapeutic trials with ACTH and cortisone.

Four of the patients were cases of idiopathic acquired haemolytic anaemia. Two of these responded favourably, and two derived little or no benefit. In one of the successful cases remission persisted for a period of six months after which relapse occurred. The other, after recovery from a severe haemolytic crisis, was subjected to splenectomy with successful results.

Two patients with symptomatic haemolytic anaemia showed no significant improvement and died from the underlying disease.

In the remaining four patients, who were cases of congenital acholuric jaundice, the results were negative.

The Coombs test was positive in three of the four cases of idiopathic acquired haemolytic anaemia, and in one of the cases of symptomatic haemolytic anaemia. In all the other cases it was negative. The positive reactors included the two cases responding favourably to treatment, and also two who failed to do so.

One of the cases of acquired haemolytic anaemia in which treatment was successful, showed a striking arrest of erythropoiesis at the height of a haemolytic crisis, and subsequent active regeneration. Although this phenomenon has been described in congenital acholuric jaundice we believe it has not previously been recorded in acquired haemolytic anaemia. Its significance is discussed.

It is concluded that ACTH and cortisone are of therapeutic value in certain cases of haemolytic anaemia of the acquired type, but that at present there is no entirely reliable method of predicting the response to treatment in individual cases. When benefit is obtained it is not necessarily permanent.

#### ACKNOWLEDGEMENTS.

The present study would not have been possible without the ready co-operation of our colleagues in referring patients to us and supplying full clinical notes. We have much pleasure therefore in acknowledging our indebtedness to Drs. J. N. Cruickshank, J. W. Ferguson, E. G. Oastler, Anne Aitkenhead, and A. P. Agnew. We also wish to thank Mr. G. H. Stevenson and Mr. G. T. Mowat for their skilled surgical co-operation, and Dr. J. Wallace and Mr. G. M. Todd of the West of Scotland Blood Transfusion Service for their help and advice in connection with serological studies.

The cortisone was provided from a generous gift made jointly to the Medical Research Council and the Nuffield Foundation by Messrs. Merck & Co. Inc. Part of the expenses of this work was borne by the Rankin Fund, University of Glasgow. The authors are very grateful to the Carnegie Trust for a contribution towards the cost of the illustrations.



## REFERENCES.

- Boorman, K. E., Dodd, B. E. & Loutit, J. F. (1946). *Lancet*. **1**: 812
- Dacie, J. V., Israels, M. C. G. & Wilkinson, J. F. (1938). *Lancet*. **1**: 479
- Dameshek, W. & Bloom, M. L. (1948). *Blood*. **3**: 1381
- Dameshek, W. (1950). *Blood*. **5**: 791
- Dameshek, W., Rosenthal, M. C. & Schwartz, I. I. (1951). *New Engl. J. Med.* **244**: 117
- Davidson, L. S. P., Duthie, J. J. R., Girdwood, R. H. & Sinclair, R. J. G. (1951). *Brit. med. J.* **1**: 657
- Gardner, F. H. (1950). *Blood*. **5**: 791
- Gardner, F. H., McElfresh, A. E., Harris, J. W. & Diamond, I. K. (1951). *J. Lab. clin. Med.* **37**: 444
- McFadzean, A. J. S. & Davis, L. J. (1947). *Glasg. med. J.* **28**: 237
- Medical Research Council (1952). *Brit. med. J.* **1**: 1261
- Owren, P. A. (1948). *Blood*. **3**: 231
- Randolph, T. G. (1944). *J. Allergy*. **15**: 89
- Watson, C. J. (1936). *Amer. J. clin. Path.* **6**: 458
- Wilson, T. M. & Davidson, L. S. P. (1949). *Brit. med. J.* **1**: 884
- Wintrobe, M. M., Cartwright, G. E., Palmer, J. G., Kuhns, W. J. & Samuels, L. T. (1951). *Arch. intern. Med.* **88**: 310
- Wright, C. S., Dodd, M. C., Bouroncle, B. A., Doan, C. A. & Zollinger, R. M. (1951). *J. Lab. clin. Med.* **37**: 165