

# Digital metastasis of tongue squamous cell carcinoma



Kumpol Aiempanakit, MD  
Songkhla, Thailand

**Key words:** digit metastasis; nail change; oncologic patient; squamous cell carcinoma; tongue.

## INTRODUCTION

Nail disorders are common complications in oncologic patients who have received chemotherapy.<sup>1-4</sup> The all-grade incidence of nail changes with paclitaxel treatment has been reported to be 43.7%.<sup>3</sup> Nail characteristics can be divided into anatomic sites—nail matrix (Beau's line, onychomadesis), nail bed (onycholysis, pigmentation changes), and nail fold (paronychia, pyogenic granuloma). This study reports a patient with advanced squamous cell carcinoma of the tongue who had nail changes on the left index finger after treatment with taxane chemotherapy and an epidermal growth factor receptor inhibitor.

## CASE REPORT

A 61-year-old man had squamous cell carcinoma (SCC) at the base of the tongue (clinical stage III, T3, N1, M0) diagnosed 2 years previously. He received multiple courses of chemotherapy (cisplatin based), but his disease progressed. The SCC had metastasized to his bones, liver, and lungs. He then received second and third lines of treatment with targeted therapy (afatinib) and chemotherapy (paclitaxel). He was also treated with adjuvant radiation. During treatment with targeted therapy, he experienced grade II paronychia of the fingernails with spontaneous resolution.

He presented with a 2-week-old painful, red lesion on the left index finger with a history of spontaneous bleeding within the first 4 days. Two months earlier, he received the last course of paclitaxel chemotherapy. A physical examination of the left index finger found a tender, ill-defined erythematous patch with a firm consistency on the

radial side of the lateral nail fold and one-third of the adjacent subungual tissue (Fig 1). The differential diagnosis included infection, particularly bacterial infection, pyogenic granuloma, and metastasis of SCC. Gram stain was negative. A plain radiograph of both hands (anteroposterior view) showed a well-defined osteolytic lesion at the radial side of the distal phalanx (Fig 2). A skin biopsy found multiple fragments of squamous epithelial cells with some prominent nucleoli, mitosis, and foci of keratinization (Fig 3). The diagnosis was digital metastasis of squamous cell carcinoma, and the patient was treated with supportive care. He died 5 days after the diagnosis of the digital metastasis.

## DISCUSSION

Nail changes commonly occur in patients who receive taxane chemotherapy and treatment with epidermal growth factor receptor inhibitors.<sup>3-6</sup> The physician should be attentive to nail changes occurring on a few or multiple nails which develop from common types of chemotherapy and improve after cessation of therapy. In this case report, the patient's nail condition possibly mimicked nail change from chemotherapy or a pyogenic granuloma-like lesion. However, the patient had only single fingernail involvement with persistent symptoms after cessation of chemotherapy.

Fingers are a rare site for metastasis with no exact incidence rate. In a large review of 221 cases of over 27 years, it was found that cancers metastasize to the hand and wrist more commonly in males than females.<sup>7</sup> The most common presentations are redness and pain, but the symptoms can also develop with a mass, such as a pyogenic

From the Division of Dermatology, Department of Internal Medicine, Faculty of Medicine, Prince of Songkla University.

Funding sources: None.

Conflicts of interest: None declared.

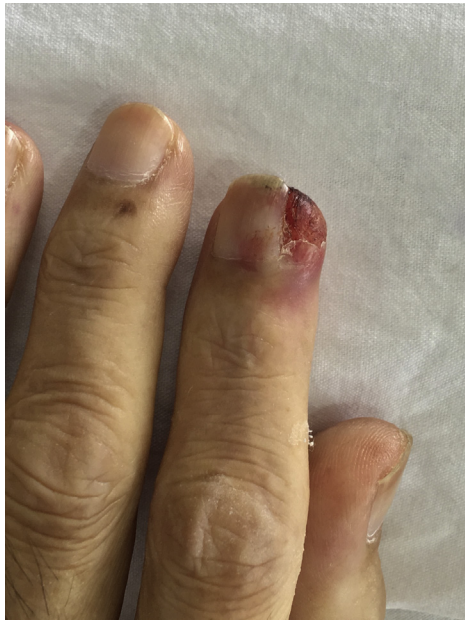Correspondence to: Kumpol Aiempanakit, MD, Division of Dermatology, Department of Internal Medicine, Faculty of Medicine, Prince of Songkla University, Hatyai, Songkhla, Thailand, 90110. E-mail: [akumpol@medicine.psu.ac.th](mailto:akumpol@medicine.psu.ac.th).

JAAD Case Reports 2018;4:200-2.

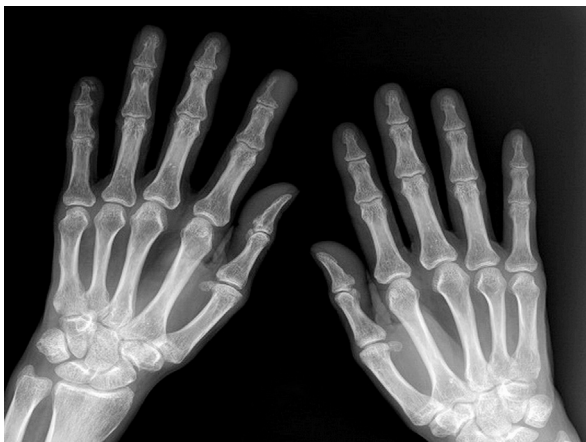2352-5126

© 2017 by the American Academy of Dermatology, Inc. Published by Elsevier, Inc. This is an open access article under the CC BY-NC-ND license (<http://creativecommons.org/licenses/by-nc-nd/4.0/>).

<https://doi.org/10.1016/j.jidcr.2017.09.009>



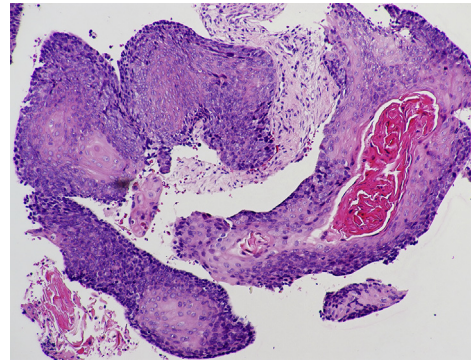
**Fig 1.** Appearance of the nail change.



**Fig 2.** Plain radiograph of both hands shows bone lesion at distal phalanx on the left index.

granuloma-like lesion.<sup>8</sup> Clinical signs are easily mistaken for infections and inflammation such as felon, paronychia, pyogenic granuloma, or rheumatoid arthritis.<sup>9</sup> The distal phalanx of the thumb is the most common site of involvement.<sup>7,9</sup> Malignancies of the lung, gastrointestinal tract, and kidney are often the primary tumors.<sup>7-9</sup> Metastases to the fingers and hands are most commonly from malignancy of the lung, whereas metastases to the toes and feet is most frequently from the genitourinary tract.<sup>10</sup> To our knowledge, there are no previous reports of this condition stemming from a primary tumor of the tongue.

Radiographic and histopathologic studies can be useful for diagnosis. The plain radiograph could



**Fig 3.** Hematoxylin-eosin staining of the skin biopsy specimen shows well-differentiated squamous cell carcinoma. (Original magnification:  $\times 40$ .)

show spotting osteolysis and periosteal bone reaction.<sup>8</sup> The pathologic results are relatable and consistent with the primary tumor. There is no standard management of digital metastases. Surgical treatments including excision, curettage, and amputation are the treatments of choice.<sup>8,9</sup> There is no survival outcome study in cases of patients with digital metastasis. However, this condition is associated with a poor prognosis of an advanced primary tumor.

Digital metastasis is a rare condition. To our knowledge, this is the first case of digital metastasis from squamous cell carcinoma of the tongue. This report points to the need for dermatologists to consider a possible diagnosis of digital metastasis with a high index of suspicion.

The authors thank Glenn Shingledecker of the International Affairs Office, Faculty of Medicine, Prince of Songkla University for proofreading and language editing service.

#### REFERENCES

1. Pavey RA, Kambil SM, Bhat RM. Dermatological adverse reactions to cancer chemotherapy. *Indian J Dermatol Venereol Leprol.* 2015;81:434.
2. Miller KK, Gorcey L, McLellan BN. Chemotherapy-induced hand-foot syndrome and nail changes: a review of clinical presentation, etiology, pathogenesis, and management. *J Am Acad Dermatol.* 2014;71:787-794.
3. Capriotti K, Capriotti JA, Lessin S, et al. The risk of nail changes with taxane chemotherapy: a systematic review of the literature and meta-analysis. *Br J Dermatol.* 2015;173:842-845.
4. Sibaud V, Lebœuf NR, Roche H, et al. Dermatological adverse events with taxane chemotherapy. *Eur J Dermatol.* 2016;26:427-443.
5. Fox LP. Nail toxicity associated with epidermal growth factor receptor inhibitor therapy. *J Am Acad Dermatol.* 2007;56:460-465.
6. Reyes-Habito CM, Roh EK. Cutaneous reactions to chemotherapeutic drugs and targeted therapy for cancer: Part II. Targeted therapy. *J Am Acad Dermatol.* 2014;71:217.e1-217.e11.

7. Afshar A, Farhadnia P, Khalkhali H. Metastases to the hand and wrist: an analysis of 221 cases. *J Hand Surg Am.* 2014;39:923-932.
8. Madjidi A, Cole P, Laucirica R. Digital acrometastasis: a rare initial sign of occult pulmonary squamous cell carcinoma. *J Plast Reconstr Aesthet Surg.* 2009;62:e365-e367.
9. Cohen PR. Metastatic tumors to the nail unit: subungual metastases. *Dermatol Surg.* 2001;27:280-293.
10. Baran R, Guillot P, Tosti A. Metastasis from carcinoma of the bronchus to the distal aspect of two digits. *Br J Dermatol.* 1998;138:708.