

## Unilateral acne after facial palsy\*

Emilio Sudy<sup>1</sup>

Francisco Urbina<sup>1</sup>

DOI: <http://dx.doi.org/10.1590/abd1806-4841.20187437>

**Abstract:** We describe a case of unilateral acne which appeared after an episode of facial nerve palsy. An 18-year-old female patient presented with papules and pustules predominantly located on the side where the facial paralysis occurred. The patient suffered right facial paralysis, which was treated with prednisone and kinesiotherapy with massages, electrostimulation, and infrared light. Two weeks later, acne lesions appeared in the area affected by the paralysis. As suggested in other cases of paralysis, including cases of Parkinson's disease and spinal cord injury, an increased sebum excretion rate and the immobility of the affected area are most likely what caused the unilateral acne lesions.

**Keywords:** Acne vulgaris; Dermatitis, seborrheic; Facial paralysis

### INTRODUCTION

Unilateral acne and related disorders (rosacea, seborrheic dermatitis, and demodicidosis) have been described in relation to paralyzed areas of different causes. We report a case of unilateral acne following facial nerve palsy.

### CASE REPORT

An 18-year-old female patient presented with a unilateral facial eruption. She had no significant history of acne and was not receiving any previous medication. Three months earlier she suffered facial nerve palsy to the right side of the face, which was treated with oral acyclovir, prednisone 40mg/day for five days, and kinesiological therapy with massages, electrostimulation and infrared light. The patient's condition improved with treatment without sequelae. However, two weeks later, acne lesions appeared in the area affected by the paralysis, with lesions that increased progressively and continued worsening a month later. On examination she presented abundant papules and pustules on the right side of the face, affecting the mandibular area and cheeks, but with few papules and comedones on the left side (Figures 1 and 2). The patient was treated with doxycycline 50mg every 12 hours for one month and adapalene 0.3% gel.

### DISCUSSION

Unilateral acne is rare, but it has been reported associated with facial paralysis. It was first described in a 13-year-old male patient with no history of acne, who developed comedones and seborrhea limited to the paralyzed area after a surgical intervention in the mastoid area due to severe otitis.<sup>1</sup> Another case was reported in a 23-year-old female with Ramsay-Hunt syndrome, treated with prednisone 15mg/day; a month after treatment started, unilateral acne appeared on the side of the paralysis.<sup>2</sup> Similarly, a 21-year-old woman presented with acne lesions on the side of facial paralysis, which was treated with white petrolatum massages.<sup>3</sup> The authors linked the eruption to the use of petrolatum, however, in a critical letter, English and Murphy suggested that the most probable etiological factor causing the patient's acne was the increased sebum excretion rate subsequent to the paralysis.<sup>4</sup> Two case reports, in which petrolatum and other topical products were not used, provide further support to the hypothesis that the increased sebum excretion rate is the most important factor causing unilateral acne.<sup>1,4</sup> Al-Ghambi *et al.* report a case where a 25-year-old woman developed acne with scars in the region affected by facial paralysis even though treatment did not include physical therapy or topical medications.<sup>5</sup> Additionally, in cases where a spinal cord injury occurs, sebum secretion increases in the paraplegic and distal area

Received 12 July 2017.

Accepted 17 September 2017.

\* Work conducted at private practice, Santiago, Chile.

Financial support: None.

Conflict of interest: None.

<sup>1</sup> Clínica Vespucio, Santiago, Chile.

MAILING ADDRESS:

Emilio Sudy

E-mail: [emiliosudy@gmail.com](mailto:emiliosudy@gmail.com)

©2018 by Anais Brasileiros de Dermatologia



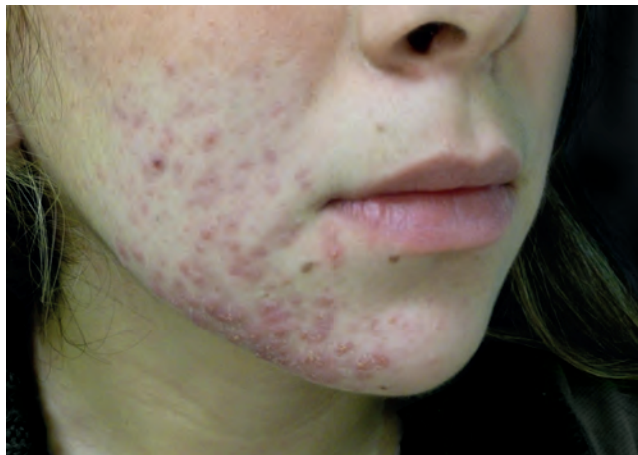

FIGURE 1: Unilateral papules and pustules in the mandibular area

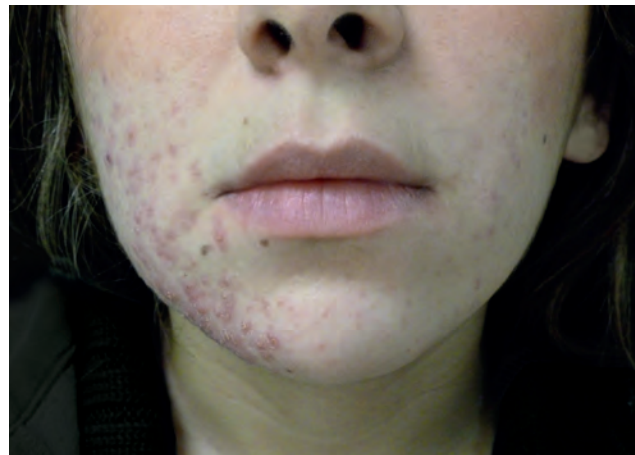

FIGURE 2: Predominance of acne lesions on the right side of the face

of the neurological lesion.<sup>4</sup>

Given the frequent occurrence of facial paralysis, the scarcity of cases describing the development of unilateral acne is striking. However, in a series of 42 cases of facial paralysis, approximately 17% of cases detected acne and skin changes.<sup>6</sup> We agree with English and Murphy that the cause of unilateral acne is an increase in sebum production on the paralyzed side.<sup>4</sup> Studies have shown that the sebum excretion rate is greater on the paralyzed side of patients with facial paralysis, and similarly, in paraplegic patients, below their neurological lesions.<sup>7</sup> Additionally, a greater reserve of lipids in the pilosebaceous ducts of paraplegic areas have been found, which may be due to immobility and muscular paralysis.<sup>7</sup> Thus, both an augmented sebaceous secretion and an increased keratinization are among the factors causing the onset of unilateral acne.

Patients with Parkinson's disease have also been found to show an increase in sebaceous secretion. Facial immobility facilitates sebum accumulation, which becomes coarse and thickened with enlarged follicular openings.<sup>8</sup> Therefore, the accumulated sebum, together with the overgrowth of *Pityrosporum ovale*, would favor the development of seborrheic dermatitis in patients with neurological disorders, including Parkinson's disease, facial paralysis and paralysis at the level of the spinal cord.<sup>8</sup>

Similarly, unilateral rosacea appearing at the site of healed

herpes zoster (a Wolf's isotopic response) has been reported. It has been postulated that the damage of nerve fibers produced by herpes zoster can trigger the secretion of neuropeptides, activating the immune system and causing an inflammatory disease such as rosacea in the area previously affected by herpes zoster.<sup>9</sup> We believe that a common phenomenon could be involved in rosacea, seborrheic dermatitis and unilateral acne, as in our case.

The role that *Demodex folliculorum* might have played in our case is unclear, since unilateral rosacea related to *D. folliculorum* has been described, and considering that it proliferates in areas with abundant sebum, as can be the case of areas affected by paralysis or in the so-called rosaceiform demodicidosis.<sup>10</sup> Our case was not rosacea, considering it had no erythema, flushing or telangiectases; moreover, she presented comedones.

However, whether the acne rash is due to the paralysis itself or to the different therapies employed, including oral corticosteroids, manipulation of the area, or the use of occlusive substances, is still questionable.

The presentation of unilateral acne affecting the area of facial paralysis could be explained by several factors, including increased sebaceous secretion of the affected site, increased keratinization and enlarged follicular openings, with raised proinflammatory neuropeptides and immobility of the area. The role of the mite *Demodex folliculorum* is still uncertain. □


#### REFERENCES

1. Nexmand PH. A case of seborrhoea with comedones in conjunction with facial paralysis. *Acta Dermatovenereol.* 1944;25:275-81.
2. Tagami H. Unilateral steroid acne on the paralyzed side of the face. *J Dermatol.* 1983;10:281-2.
3. Frankel EB. Acne secondary to white petrolatum use. *Arch Dermatol.* 1985;121:589-90.
4. English JS, Murphy G. Acne secondary to white petrolatum use. *Arch Dermatol.* 1983;10:1240.
5. Al-Ghambi Y, Junainah J. Unilateral steroid induced acne on the paralyzed side of the face. *Gulf J Dermatol Venereol.* 2014;21: 44-5.
6. Terzis JK, Anesti K. Experience with developmental facial paralysis: part I Diagnosis and associated stigmata. *Plast Reconstr Surg.* 2011;128:488e-497e.
7. Thomas SE, Conway J, Ebling FJ, Harrington CI. Measurement of sebum excretion rate and skin temperature above and below the neurological lesion in paraplegic patients. *Br J Dermatol.* 1985;112:569-73.
8. Gupta AK, Bluhm R. Seborrheic dermatitis. *J Eur Acad Dermatol Venereol.* 2004;18:13-26.
9. Sezer E, Koseoglu RD, Filiz N. Wolf's isotopic response: rosacea appearing at the site of healed herpes zoster. *Australas J Dermatol.* 2006;47:189-91.
10. Pallotta S, Cianchini G, Martelloni E, Ferranti G, Girardelli CR, Di Lella G, et al. Unilateral demodicidosis. *Eur J Dermatol.* 1998;8:191-2.

Emilio Sudy

 ORCID 0000-0001-8349-4285

Francisco Urbina

 ORCID 0000-0001-6642-0284

**How to cite this article:** Sudy E, Urbina F. Unilateral acne after facial palsy. *An Bras Dermatol.* 2018;93(3):441-2.