

Curcumin alleviates pain and improves cognitive impairment in a rat model of cobra venom-induced trigeminal neuralgia

Li Zhang¹
Xinli Ding²
Zhe Wu³
Min Wang¹
Ming Tian¹

¹Department of Anesthesiology, Beijing Friendship Hospital, Capital Medical University, Beijing 100050, ²Department of Rehabilitation Medicine, Shandong Provincial Hospital Affiliated to Shandong University, Jinan 250021, ³Department of Anesthesiology, Pain Medicine and Critical Care Medicine, Aviation General Hospital of China Medical University, Beijing 100012, China

Correspondence: Xinli Ding
Department of Rehabilitation Medicine,
Shandong Provincial Hospital Affiliated
to Shandong University, No 324, Jingwu
Road, Jinan 250021, Shandong Province,
China
Tel +86 531 6877 6571
Fax +86 531 8706 8707
Email xinlidingaa@163.com

Background: Cognitive impairment is a common complication in patients with chronic neuropathic pain, without effective therapy. Recent works have indicated that curcumin (Cur) possesses antinociceptive and neuroprotective potentials, suggesting its possible effectiveness for the treatment of this complication.

Objective: The aim of this study was to explore the effects of Cur on pain behaviors and cognitive impairment in rats with cobra venom-induced trigeminal neuralgia (TN).

Design: This is a randomized, controlled experiment.

Setting: This study was conducted at the Experimental Animal Center, Beijing Friendship Hospital, Capital Medical University.

Subjects: A total of 40 adult male Sprague Dawley rats were used in this study.

Methods: A cobra venom solution was injected into the sheath of infraorbital nerve. Cur was administered intragastrically at 45 mg/kg twice daily for 28 successive days from postoperative day 15. Mechanical allodynia was evaluated using von Frey filaments. Free behaviors were observed using video recording. Cognitive capacity was tested using the Morris water maze. Both morphology and ultrastructure of the CA1 hippocampal region were visualized using hematoxylin and eosin (HE) staining and transmission electron microscopy, respectively.

Results: Cur treatment reduced mechanical allodynia and face-grooming activities but increased exploratory activities and improved spatial learning and memory deficits. Microscopic examination revealed nucleus pyknosis, swollen organelles, and decreased synapse density in the CA1 hippocampal region after cobra venom injection. However, chronic Cur treatment reversed damage to hippocampal neurons and synapses.

Conclusion: Cur can alleviate pain, improve spatial learning and memory deficits, and restore the damage to hippocampal neurons and synapses in cobra venom-induced TN rats. Cur may be useful as an adjuvant to treat chronic neuropathic pain-induced cognitive deficits.

Keywords: curcumin, cognitive impairment, trigeminal neuralgia, cobra venom, hippocampus, ultrastructural changes

Introduction

Cognitive impairment is a common complication in patients with chronic neuropathic pain, and memory deterioration is the primary clinical manifestation.¹ Chronic pain predisposes patients to cognitive impairment, which affects daily activities and deteriorates the quality of life.² Cognitive deficits in chronic pain patients restrict the effectiveness of communicating their pain symptoms, which further constrains the application of cognitive-based therapy and may exacerbate preexisting pain.³ Thus,

the identification of effective strategies for this complication is imperative. In available literatures, numerous studies have been performed to elucidate the mechanisms of neuropathic pain and investigate the relationship between neuropathic pain and cognitive impairment.⁴⁻⁶ Few studies are focused on the treatment of pain-induced cognitive impairment.

Current strategies for the management of pain-induced cognitive impairment primarily concentrated on the amelioration of neuropathic pain and improvement in cognitive deficits induced by chronic pain, but the results are contradictory and inconclusive. Some studies show that pain relief by analgesic drugs can reverse the cognitive deficits observed in chronic pain models.⁷ However, other studies find that neuropathic pain is a chronic intractable pain with a poor response to opioids and nonsteroidal anti-inflammatory drugs.^{8,9} Antiepileptic drugs (AED) are the first-line drugs commonly used for the treatment of neuropathic pain, but the prolonged use of AED itself may lead to cognitive deficits.^{10,11} Thus, studies on novel therapeutic agents using dietary or phytomedicine should be performed to alleviate neuropathic pain and improve pain-induced cognitive deficits.

Curcumin (Cur), a yellow pigment derived from the rhizome of *Curcuma longa*,¹² has been widely studied for its pleiotropic properties, including anti-inflammatory, antinociceptive, and neuroprotective activities.¹³⁻¹⁵ It has been shown that Cur provides analgesic activity against various neuropathic pains.^{14,16} Furthermore, Cur possesses neuroprotective property and improves learning and memory performances in different experimental models.^{15,17} The concurrent antinociceptive and neuroprotective properties of Cur suggest its potential as a treatment for cognitive impairment induced by chronic neuropathic pain. Thus, this study was designed to determine whether Cur could improve pain behaviors and cognitive impairments in cobra venom-induced trigeminal neuralgia (TN) rats and elucidate the underlying mechanisms.

Methods

Animals

After experimental plan was approved by the Animal Ethical Committee of Beijing Friendship Hospital, Capital Medical University (China), all procedures were performed according to the guidelines of the International Association for the Study of Pain. Male Sprague Dawley rats (200–250 g) were used in this study. Rats were housed under controlled temperature (22–25°C), humidity (60–80%), and a 12-hour

light/dark cycle (lights on for 07:00 h). By a random table, 40 rats were assigned into the following four groups (n=10 each group): sham + vehicle group, sham + Cur group, TN + vehicle group, and TN + Cur group.

Surgery procedure

The TN rat model was established as previously described.^{18,19} Briefly, animal was anesthetized using sodium pentobarbital (50 mg/kg intraperitoneally). After the left infraorbital nerve (ION) trunk was exposed, 4 µL of a cobra venom solution (containing 0.4 mg of lyophilized cobra venom) was injected into the ION sheath. Then, the incision was closed. The sham group underwent the same procedure with an injection of saline. One rat died accidentally, and nine rats remained in the TN + vehicle group.

Drug preparation and treatment

Lyophilized cobra venom (Formosan cobra; Sigma-Aldrich Co., St Louis, MO, USA) was dissolved in 0.9% saline for injection. Cur (Sigma-Aldrich Co.) was dissolved in peanut oil for oral administration (via gavage, po). A dose of 45 mg/kg Cur was administered intragastrically twice daily (morning and evening) according to the previous report.²⁰ The treatment was started on the 15th day after surgery, when the neuropathic TN was well established, and continued for 28 consecutive days.

Behavioral testing

Both mechanical allodynia and free behavioral tests were used to determine whether the TN model was well established.

Animals were tested 3 days before surgery and 4, 7, 14, 21, 28, 35, and 42 days after surgery. They were placed individually in a transparent plastic cage on an elevated mesh (1.0 cm × 1.0 cm perforations) and allowed to acclimatize for 20 min. A set of von Frey hairs (Stoelting, Chicago, IL, USA) with calibrated bending forces (0.41–15.1 g) was used to measure mechanical sensitivity. Each filament was applied to the ipsilateral ION territory near the center of the vibrissal pad and held for ~5 s. Mechanical withdraw thresholds (MWTs) were calculated using the up-down method as described previously.²¹

Free behaviors of rats were recorded in a transparent plastic cage (24 cm × 35 cm × 18 cm) using a video camera placed 1 m in front of the cage. Animals were placed in the cage for 15 min, and a 7-minute video was recorded. An experimenter who was blinded to the experimental schemes analyzed the videos. Face-grooming (movement patterns in

which paws contact facial areas) and exploratory (walking, running, climbing, or rearing) behaviors were observed to assess changes in spontaneous activity. Behavior tests were performed 1 h before each Cur administration in the morning.

Morris water maze (MWM) task

Cur was continuously administered for 28 days, and both spatial learning and memory abilities were evaluated using an MWM as described previously.¹⁹ The maze was modified slightly, which consists of a circular pool (180 cm diameter and 60 cm high) filled with 19–22°C opaque water and a black escape platform (10 cm diameter and 2 cm above the water level). The pool was divided into four equivalent quadrants and surrounded by external cues that were visible in the wall. Rats underwent four acquisition trials separated by 20-minute intervals daily for 4 consecutive days. Animals were placed into the water facing the pool at different predetermined positions (E, S, W, and N) on each trial, while the platform remained in the same position. Swimming speed and escape latency were video recorded. On day 5 (24 h following the last acquisition trial), a probe trial was performed, in which the hidden platform was removed. Rats were placed in the pool at the location opposite to the platform position and allowed to swim freely for 90 s. The percentage of time spent in the target quadrant and the number of crossings over the platform location were collected.

HE staining

After the MWM test, rats in the sham + vehicle, TN + vehicle, and TN + Cur groups ($n=3$ each group) were deeply anesthetized and transcardially perfused with 0.9% saline followed by 4% paraformaldehyde. Brain slices obtained at coronal level (bregma -3 to -4 mm) were immediately removed, fixed in 10% neutral buffered formalin, and embedded in paraffin. Coronal sections (6 μm thick) of hippocampus were cut, and the sections were stained with HE. The morphology of the CA1 region of hippocampus in different groups was observed by a light microscope (XI-70; Olympus Corporation, Tokyo, Japan). Dense and irregular-shaped pyknotic cells were identified as degenerated neurons.

Electron microscopy

Three rats were taken from the sham + vehicle, TN + vehicle, and TN + Cur groups for ultrastructure analysis on day 48 after surgery. Animals were deeply anesthetized and perfused via the left ventricle with warm saline followed by the mixed

fixation of 2% glutaraldehyde and 4% paraformaldehyde (Sigma-Aldrich Co.) under anesthesia. The CA1 region of hippocampus was dissected out, washed in 3% glutaraldehyde for 2 h, and then rinsed with 0.1 M phosphate buffer for three times. Subsequently, the hippocampus specimens were fixed in 1% osmium tetroxide (Sigma-Aldrich Co.) for 2 h, dehydrated in graded ethanol, embedded using araldite, polymerized for 2 days, and cut into 50–70 nm ultrathin sections. Finally, sections were stained with uranyl acetate and lead citrate. Ultrastructural changes in neurons, organelles, and synapses in the CA1 region of hippocampus were observed using the transmission electron microscopy (TEM; H-9000NARI baraki; Hitachi Ltd., Tokyo, Japan). Electron microscopic photographs were analyzed using the Image-Pro Plus 6.0 software (Media Cybernetics, Silver Spring, MD, USA). The number of synapses, the synaptic clefts, and the area of the postsynaptic density (PSD) were calculated as described previously.²²

Statistical analysis

Data were expressed as mean \pm standard error of the mean (SEM). Repeated measures two-way ANOVA followed by Bonferroni post hoc test were used to compare intergroup differences in the behavior activities and latencies to reach the platform in the MWM task. Data on swimming speeds, time spent in target quadrant, and platform crossings were compared using one-way ANOVA. The Student–Newman–Keuls test was performed for multiple comparisons, followed by Student's *t*-test to evaluate the difference between groups at the same time points. All data were analyzed by SPSS 16.0 (SPSS Inc., Chicago, IL, USA). $P<0.05$ was considered statistically significant.

Results

Effect of Cur on mechanical allodynia

There was no significant difference in the mechanical thresholds between the sham + vehicle and sham + Cur groups. Compared to rats in the sham + vehicle and sham + Cur groups, animals in the TN + vehicle group exhibited a significant decrease in the MWT after cobra venom injection, which lasted for the 42-day observation period ($P<0.001$; Figure 1). A 28-day Cur treatment markedly attenuated the mechanical allodynia in cobra venom-induced TN rats ($P<0.001$; Figure 1). The ipsilateral MWT displayed a significant increase at the time points on days 28 ($P<0.001$), 35 ($P<0.001$), and 42 ($P<0.001$) after surgery compared to the TN + vehicle group. Chronic Cur treatment resulted in a recuperating effect on the mechanical allodynia in the TN

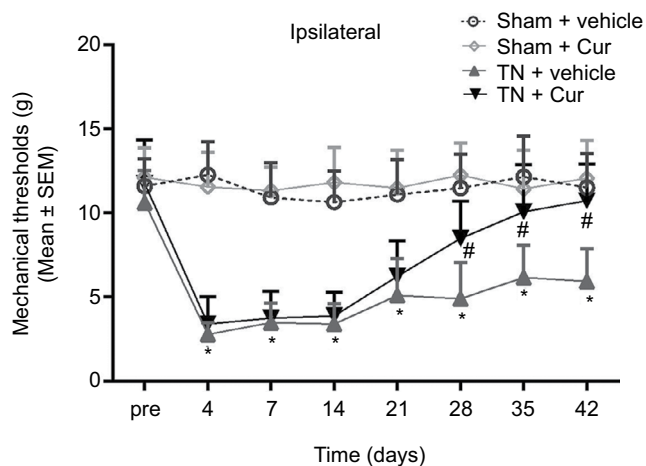


Figure 1 Effect of Cur on mechanical allodynia in rats.
Notes: Chronic Cur treatment began 15 days after surgery. Data are shown as mean \pm SEM (n=9–10 per group). * P <0.05 vs sham + vehicle. # P <0.05 vs TN + vehicle.
Abbreviations: Cur, curcumin; MWTs, mechanical withdraw thresholds; SEM, standard error of the mean; TN, trigeminal neuralgia.

rats but not any influence on the mechanical allodynia in the sham + Cur group.

Effect of Cur on spontaneous behaviors

Video recordings of the free behaviors revealed that rats injected with cobra venom present a significant increase

in time (P <0.001; Figure 2A) and frequency (P <0.001; Figure 2B) of face-grooming activities as well as a significant decrease in time (P <0.001; Figure 2C) and frequency (P <0.001; Figure 2D) of exploratory behaviors from day 4 after surgery. Rats in the sham + vehicle and sham + Cur groups did not display any significant change in behavior activities after surgery. However, chronic Cur treatment significantly reversed abnormal alterations in spontaneous behaviors.

Effect of Cur on spatial learning and memory function

The spatial learning abilities in the MWM task were impaired in TN rats treated with vehicle compared to sham (sham + vehicle and sham + Cur) animals (Figure 3). However, the Cur-treated rats exhibited a significant decrease in the latency to platform. There was a significant difference in the latency to platform between groups (P <0.001; Figure 3A). Post hoc analyses indicated that latency curve to reach the platform was significantly longer in the TN + vehicle group compared to the sham group (P <0.01). The latency time was significantly shorter in the TN + Cur group than in the TN + vehicle group (P <0.01). There was no significant difference in swimming speed among all groups (Figure 3B).

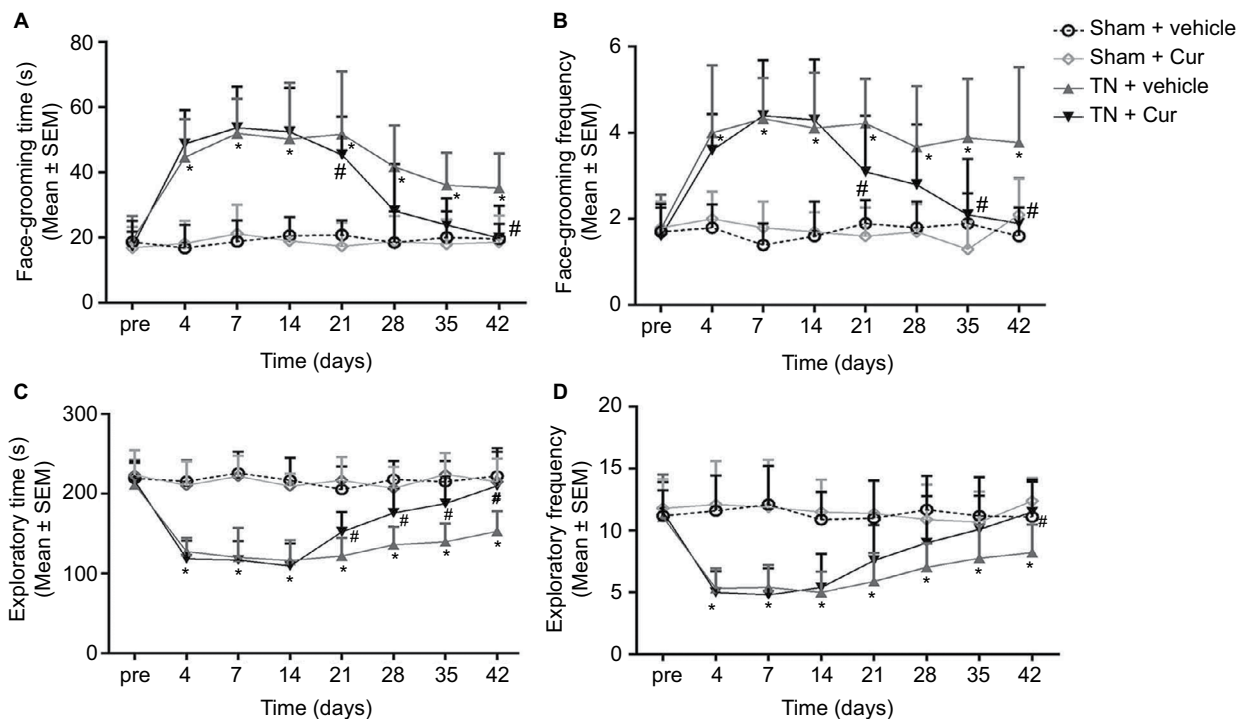


Figure 2 Alterations of spontaneous behaviors in rats.
Notes: (A and B) Duration and frequency of observed face-grooming behaviors at different time points. (C and D) Duration and frequency of observed exploratory activities at different time points. Data are shown as mean \pm SEM (n=9–10 per group). * P <0.05 vs sham + vehicle. # P <0.05 vs TN + vehicle.
Abbreviations: Cur, curcumin; SEM, standard error of the mean; TN, trigeminal neuralgia.

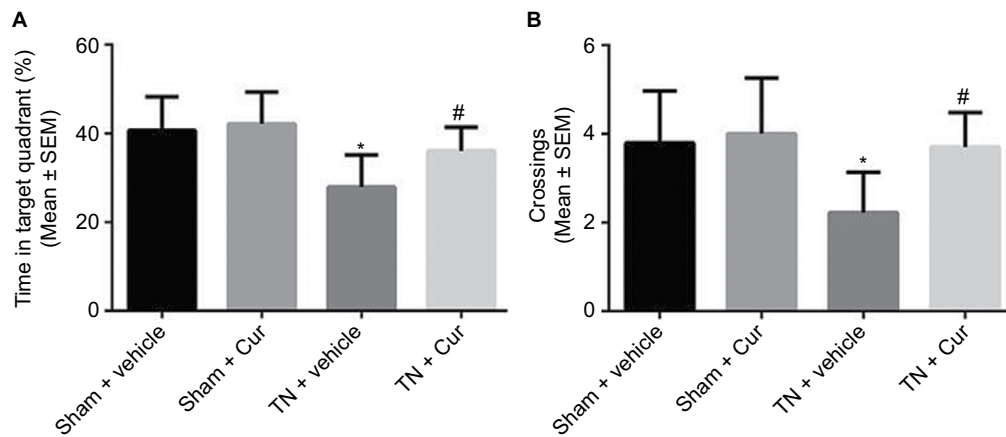


Figure 3 Learning curve and swimming speeds in the Morris water maze task in the experimental groups.

Notes: (A) Learning curve at 56 days after surgery. (B) Swimming speeds at 56 days after surgery. Data are shown as mean \pm SEM ($n=9-10$ per group). * $P<0.05$ vs sham + vehicle. # $P<0.05$ vs TN + vehicle.

Abbreviations: Cur, curcumin; SEM, standard error of the mean; TN, trigeminal neuralgia.

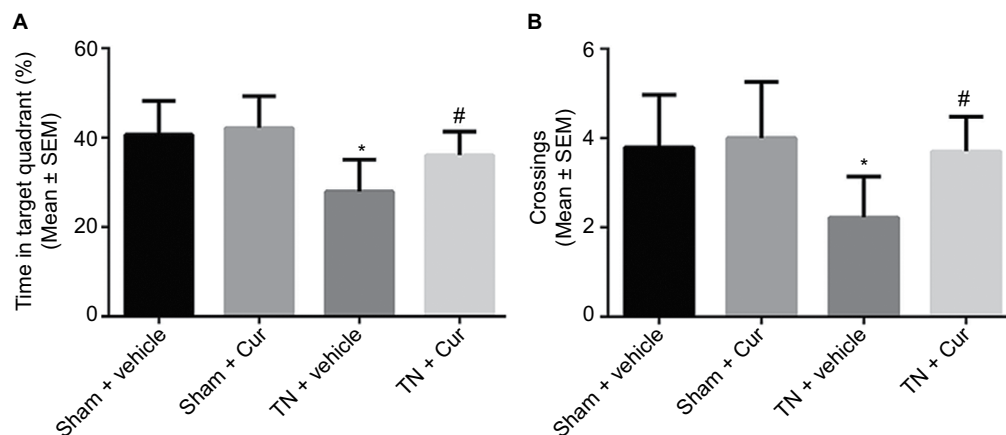


Figure 4 Results of probe trials in Morris water maze.

Notes: (A) The times in the target quadrant in different groups during probe trials. (B) The number of platform site crossings in different groups during probe trials. Data are shown as mean \pm SEM ($n=9-10$ per group). * $P<0.05$ vs sham + vehicle. # $P<0.05$ vs TN + vehicle.

Abbreviations: Cur, curcumin; SEM, standard error of the mean; TN, trigeminal neuralgia.

The TN rats exhibited a decreased time in the target quadrant and a reduced number of platform site crossings compared to the sham rats during the probe trials. Chronic Cur treatment reversed this effect (Figure 4). Memory retention was aggravated in the TN rats treated with vehicle, shown by a decreased time in the target quadrant ($P<0.01$; Figure 4A). Cur treatment attenuated the cognitive deficits induced by TN. Moreover, the number of platform site crossings was significantly reduced in the TN rats treated with vehicle compared with sham groups ($P<0.05$; Figure 4B). However, Cur-treated rats did not exhibit a significant decrease in the number of platform crossings.

Effect of Cur on morphological alterations in the CA1 region of hippocampus

Most hippocampal neurons in the sham group were normal and arranged in alignment with obvious nucleolus (Figure 5A). In contrast, the number of pyknotic neurons significantly increased in the TN group, with the loss of neurons, cytoplasm shrinkage, and nucleus pycnosis. Neurons were arranged loosely (Figure 5B). The density of pyknotic neurons markedly decreased in the Cur-treated group compared to the TN group. Moreover, neurons were less damaged and arranged closer than those in the TN group (Figure 5C).

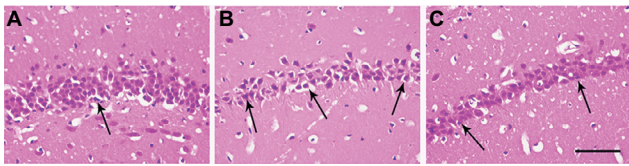


Figure 5 Representative photomicrographs of morphological changes in the hippocampal CA1 region.

Notes: (A) Sham + vehicle group. (B) TN + vehicle group. (C) TN + Cur group. Black arrows indicate degenerated neurons. Scale bar = 50 μ m. HE staining, magnification 400 \times .

Abbreviations: Cur, curcumin; HE, hematoxylin and eosin; TN, trigeminal neuralgia.

Effect of Cur on ultrastructure changes in the CA1 region of the hippocampus

The ultrastructure changes in the hippocampal CA1 area by TEM are shown in Figure 6. In the sham + vehicle group, large and round nuclei containing a uniform density of chromatin were observed and organelles were clear with neatly arranged mitochondria cristae, a regular Golgi apparatus, and numerous dispersed rough endoplasmic reticulum in the cytoplasm. However, in the TN rats, CA1 neurons exhibited an irregular

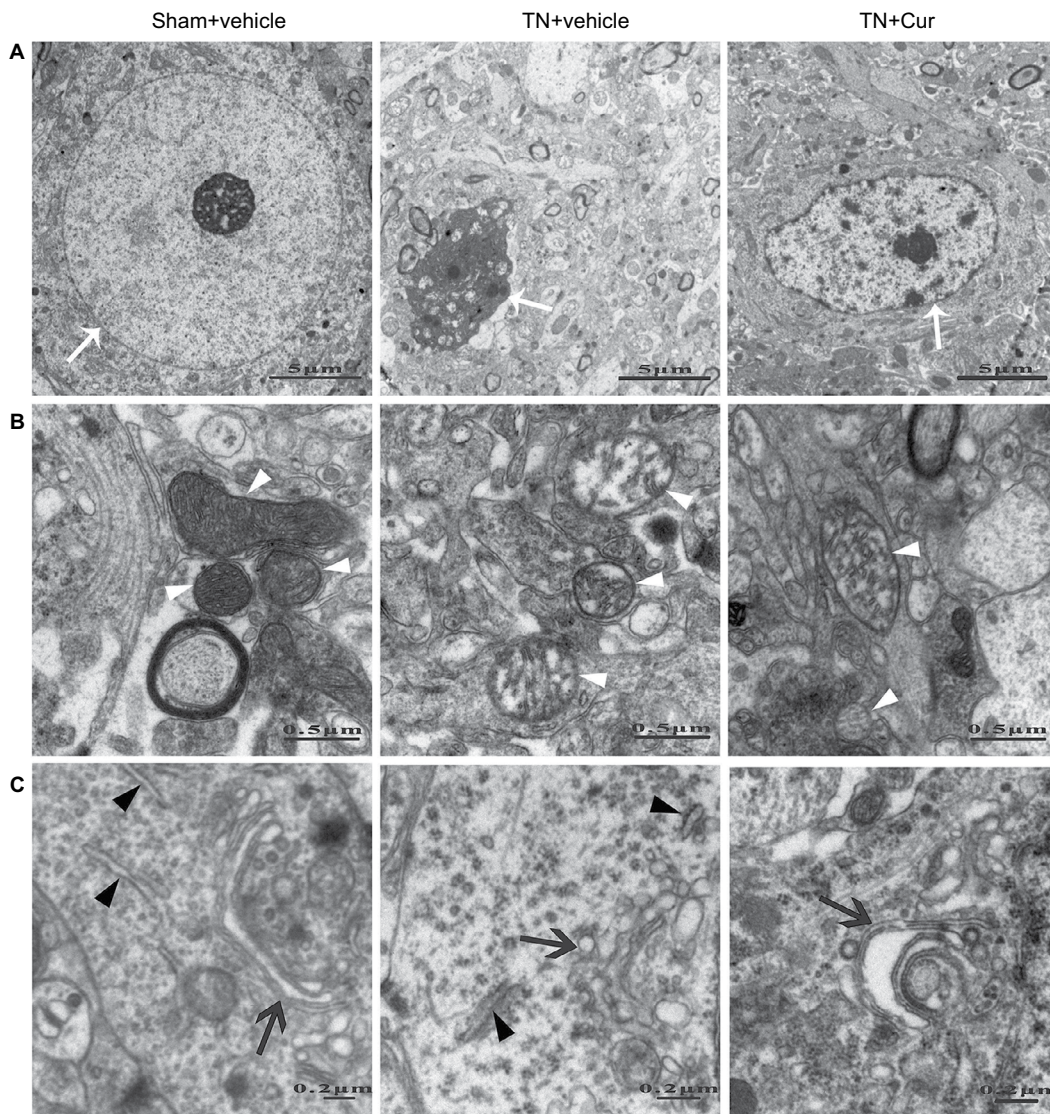


Figure 6 Representative photomicrographs showing the ultrastructures of neurons in the hippocampal CA1 region.

Notes: (A) Nucleus (white arrow), (B) mitochondria (white arrowhead), and (C) Golgi apparatus (black arrow) and rough endoplasmic reticulum (black arrowhead).

Abbreviations: Cur, curcumin; TN, trigeminal neuralgia.

clumping of chromatin, swollen mitochondria with disordered and reduced numbers of cristae, an enlarged Golgi apparatus, and a dilated rough endoplasmic reticulum. Chronic Cur treatment attenuated these aberrant alterations and neurons displayed more regular nuclei and clearer organelles.

In the sham + vehicle group, the outline of synaptic membranes was clear with abundant vesicles distributed in the presynaptic membrane and the PSD was thick. Compared to sham rats, the TN rats exhibited a decreased synapse density with obscure synaptic outlines, fewer presynaptic vesicles, and thinner PSD. Chronic Cur treatment restored the synaptic structure with increased synapse density, distinct

outline, more presynaptic vesicles, and thicker PSD in TN rats (Figure 7).

Discussion

The present study demonstrated that Cur treatment ameliorated pain and improved cognition deficits in a cobra venom-induced TN rat model. Furthermore, Cur provided a protection against neuropathic pain-induced neuron degeneration and synapse damage in hippocampus.

Cognitive deficits, especially memory deterioration, are the most common complaints in patients with neuropathic pain, without effective therapy. Patients with long-term

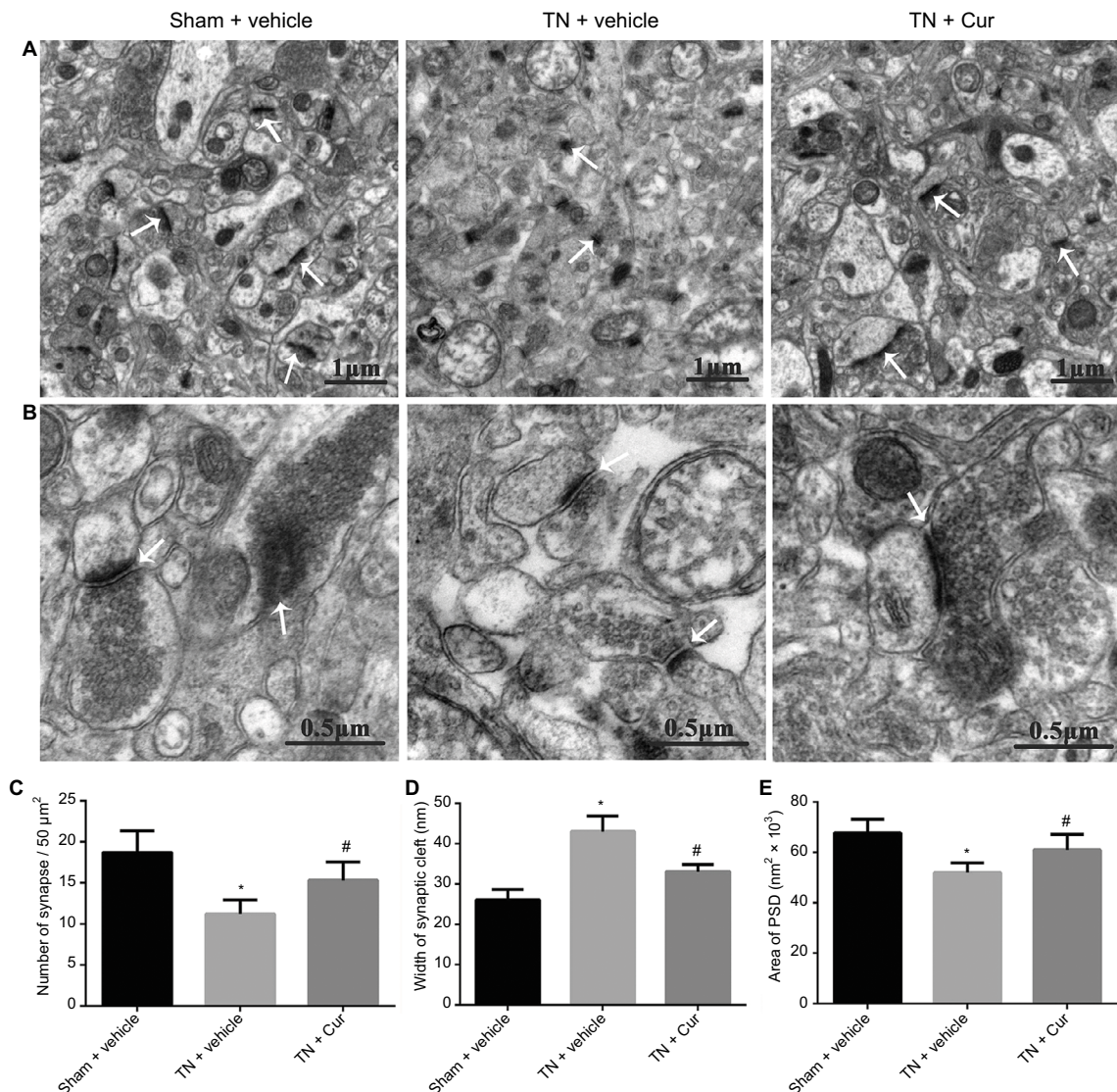


Figure 7 Representative photomicrographs showing the ultrastructures of synapses in the hippocampal CA1 region.

Notes: (A) Images show the difference in synapse density in the three groups (magnification 3000 \times). White arrows indicate the synapses. Scale bars = 1 μm . (B) Images show the difference in synapse cleft, presynaptic vesicles, and PSD in three groups (magnification 10000 \times). White arrows show the synaptic linkages (scale bars = 0.5 μm). (C) Number of synapses in the CA1 region of hippocampus. (D) Width of synaptic cleft in the hippocampal CA1 region. (E) Area of PSD in the hippocampal CA1 region. Data are expressed as mean \pm SEM (n=5 per group). *P<0.05 vs sham + vehicle. #P<0.05 vs TN + vehicle.

Abbreviations: Cur, curcumin; PSD, postsynaptic density; SEM, standard error of the mean; TN, trigeminal neuralgia.

moderate-to-severe pain predispose to cognitive impairment.²³ Some analgesics may be associated with cognitive deficits de novo, or even can further exacerbate preexisting cognitive deficits. Thus, novel strategies for the treatment of cognitive impairment induced by chronic neuropathic pain deserve extensive attentions from health care professionals. However, knowledge of the pathology and molecular mechanisms of pain-induced cognitive deficits is limited and effective drugs remain scarce, despite ever-increasing researches.

In this study, the cobra venom-induced TN model was used to induce persistent neuropathic pain as it can reliably mimic signs and symptoms of neuropathic patients.¹⁸ Moreover, our previous work showed that both spatial learning and memory abilities were impaired in cobra venom-induced TN rats.¹⁹ Thus, the cobra venom-induced TN model is suitable to mimic the cognitive impairments caused by chronic neuropathic pain.

Cur attenuated mechanical allodynia and abnormal changes in free behaviors

This study showed that chronic Cur treatment alleviated pain-related behaviors, increased PWTs and explorative activities, and decreased face-grooming behaviors. Furthermore, these effects were clearly time dependent. The alterations in pain behaviors diminished over time and approximately returned to basal levels after 28 days of Cur treatment. These results are consistent with findings of previous studies, in which chronic Cur treatment markedly facilitates recovery from surgery in a rat model of postoperative pain²⁴ and alleviates complete Freund's adjuvant-induced inflammatory hyperalgesia by decreasing oxidative stress and downregulating proinflammatory cytokines.²⁵ In a chronic constriction injury model of neuropathic pain, moreover, Zhao et al²⁰ demonstrated that Cur ameliorates mechanical and thermal hyperalgesia by modulation of the descending monoamine system and opioid receptors. These findings indicate that Cur provides antinociceptive potential and attenuates cobra venom-induced TN. However, the mechanisms underlying the antinociceptive action of Cur in TN are poorly understood and future research is still needed.

Cur improved spatial learning and memory

Our results showed that chronic Cur treatment shortened escape latencies and increased time in the target quadrant and platform site crossings in the water maze task, indicating that Cur treatment improves spatial learning and memory deficits, similar to the findings of previous studies.^{26–28} It

has been shown that Cur ameliorates memory deficits in senescence-accelerated mice.²⁶ Moreover, Cur can provide a protection against chronic unpredictable stress-induced cognitive deficits in mice.²⁷ Additionally, Cur improves Alzheimer's disease-related cognitive deficits by the BDNF–ERK signaling pathway.²⁸ These findings suggest that Cur has a potential neuroprotection and can improve the function of spatial learning and memory in rats with TN. To exclude the possible effect of partial vision loss in the eye on the lesion side of the rats,¹⁹ visible platform training was adopted to assess sensorimotor function in our study. Thus, our results exclude the possibility that sensorimotor deficits are the cause of cognitive deficits in the MWM task.

Cur ameliorated hippocampal neuron and synapse damage

It has been shown that persistent alterations in neuronal development and synaptic plasticity in cognition-related brain areas underlie the impairments in neurobehavioral performance, especially for hippocampus-dependent water maze tasks.²⁹ The hippocampus is a critical brain region responsible for learning and memory, and it is likely involved in various cognitive deficits.^{30,31} Thus, abnormalities in neurons or synapses in the hippocampus may be involved in the mechanisms of pain-induced cognitive deficits. In this study, TEM showed that chronic Cur treatment alleviated nucleus shrinkage, mitochondria swell and vacuolation, Golgi apparatus enlargement, and endoplasmic expansion in the TN rats. Furthermore, increased number of synapses and presynaptic vesicles, narrower synapse clefts, and thicker PSD were observed in Cur-treated TN rats. It is well believed that the number of presynaptic vesicles represents the quantity of neurotransmitters released into the synaptic cleft³² and the thickness of PSD reflects synaptic efficacy.³³ Subtle changes in the synaptic structure can lead to significant alterations in the biophysical properties of synapse,³³ resulting in variations of memory abilities. In our study, Cur improved neuronal activity or synaptic efficacy and eventually ameliorated learning and memory deterioration. These beneficial effects of Cur on the neuronal activity and synaptic plasticity are consistent with the findings of previous studies.^{34,35} A recent study demonstrates that long-term Cur administration prompts hippocampal neurogenesis and improves memory in senescent-age rats.³⁴ Additionally, Hoppe et al³⁵ show that Cur modulates the synaptic-related proteins, such as CaMKII and synapsin I, to prevent the deleterious effects of A β on synaptic activity in hippocampus. Consequently, the amelioration of neuronal and synapse damages following Cur

administration suggests the possible involvement of neurons and synapses in the beneficial effect of Cur on pain-induced cognitive deficits.

It has been demonstrated that chronic pain can produce alterations of neuronal and synaptic plasticities in the central nervous system.³⁶ Secondary to altered nociceptive signaling in peripheral neuropathic pain, both the neural circuit remodeling and structural synaptic plasticity occur in the “pain matrix” cortices.³⁷ Given that Cur possesses antinociceptive and neuroprotective properties, the improvement in pain-induced cognitive deficits by Cur in the TN rats may be attributable to these properties. On one hand, the neuroprotective potential exerted by Cur can directly improve the hippocampal neuronal and synaptic plasticity. On the other hand, the antinociceptive potential exhibited by Cur may attenuate cobra venom-induced TN and further prevent the structural plasticity alterations of neuronal and synaptic connections under chronic pain conditions, which indirectly ameliorates pain-induced cognitive deficits. Thus, Cur may be a potentially therapeutic alternative for the treatment of pain-induced cognitive deficits.

There are some limitations in our design that deserve attention. First, this study was focused on the pathophysiological mechanisms of Cur affecting cognitive function. In fact, specific molecular mechanisms of Cur in improving cobra venom-induced TN and pain-induced cognitive deficits remain elusive. Second, this study only examined hippocampal ultrastructural alterations. Thus, it is unclear whether similar changes occur in other brain regions associated with learning and memory. Further experiments are needed to clarify the molecular mechanisms and alterations in other pain-related brain regions. Third, as cobra venom is a complex molecular compound with several biological and physiological effects,¹⁹ it is uncertain whether it has a direct and/or indirect neurotoxic effect on the hippocampus, after retrogradely transported along the intraorbital nerve into the central nervous system (CNS) and/or diffusion into the systemic circulation and subsequent transportation to the CNS. Perhaps, contralateral facial von Frey fiber analysis should be performed as a control measure to account for the systemic effects of the venom. In the future study, moreover, unilateral chronic constriction injury of the ION, as previously described,³⁸ may be adopted to exclude the neurotoxic effect on the CNS, produced by the agent being used to induce neuropathic pain. Fourth, the contribution of chronic pain to exploratory behavior may be considered as a possible confounder. Other cognitive tests, such as radial arm maze and T maze, should be carried out to clarify the relationship between pain and cognition.

Conclusion

The results of this study confirm that in cobra venom-induced TN rat model, chronic Cur treatment can alleviate pain-related behaviors (mechanical allodynia and free behavioral alterations) and improve spatial learning and memory deficits. These results suggest that Cur may be a therapeutic strategy of cognitive impairment induced by chronic neuropathic pain. The improvement in cognitive impairment by Cur may be associated with the structural alterations of neurons and synapses in the hippocampal CA1 region.

Acknowledgments

We are grateful to Dr Fushan Xue for advice in revising this paper. This work was supported by the National Natural Science Foundation of China (81401860) and the Research Foundation of Beijing Friendship Hospital, Capital Medical University (yyqdk2016-7).

Disclosure

The authors report no conflicts of interest in this work.

References

1. Grace GM, Nielson WR, Hopkins M, Berg MA. Concentration and memory deficits in patients with fibromyalgia syndrome. *J Clin Exp Neuropsychol*. 1999;21(4):477–487.
2. Niv D, Kreitler S. Pain and quality of life. *Pain Pract*. 2001;1(2):150–161.
3. Kreitler S, Niv D. Cognitive impairment in chronic pain. *Pain Clin Update*. 2007;15:1–4.
4. Yalcin I, Barthas F, Barrot M. Emotional consequences of neuropathic pain: insight from preclinical studies. *Neurosci Biobehav Rev*. 2014;47:154–164.
5. Berryman C, Stanton TR, Bowering KJ, Tabor A, McFarlane A, Moseley GL. Do people with chronic pain have impaired executive function? A meta-analytical review. *Clin Psychol Rev*. 2014;34(7):563–579.
6. Hart RP, Martelli MF, Zasler ND. Chronic pain and neuropsychological functioning. *Neuropsychol Rev*. 2000;10(3):131–149.
7. Hu Y, Yang J, Hu Y, Wang Y, Li W. Amitriptyline rather than lornoxicam ameliorates neuropathic pain-induced deficits in abilities of spatial learning and memory. *Eur J Anaesthesiol*. 2010;27(2):162–168.
8. Arnér S, Meyerson BA. Lack of analgesic effect of opioids on neuropathic and idiopathic forms of pain. *Pain*. 1988;33(1):11–23.
9. Vo T, Rice AS, Dworkin RH. Non-steroidal anti-inflammatory drugs for neuropathic pain: how do we explain continued widespread use? *Pain*. 2009;143(3):169–171.
10. Besi E, Boniface DR, Cregg R, Zakrzewska JM. Comparison of tolerability and adverse symptoms in oxcarbazepine and carbamazepine in the treatment of trigeminal neuralgia and neuralgiform headaches using the Liverpool Adverse Events Profile (AEP). *J Headache Pain*. 2015;16:563.
11. Schiltenswolf M, Akbar M, Hug A, et al. Evidence of specific cognitive deficits in patients with chronic low back pain under long-term substitution treatment of opioids. *Pain Physician*. 2014;17(1):9–19.
12. Nafisi S, Adelzadeh M, Norouzi Z, Sarbolouki MN. Curcumin binding to DNA and RNA. *DNA Cell Biol*. 2009;28(4):201–208.
13. Motterlini R, Foresti R, Bassi R, Green CJ. Curcumin, an antioxidant and anti-inflammatory agent, induces heme oxygenase-1 and protects endothelial cells against oxidative stress. *Free Radic Biol Med*. 2000;28(8):1303–1312.

14. Di YX, Hong C, Jun L, Renshan G, Qinquan L. Curcumin attenuates mechanical and thermal hyperalgesia in chronic constrictive injury model of neuropathic pain. *Pain Ther.* 2014;3(1):59–69.
15. Thiagarajan M, Sharma SS. Neuroprotective effect of curcumin in middle cerebral artery occlusion induced focal cerebral ischemia in rats. *Life Sci.* 2004;74(8):969–985.
16. Babu A, Prasanth KG, Balaji B. Effect of curcumin in mice model of vincristine-induced neuropathy. *Pharm Biol.* 2015;53(6):838–848.
17. Kumar A, Dogra S, Prakash A. Protective effect of curcumin (*Curcuma longa*), against aluminium toxicity: possible behavioral and biochemical alterations in rats. *Behav Brain Res.* 2009;205(2):384–390.
18. An JX, He Y, Qian XY, et al. A new animal model of trigeminal neuralgia produced by administration of cobra venom to the infraorbital nerve in the rat. *Anesth Analg.* 2011;113(3):652–656.
19. Wu Z, Qian XY, An JX, et al. Trigeminal neuralgia induced by cobra venom in the rat leads to deficits in abilities of spatial learning and memory. *Pain Physician.* 2015;18(2):E207–E216.
20. Zhao X, Wang C, Zhang JF, et al. Chronic curcumin treatment normalizes depression-like behaviors in mice with mononeuropathy: involvement of supraspinal serotonergic system and GABAA receptor. *Psychopharmacology (Berl).* 2014;231(10):2171–2187.
21. Dixon WJ. Efficient analysis of experimental observations. *Annu Rev Pharmacol Toxicol.* 1980;20:441–462.
22. Wu J, Dong L, Zhang M, et al. Class I histone deacetylase inhibitor valproic acid reverses cognitive deficits in a mouse model of septic encephalopathy. *Neurochem Res.* 2013;38(11):2440–2449.
23. Glass JM. Review of cognitive dysfunction in fibromyalgia: a convergence on working memory and attentional control impairments. *Rheum Dis Clin North Am.* 2009;35(2):299–311.
24. Zhu Q, Sun Y, Yun X, Ou Y, Zhang W, Li JX. Antinociceptive effects of curcumin in a rat model of postoperative pain. *Sci Rep.* 2014;4:4932.
25. Singh AK, Vinayak M. Curcumin attenuates CFA induced thermal hyperalgesia by modulation of antioxidant enzymes and down regulation of TNF- α , IL-1 β and IL-6. *Neurochem Res.* 2015;40(3):463–472.
26. Sun CY, Qi SS, Zhou P, et al. Neurobiological and pharmacological validity of curcumin in ameliorating memory performance of senescence-accelerated mice. *Pharmacol Biochem Behav.* 2013;105:76–82.
27. Rinwa P, Kumar A. Piperine potentiates the protective effects of curcumin against chronic unpredictable stress-induced cognitive impairment and oxidative damage in mice. *Brain Res.* 2012;1488:38–50.
28. Zhang L, Fang Y, Xu Y, et al. Curcumin improves amyloid β -peptide (1–42) induced spatial memory deficits through BDNF–ERK signaling pathway. *PLoS One.* 2015;10(6):e0131525.
29. An L, Zhang T. Vitamins C and E reverse melamine-induced deficits in spatial cognition and hippocampal synaptic plasticity in rats. *Neurotoxicology.* 2014;44:132–139.
30. Ji S, Tian Y, Lu Y, et al. Irradiation-induced hippocampal neurogenesis impairment is associated with epigenetic regulation of bdnf gene transcription. *Brain Res.* 2014;1577:77–88.
31. Aguiar AS Jr, Castro AA, Moreira EL, et al. Short bouts of mild-intensity physical exercise improve spatial learning and memory in aging rats: involvement of hippocampal plasticity via AKT, CREB and BDNF signaling. *Mech Ageing Dev.* 2011;132(11–12):560–567.
32. Ahnert-Hilger G, Münster-Wandowski A, Hölting M. Synaptic vesicle proteins: targets and routes for botulinum neurotoxins. *Curr Top Microbiol Immunol.* 2013;364:159–177.
33. Jing Y, Wang Z, Song Y. Quantitative study of aluminum-induced changes in synaptic ultrastructure in rats. *Synapse.* 2004;52(4):292–298.
34. Dong S, Zeng Q, Mitchell ES, et al. Curcumin enhances neurogenesis and cognition in aged rats: implications for transcriptional interactions related to growth and synaptic plasticity. *PLoS One.* 2012;7(2):e31211.
35. Hoppe JB, Haag M, Whalley BJ, Salbego CG, Cimarosti H. Curcumin protects organotypic hippocampal slice cultures from Abeta1–42-induced synaptic toxicity. *Toxicol In Vitro.* 2013;27(8):2325–2330.
36. May A. Chronic pain may change the structure of the brain. *Pain.* 2008;137(1):7–15.
37. Kim W, Kim SK. Neural circuit remodeling and structural plasticity in the cortex during chronic pain. *Korean J Physiol Pharmacol.* 2016;20(1):1–8.
38. Vos BP, Strassman AM, Maciewicz RJ. Behavioral evidence of trigeminal neuropathic pain following chronic constriction injury to the rat's infraorbital nerve. *J Neurosci.* 1994;14(5 pt 1):2708–2723.

Journal of Pain Research

Publish your work in this journal

The Journal of Pain Research is an international, peer reviewed, open access, online journal that welcomes laboratory and clinical findings in the fields of pain research and the prevention and management of pain. Original research, reviews, symposium reports, hypothesis formation and commentaries are all considered for publication.

Submit your manuscript here: <https://www.dovepress.com/journal-of-pain-research-journal>

Dovepress

The manuscript management system is completely online and includes a very quick and fair peer-review system, which is all easy to use. Visit <http://www.dovepress.com/testimonials.php> to read real quotes from published authors.