

# Sudden deaths from positional asphyxia

## A case report

Sigitas Chmieliauskas, PhD<sup>a,b,\*</sup>, Eimantas Mundinas, MD<sup>a</sup>, Dmitrij Fomin, PhD<sup>a,b</sup>, Gerda Andriuskeviciute, MD<sup>b</sup>, Sigitas Laima, PhD<sup>a,b</sup>, Eleonora Jurolaic, MD<sup>a</sup>, Jurgita Stasiuniene, PhD<sup>a</sup>, Algimantas Jasulaitis, PhD<sup>a</sup>

### Abstract

**Rationale:** Positional asphyxia is a rare cause of sudden death and a difficult diagnosis, based mostly on the circumstances of the incident, along with particular external and internal findings, frequent in asphyxia (signs of sudden death).

**Patient concerns:** In this report, we are describing one case of adult who was found positioned in a way that led to eventual asphyxiation.

**Diagnoses:** The final diagnosis of positional asphyxia was determined after the autopsy.

**Interventions:** In a head-down position, gravitation and mechanical forces lead to an increased pressure on the diaphragm from the weight of the abdominal organs. Abdominal breathing, and later, chest breathing were hindered by the raised diaphragm and the difference between abdominal and breathing pressures.

**Outcomes:** It is known that death from positional asphyxia can emerge in several ways, such as the external breathing suppression when the victim's torso is compressed or deformed.

**Lessons:** Therefore, the current criteria for positional asphyxia are based on the obstruction of normal gas exchange caused by the body position, the impossibility to move to another position, and the exclusion of other causes of death. The forensic medical examination must also be started at the scene of the incident.

**Abbreviations:** BMI = body mass index, SD = standard deviation.

**Keywords:** body position, external breathing, forensic medicine, positional asphyxia, sudden death

## 1. Introduction

Positional (postural) asphyxia is a form of mechanical asphyxia that occurs when a person is immobilized in a position which impairs adequate pulmonary ventilation and thus, results in a respiratory failure.<sup>[1,2]</sup> In some cases, the body position has a direct hindering effect on normal circulation and venous return to the heart, which may be additional contributing factors to the obstruction of normal gas exchange.<sup>[3]</sup>

Positional asphyxia is a rare cause of death, responsible for only 1% of all asphyxial deaths in Lithuania and described in just 0.03% of autopsies performed between the years 2010–2016.

This form of asphyxia is usually accidental, however, it has been also linked with torturing and homicide.<sup>[4,5]</sup>

The mechanism of asphyxia can be elicited in a variety of ways. For instance, the inversion of the whole body or of the upper part interferes with normal respiration and blood circulation due to the increase in the intrathoracic pressure and the compression of inferior vena cava.<sup>[6]</sup> A certain restricted posture of the neck (e.g., hyperflexion or hyperextension) can cause partial or complete airway obstruction.<sup>[7]</sup>

Lastly, the compression or flexion of the torso reduces total lung volume, functional residual capacity and pulmonary expansion, eventually making breathing ineffective.<sup>[5,8]</sup> Additionally, depending on the circumstances, these positions can be further categorized into active and passive actions, the latter usually involving cognitive impairment.<sup>[9]</sup>

Even in the presence of a compromising position, other potential underlying causes of death, such as trauma, intoxication, hyperthermia, exhaustion or crush syndrome should not be overlooked and thus, must be excluded first. To help differentiate these deaths, various criteria have been proposed by a number of authors.

In this report, we are describing single case of adult who was found positioned in a way that led to eventual asphyxiation, as well as discussing the major pathophysiologic and diagnostic characteristics of positional asphyxia.

This case report was approved by the Ethics Committee of Vilnius regional biomedical research. An informed consent was signed by the patient and his representatives. An analysis was performed to evaluate data from the State Forensic Medicine Service forensic pathology autopsies of positional asphyxia cases between 2010 and 2016. During this period, the total number of

Editor: N/A.

The authors have no conflicts of interest to disclose.

<sup>a</sup> Department of Pathology, Forensic Medicine and Pharmacology, Institute of Biomedical Sciences of the Faculty of Medicine of Vilnius University, Vilnius.,

<sup>b</sup> State Forensic Medicine Service, Vilnius, Lithuania.

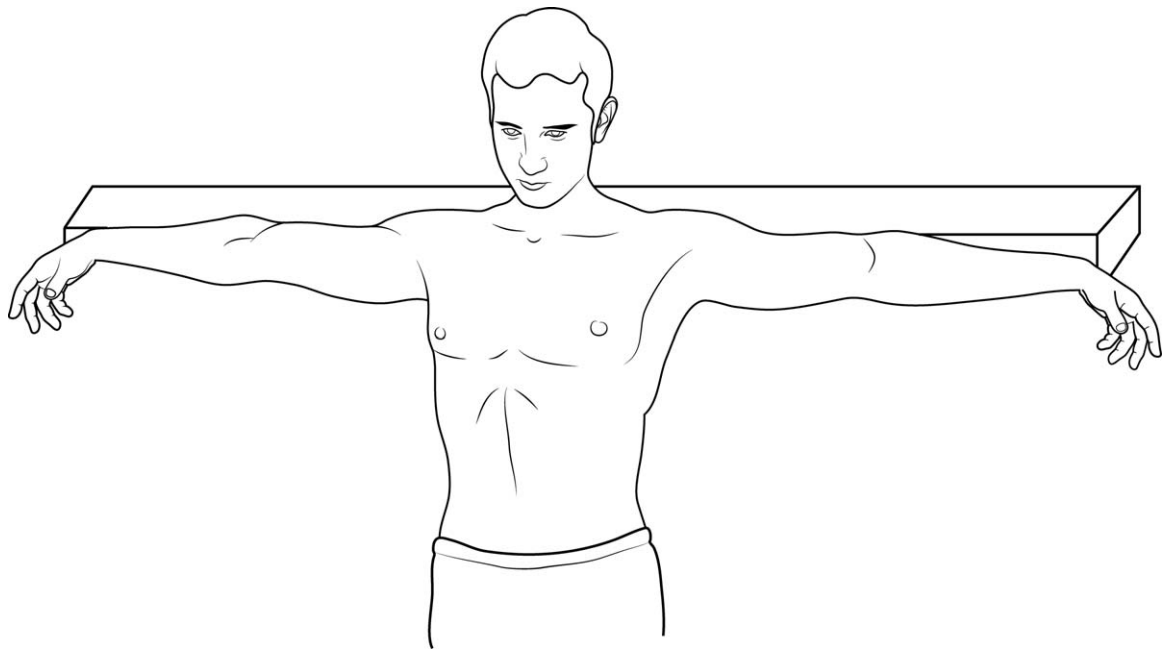
\* Correspondence: Sigitas Chmieliauskas, Department of Pathology, Forensic Medicine and Pharmacology, Institute of Biomedical Sciences of the Faculty of Medicine of Vilnius University, Vilnius, M. K. Ciurlionio str. 21/27, Lithuania (e-mail: sigitas.chmieliauskas@mf.vu.lt).

Copyright © 2018 the Author(s). Published by Wolters Kluwer Health, Inc. This is an open access article distributed under the terms of the Creative Commons Attribution-Non Commercial License 4.0 (CCBY-NC), where it is permissible to download, share, remix, transform, and buildup the work provided it is properly cited. The work cannot be used commercially without permission from the journal.

Medicine (2018) 97:24(e11041)

Received: 27 February 2018 / Accepted: 18 May 2018

<http://dx.doi.org/10.1097/MD.00000000000011041>



**Figure 1.** The body found with arms stretched out to the sides.

performed autopsies in Lithuania decreased. In 2010, the number of performed autopsies was 7395, which represented 17.3% of all deaths that year. In 2016, the number of performed autopsies was 5873, which was 14.3% of all deaths that year. The toxicology test for alcohol was done routinely. Regarding this case, information was provided from the law enforcement agencies, including the possible crime place, probable time of death, and the presumable death mechanism. A descriptive method was used. The literature focusing on positional asphyxia was reviewed as well.

## 2. Case

A 51-year-old man died in a rural location while operating a tractor with a trailer. According to the preliminary police investigation, the accident happened at around 03:00 p.m. The deceased ignored the safety protocol and crouched under the trailer, where his clothes got pulled in by the rotating shaft, immobilizing the subject. The body was found at 10:30 p.m. in a semikneeling position under the trailer with his dorsal clothing stuck in the axis and his arms stretched out to the sides (Fig. 1).

The deceased was 172 cm of height and 75 kg of weight. At autopsy, external examination showed that the outerwear was loose and raised, located on the upper back. With the clothing removed, subcutaneous hemorrhages, abrasions, and parchment-like skin lesions were visible on the shoulders, and upper arms. A crush wound on the posterior surface of the left upper arm was also noted. The visible external injuries corresponded with the clothing creases and folds.

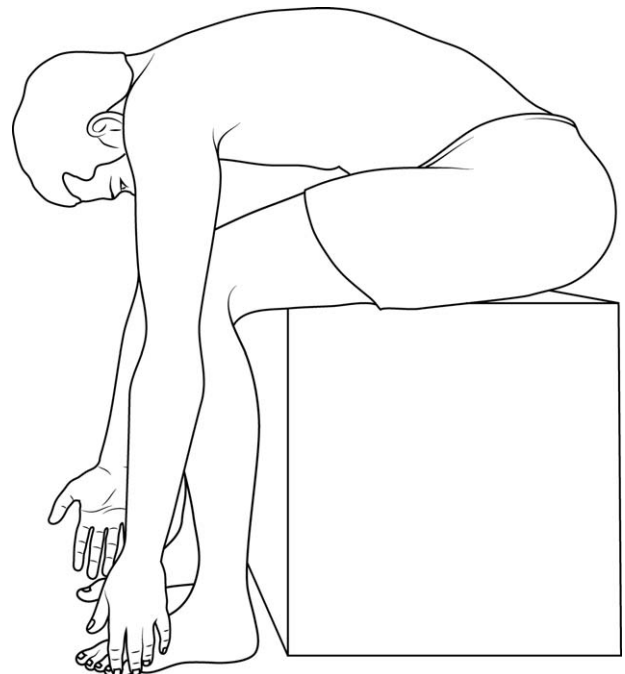
Internal examination of the body revealed signs of sudden death. Cerebral and pulmonary edema was evident, together with a general vascular congestion of the abdominal viscera. All other internal organs were generally congested with no other remarkable findings.

Toxicological analysis detected no ethanol in the blood or urine.

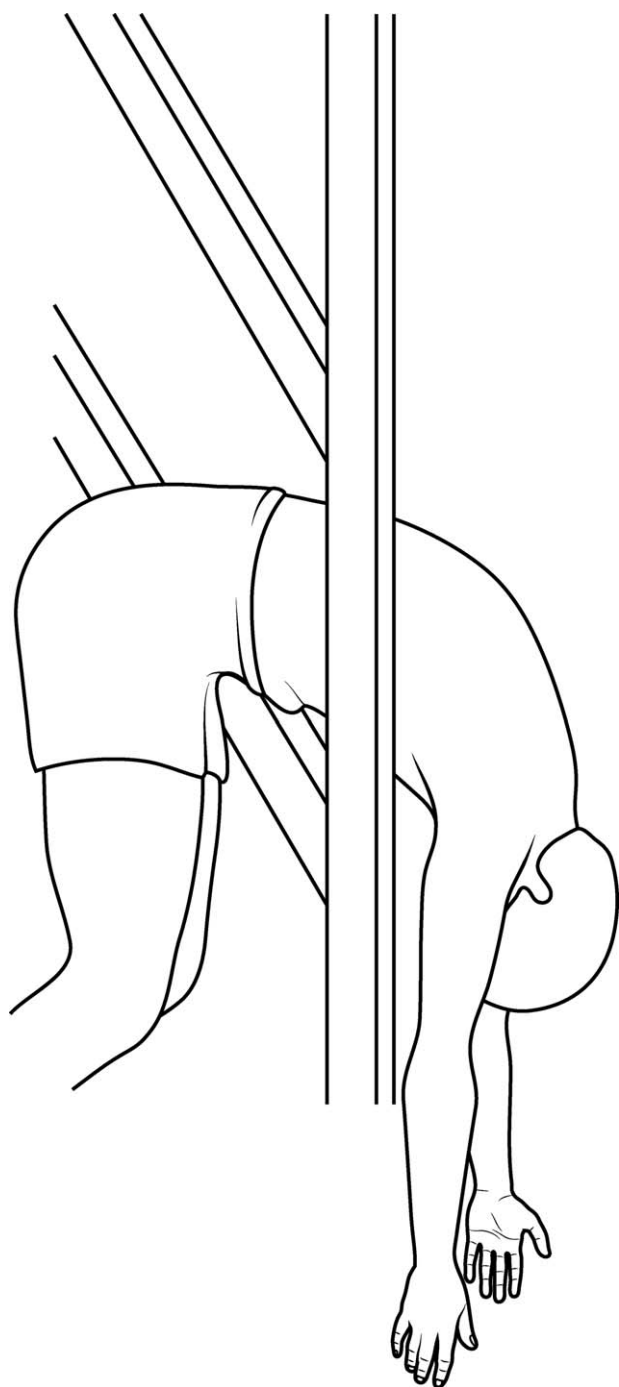
Asphyxia due to a fixed rib cage at the back, which significantly impaired respiratory movements, was determined as the cause of death.

## 3. Discussion

The classical signs of asphyxia mentioned (petechial hemorrhages of the conjunctivae, viscera and/or skin, cerebral and/or pulmonary edema, visceral congestion, the fluidity of the blood)



**Figure 2.** The body found sitting in an abnormal position.



**Figure 3.** The body found trapped in a door with a narrow window opening.

have been used in the diagnosis of asphyxial death for many years. However, these autopsy findings are known to be nonspecific and can appear in various other causes of death.<sup>[1]</sup> Thus, an assured conclusion mostly depends on the circumstances of the incident, especially in the case of positional asphyxia (Figs. 2 and 3).

Bell et al<sup>[10]</sup> were the first to use this term, along with suggesting certain criteria that could assist with the complicated diagnosis. Even though some of the criteria have been challenged by more recent publications, such as the requirement that the human body cannot be forced into the abnormal position,<sup>[11]</sup> the majority of authors still rely heavily on the main assessments made. These criteria essentially can be summarized into the following:<sup>[7,12]</sup>

1. Negative autopsy or some signs of asphyxia.
2. The body position must interfere with normal gas exchange.
3. It must be impossible for the subject to move to another position.
4. Other causes of death (natural and unnatural) must be excluded.

In the above-mentioned case report, the deceased seems to satisfy the criteria, with his position significantly compromising normal respiration, the reasons behind the inability to self-liberate evident and no fatal morphological findings present.

Since the first mentioning of positional asphyxia in 1992, a number of cases have been reported declaring it as a cause of death. A further review of literature revealed 37 cases (Table 1) meeting set conditions (reported individual descriptions of adult subjects since 1992, meeting the criteria of positional asphyxia mentioned above). Restraint asphyxia, a purposed form of positional asphyxia, still being a matter of discussion,<sup>[13,14]</sup> has been omitted.

One of the more commonly reported positions in literature is the inversion of the whole or only the upper part of the body (found in 23 out of the 37 cases). This position has a strong negative outcome on the body's hemodynamics.<sup>[15]</sup> The movement of the diaphragm increases pleural and intrathoracic pressures, which raises the systemic and pulmonary vascular resistance, while lowering the flow in the inferior vena cava and venous return to the heart. Thus, due to an increase of the afterload, a decrease of the preload and an initiated arterial reflex—cardiac output falls.<sup>[16]</sup> The inversion also causes an increase in hydrostatic pressure of the venous systems of the head, neck, and chest, as well as an increased static pressure in the carotid sinus.<sup>[12]</sup> The increased intrathoracic pressure, the decreased venous return and the provoked carotid sinus reflex are known factors, capable of affecting heart contractility and invoking bradycardia.<sup>[17]</sup> Whereas the venous retention in the extremities

**Table 1**  
**Included case reports.**

Purdue, B., 1992 <sup>[19]</sup> ;	Schafer, A., 2005 <sup>[32]</sup> ;	Benomran, F.A., 2010 <sup>[8]</sup> ;	Fernando, T., Byard RW, 2013 <sup>[9]</sup> ;
Lawler, W., 1993 <sup>[30]</sup> ;	Wick, R., Byard, R., 2006 <sup>[33]</sup> ;	Benomran, F.A. and Hassan A.I., 2011 <sup>[7]</sup> ;	Pareja-Pineda, J.I., et al, 2014 <sup>[39]</sup> ;
Madea, B., 1993 <sup>[15]</sup> ;	Fonsenca, C.A., 2007 <sup>[34]</sup> ;	Hayashi, et al, 2011 <sup>[41]</sup> ;	George, et al, 2016 <sup>[40]</sup> ;
Yoshida, et al, 1995 <sup>[31]</sup> ;	Conroy, et al, 2007 <sup>[35]</sup> ;	Martin, et al, 2011 <sup>[11]</sup> ;	Chaudhari, et al, 2016 <sup>[28]</sup>
Belviso, et al, 2003 <sup>[12]</sup> ;	Sauvageau, et al, 2008 <sup>[6]</sup> ;	Shields, L.B., Stewart, D., 2011 <sup>[36]</sup> ;	
Falk, et al, 2004 <sup>[3]</sup> ;	De Donno, A. et al, 2008 <sup>[27]</sup> ;	Hayashi, et al, 2012 <sup>[37]</sup> ;	
Padosch, et al, 2005 <sup>[26]</sup> ;	Byard, et al, 2008 <sup>[25]</sup> ;	Doberentz, E., Madea, B., 2012 <sup>[38]</sup> ;	

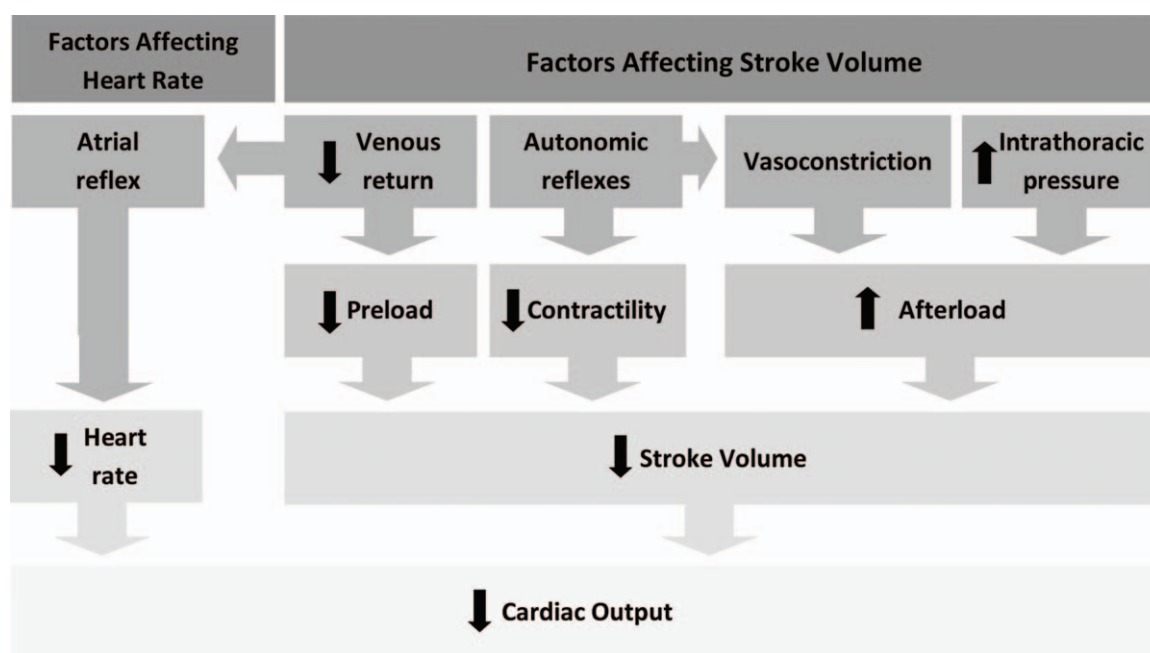


Figure 4. Interacting negative cardiovascular factors.

due to gravity can lead up to a 20% loss of circulating blood volume, causing relative hypovolemia, further venous return reduction.<sup>[18]</sup> Therefore, it seems that the increased blood volume in the upper half of the body induces negative cardiovascular effect through multiple interacting processes (Fig. 4), leading to inadequate circulation and oxygen distribution.

Some authors suggest that the restriction of thoracic movements may also be an important component, which could arise as a result of muscles tensing up in response to suspension (fixing the chest in expiration) and/or to the arms hanging freely (fixing the chest in inspiration).<sup>[19]</sup> Additionally, animal studies have revealed the significant impact of the abdominal viscera pressing on the diaphragm due to gravity,<sup>[20]</sup> which can be further exaggerated by the increased pressure as a result of a compressed torso. In the studies of abdominal compartment syndrome, it has been shown that elevated intra-abdominal pressure induces compression of the pulmonary parenchyma. Consequently, this leads to respiratory dysfunction, characterized by a decrease in total and an increase in non-aerated lung volumes, in addition to a decrease in gas diffusion across the alveolar-capillary membrane.<sup>[21]</sup> In fact, secondary acute respiratory distress syndrome is not uncommon among patients with abdominal compartment syndrome.<sup>[16]</sup>

Impediment of respiration movements is the predominant factor in a majority of other identified positions, not related to body inversion. Besides the mechanisms mentioned, this can also

be attained by the hyperflexion, hyperextension or confinement of the torso (mentioned in 7 cases, usually together with neck hyperflexion/hyperextension). Due to several accessory muscles of respiration arising directly from the scapula and the spine, these conditions can cause muscles to restrict the chest wall in an extreme expiration or inspiration, making it difficult for an individual to respire and eventually leading to respiratory muscle fatigue and hypoxia.<sup>[22,23]</sup> Thus, as seen in case, the force at each arm from being pulled by the shaft's rotation would fixate the chest in an expanded position, causing similar negative effect on breathing as seen in victims of crucifixion.<sup>[23]</sup>

Moreover, the abnormal positioning of the neck (hyperflexion established to be the most frequent, with or without torso hyperflexion described in 11 cases) has been reported to cause partial or complete external airway obstruction, preventing normal oxygenation of the blood.<sup>[10]</sup> This is particularly notable when the person is unconscious, as research shows that head posture has a marked effect on the collapsibility of the passive upper airway and the susceptibility for airway obstruction during sleep and sedation.<sup>[24]</sup>

Many positional asphyxia predisposing risk factors and conditions have been described. Those impairing individual's cognitive functions and normal reflexes, such as intoxication or organic disease, are among the most widely discussed.<sup>[25]</sup> Alcohol is a frequent hazard, as half of the 37 subject were intoxicated, with a mean post-mortem blood alcohol concentration of 2.5 g/L

Table 2

The victim's characteristics.

Men	Women	Alcohol intoxication	Obesity	Body inversion	Accidents		
83.8%	16.2%	45.9%	27.0%	62.2%	91.9%		
Age of men		Age of women		Body mass index		Alcohol concentration in blood	
Mean	SD	Mean	SD	Mean	SD	Mean	SD
47.5	18.3	61.3	23.3	36.9	8.5	2.5 g/L	0.7 g/L

SD = standard deviation.

(1.3–3.5g/L). These levels are usually sufficient to explain the lack of self-liberation attempt, as well as having an important impairing effect on the cardiovascular system.<sup>[26,27]</sup> Obesity has been described as a significant cause of being incapable of rising up from an inverted position.<sup>[28]</sup> In total, 10 subjects have been described as being significantly overweight (mean BMI of 36.9 [29.3–60.8]), 8 of which were found in a head-down body position. Not surprisingly, studies have shown that certain placement of obese patients (surgical), where the head is lower than the rest of the body, has a noteworthy negative cardiopulmonary effect, not seen in nonobese patients.<sup>[29]</sup> Other features commonly distinguished are older age and a strong male predominance (31 males, mean age 48.1±18.3 and 5 females, mean age 61.3±23.3). Majority (91.9%) of cases were deemed to be an accident (Table 2).

#### 4. Conclusion

Positional asphyxia is caused by insufficient pulmonary ventilation (or a combination of hemodynamic and respiratory dysfunctions), invoked by the effect of an abnormal and compromised body position. It is difficult to diagnose and is a rare cause of sudden death because of the non-specific morphological findings, depending largely on circumstantial evidence. It should be considered in cases that feature the following criteria: the body position hinders normal respiration; there is a reason behind the inability to alter this position; other causes of death were excluded first. The identification of possible co-factors through profound pathomorphological and toxicological examinations must be performed. The forensic medical examination must also be started at the scene of death. Therefore, police officers should submit photos and detailed description of the crime scene.

#### Author contributions

**Investigation:** Sigitas Chmieliauskas, Eimantas Mundinas, Dmitrij Fomin, Gerda Andriuskeviciute, Sigitas Laima, Eleonora Jurolaic.

**Supervision:** Jurgita Stasiuniene, Algimantas Jasulaitis.

#### References

- Saukko P, Knight B. *Knight's Forensic Pathology*. 3rd ed. 2004; Arnold Publication, London:352–367.
- Sauvageau A, Boghossian E. Classification of asphyxia: the need for standardization. *J Forensic Sci* 2011;56:264–1264.
- Falk J, Riepert T, Iffland R, et al. Death due to unusual position of the body—an explanation for the consequence of reduced venous reflux to the heart. *Arch Kriminol* 2004;213:102–7.
- Boghossian E, Tambuscio S, Sauvageau A. Nonchemical suffocation deaths in forensic setting: a 6-year retrospective study of environmental suffocation, smothering, choking, and traumatic/positional asphyxia. *J Forensic Sci* 2010;55:646–51.
- Pineda JJP, Vilorio VBB. Homicides due to positional asphyxia: two case reports. *Rom J Leg Med* 2014;22:229–32.
- Sauvageau A, Desjarlais A, Racette S. Deaths in a head-down position: a case report and review of the literature. *Forensic Sci Med Pathol* 2008;4:51–4.
- Benomran FA, Hassan AI. An unusual accidental death from positional asphyxia. *Am J Forensic Med Pathol* 2011;32:31–4.
- Benomran FA. Fatal accidental asphyxia in a jack-knife position. *J Forensic Leg Med* 2010;17:397–400.
- Fernando T, Byard RW. Positional asphyxia without active restraint following an assault. *J Forensic Sci* 2013;58:1633–5.
- Bell MD, Rao VJ, Wetli CV, et al. Positional asphyxiation in adults. A series of 30 cases from the Dade and Broward County Florida Medical Examiner Offices from 1982 to 1990. *Am J Forensic Med Pathol* 1992;13:101–7.
- Martin A, Miller JB, Walsh M, et al. Positional asphyxia in rollover vehicular incidents. *Inj Extra* 2011;42:1–3.
- Belviso M, De Donno A, Vitale L, et al. Positional asphyxia: reflection on 2 cases. *Am J Forensic Med Pathol* 2003;24:292–7.
- Laposata EA. Positional asphyxia during law enforcement transport. *Am J Forensic Med Pathol* 1993;14:86–7.
- Glatter K, Karch SB. Positional asphyxia: inadequate oxygen, or inadequate theory? *Forensic Sci Int* 2004;141:201–2.
- Madea B. Death in a head-down position. *Forensic Sci Int* 1993;61:119–32.
- Pelosi P, Quintel M, Malbrain MLNG. Effect of intra-abdominal pressure on respiratory mechanics. *Acta Clin Belg* 2007;62:78–88.
- Arthur W, Kaye G. The pathophysiology of common causes of syncope. *Postgrad Med J* 2000;76:750–3.
- Lee C, Porter KM. Suspension trauma. *Emerg Med J EMJ* 2007;24:237–8.
- Purdue B. An unusual accidental death from reverse suspension. *Am J Forensic Med Pathol* 1992;13:108–11.
- Uchigasaki S, Takahashi H, Suzuki T. An experimental study of death in a reverse suspension. *Am J Forensic Med Pathol* 1999;20:116–9.
- Papavramidis TS, Marinis AD, Pliakos I, et al. Abdominal compartment syndrome -intra-abdominal hypertension: defining, diagnosing, and managing. *J Emerg Trauma Shock* 2011;4:279–91.
- Max M. Houck. *Forensic Pathology*. 2017; Academic Press Publications, London:149–155.
- Bergeron JW. The crucifixion of Jesus: review of hypothesized mechanisms of death and implications of shock and trauma-induced coagulopathy. *J Forensic Leg Med* 2012;19:113–6.
- Walsh JH, Maddison KJ, Platt PR, et al. Influence of head extension, flexion, and rotation on collapsibility of the passive upper airway. *Sleep* 2008;31:1440–7.
- Byard RW, Wick R, Gilbert JD. Conditions and circumstances predisposing to death from positional asphyxia in adults. *J Forensic Leg Med* 2008;15:415–9.
- Padosch SA, Schmidt PH, Kröner LU, et al. Death due to positional asphyxia under severe alcoholisation: pathophysiologic and forensic considerations. *Forensic Sci Int* 2005;149:67–73.
- Donno A, Fazio A, Greco MG, et al. Death in head-down position in a heavily intoxicated obese man. *Leg Med Tokyo Jpn* 2008;10:204–9.
- Chaudhari VA, Ghodake DG, Kharat RD. Positional asphyxia: death due to unusual head-down position in a narrow space. *Am J Forensic Med Pathol* 2016;37:51–3.
- Brodsky JB. Positioning the morbidly obese patient for anesthesia. *Obes Surg* 2002;12:751–8.
- Lawler W. Death by reverse suspension. *Am J Forensic Med Pathol* 1993;14:87–8.
- Yoshida K, Harada K, Sorimachi Y, Makisumi T. Death in head-down position: an autopsy report with reference to physiological mechanism. *Nihon Hoigaku Zasshi* 1995;49:33–6.
- Schäfer AT. Death in a Head-Down Position. In: *Forensic Pathology Reviews*. Humana Press 2005;137–54.
- Wick R, Byard RW. Mechanisms of unexpected and/or sudden death in Lafora disease. *Forensic Sci Int* 2006;163:144–7.
- Fonseca CA. Reverse suspension. *American College of Forensic Examiners* 2007;16:34–7.
- Conroy C, Eastman AB, Stanley C, et al. Fatal positional asphyxia associated with rollover crashes. *Am J Forensic Med Pathol* 2007;28:330–2.
- Shields LBE, Stewart D. Deer stand fatalities in Kentucky: two cases of reverse suspension and blunt force trauma. *Am J Forensic Med Pathol* 2011;32:39–43.
- Hayashi T, Buschmann C, Correns A, et al. Fatal positional asphyxia. *Forensic Sci Med Pathol* 2012;8:470–2.
- Doberentz E, Madea B. Positional asphyxia-death in a head-down position after falling down stairs. *Arch Kriminol* 2012;230:128–36.
- Pareja-Pineda JI, Bravo Vilorio VB. Homicides due to positional asphyxia: two case reports. *Rom J Leg Med* 2014;22:229–32.
- George SB, Shetty SS, Raj MS, Shetty M. Death due to Positional Asphyxia – a Case Report. *International Journal of Medical Toxicology and Forensic Medicine* 2016;6:164–6.
- Hayashi T, Ago K, Ogata M. Positional asphyxia or diabetic ketoacidosis? A case report. *Leg Med (Tokyo)* 2011;13:196–200.