



## Case report

## Foreign body (kidney beans) in urinary bladder: An unusual case report

Ankita Jain<sup>a,\*</sup>, Manish Gupta<sup>b</sup>, Trilok Chand Sadasukhi<sup>b</sup>, Krishan Kumar Dangayach<sup>c</sup><sup>a</sup> Department of General Surgery, Mahatma Gandhi Medical College and Hospital, Jaipur, Rajasthan, India<sup>b</sup> Department of Urology, Mahatma Gandhi Medical College and Hospital, Jaipur, Rajasthan, India<sup>c</sup> Department of General Surgery, Mahatma Gandhi Medical College and Hospital, Jaipur, Rajasthan, India

## ARTICLE INFO

## Keywords:

Foreign body  
Bladder  
Kidney beans

## ABSTRACT

**Introduction:** Foreign body in urinary bladder has always been a topic of interest amongst the urologists and surgeon. Foreign body in lower urinary tract is not an unusual finding. Different types of foreign bodies has been retrieved from the lower urinary tract like for example, electric wire, safety pin, hairclip, intrauterine contraceptive device (IUCD), gauze pieces, battery, leech, hairballs and so on.

This article presents an unusual case report of the presence of kidney beans in the bladder, self-inflicted by the patient in the middle of the night for the purpose of sexual gratification or autoerotism. A 25 years old male patient, chef by occupation, presented to the outpatient department with history of insertion of 4 kidney beans 3 days back through his penis during the act of masturbation. The patient had complaints of dysuria, one episode, next morning after the act, which was relieved thereafter. Patient came to us only for the purpose of removal of the kidney beans. Attempt was made to remove the beans by non-invasive method by cystoscopy but as the beans were soaked in urine they got swollen and forceps removal was not possible. Hence, the kidney beans were removed by an invasive method by a suprapubic incision.

**Conclusion:** There has been many cases reported in literature about insertion of foreign bodies in bladder but presence of kidney beans in bladder is first of its kind as far as our knowledge is concerned.

## 1. Introduction

This case report has been reported in line with the SCARE criteria [22].

Foreign body in urinary bladder constitute an amusing finding faced by general surgeons and urologists. Intravesical or intraurethral foreign bodies usually found as a result of iatrogenic injuries, self-insertion, sexual abuse, assault, and migration from adjacent sites, although migration from adjacent sites is rare [1].

A wide range of foreign bodies has been reported in the urinary bladder, including electrical wires, chicken bones, wooden sticks, thermometers, bullets, intrauterine contraceptive devices (IUCDs), encrusted sutures, surgical staples with stones, needles, pencils, household batteries, gauze, screws, pessaries, ribbon gauze, parts of Foley catheters, broken parts of endoscopic instruments, and knotted suprapubic catheters [2–14].

Obtaining the actual history from patients with this condition is usually very difficult, especially for patients who have inserted the objects for sexual pleasure. This leads to delayed presentation of such patients to the doctor as they are embarrassed to disclose the sequence

of events that has made them visit the doctor.

The usual presentation of such patients is generally urinary tract infection, pain, and haematuria [15,16]. Some patients presents with no clinical findings but for the purpose of removal of foreign body. Radiopaque objects are detected by X-ray images while other can be detected by ultrasonography. The primary treatment includes careful removal of the foreign body causing minimal trauma to patients in order to avoid erectile dysfunction in male patients. With advances in endoscopic techniques, open surgery is not usually required, and the majority of cases can be treated using minimally invasive techniques. In this study, we share our experience dealing with red kidney beans present as foreign body in urinary bladder.

There are many cases in literature of foreign body in the bladder but this case is the first reported case of red kidney beans present as foreign body in bladder.

## 2. Case report

A 27 year old man, chef by occupation presented with a history of insertion of 4 kidney beans in the penis at night as a part of sexual

\* Corresponding author.

E-mail addresses: [dr.ankitajain18@gmail.com](mailto:dr.ankitajain18@gmail.com) (A. Jain), [guptadrmanish@gmail.com](mailto:guptadrmanish@gmail.com) (M. Gupta), [drsadasuki@rediffmail.com](mailto:drsadasuki@rediffmail.com) (T.C. Sadasukhi), [drkkdangayach@gmail.com](mailto:drkkdangayach@gmail.com) (K.K. Dangayach).<https://doi.org/10.1016/j.amsu.2018.06.009>

Received 13 September 2017; Received in revised form 15 May 2018; Accepted 13 June 2018

2049-0801/© 2018 The Authors. Published by Elsevier Ltd on behalf of IJS Publishing Group Ltd. This is an open access article under the CC BY-NC-ND license (<http://creativecommons.org/licenses/by-nc-nd/4.0/>).

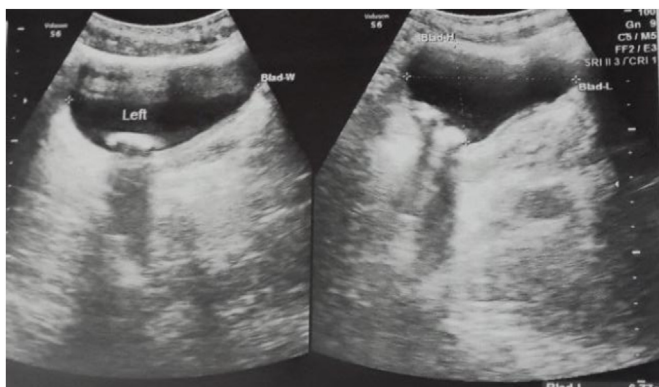


Fig. 1. Ultrasound abdomen showing multiple foreign body in urinary bladder.

gratification during the act of masturbation. Patient had complaints of lower urinary tract symptoms like dysuria for one day, thereafter he was asymptomatic and hence did not visit any doctor as patient was embarrassed to disclose the history. He had presented to the outpatient department for the purpose of removal of the beans after 3 days of the act. Patient had no past history of similar act. He had no history of any psychiatric illness or history of any medications in the past.

The patient was admitted and an X-ray erect of Kidney Ureter and Bladder (KUB), Ultrasonography, Retrograde urethrogram (RGU) and Micturating Cystourethrogram (MCU) was done. These investigations were done to confirm the nature of foreign body, and to identify the presence of any other foreign body in the bladder. X-ray KUB was normal as the foreign body was not radiopaque. RGU and MCU revealed no filling defect or stricture in the urethra. Ultrasonography suggested presence of multiple intravesical foreign body (Fig. 1).

The patient was admitted and cystoscopy was done. On cystoscopy the urethra was found to be normal, cystoscopy showed the presence of 4 kidney beans floating in the lumen of bladder (Fig. 2). The kidney beans were intact soaked in urine and swollen. Due to non-availability of stone punch forceps, triprong forceps was used to attempt the removal of the beans. While removing the beans with the forceps the outer covering of the beans was getting sloughed off but the beans could not be crushed. Hence procedure was abandoned and decision of an invasive or open procedure was taken up. Patient was catheterized by using a Foley's Catheter of 16 French size. The bladder was filled through the catheter and the catheter was clamped. A 5mm incision was given over the bladder, 2 cms above to the pubic symphysis. Cystoscope was inserted from this incision. Cystoscope removed and tract was dilated till 30ch/Fr and kidney beans withdrawn with the help of triprong forceps. Due to imbibition by urine the beans got softened and swollen and hence got broken during withdrawal by using triprong

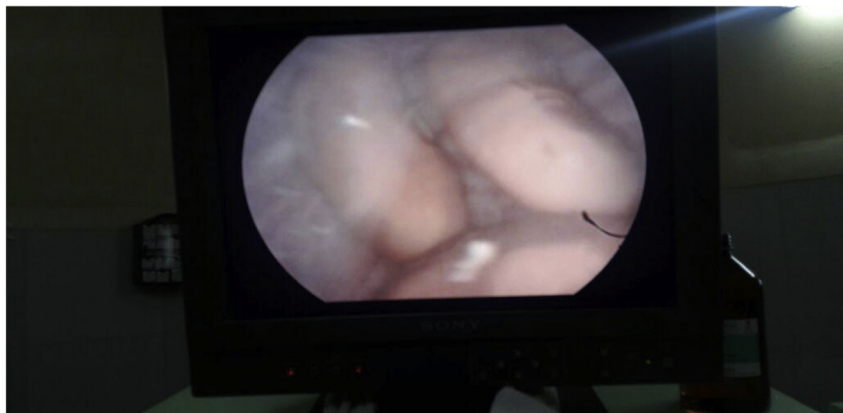

Fig. 2. Cystoscopic view showing kidney beans in urinary bladder, 4 in number. The kidney beans are intact and swollen due to imbibition of urine.

forceps. The beans were hence removed piecemeal as shown in Fig. 3. After complete removal of the beans the tract was closed in layers and catheter left in place, bladder was emptied. Patient was catheterized for 3 days. The patient was discharged after removal of catheter on day 4. Patient was advised a Psychiatry Reference for which patient refused and hence patient was discharged. The patient did not come for follow-up thereafter.

### 3. Discussion

Foreign body insertion in the urethra ascending upto the bladder is most commonly associated in view of sexual gratification or to relieve urinary symptoms [17].

Symptoms associated with intravesical foreign body range from acute urinary retention, cystitis, abdominal pain, frequency, urgency, strangury and sometimes it can be symptomless and patient only consults the doctor in view of its removal [18].

Kochakarn, Wachira et al. did a retrospective study of female patients presenting to the outpatient department with history of foreign body insertion over 20 years and the motives behind it and tabulated the data obtained.

The main mechanism was the insertion through urethra and the foreign body ascending up to reach the bladder. This study was conducted in females where urethra being short provides an easy access for foreign body to ascend up and reach the bladder without causing much difficulty. Also due to low visibility of the urethra, a foreign body can be inserted in the urethra accidentally during masturbation [10].

Similar study conducted by Van Ophoven et al., showed that foreign body in the bladder is most common via the ascending tract. The most common motive associated with foreign body insertion into the genitourinary tract was sexual or erotic in nature. The most suitable method of removing a urethral foreign body depends on the size and mobility of the object inserted to the genitourinary tract [15].

According to a study conducted by Rafique M on patients with intravesical foreign body of age group 14–70 years out of which 10 of them were men. Seven patients (43.8%) presented with iatrogenic intravesical foreign bodies, 5 (31.3%) had migrated foreign bodies from the adjacent organs, and 4 (25.0%) had self-introduced foreign bodies into the bladder. The objects included copper wire, carrot, lead pencil, intrauterine device, surgical gauze, pieces of foley catheter, and teflon beak of resectoscope sheath. All of these patients presented with complaints of urinary frequency and dysuria. Endoscopic retrieval was possible in 8 (50.0%) patients, and the remaining underwent open cystostomy [16]. This is similar to the procedure done on our patient, due to failure of endoscopic technique open cystostomy was attempted to remove the kidney beans.

Pec et al. also reported a case series of 23 men presenting with mechanical urethritis and with sepsis and gangrene of the external




Fig. 3. Kidney beans removed piecemeal.

genitalia due to self-insertion of foreign body [19].

Long term kept catheter can also lead to intravesical stone formation, or self removal of catheter can also leave behind the tip or the balloon of the catheter in the bladder presenting as a foreign body in bladder [20].

Removal of such foreign bodies can be done with endoscopic procedures or open surgery depending on the location of the foreign body. Foreign body lying below the urogenital diaphragm can be removed endoscopically while foreign bodies above the urogenital diaphragm requires endoscopic manipulation or open surgical procedures [21]. In our study the foreign body although present below the urogenital diaphragm was removed by open surgical technique.

Hence we can comment that, in cases of foreign body in bladder, the aim and objective of the intervention should be to remove the foreign body in-toto, as retained parts of the foreign body can further complicate the situation. This can be done by either endoscopic or open procedure. To avoid recurrence of such cases, a psychiatry consultation of such patients should be done, as recurrent self-infliction of foreign bodies can be life threatening leading to sepsis or even gangrene of the external genitalia.

#### 4. Conclusion

The present case report is first to be reported of foreign body being an eatable. Difficulties faced while removal of an eatable object is well explained in this case report when and we had to switch to an open method. The open method was taken up because an eatable always takes up water and liquid around it by imbibition and gets swollen up making it soft and friable. Any attempt to pull out such objects will lead to breakage and incomplete clearance of the foreign body. Hence in such cases the main aim should be complete clearance causing minimal damage to the organs. Open method of removal should not be considered as a failure or incompetency of the operating surgeon.

To conclude, intravesical foreign body can range from any types of easily available objects. Such cases requires prompt evaluation and removal. Total removal and complete clearance should be the main aim in such cases. A psychiatry evaluation of such patients should be done and patients should be counselled about the complications associated with such acts and not to repeat such incidences in future.

#### Ethical approval

Institutional ethics committee.

#### Sources of funding

None.

#### Author contribution

	Author 1 Jain A	Author 2 Gupta M	Author 3 Sadasukhi TC	Author 4 Dangayach KK
Concept	**Yes	Yes	Yes	
Design	Yes	Yes		
Definition of intellectual	Yes	Yes		
Literature search	Yes			Yes
Clinical studies	Yes			
Experimental studies		Yes		
Data acquisition	Yes			
Data analysis	Yes	Yes		
Statistical analysis	Yes			
Manuscript preparation	Yes	Yes	Yes	Yes
Manuscript editing			Yes	Yes
Manuscript review		Yes	Yes	Yes
Guarantor	Yes			

#### Conflicts of interest

None.

#### Research registration number

None.

#### Guarantor

Guarantor will be the corresponding author.

#### Consent

Written informed consent was obtained from the patient for publication of this case report and accompanying images. A copy of the written consent is available for review by the Editor-in-Chief of this journal on request.

#### References

- [1] T. Sukkarieh, M. Smaldone, B. Shah, Multiple foreign bodies in the anterior and posterior urethra, *Int. Braz J. Urol.* 30 (2004) 219–220.

- [2] P. Ejstrup, J. Poulsen, Laparoscopic removal of an electric wire from the bladder, *Br. J. Urol.* 80 (1997) 338.
- [3] N.J. Andrews, C.N. Hall, T.V. Taylor, Colovesical fistula caused by a chicken bone, *Br. J. Urol.* 62 (1988) 617.
- [4] D. Potter, D. Smith, A.J. Shorthouse, Colovesical fistula following ingestion of a foreign body, *Br. J. Urol.* 81 (1998) 499–500.
- [5] K. Nishiyama, T. Shimada, S. Yagi, M. Kawahara, M. Nakagawa, Endoscopic removal of intravesical thermometer using a rigid nephroscope and forceps, *Int. J. Urol.* 9 (2002) 717–718.
- [6] A. Gulanikar, P. Pandey, F. Terrell, A bullet in the bladder, *Br. J. Urol.* 82 (1998) 304.
- [7] T.A. el-Diasty, A.A. Shokeir, M.S. el-Gharib, L.S. Sherif, M.A. Shamaa, Bladder stone: a complication of intravesical migration of Lippes loop, *Scand. J. Urol. Nephrol.* 27 (1993) 279–280.
- [8] N.D. Forester, C. Evans, D.F. Thomas, A. Najmaldin, Bladder stones associated with synthetic absorbable sutures in children, *BJU Int.* 88 (2001) 984.
- [9] H.C. Ward, Surgical staples in bladder calculi after caecocystoplasty, *Br. J. Urol.* 60 (1987) 375.
- [10] W. Kochakarn, W. Pummanagura, Foreign bodies in the female urinary bladder: 20-year experience in Ramathibodi Hospital, *Asian J. Surg.* 31 (2008) 130–133.
- [11] T.Y. Lin, C.K. Chuang, Y.C. Wong, H.C. Liao, Gossypiboma: migration of retained surgical gauze and spontaneous transurethral protrusion, *BJU Int.* 84 (1999) 879–880.
- [12] S.D. Eckford, R.A. Persad, S.F. Brewster, J.C. Gingell, Intravesical foreign bodies: five-year review, *Br. J. Urol.* 69 (1992) 41–45.
- [13] G. Habermacher, R.B. Nadler, Intravesical holmium laser fragmentation and removal of detached resectoscope sheath tip, *J. Urol.* 174 (4 Pt 1) (2005) 1296–1297.
- [14] K.A. Hutton, S.N. Huddart, Percutaneous retrieval of an intravesical foreign body using direct transurethral visualization: a technique applicable to small children, *BJU Int.* 83 (1999) 337–338.
- [15] A. Van Ophoven, J.B. deKernion, Clinical management of foreign bodies of the genitourinary tract, *J. Urol.* 164 (2000) 274–287.
- [16] M. Rafique, Intravesical foreign bodies: review and current management strategies, *Urol. J.* 5 (2008) 223–231.
- [17] D.K. Pal, Intravesical foreign body, *Indian J. Surg.* 61 (1999) 381–383.
- [18] S.D. Eckford, R.A. Persad, S.F. Brewster, J.C. Gingell, Intravesical foreign bodies: five-year review, *Br. J. Urol.* 69 (1992) 41–45.
- [19] J. Pec, S. Straka, F. Novoesky, F. Novomesky, J. Khiment, M. Pec, et al., Mechanical urethritis and ascendant genitourinary infection due to sexual stimulation of the urethra by inserted foreign bodies, *Genitourin. Med.* 68 (1992) 399–400.
- [20] R.D. Kenney, Adolescent males who insert genitourinary foreign bodies: is psychiatric referral required? *Urology* 32 (1988) 127–129.
- [21] H. Aliabadi, A.S. Cass, P. Gleich, C.F. Johnson, Selfinflicted foreign bodies involving lower urinary tract and male genitals, *Urology* 26 (1985) 12–16.
- [22] R.A. Aghe, A.J. Fowler, A. Saetta, I. Barai, Rajmohan, D.P. Orgill, The SCARE Group, The SCARE statement: consensus-based surgical case report guidelines, *Int. J. Surg.* 34 (2016) 180–186.